



AMERICAN ACADEMY  
OF OPHTHALMOLOGY®  
Protecting Sight. Empowering Lives.

6

---

# Pediatric Ophthalmology and Strabismus

---

2019–2020  
**BCSC**  
Basic and Clinical  
Science Course™

## Editorial Committee

Robert W. Hered, MD, *Chair*  
Steven M. Archer, MD  
Rebecca Sands Braverman, MD  
Arif O. Khan, MD  
Katherine A. Lee, MD, PhD  
Gregg T. Lueder, MD  
Mary A. O'Hara, MD  
Kristina Tarczy-Hornoch, MD, DPhil





AMERICAN ACADEMY  
OF OPHTHALMOLOGY®

6

---

# Pediatric Ophthalmology and Strabismus

---

*Last major revision 2018–2019*

2019–2020  
**BCSC**  
Basic and Clinical  
Science Course™

The American Academy of Ophthalmology is accredited by the Accreditation Council for Continuing Medical Education (ACCME) to provide continuing medical education for physicians.

The American Academy of Ophthalmology designates this enduring material for a maximum of 15 *AMA PRA Category 1 Credits*<sup>™</sup>. Physicians should claim only the credit commensurate with the extent of their participation in the activity.

CME expiration date: June 1, 2021. *AMA PRA Category 1 Credits*<sup>™</sup> may be claimed only once between June 1, 2018, and the expiration date.

BCSC<sup>®</sup> volumes are designed to increase the physician's ophthalmic knowledge through study and review. Users of this activity are encouraged to read the text and then answer the study questions provided at the back of the book.

To claim *AMA PRA Category 1 Credits*<sup>™</sup> upon completion of this activity, learners must demonstrate appropriate knowledge and participation in the activity by taking the posttest for Section 6 and achieving a score of 80% or higher. For further details, please see the instructions for requesting CME credit at the back of the book.

The Academy provides this material for educational purposes only. It is not intended to represent the only or best method or procedure in every case, nor to replace a physician's own judgment or give specific advice for case management. Including all indications, contraindications, side effects, and alternative agents for each drug or treatment is beyond the scope of this material. All information and recommendations should be verified, prior to use, with current information included in the manufacturers' package inserts or other independent sources, and considered in light of the patient's condition and history. Reference to certain drugs, instruments, and other products in this course is made for illustrative purposes only and is not intended to constitute an endorsement of such. Some material may include information on applications that are not considered community standard, that reflect indications not included in approved FDA labeling, or that are approved for use only in restricted research settings. **The FDA has stated that it is the responsibility of the physician to determine the FDA status of each drug or device he or she wishes to use, and to use them with appropriate, informed patient consent in compliance with applicable law.** The Academy specifically disclaims any and all liability for injury or other damages of any kind, from negligence or otherwise, for any and all claims that may arise from the use of any recommendations or other information contained herein.

All trademarks, trade names, logos, brand names, and service marks of the American Academy of Ophthalmology (AAO), whether registered or unregistered, are the property of AAO and are protected by US and international trademark laws. These trademarks include AAO; AAOE; AMERICAN ACADEMY OF OPHTHALMOLOGY; BASIC AND CLINICAL SCIENCE COURSE; BCSC; EYENET; EYEWIKI; FOCAL POINTS; FOCUS DESIGN (logo shown on cover); IRIS; ISRS; OKAP; ONE NETWORK; OPHTHALMOLOGY; OPHTHALMOLOGY GLAUCOMA; OPHTHALMOLOGY RETINA; PREFERRED PRACTICE PATTERN; PROTECTING SIGHT. EMPOWERING LIVES; and THE OPHTHALMIC NEWS & EDUCATION NETWORK.

Cover image: From BCSC Section 9, *Uveitis and Ocular Inflammation*. Large mutton-fat keratic precipitates in a patient with sarcoidosis. (Courtesy of Debra Goldstein, MD.)



Copyright © 2019 American Academy of Ophthalmology. All rights reserved. No part of this publication may be reproduced without written permission.

Printed in China.

# Basic and Clinical Science Course

Louis B. Cantor, MD, Indianapolis, Indiana, *Senior Secretary for Clinical Education*  
Christopher J. Rapuano, MD, Philadelphia, Pennsylvania, *Secretary for Lifelong Learning and Assessment*  
Colin A. McCannel, MD, Los Angeles, California, *BCSC Course Chair*

## Section 6

---

### Faculty for the Major Revision

Robert W. Hered, MD, *Chair*, Maitland, Florida  
Steven M. Archer, MD, Ann Arbor, Michigan  
Rebecca Sands Braverman, MD, Aurora, Colorado  
Arif O. Khan, MD, Abu Dhabi, United Arab Emirates  
Katherine A. Lee, MD, PhD, Boise, Idaho  
Gregg T. Lueder, MD, St Louis, Missouri  
Mary A. O'Hara, MD, Sacramento, California  
Kristina Tarczy-Hornoch, MD, DPhil, Seattle, Washington

The Academy wishes to acknowledge the *American Association for Pediatric Ophthalmology and Strabismus (AAPOS)* and the *American Academy of Pediatrics (AAP), Section on Ophthalmology*, for recommending faculty members to the BCSC Section 6 committee.

The Academy also wishes to acknowledge the following committees for review of this edition:

*Committee on Aging:* Aaron M. Miller, MD, MBA, Shenandoah, Texas

*Vision Rehabilitation Committee:* Terry L. Schwartz, MD, Cincinnati, Ohio

*Practicing Ophthalmologists Advisory Committee for Education:* Alice Bashinsky, MD, *Primary Reviewer*, Asheville, North Carolina; Edward K. Isbey III, MD, *Chair*, Asheville, North Carolina; David J. Browning, MD, PhD, Charlotte, North Carolina; Bradley D. Fouraker, MD, Tampa, Florida; Steven J. Grosser, MD, Golden Valley, Minnesota; Stephen R. Klapper, MD, Carmel, Indiana; James A. Savage, MD, Memphis, Tennessee; Michelle S. Ying, MD, Ladson, South Carolina



*European Board of Ophthalmology:* Wagih Aclimandos, MB BCh, DO, FEBO, *EBO Chair*, London, United Kingdom; Peter J. Ringens, MD, PhD, *EBO Liaison*, Maastricht, Netherlands;

Georges Caputo, MD, Paris, France; Rosario Gómez de Liaño, MD, Madrid, Spain; Peng T. Khaw, MD, PhD, London, United Kingdom; Birgit Lorenz, MD, PhD, Giessen, Germany; Francis L. Munier, MD, Lausanne, Switzerland; Seyhan B. Özkan, MD, Aydin, Turkey; Maria Papadopoulos, MBBS, London, United Kingdom; Nicoline E. Schalij-Delfos, MD, PhD, Leiden, Netherlands

The Academy also wishes to acknowledge the following committee for assistance in developing study questions and answers for this BCSC Section:

*Self-Assessment Committee:* Mitchell B. Strominger, MD, *Chair*, Boston, Massachusetts; Deborah M. Costakos, MD, Milwaukee, Wisconsin; Theodore Curtis, MD, Mount Kisco, New York; Mark I. Salevitz, MD, Scottsdale, Arizona

## **Financial Disclosures**

Academy staff members who contributed to the development of this product state that within the 12 months prior to their contributions to this CME activity and for the duration of development, they have had no financial interest in or other relationship with any entity discussed in this course that produces, markets, resells, or distributes ophthalmic health care goods or services consumed by or used in patients, or with any competing commercial product or service.

The authors and reviewers state that within the 12 months prior to their contributions to this CME activity and for the duration of development, they have had the following financial relationships:\*

Dr Sands Braverman: Welch Allyn (C)

Dr Browning: Aerpio Therapeutics (S), Alcon Laboratories (S), Alimera Sciences (C), Genentech (S), Novartis Pharmaceuticals (S), Ohr Pharmaceuticals (S), Pfizer (S), Regeneron Pharmaceuticals (S), Zeiss (O)

Dr Fouraker: Addition Technology (C, L), Alcon Laboratories (C, L), KeraVision (C, L), OASIS Medical (C, L)

Dr Gómez de Liaño: Alcon Laboratories (C)

Dr Grosser: InjectSense (O), Ivantis (O)

Dr Hered: Moria Surgical (P)

Dr Isbey: Alcon Laboratories (S), Allscripts (C), Bausch + Lomb (S), Medflow (C), Oculoc Clinical Research (S)

Dr Khaw: Isarna Therapeutics (C), Novartis (C), Santen (C)

Dr Lorenz: Bausch + Lomb (C), Bayer HealthCare Pharmaceuticals (L), Clarity (L, S), Novartis Pharmaceuticals (L, S), Spark Therapeutics (C)

Dr Miller: Alcon Laboratories (L), Credential Protection (O)

Dr Schalij-Delfos: Novartis (C)

Dr Tarczy-Hornoch: Amgen (O), Mylan (O)

The other authors and reviewers state that within the 12 months prior to their contributions to this CME activity and for the duration of development, they have had no financial interest in or other relationship with any entity discussed in this course that produces, markets, resells, or distributes ophthalmic health care goods or services consumed by or used in patients, or with any competing commercial product or service.

\*C = consultant fees, paid advisory boards, or fees for attending a meeting; L = lecture fees (honoraria), travel fees, or reimbursements when speaking at the invitation of a commercial sponsor; O = equity ownership/stock options of publicly or privately traded firms (excluding mutual funds) with manufacturers of commercial ophthalmic products or commercial ophthalmic services; P = patents and/or royalties that might be viewed as creating a potential conflict of interest; S = grant support for the past year (all sources) and all sources used for a specific talk or manuscript with no time limitation

### **Recent Past Faculty**

Daniel J. Karr, MD  
Sylvia R. Kodsi, MD  
Stephen P. Kraft, MD  
Kanwal (Ken) Nischal, MD  
Evelyn A. Paysse, MD

In addition, the Academy gratefully acknowledges the contributions of numerous past faculty and advisory committee members who have played an important role in the development of previous editions of the Basic and Clinical Science Course.

### **American Academy of Ophthalmology Staff**

Dale E. Fajardo, EdD, MBA, *Vice President, Education*  
Beth Wilson, *Director, Continuing Professional Development*  
Ann McGuire, *Acquisitions and Development Manager*  
Stephanie Tanaka, *Publications Manager*  
D. Jean Ray, *Production Manager*  
Susan Malloy, *Acquisitions Editor and Program Manager*  
Jasmine Chen, *Manager of E-Learning*  
Beth Collins, *Medical Editor*  
Eric Gerdes, *Interactive Designer*  
Naomi Ruiz, *Publications Specialist*

American Academy of Ophthalmology  
655 Beach Street  
Box 7424  
San Francisco, CA 94120-7424



# Contents

General Introduction . . . . .	xix
<b>Objectives . . . . .</b>	<b>1</b>
<b>1 The Pediatric Eye Examination . . . . .</b>	<b>3</b>
Examination of Children in the Outpatient Setting . . . . .	3
History and Examination: General Considerations and Strategies . . . . .	3
Examination: Specific Elements. . . . .	5
Visual Acuity Assessment . . . . .	5
Red Reflex Examination and the Brückner Test . . . . .	9
Dynamic Retinoscopy . . . . .	9
Visual Field Testing . . . . .	10
Pupil Testing . . . . .	10
Anterior Segment Examination . . . . .	10
Intraocular Pressure Measurement . . . . .	10
Cycloplegic Refraction . . . . .	10
Fundus Examination . . . . .	12
<b>PART I Strabismus . . . . .</b>	<b>13</b>
<b>2 Strabismus Terminology . . . . .</b>	<b>15</b>
Definitions. . . . .	15
Prefixes and Suffixes. . . . .	15
Strabismus Classification Terms. . . . .	16
Abbreviations for Types of Strabismus . . . . .	17
<b>3 Anatomy of the Extraocular Muscles . . . . .</b>	<b>19</b>
Origin, Course, Insertion, and Innervation of the Extraocular Muscles . . . . .	19
Horizontal Rectus Muscles . . . . .	20
Vertical Rectus Muscles . . . . .	20
Oblique Muscles . . . . .	20
Levator Palpebrae Superioris Muscle. . . . .	22
Relationship of the Rectus Muscle Insertions . . . . .	22
Blood Supply of the Extraocular Muscles. . . . .	23
Arterial System . . . . .	23
Venous System . . . . .	23
Structure of the Extraocular Muscles . . . . .	24
Orbital and Fascial Relationships . . . . .	25
Adipose Tissue . . . . .	25
Muscle Cone . . . . .	26



Muscle Capsule . . . . .	26
The Tenon Capsule . . . . .	26
The Pulley System . . . . .	28
Anatomical Considerations for Ophthalmic Procedures . . . . .	28
<b>4 Motor Physiology . . . . .</b>	<b>31</b>
Basic Principles and Terms . . . . .	31
Ocular Rotations . . . . .	31
Positions of Gaze . . . . .	31
Extraocular Muscle Action . . . . .	31
Eye Movements . . . . .	32
Motor Units . . . . .	32
Monocular Eye Movements . . . . .	33
Binocular Eye Movements . . . . .	37
Supranuclear Control Systems for Eye Movement . . . . .	40
<b>5 Sensory Physiology and Pathology . . . . .</b>	<b>41</b>
The Physiology of Normal Binocular Vision . . . . .	41
Retinal Correspondence . . . . .	41
Fusion . . . . .	42
Selected Aspects of the Neurophysiology of Vision . . . . .	43
Visual Development . . . . .	44
Effects of Abnormal Visual Experience on the Retinogeniculocortical Pathway . . . . .	44
Abnormalities of Binocular Vision . . . . .	47
Visual Confusion . . . . .	47
Diplopia . . . . .	47
Sensory Adaptations in Strabismus . . . . .	48
Suppression . . . . .	48
Anomalous Retinal Correspondence . . . . .	50
Monofixation Syndrome . . . . .	51
<b>6 Amblyopia . . . . .</b>	<b>53</b>
Epidemiology . . . . .	53
Pathophysiology . . . . .	53
Classification . . . . .	54
Strabismic Amblyopia . . . . .	54
Refractive Amblyopia . . . . .	54
Visual Deprivation Amblyopia . . . . .	55
Detection and Screening . . . . .	56
Evaluation . . . . .	56
Treatment . . . . .	57
Cataract Removal . . . . .	57
Refractive Correction . . . . .	57
Occlusion Therapy . . . . .	58
Pharmacologic or Optical Treatment . . . . .	58
Binocular Treatment . . . . .	59
Complications and Challenges of Therapy . . . . .	59

<b>7</b>	<b>Diagnostic Evaluation of Strabismus and Torticollis . . .</b>	<b>63</b>
	Obtaining a History in Cases of Strabismus or Torticollis . . . . .	63
	Assessment of Ocular Alignment . . . . .	64
	Diagnostic Positions of Gaze . . . . .	64
	Cover Tests . . . . .	64
	Corneal Light Reflex and Red Reflex Tests . . . . .	67
	Subjective Tests of Ocular Alignment . . . . .	68
	Assessment of Eye Movements . . . . .	71
	Ocular Rotations . . . . .	71
	Convergence . . . . .	71
	Fusional Vergence . . . . .	72
	Forced Duction, Active Force Generation, and Saccadic Velocity . . . . .	73
	The 3-Step Test . . . . .	73
	Tests of Sensory Adaptation and Binocular Function . . . . .	75
	The Red-Glass (Diplopia) Test . . . . .	75
	Bagolini Lenses . . . . .	77
	The $4\Delta$ Base-Out Prism Test . . . . .	78
	The Afterimage Test . . . . .	79
	Amblyoscope Testing . . . . .	79
	The Worth 4-Dot Test . . . . .	80
	Stereoacuity Tests . . . . .	81
	Assessment of the Field of Single Binocular Vision . . . . .	81
	The Prism Adaptation Test . . . . .	82
	Torticollis: Differential Diagnosis and Evaluation . . . . .	82
	Ocular Torticollis . . . . .	82
<b>8</b>	<b>Esodeviations . . . . .</b>	<b>85</b>
	Epidemiology . . . . .	85
	Pseudoesotropia . . . . .	85
	Infantile (Congenital) Esotropia . . . . .	87
	Pathogenesis . . . . .	87
	Clinical Features and Evaluation . . . . .	87
	Management . . . . .	88
	Accommodative Esotropia . . . . .	90
	Pathogenesis and Types of Accommodative Esotropia . . . . .	90
	Evaluation . . . . .	91
	Management . . . . .	91
	Acquired Nonaccommodative Esotropia . . . . .	92
	Basic Acquired Nonaccommodative Esotropia . . . . .	93
	Cyclic Esotropia . . . . .	93
	Sensory Esotropia . . . . .	93
	Divergence Insufficiency . . . . .	94
	Spasm of the Near Reflex . . . . .	94
	Consecutive Esotropia . . . . .	95
	Nystagmus and Esotropia . . . . .	95
	Incomitant Esotropia . . . . .	95
	Sixth Nerve Palsy . . . . .	95
	Other Forms of Incomitant Esotropia . . . . .	97

<b>9</b>	<b>Exodeviations</b> . . . . .	<b>99</b>
	Pseudoexotropia . . . . .	99
	Exophoria . . . . .	99
	Intermittent Exotropia. . . . .	99
	Clinical Characteristics . . . . .	99
	Evaluation . . . . .	100
	Treatment . . . . .	101
	Convergence Insufficiency . . . . .	103
	Constant Exotropia . . . . .	103
	Infantile Exotropia . . . . .	103
	Sensory Exotropia . . . . .	104
	Consecutive Exotropia . . . . .	104
	Other Forms of Exotropia . . . . .	105
	Exotropic Duane Retraction Syndrome. . . . .	105
	Neuromuscular Abnormalities . . . . .	105
	Dissociated Horizontal Deviation . . . . .	105
	Convergence Paralysis . . . . .	105
<b>10</b>	<b>Pattern Strabismus</b> . . . . .	<b>107</b>
	Etiology . . . . .	107
	Clinical Features and Identification of Pattern Strabismus . . . . .	109
	V Pattern . . . . .	109
	A Pattern. . . . .	109
	Y Pattern. . . . .	109
	X Pattern. . . . .	110
	λ Pattern . . . . .	110
	Management . . . . .	110
	Surgical Correction of Pattern Deviations: General Principles . . . . .	110
	Surgical Treatment of Specific Patterns . . . . .	111
<b>11</b>	<b>Vertical Deviations</b> . . . . .	<b>115</b>
	A Clinical Approach to Vertical Deviations. . . . .	115
	Vertical Deviations With Marked Horizontal Incomitance . . . . .	116
	Overelevation and Overdepression in Adduction . . . . .	116
	Superior Oblique Muscle Palsy . . . . .	119
	Inferior Oblique Muscle Palsy. . . . .	124
	Skew Deviation . . . . .	125
	Other Conditions With Incomitant Vertical Deviations. . . . .	125
	Vertical Deviations With Horizontal Comitance . . . . .	125
	Monocular Elevation Deficiency . . . . .	125
	Orbital Floor Fractures. . . . .	127
	Other Conditions With Comitant Vertical Deviations . . . . .	128
	Dissociated Vertical Deviation . . . . .	129
	Clinical Features . . . . .	129
	Management . . . . .	130
<b>12</b>	<b>Special Motility Disorders</b> . . . . .	<b>131</b>
	Congenital Cranial Dysinnervation Disorders . . . . .	131
	Duane Retraction Syndrome . . . . .	131

Congenital Fibrosis of the Extraocular Muscles . . . . .	134
Möbius Syndrome . . . . .	135
Miscellaneous Special Forms of Strabismus . . . . .	136
Brown Syndrome . . . . .	136
Third Nerve Palsy . . . . .	138
Fourth Nerve Palsy . . . . .	140
Sixth Nerve Palsy . . . . .	140
Thyroid Eye Disease . . . . .	140
Chronic Progressive External Ophthalmoplegia . . . . .	141
Myasthenia Gravis . . . . .	142
Esotropia and Hypotropia Associated With High Myopia . . . . .	143
Internuclear Ophthalmoplegia . . . . .	144
Ocular Motor Apraxia . . . . .	144
Superior Oblique Myokymia . . . . .	145
Strabismus Associated With Other Ocular Surgery . . . . .	145
<b>13 Childhood Nystagmus . . . . .</b>	<b>147</b>
General Features . . . . .	147
Nomenclature . . . . .	147
Types of Childhood Nystagmus . . . . .	148
Infantile Nystagmus Syndrome (Congenital Nystagmus) . . . . .	148
Central Vestibular Instability Nystagmus (Periodic Alternating Nystagmus) . . . . .	149
Fusion Maldevelopment Nystagmus Syndrome (Latent Nystagmus) . . . . .	150
Acquired Nystagmus . . . . .	151
Nystagmus-Like Disorders . . . . .	152
Induced Convergence-Retraction (Convergence-Retraction Nystagmus) . . . . .	152
Opsoclonus . . . . .	153
Evaluation . . . . .	153
History . . . . .	153
Ocular Examination . . . . .	153
Treatment . . . . .	155
Prisms . . . . .	155
Surgery . . . . .	155
<b>14 Surgery of the Extraocular Muscles . . . . .</b>	<b>159</b>
Evaluation . . . . .	159
Indications for Surgery . . . . .	159
Planning Considerations . . . . .	160
Vision . . . . .	160
General Considerations . . . . .	160
Incomitance . . . . .	161
Cyclovertical Strabismus . . . . .	162
Prior Surgery . . . . .	162
Surgical Techniques for the Extraocular Muscles and Tendons . . . . .	162
Approaches to the Extraocular Muscles . . . . .	162
Rectus Muscle Weakening Procedures . . . . .	163
Rectus Muscle Tightening Procedures . . . . .	163

Rectus Muscle Surgery for Hypotropia and Hypertropia . . . . .	164
Adjustable Sutures. . . . .	165
Oblique Muscle Weakening Procedures . . . . .	165
Oblique Muscle Tightening Procedures . . . . .	166
Stay Sutures . . . . .	167
Transposition Procedures . . . . .	167
Posterior Fixation . . . . .	167
Complications of Strabismus Surgery . . . . .	168
Diplopia . . . . .	168
Unsatisfactory Alignment . . . . .	168
Iatrogenic Brown Syndrome . . . . .	168
Anti-Elevation Syndrome . . . . .	168
Lost and Slipped Muscles. . . . .	169
Pulled-in-Two Syndrome. . . . .	169
Perforation of the Sclera . . . . .	170
Postoperative Infections . . . . .	170
Pyogenic Granuloma and Foreign-Body Granuloma . . . . .	170
Epithelial Cyst . . . . .	170
Conjunctival Scarring . . . . .	171
Adherence Syndrome . . . . .	172
Delle . . . . .	172
Anterior Segment Ischemia. . . . .	172
Change in Eyelid Position . . . . .	173
Refractive Changes . . . . .	173
Anesthesia for Extraocular Muscle Surgery. . . . .	174
Methods . . . . .	174
Postoperative Nausea and Vomiting . . . . .	174
Oculocardiac Reflex . . . . .	174
Malignant Hyperthermia. . . . .	174
Chemodenervation Using Botulinum Toxin . . . . .	175
Pharmacology and Mechanism of Action. . . . .	175
Indications, Techniques, and Results. . . . .	175
Complications . . . . .	176

**PART II Pediatric Ophthalmology . . . . . 177**

**15 Growth and Development of the Eye . . . . . 179**

Normal Growth and Development . . . . .	179
Dimensions of the Eye . . . . .	179
Refractive State . . . . .	180
Orbit and Ocular Adnexa . . . . .	181
Cornea, Iris, Pupil, and Anterior Chamber . . . . .	181
Intraocular Pressure . . . . .	181
Extraocular Muscles. . . . .	181
Retina . . . . .	182
Visual Acuity and Stereoacuity . . . . .	182
Abnormal Growth and Development . . . . .	182

<b>16</b>	<b>Decreased Vision in Infants and Pediatric Vision Rehabilitation . . . . .</b>	<b>185</b>
	Visual Development in Young Infants . . . . .	185
	Classification of Visual Impairment in Infants and Children . . . . .	186
	Pregeniculate Visual Impairment . . . . .	186
	Cerebral Visual Impairment . . . . .	186
	Delayed Visual Maturation . . . . .	186
	Evaluation of the Infant With Decreased Vision . . . . .	187
	Pediatric Low Vision Rehabilitation . . . . .	188
<b>17</b>	<b>Eyelid Disorders . . . . .</b>	<b>191</b>
	Congenital Eyelid Disorders . . . . .	191
	Dystopia Canthorum . . . . .	191
	Cryptophthalmos . . . . .	191
	Ablepharon . . . . .	193
	Congenital Coloboma of the Eyelid . . . . .	193
	Ankyloblepharon . . . . .	193
	Congenital Ectropion . . . . .	194
	Congenital Entropion . . . . .	194
	Epiblepharon . . . . .	194
	Congenital Tarsal Kink . . . . .	194
	Distichiasis . . . . .	195
	Euryblepharon . . . . .	195
	Epicanthus . . . . .	196
	Palpebral Fissure Slants . . . . .	196
	Congenital Ptosis . . . . .	196
	Other Causes of Ptosis in Children . . . . .	198
	Infectious and Inflammatory Eyelid Disorders . . . . .	198
	Vascular Eyelid Disorders . . . . .	199
	Port-Wine Stain . . . . .	199
	Eyelid Hemangioma . . . . .	199
	Neoplasms and Other Noninflammatory Eyelid Lesions . . . . .	199
	Pilomatricoma . . . . .	200
	Epithelial Lesions . . . . .	200
	Eyelid Nevi . . . . .	200
	Other Eyelid Conditions . . . . .	201
	Trichotillomania . . . . .	201
	Excessive Blinking . . . . .	201
<b>18</b>	<b>Orbital Disorders . . . . .</b>	<b>203</b>
	Abnormal Interocular Distance: Terminology and Associations . . . . .	203
	Congenital and Developmental Disorders: Craniofacial	
	Malformations . . . . .	203
	Craniosynostosis . . . . .	203
	Nonsynostotic Craniofacial Conditions . . . . .	209
	Infectious and Inflammatory Conditions . . . . .	212
	Preseptal Cellulitis . . . . .	212

Orbital Cellulitis . . . . .	213
Childhood Orbital Inflammation . . . . .	215
Neoplasms . . . . .	216
Differential Diagnosis . . . . .	216
Primary Malignant Neoplasms . . . . .	217
Metastatic Tumors . . . . .	218
Hematopoietic, Lymphoproliferative, and Histiocytic Neoplasms . . . . .	218
Benign Tumors . . . . .	219
Ectopic Tissue Masses . . . . .	223
Cystic Lesions . . . . .	223
Teratoma. . . . .	225
Ectopic Lacrimal Gland . . . . .	226
<b>19 Lacrimal Drainage System Abnormalities . . . . .</b>	<b>227</b>
Congenital and Developmental Anomalies . . . . .	227
Atresia of the Lacrimal Puncta or Canaliculi . . . . .	227
Congenital Lacrimal Fistula . . . . .	228
Dacryocystocele . . . . .	228
Congenital Nasolacrimal Duct Obstruction . . . . .	230
Clinical Features and Examination. . . . .	230
Nonsurgical Management . . . . .	231
Surgical Management . . . . .	232
<b>20 External Diseases of the Eye . . . . .</b>	<b>237</b>
Infectious Conjunctivitis. . . . .	237
Ophthalmia Neonatorum . . . . .	237
Bacterial Conjunctivitis in Children and Adolescents. . . . .	240
Viral Conjunctivitis in Infants and Children . . . . .	241
Inflammatory Disease . . . . .	244
Blepharitis . . . . .	244
Ocular Allergy . . . . .	246
Ligneous Conjunctivitis . . . . .	249
Other Conjunctival and Subconjunctival Disorders . . . . .	250
Papillomas . . . . .	250
Conjunctival Epithelial Inclusion Cysts. . . . .	250
Conjunctival Nevi . . . . .	250
Ocular Melanocytosis . . . . .	250
Stevens-Johnson Syndrome and Toxic Epidermal Necrolysis . . . . .	251
<b>21 Disorders of the Anterior Segment . . . . .</b>	<b>253</b>
Abnormalities of Corneal Size or Shape . . . . .	253
Megalocornea . . . . .	253
Microcornea . . . . .	254
Keratoglobus . . . . .	254
Keratoconus . . . . .	254
Abnormalities of Peripheral Corneal Transparency . . . . .	255
Posterior Embryotoxon . . . . .	255

Cornea Plana . . . . .	255
Epibulbar Dermoid . . . . .	256
Dermolipoma . . . . .	256
Abnormalities of Central and Diffuse Corneal Transparency . . . . .	257
Primary Causes . . . . .	258
Secondary Causes . . . . .	259
Treatment of Corneal Opacities . . . . .	262
Congenital and Developmental Anomalies of the Globe . . . . .	263
Microphthalmia, Anophthalmia, and Coloboma. . . . .	263
Nanophthalmos. . . . .	263
Congenital and Developmental Anomalies of the Iris or Pupil. . . . .	264
Abnormalities of the Iris . . . . .	264
Abnormalities in the Size, Shape, or Location of the Pupil. . . . .	267
Acquired Corneal Conditions . . . . .	269
Keratitis . . . . .	269
Systemic Diseases Affecting the Cornea or Iris . . . . .	269
Metabolic Disorders Affecting the Cornea or Iris . . . . .	269
Other Systemic Diseases Affecting the Cornea or Iris . . . . .	271
Tumors of the Anterior Segment . . . . .	271
Cornea . . . . .	271
Iris . . . . .	271
Ciliary Body . . . . .	273
Miscellaneous Clinical Signs . . . . .	274
Pediatric Iris Heterochromia . . . . .	274
Anisocoria . . . . .	275

**22 Pediatric Glaucomas . . . . . 277**

Classification. . . . .	277
Genetics. . . . .	277
Primary Childhood Glaucoma . . . . .	278
Primary Congenital Glaucoma . . . . .	278
Juvenile Open-Angle Glaucoma . . . . .	284
Secondary Childhood Glaucoma . . . . .	284
Secondary Glaucoma Associated With an Acquired Condition . . . . .	284
Glaucoma Following Cataract Surgery . . . . .	285
Treatment . . . . .	285
Surgical Therapy . . . . .	285
Medical Therapy . . . . .	288
Prognosis and Follow-Up . . . . .	290

**23 Childhood Cataracts and Other Pediatric Lens Disorders. . . . . 293**

Pediatric Cataracts . . . . .	293
General Features . . . . .	293
Morphology . . . . .	294
Evaluation of Pediatric Cataracts . . . . .	299
Examination . . . . .	300



Cataract Surgery in Pediatric Patients . . . . .	301
Timing of the Procedure . . . . .	301
Intraocular Lens Use in Children . . . . .	301
Management of the Anterior Capsule . . . . .	302
Lensectomy Without Intraocular Lens Implantation . . . . .	302
Lensectomy With Intraocular Lens Implantation . . . . .	302
Postoperative Care . . . . .	304
Complications Following Pediatric Cataract Surgery . . . . .	304
Visual Outcome After Cataract Extraction . . . . .	305
Structural or Positional Lens Abnormalities . . . . .	305
Congenital Aphakia . . . . .	305
Spherophakia. . . . .	305
Coloboma . . . . .	305
Dislocated Lenses in Children . . . . .	306
Isolated Ectopia Lentis . . . . .	307
Ectopia Lentis et Pupillae. . . . .	307
Marfan Syndrome . . . . .	307
Homocystinuria . . . . .	308
Weill-Marchesani Syndrome . . . . .	309
Sulfite Oxidase Deficiency . . . . .	310
Treatment . . . . .	310

**24 Uveitis in the Pediatric Age Group . . . . . 311**

Epidemiology . . . . .	311
Classification. . . . .	311
Anterior Uveitis . . . . .	312
Juvenile Idiopathic Arthritis . . . . .	312
Juvenile Spondyloarthropathies . . . . .	315
Tubulointerstitial Nephritis and Uveitis Syndrome . . . . .	316
Kawasaki Disease . . . . .	316
Other Causes of Anterior Uveitis . . . . .	316
Intermediate Uveitis. . . . .	316
Posterior Uveitis . . . . .	317
Toxoplasmosis . . . . .	317
Toxocariasis . . . . .	317
Other Causes of Posterior Uveitis . . . . .	318
Panuveitis . . . . .	318
Sarcoidosis . . . . .	318
Familial Juvenile Systemic Granulomatosis . . . . .	319
Vogt-Koyanagi-Harada Syndrome . . . . .	319
Other Causes of Panuveitis . . . . .	319
Masquerade Syndromes . . . . .	319
Evaluation of Pediatric Uveitis . . . . .	319
Treatment of Pediatric Uveitis . . . . .	320
Management of Inflammation . . . . .	320
Surgical Treatment of Complications of Uveitis . . . . .	322

<b>25</b>	<b>Disorders of the Retina and Vitreous . . . . .</b>	<b>325</b>
	Congenital and Developmental Abnormalities . . . . .	325
	Persistent Fetal Vasculature . . . . .	325
	Retinopathy of Prematurity . . . . .	325
	Hereditary Retinal Disease . . . . .	335
	Hereditary Macular Dystrophies . . . . .	339
	Hereditary Vitreoretinopathies . . . . .	342
	Infectious Diseases . . . . .	348
	Herpes Simplex Virus and Cytomegalovirus . . . . .	348
	Human Immunodeficiency Virus . . . . .	348
	Tumors . . . . .	349
	Choroidal and Retinal Pigment Epithelial Lesions . . . . .	349
	Retinoblastoma . . . . .	351
	Acquired Disorders . . . . .	358
	Coats Disease . . . . .	358
<b>26</b>	<b>Optic Disc Abnormalities . . . . .</b>	<b>361</b>
	Developmental Anomalies . . . . .	361
	Optic Nerve Hypoplasia . . . . .	361
	Morning Glory Disc Anomaly . . . . .	362
	Optic Nerve Coloboma . . . . .	364
	Optic Nerve Pit . . . . .	364
	Myelinated Retinal Nerve Fiber Layer . . . . .	365
	Tilted Disc . . . . .	365
	Bergmeister Papilla . . . . .	366
	Megalopapilla . . . . .	366
	Peripapillary Staphyloma . . . . .	366
	Optic Nerve Aplasia . . . . .	366
	Melanocytoma of the Optic Disc . . . . .	367
	Optic Atrophy . . . . .	367
	Dominant Optic Atrophy, Kjer Type . . . . .	367
	Recessive Optic Atrophy . . . . .	368
	Leber Hereditary Optic Neuropathy . . . . .	368
	Optic Neuritis . . . . .	369
	Papilledema . . . . .	370
	Idiopathic Intracranial Hypertension . . . . .	370
	Pseudopapilledema . . . . .	372
	Drusen . . . . .	373
<b>27</b>	<b>Ocular Trauma in Childhood . . . . .</b>	<b>375</b>
	Special Considerations in the Management of Pediatric	
	Ocular Trauma . . . . .	375
	Accidental Trauma . . . . .	375
	Corneal Abrasion . . . . .	376
	Thermal Injury . . . . .	376
	Chemical Injury . . . . .	376
	Corneal Foreign Body . . . . .	376

Penetrating or Perforating Injury . . . . .	376
Blunt Injury . . . . .	378
Orbital Fractures . . . . .	379
Traumatic Optic Neuropathy . . . . .	381
Nonaccidental Trauma . . . . .	381
Abusive Head Trauma . . . . .	381
Ocular Injury Secondary to Nonaccidental Trauma . . . . .	384

**28 Ocular Manifestations of Systemic Disease . . . . . 385**

Diseases due to Chromosomal Abnormalities. . . . .	385
Inborn Errors of Metabolism . . . . .	385
Familial Oculorenal Syndromes . . . . .	391
Lowe Syndrome . . . . .	391
Alport Syndrome . . . . .	391
Ciliopathies . . . . .	391
Neuro-Oculocutaneous Syndromes . . . . .	392
Neurofibromatosis Type 1 . . . . .	392
Neurofibromatosis Type 2 . . . . .	397
Tuberous Sclerosis. . . . .	397
Von Hippel–Lindau Disease . . . . .	399
Sturge-Weber Syndrome . . . . .	401
Ataxia-Telangiectasia . . . . .	403
Incontinentia Pigmenti . . . . .	404
Wyburn-Mason Syndrome . . . . .	405
Klippel-Trénaunay Syndrome . . . . .	406
Albinism . . . . .	406
Diagnosis . . . . .	406
Treatment . . . . .	408
Diabetes Mellitus . . . . .	408
Intrauterine or Perinatal Infection. . . . .	409
Toxoplasmosis . . . . .	409
Rubella . . . . .	410
Cytomegalovirus . . . . .	411
Herpes Simplex Virus . . . . .	412
Syphilis . . . . .	412
Lymphocytic Choriomeningitis . . . . .	413
Zika Virus . . . . .	413
Malignant Disease . . . . .	413
Leukemia . . . . .	413
Neuroblastoma . . . . .	414

Basic Texts. . . . .	417
Related Academy Materials . . . . .	419
Requesting Continuing Medical Education Credit. . . . .	421
Study Questions . . . . .	423
Answer Sheet for Section 6 Study Questions . . . . .	431
Answers . . . . .	433
Index . . . . .	439

# General Introduction

The Basic and Clinical Science Course (BCSC) is designed to meet the needs of residents and practitioners for a comprehensive yet concise curriculum of the field of ophthalmology. The BCSC has developed from its original brief outline format, which relied heavily on outside readings, to a more convenient and educationally useful self-contained text. The Academy updates and revises the course annually, with the goals of integrating the basic science and clinical practice of ophthalmology and of keeping ophthalmologists current with new developments in the various subspecialties.

The BCSC incorporates the effort and expertise of more than 90 ophthalmologists, organized into 13 Section faculties, working with Academy editorial staff. In addition, the course continues to benefit from many lasting contributions made by the faculties of previous editions. Members of the Academy Practicing Ophthalmologists Advisory Committee for Education, Committee on Aging, and Vision Rehabilitation Committee review every volume before major revisions. Members of the European Board of Ophthalmology, organized into Section faculties, also review each volume before major revisions, focusing primarily on differences between American and European ophthalmology practice.

## Organization of the Course

The Basic and Clinical Science Course comprises 13 volumes, incorporating fundamental ophthalmic knowledge, subspecialty areas, and special topics:

- 1 Update on General Medicine
- 2 Fundamentals and Principles of Ophthalmology
- 3 Clinical Optics
- 4 Ophthalmic Pathology and Intraocular Tumors
- 5 Neuro-Ophthalmology
- 6 Pediatric Ophthalmology and Strabismus
- 7 Oculofacial Plastic and Orbital Surgery
- 8 External Disease and Cornea
- 9 Uveitis and Ocular Inflammation
- 10 Glaucoma
- 11 Lens and Cataract
- 12 Retina and Vitreous
- 13 Refractive Surgery

In addition, a comprehensive Master Index allows the reader to easily locate subjects throughout the entire series.

## References

Readers who wish to explore specific topics in greater detail may consult the references cited within each chapter and listed in the Basic Texts section at the back of the book.

These references are intended to be selective rather than exhaustive, chosen by the BCSC faculty as being important, current, and readily available to residents and practitioners.

### Multimedia

This edition of Section 6, *Pediatric Ophthalmology and Strabismus*, includes videos related to topics covered in the book. The videos were selected by members of the BCSC faculty to present important topics that are best delivered visually. This edition also includes an interactive feature, or “activity,” developed by members of the BCSC faculty. Both the videos and the activity are available to readers of the print and electronic versions of Section 6 ([www.aa.org/bcscvideo\\_section06](http://www.aa.org/bcscvideo_section06) and [www.aa.org/bcscactivity\\_section06](http://www.aa.org/bcscactivity_section06)). Mobile-device users can scan the QR codes below (a QR-code reader must already be installed on the device) to access the videos and activity.



Videos



Activity

### Self-Assessment and CME Credit

Each volume of the BCSC is designed as an independent study activity for ophthalmology residents and practitioners. The learning objectives for this volume are given on page 1. The text, illustrations, and references provide the information necessary to achieve the objectives; the study questions allow readers to test their understanding of the material and their mastery of the objectives. Physicians who wish to claim CME credit for this educational activity may do so by following the instructions given at the end of the book.

This Section of the BCSC has been approved by the American Board of Ophthalmology as a Maintenance of Certification (MOC) Part II self-assessment CME activity.

### Conclusion

The Basic and Clinical Science Course has expanded greatly over the years, with the addition of much new text, numerous illustrations, and video content. Recent editions have sought to place greater emphasis on clinical applicability while maintaining a solid foundation in basic science. As with any educational program, it reflects the experience of its authors. As its faculties change and medicine progresses, new viewpoints emerge on controversial subjects and techniques. Not all alternate approaches can be included in this series; as with any educational endeavor, the learner should seek additional sources, including Academy Preferred Practice Pattern Guidelines.

The BCSC faculty and staff continually strive to improve the educational usefulness of the course; you, the reader, can contribute to this ongoing process. If you have any suggestions or questions about the series, please do not hesitate to contact the faculty or the editors.

The authors, editors, and reviewers hope that your study of the BCSC will be of lasting value and that each Section will serve as a practical resource for quality patient care.

# Objectives

---

Upon completion of BCSC Section 6, *Pediatric Ophthalmology and Strabismus*, the reader should be able to

- describe techniques for evaluating young children that provide the maximum information gain with the least trauma and frustration
- describe the anatomy and physiology of the extraocular muscles
- explain the classification and diagnosis of amblyopia
- describe the treatment options for amblyopia
- describe the commonly used tests for the diagnosis and measurement of strabismus
- classify the various esodeviations and exodeviations
- describe the management of each type of esodeviation and exodeviation
- identify pattern and vertical strabismus, as well as special forms of strabismus, and describe a treatment plan for each type
- describe the features of the various forms of nystagmus seen in children, and explain their significance
- state the possible complications of strabismus surgery, and describe guidelines to minimize them
- describe an approach to the diagnosis of decreased vision in children
- list various causes of congenital and acquired ocular infections in children, and describe a logical plan for the diagnosis and management of each type
- list the most common lacrimal drainage system abnormalities found in children
- describe a management plan for the most common lacrimal drainage system abnormalities occurring in children

- list the most common diseases and malformations of the anterior segment occurring in children
  - describe the diagnostic findings and treatment options for childhood glaucoma
  - identify common types of childhood cataract and other lens disorders
  - describe a diagnostic and management plan for childhood cataracts
  - identify appropriate diagnostic tests for pediatric uveitis
  - identify various vitreoretinal, optic disc, and metabolic diseases and disorders that occur in children
  - describe the characteristic findings of accidental and nonaccidental ocular trauma in childhood
  - list the characteristics of ocular tumors and phakomatoses occurring in children
-

## The Pediatric Eye Examination



*This chapter includes a related video, which can be accessed by scanning the QR code provided in the text or going to [www.aaopt.org/bcscvideo\\_section06](http://www.aaopt.org/bcscvideo_section06).*

Children and their ophthalmic problems differ greatly from the patients and ocular conditions encountered in adult ophthalmology. Each developmental level in children requires a different approach for the examination, but with proper preparation and a positive attitude, the ophthalmologist can find the examination of pediatric patients to be both enjoyable and rewarding.

### Examination of Children in the Outpatient Setting

---

An unworried child will allow a more pleasant and valuable examination. The atmosphere in the ophthalmology office or clinic, therefore, should be welcoming and positive. Preferably, a small room or section of the waiting area should be designated and designed for children. Parents and caregivers, as well as any adult patients, will be grateful for this separation. Also, because some children fear the white coat, many pediatric practitioners choose not to wear one.

A dedicated long pediatric examination lane with different types of distance fixation targets (including remotely activated videos and mechanical animals 6 meters from the examination chair) is optimal. Having several small toys readily available for near fixation is useful for the *1 toy, 1 look* rule (Fig 1-1). Translucent, plastic finger puppets become silent accommodative near targets that can also provide a corneal light reflex if placed over a muscle light or penlight.

### History and Examination: General Considerations and Strategies

---

For the pediatric history, it is important to obtain information about the pregnancy and neonatal period, with attention to maternal health and the patient's weight and gestational age at birth. The practitioner should ask whether the child has reached applicable developmental milestones, whether there are any neurologic problems, and whether there is a family history of strabismus or other childhood eye disorders.

The examination begins as the practitioner enters the room. An experienced practitioner may gather important information before formal examination begins. Visual behavior, abnormal head position, dysmorphic features, ability to ambulate, familial disorders





**Figure 1-1** Small toys, pictures, and eye charts are used as accommodative near fixation targets. (Courtesy of Robert W. Hered, MD.)

(note parents and siblings), and family social dynamics can be effectively observed. A parent’s smartphone may contain photos and videos that prove useful in establishing a diagnosis and a condition’s progression over time.

The practitioner should sit at the child’s eye level; note that some children are more contented sitting in a parent’s lap. Introducing oneself to the child and family and establishing and maintaining eye contact with the child are important. Being relaxed, open, and playful during the examination helps create a “safe” environment. Gaining the child’s confidence can lead to a faster and better examination, easier follow-up visits, and greater parental support.

It is helpful to first address a young child with easy questions. For example, children enjoy being regarded as “big” and correcting adults when they are wrong. The practitioner can tell a child, “You look so grown up,” before grossly overestimating the patient’s age or grade level and asking, “Is that right?” A simple joke can relax both child and parent.

Because cooperation may be fleeting, the examination elements that are most critical for diagnosis and management should be addressed early. If binocular fusion is in doubt, it should be checked first, before being disrupted by other tests, including those for visual acuity. When possible, the most threatening parts of the examination should be performed last.

A different vocabulary should be developed for working with children, such as “I want to show you something special” instead of “I need to examine you.” Use “magic sunglasses” for the stereo glasses, “special flashlight” for the retinoscope, “funny hat” for the indirect ophthalmoscope, and “magnifying glass” for the indirect lens.

While checking vision, the practitioner can make the child feel successful by initially presenting objects that can be readily discerned and then saying, “That’s too easy—let’s try this one.” Confrontation visual field testing can be performed as a counting-fingers game. Children might be coaxed into a slit-lamp examination if told they can “drive the motorcycle” by grabbing the handles of the slit lamp. Pushing the “magic button” on the child’s

nose while a distance fixation target is surreptitiously activated distracts and disarms the patient and allows for a more deliberate examination.

For examination of a difficult child, some combination of rest periods, persuasion, persistence, and rewards is usually successful. If a child is having a bad day, however, it is sometimes best to stop the examination and schedule another appointment. For the follow-up examination of an infant who was fussy during the first visit, ask the parent or other caregiver to bring the infant in hungry and then feed him or her during the examination. In infants and younger children, brief restraint may prevail. However, the practitioner must consider the physical and emotional consequences of restraining a child. Depending on the nature of the ocular problem, a sedated examination or an examination under anesthesia may be a better solution.

## Examination: Specific Elements

---

The elements that constitute a complete pediatric ophthalmology examination parallel those that make up an adult examination but often require different techniques and devices. The following sections focus on these differences.

### Visual Acuity Assessment

Visual acuity assessment requires different approaches depending on the age, developmental level, and cooperativeness of the child. In children, detection of amblyopia is of particular concern (see Chapter 6). Amblyopia is a developmental disorder of the central nervous system due to the abnormal processing of visual images, which leads to reduced visual acuity. Amblyopia is responsible for more cases of childhood-onset unilateral decreased vision than all other causes combined but is preventable or reversible with timely detection and intervention. Early detection of reduced vision from amblyopia is possible with the techniques described herein.

Ideally, accurate measurement of monocular distance visual acuity using a linear display of Sloan letters would be possible in all pediatric patients. Commonly, however, the child is preverbal, preliterate, or not fully cooperative. In these cases, clinical options include assessment of fixation behavior or testing with alternative eye charts designed for preliterate children.

In infants and toddlers, fixation behavior is observed to qualitatively assess visual acuity. Preferential looking and visual evoked potential testing may allow quantitative assessment of visual acuity in this young population (see the section “Alternative methods of visual acuity assessment in preverbal children”). *Fixation and following (tracking)* behavior is observed as the child’s attention is directed to the examiner’s face or to a small toy in the examiner’s hand. *Fixation preference* is determined by observing how the patient responds to having one eye covered compared with the other eye covered. Children typically resist occlusion of the eye with better vision. Determining whether each eye can maintain fixation through smooth pursuit or a blink provides additional information; strong fixation preference for one eye indicates decreased vision in the nonpreferred eye.

Fixation behavior may be characterized by the CSM (Central, Steady, and Maintained) method. *Central* refers to foveal fixation, tested monocularly. If the fixation target is viewed eccentrically, fixation is termed *uncentral* (UC). *Steady* refers to the absence of nystagmus and other motor disruptions of fixation (see Chapter 13). The *S* assessment is also performed monocularly. *Maintained* refers to fixation that is held after the opposite eye is uncovered. An eye that does not maintain fixation may be presumed to have lower visual acuity than the opposite eye. Maintained fixation is easier to identify in a patient with strabismus than in one without this defect. For children without strabismus or with a small angle of strabismic deviation, the *induced tropia test* may be useful (see Chapter 2 for strabismus terminology). First, the examiner directs the child's attention to a target. Then a 10–20 prism diopter base-down prism is placed in front of 1 eye, and the eyes are observed. The prism is then placed in front of the opposite eye. If the eyes move up, the child is fixating with the eye under the prism. If the child alternates fixation during the test, a strong preference is not present. If the child consistently fixates with the same eye, the opposite eye likely has decreased vision. The visual acuity of an eye that has eccentric fixation and nystagmoid movements when attempting fixation would be designated *uncentral*, *unsteady*, and *unmaintained* (UC, US, UM).

Monocular recognition testing—which involves identifying letters, numbers, or symbols (all termed *optotypes*) with each eye separately—is the preferred method of assessing visual acuity. Optotypes may be presented on a wall chart, computer monitor, or handheld card. The acuity test should be calibrated for the test distance used. Because of the potential for variable or inaccurate viewing distances when near vision is tested, measurement at distance is preferred.

In eye charts used for testing preliterate children, the optotypes may be symbols or letters for matching. Table 1-1 lists the expected recognition visual acuity, as measured by an ophthalmologist, for children at different ages; these visual acuity levels may differ from those used in primary care vision screening criteria. Copies of appropriate optotypes may be given to the parent before the test for at-home rehearsal to improve testability, as well as the speed and reliability of responses.


Various optotypes are available for recognition visual acuity testing in preliterate children. LEA symbols (Fig 1-2) and the HOTV test (Fig 1-3) are reliably calibrated and

**Table 1-1 Monocular HOTV Visual Acuity Test Results in Preschool Children**

Age, y	Mean Visual Acuity	Threshold Visual Acuity <sup>a</sup>
2½	20/30	20/63
3	20/30	20/50
4	20/25	20/40
5	20/20	20/32

<sup>a</sup> Over 95% of children with normal vision are expected to achieve this level of visual acuity.

Information from Pan Y, Tarczy-Hornoch K, Cotter SA, et al; Multi-ethnic Pediatric Eye Disease Study Group. Visual acuity norms in preschool children: The Multi-ethnic Pediatric Eye Disease Study. *Optom Vis Sci*. 2009;86(6):607–612.



**Figure 1-2** LogMAR (logarithm of the minimum angle of resolution) visual acuity chart with LEA symbols. (Courtesy of the Good-Lite Company and Robert W. Hered, MD.)



**Figure 1-3** Crowded HOTV optotypes. (Courtesy of the Good-Lite Company and Robert W. Hered, MD.)

have high testability rates for preschool-aged children. For a shy child, testability may be improved by having the child point to match optotypes on a chart with those on a hand-held card rather than verbally identify them. Several symbol charts, such as Allen figures and the Lighthouse chart, are not recommended by the World Health Organization and the National Academy of Sciences because the optotypes are considered confusing, culturally biased, or nonstandardized. The Tumbling E chart is conceptually difficult for many preschool-aged children.

Because visual acuity may be overestimated when measured with isolated optotypes, particularly in amblyopia (see Chapter 6), a line of optotypes (linear acuity) or single

optotypes surrounded by *contour interaction bars* (“crowding bars”; see Fig 1-3) should be used whenever possible. The optotypes should be spaced such that the distance between each optotype is no greater than the width of the optotypes on any given line. The design of the Bailey-Lovie and ETDRS (Early Treatment of Diabetic Retinopathy Study) charts incorporates appropriate linear-optotype spacing, a consistent number of optotypes on each line, and a logarithmic (logMAR) change in letter size from one line to the next (see Fig 1-2). See also BCSC Section 3, *Clinical Optics*, for further discussion of visual acuity charts.

By convention, visual acuity is determined first for the right eye and then for the left. A patch or other occluder is used in front of the left eye as the acuity of the right eye is checked and vice versa. An adhesive patch is the most reliable occluder because it reduces the possibility that the child will “peek” around the occluder. Computerized visual acuity test systems allow for randomization of optotype presentation, preventing patients from memorizing optotypes and thus increasing test accuracy. Patients with nystagmus may show better binocular than monocular visual acuity. To assess monocular distance visual acuity in this situation, the fellow eye, rather than being occluded, should be fogged by using a translucent occluder or a lens +5.00 diopters (D) greater than the refractive error in that eye. Patients with poor vision may need to move closer to the chart until they can see the 20/400 line. In such cases, visual acuity is recorded as the distance in feet (numerator) over the size of the letter (denominator); for example, if the patient is able to read 20/400 optotypes at 5 ft, the acuity is recorded as 5/400. See the visual acuity conversion chart on the inside front cover of this book, which provides conversions of visual acuity measurements for the various methods in use.

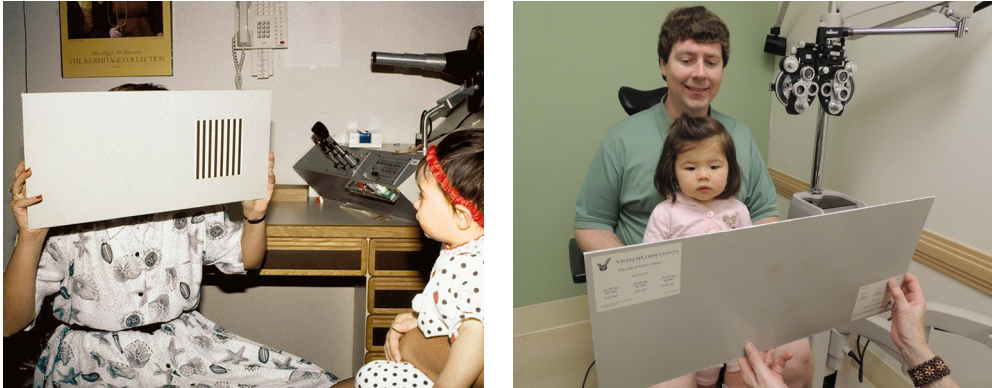The line with the smallest optotypes in which most of the optotypes are identified by the patient is recorded; if the patient misses a few optotypes on a line, a notation is made. For adults and children, visual acuity test results may vary depending on the chart used. The clinician should document the type of test performed, specifying the optotype and whether crowding was used, to facilitate comparison of measurements obtained at different times.

Age-appropriate optotypes are also used to determine uncorrected and corrected near visual acuity. Measuring near visual acuity in children with reduced vision is helpful for determining how they may function at school.

### ***Alternative methods of visual acuity assessment in preverbal children***

Two major methods are used to quantitate visual acuity in preverbal infants and toddlers: *preferential looking (PL)* and *visual evoked potential (VEP)*.

**Preferential looking tests** In these tests, the child’s response to a visual stimulus is observed to assess visual acuity. Teller Acuity Cards II (Stereo Optical, Inc, Chicago, IL), the LEA Grating Acuity Test (Good-Lite Company, Elgin, IL), and Patti Stripes Square Wave Grating Paddles (Precision Vision, Woodstock, IL) measure grating acuity, a form of resolution acuity, demonstrated by the subject’s ability to detect patterns composed of uniformly spaced black and white stripes on a gray background. Grating acuity can be measured as early as infancy. Movement of the eyes toward the stripes indicates that the



**Figure 1-4** Teller Acuity Cards can be used to measure visual acuity in a preverbal child. If the pattern is visible to the child, the eyes gaze toward the grating; otherwise, the stripes blend into the gray background. (Left image courtesy of John W. Simon, MD; right image courtesy of Lee R. Hunter, MD.)

child can see them. Seeing narrower stripes denotes better vision (Fig 1-4, Video 1-1). The Cardiff Acuity Test, popular in Europe, uses vanishing optotypes for preferential looking.



**VIDEO 1-1** Teller Acuity Card.

Courtesy of Lee R. Hunter, MD.



Access all Section 6 videos at [www.aao.org/bcscvideo\\_section06](http://www.aao.org/bcscvideo_section06).

**Visual evoked potential** Sweep visual evoked potential (VEP) can also be used to quantitatively assess visual acuity in preverbal patients. In this test, electrodes are placed over the occipital lobe to measure electrical signals produced in response to a visual stimulus. The child views a series of bar or grid patterns. If the stimulus is large enough for the child to discriminate, a visual impulse is recorded. Visual acuity is estimated based on the smallest stimulus width that produces a response.

### Red Reflex Examination and the Brückner Test

The Brückner test is performed in a semidark room using a direct ophthalmoscope to assess the red reflex from both eyes simultaneously at a distance of approximately 1 m. The clinician can quickly determine the clarity and symmetry of the 2 red reflexes and identify potentially amblyogenic conditions such as anisometropia, isoametropia, and ocular misalignment. A strabismic eye tends to give a brighter red reflex than does the fixating eye.

### Dynamic Retinoscopy

Dynamic retinoscopy is a technique for measuring accommodation. For the test, the child is presented a distance fixation target, quickly followed by a near fixation target, while the retinoscopic reflex is observed. In a child with normal accommodation, the reflex will be neutralized at near focus. A poor accommodative response indicates a possible need for bifocal or reading glasses. Hypoaccommodation occurs much more frequently in children with Down syndrome or cerebral palsy than in the general pediatric population.

### **Visual Field Testing**

Information about the visual fields can be obtained in very young patients, once visual fixation has developed (usually by 4 months of age). A peripheral target is presented while the child is fixating on an interesting central target. Movement of the eyes toward the peripheral target (an evoked saccade) confirms the field. Confrontation visual fields can be approximated in children old enough to identify fingers placed in each peripheral quadrant. School-aged children can often be evaluated with manual or automated perimetry.

### **Pupil Testing**

The pupillary light reflex is not reliably present until approximately 30 weeks' gestational age. Pupils are usually miotic in newborns and gradually increase in size until preadolescence. Accurate pupil testing in young children is complicated by the smaller pupil and difficulty controlling accommodation. Careful observation, remote or foot control of the room lights to allow continued observation during changes in room illumination, and use of appropriate distance fixation targets greatly facilitate pupil evaluation. Digital photography can also be useful for observing and documenting pupil size and symmetry.

### **Anterior Segment Examination**

A successful anterior segment examination is usually possible in children but may require persistence and varied techniques. Children old enough to sit by themselves can usually be enticed to hold the "motorcycle handles" of the slit lamp long enough for a brief examination. A younger child may be positioned at the slit lamp while in a parent's lap. Children unable or unwilling to cooperate for standard slit-lamp examination may be examined with a portable slit lamp, surgical loupes, or a 20 D or 28 D handheld lens used with an indirect ophthalmoscope.

### **Intraocular Pressure Measurement**

It is not always easy or possible to perform formal tonometry in children. Tonometry requires a relaxed patient. With a nonthreatening approach and experience, the practitioner may find that accurate testing is possible in children by using handheld devices such as the Icare tonometer (Icare Finland Oy, Helsinki, Finland) or Tono-Pen (Reichert Technologies, Depew, NY). The Tono-Pen or the Perkins Tonometer (Haag-Streit USA, Mason, OH) may be used to test infants when they are sleeping or feeding in the supine position.

Digital palpation, though not quantitative, can provide a gross assessment of intraocular pressure. Interpretation of the findings requires practice and involves correlation with formal tonometry results obtained in the same patient.

### **Cycloplegic Refraction**

Because of the relationship between accommodation and ocular convergence, refraction with cycloplegic agents is a particularly important test in the evaluation of any patient who has issues relating to binocular vision and ocular motility.

### **Refraction technique**

Refraction is generally performed after cycloplegia. The ophthalmologist's working distance and the child's visual axis are important considerations. To be accurate, retinoscopy must be performed on axis. The 2 main methods for refraction are loose lenses for infants and younger children and the phoropter for those old enough to sit in an examination chair.

### **Cycloplegic agents**

*Cyclopentolate hydrochloride* (1%) is the preferred cycloplegic drug for routine use in children. Use of a weaker concentration of cyclopentolate (0.2% to 0.5%) is suggested in infants. *Tropicamide* (0.5% or 1%) is usually not potent enough for effective cycloplegia in children. Many ophthalmologists use a combination of cyclopentolate, tropicamide, and/or phenylephrine to achieve maximum pupil dilatation. *Atropine* (1%) drops or ointment is used by some ophthalmologists, particularly in young children with esotropia or dark irides, but this drug causes prolonged blurring and is more often associated with adverse effects (see the section "Adverse effects of cycloplegic agents"). Some ophthalmologists choose atropine to ensure complete cycloplegia in select cases of accommodative esotropia.

Table 1-2 gives the administration schedule and onset of action for commonly used cycloplegics. The duration of action varies greatly, and the pupillary effect occurs earlier and lasts longer than the cycloplegic effect; thus, a dilated pupil does not necessarily indicate complete cycloplegia. For patients with accommodative esodeviations, repeated cycloplegic examinations are essential when control of strabismus is precarious.

### **Eyedrops in children**

Most young children are apprehensive about eyedrops. Fortunately, there are many approaches to administering eyedrops. If possible, to improve the child's cooperation for the remainder of the examination, someone other than the physician should instill the drops, which can be described to the child as being "like a splash of swimming pool water" that will "feel funny." Some practitioners administer a topical anesthetic drop first, while others use the cycloplegic drops alone; some use a compounded cycloplegic spray from an atomizer.

### **Adverse effects of cycloplegic agents**

Adverse reactions to cycloplegic agents include allergic (or hypersensitivity) reaction with conjunctivitis, edematous eyelids, and dermatitis. These reactions are more common with atropine than with the other agents. Cycloplegic agents may also cause systemic

**Table 1-2 Administration of Commonly Used Cycloplegic Agents**

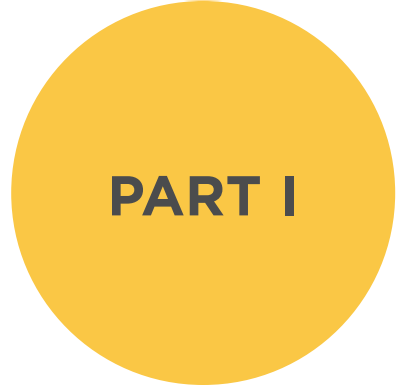<b>Medication</b>	<b>Administration Schedule</b>	<b>Onset of Action</b>
Tropicamide	1 drop every 5 min × 2; wait 30 min	20–40 min
Cyclopentolate hydrochloride	1 drop every 5 min × 2; wait 30 min	30–60 min
Atropine sulfate	1 drop, wait 90 min Alternatively, 1–3 drops per day × 1–4 days; then 1 drop morning of appointment	45–120 min



symptoms, including fever, dry mouth, flushing, tachycardia, constipation, urinary retention, nausea, dizziness, and delirium. Treatment is discontinuation of the drug, with supportive measures as necessary. If the reaction is severe, physostigmine may be given. One drop of atropine, 1%, contains 0.5 mg of atropine. See also BCSC Section 2, *Fundamentals and Principles of Ophthalmology*, Part V: Ocular Pharmacology.

### **Fundus Examination**

The fundus examination is typically the final component of a complete pediatric ophthalmology examination. Though often challenging to obtain in young children, an adequate view of the fundus is important for identifying pathology. After mydriasis is achieved, infants and small children can be examined with the indirect ophthalmoscope, often more easily by using decreased illumination. Examination may require restraint of some infants, particularly those being screened for retinopathy of prematurity (in these cases, a topical anesthetic, eyelid speculum, and scleral depression are necessary for a complete retinal evaluation). For many young children, the practitioner can obtain sufficient views by using diversionary targets such as illuminated toys and cartoons.



# Strabismus





# Strabismus Terminology

## Definitions

---

The term *strabismus* is derived from the Greek word *strabismos*—“to squint, to look obliquely or askance”—and means ocular misalignment. This misalignment may be caused by abnormalities in binocular vision or by anomalies of neuromuscular control of ocular motility. Many terms are used in discussions of strabismus. Familiarity with this terminology can aid the reader in understanding these disorders; misuse of these terms could cause confusion. Unfortunately, some terms still in use are not correct physiologically.

*Orthophoria* is the ideal condition of perfect ocular alignment. In practice, orthophoria is seldom encountered, as a small heterophoria can be found in most people. Some ophthalmologists therefore prefer *orthotropia* to mean correct direction or position of the eyes under binocular conditions. Both terms are commonly used to describe eyes without manifest strabismus. *Heterophoria* is an ocular deviation kept latent by the fusional mechanism (latent strabismus). *Heterotropia* is a deviation that is present when both eyes are open and used for viewing (manifest strabismus). It is sometimes helpful to identify the deviating eye, particularly when vertical deviations or restrictive or paretic strabismus is being measured, or when amblyopia is present in a preverbal child.

## Prefixes and Suffixes

A detailed nomenclature has evolved to describe the various types of ocular deviations. In this vocabulary, the prefix used indicates the relative position of the visual axes of the 2 eyes, or the direction of deviation.

### Prefixes

**Eso-** The eye is rotated so that it is deviated nasally. Because the visual axes align at a point closer than the fixation target, this state is also known as *convergent strabismus*, one type of horizontal strabismus.

**Exo-** The eye is rotated so that it is deviated temporally. Because the visual axes are diverging from the fixation target, this state is also known as *divergent strabismus*, another form of horizontal strabismus.

**Hyper-** The eye is rotated so that it is deviated superiorly. This describes one type of *vertical strabismus*.

**Hypo-** The eye is rotated so that it is deviated inferiorly. This describes another type of *vertical strabismus*.

**Incyclo-** The eye is rotated so that the superior pole of the vertical meridian is rotated nasally. This state is known as *intorsion*.

**Excyclo-** The eye is rotated so that the superior pole of the vertical meridian is rotated temporally. This state is known as *extorsion*.

### **Suffixes**

**-phoria** A latent deviation (eg, esophoria, exophoria, right hyperphoria); the deviation is controlled by the fusional mechanism so that the eyes remain aligned under binocular conditions.

**-tropia** A manifest deviation (eg, esotropia, exotropia, right hypertropia); the deviation exceeds the control of the fusional mechanism so that the eyes are misaligned under binocular conditions. Heterotropias can be constant or intermittent.

### **Strabismus Classification Terms**

Several methods of classifying ocular alignment and motility disorders are used, as no classification is perfect or all-inclusive. Terms used in these classifications are presented herein.

#### **Age at onset**

**Infantile** A deviation documented at or before age 6 months, presumably related to a defect present at birth. The term *congenital* is sometimes used, although it may be less accurate because the deviation is usually not present at birth.

**Acquired** A deviation with onset after 6 months of age, following a period of presumably normal ocular alignment.

#### **Fixation**

**Alternating** Spontaneous alternation of fixation from one eye to the other.

**Monocular** Fixation with one eye only.

#### **Variation of the deviation size with gaze position or fixating eye**

**Comitant (concomitant)** The size of the deviation does not vary by more than a few prism diopters in different positions of gaze or with either eye used for fixation.

**Incomitant (noncomitant)** The deviation varies in size in different positions of gaze or with the eye used for fixation.

#### **Miscellaneous terms**

**Consecutive** A strabismus that is in the direction opposite that of a previous strabismus. For example, consecutive exotropia is an exotropia that follows an esotropia.

**Dissociated strabismus complex** Consists of dissociated vertical deviation, dissociated horizontal deviation, and dissociated torsional deviation. The number of components varies, with some patients having all 3 and others having only 1. Dissociated vertical deviation is the most prevalent of the 3 components. The complex can be bilateral or unilateral; if it is bilateral, the degree of control of the deviation can vary between the eyes.

**Overelevation in adduction and overdepression in adduction** These motility anomalies—frequently also called *inferior oblique overaction* and *superior oblique overaction*, respectively—can be caused by overaction of the oblique muscles, as well as by other mechanisms (see Chapter 11).

**Underelevation in adduction and underdepression in adduction** These motility anomalies—frequently also called *inferior oblique underaction* and *superior oblique underaction*, respectively—can be caused by underaction of the oblique muscles, as well as by other mechanisms (see Chapter 11).

## Abbreviations for Types of Strabismus

---

Addition of the prime symbol (') to any of the following indicates that measurement of ocular alignment is made at near fixation (eg, E' indicates esophoria at near).

**O = O** Orthophoria (orthotropia).

**E, X, RH, LH** Esophoria, exophoria, right hyperphoria, left hyperphoria at distance fixation, respectively.

**ET, XT, RHT, LHT** Constant esotropia, exotropia, right hypertropia, left hypertropia at distance fixation, respectively.

**E(T), X(T), RH(T), LH(T)** Intermittent esotropia, exotropia, right hypertropia, left hypertropia at distance fixation, respectively. The addition of parentheses around the *T* indicates an intermittent tropia.

**RHoT, LHoT** Right hypotropia, left hypotropia at distance fixation, respectively.

**OEAd or IOOA** Overelevation in adduction or inferior oblique overaction, respectively.

**ODAd or SOOA** Overdepression in adduction or superior oblique overaction, respectively.

**UDAd or SOUA** Underdepression in adduction or superior oblique underaction, respectively.

**UEAd or IOUA** Underelevation in adduction or inferior oblique underaction, respectively.


**DSC** Dissociated strabismus complex.

**DHD, DTD, DVD** Dissociated horizontal deviation, dissociated torsional deviation, dissociated vertical deviation, respectively.



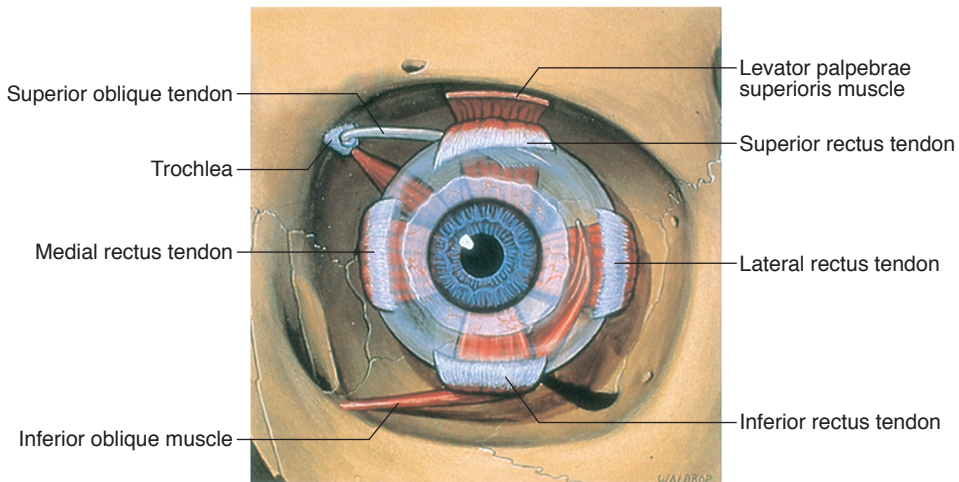
## CHAPTER 3

# Anatomy of the Extraocular Muscles

 This chapter includes a related activity, which can be accessed by scanning the QR code provided in the text or going to [www.aao.org/bcscactivity\\_section06](http://www.aao.org/bcscactivity_section06).

### Origin, Course, Insertion, and Innervation of the Extraocular Muscles

There are 7 extraocular muscles (EOMs) in the human eye: the 4 rectus muscles (lateral, medial, superior, and inferior), the 2 oblique muscles, and the levator palpebrae superioris muscle. Figure 3-1 shows an anterior view of the EOMs and their relationships to one another. Cranial nerve (CN) VI (abducens) innervates the lateral rectus muscle; CN IV (trochlear), the superior oblique muscle; and CN III (oculomotor), the levator palpebrae, superior rectus, medial rectus, inferior rectus, and inferior oblique muscles. Cranial nerve III has an upper and a lower division: the upper division supplies the levator palpebrae and superior rectus muscles, and the lower division supplies the medial rectus, inferior rectus, and



**Figure 3-1** Extraocular muscles, frontal composite view, left eye. (Reproduced with permission from Dutton JJ. *Atlas of Clinical and Surgical Orbital Anatomy*. Philadelphia: Saunders; 1994:23.)



inferior oblique muscles. The parasympathetic innervation of the sphincter pupillae and ciliary muscle travels with the branch of the lower division of CN III that supplies the inferior oblique muscle. BCSC Section 5, *Neuro-Ophthalmology*, discusses the ocular motor nerves in more detail, and Section 2, *Fundamentals and Principles of Ophthalmology*, extensively illustrates the anatomical structures mentioned in this chapter.

Table 3-1 summarizes the characteristics of the EOMs. The EOMs and their relationships to one another can be explored in Activity 3-1.



### ACTIVITY 3-1 Extraocular muscles.

Activity developed by Mary A. O'Hara, MD.

Access the activity at [www.aao.org/bcscactivity\\_section06](http://www.aao.org/bcscactivity_section06).



## Horizontal Rectus Muscles

The horizontal rectus muscles are the medial and lateral rectus muscles. Both arise from the annulus of Zinn. The *medial rectus muscle* courses along the medial orbital wall. The *lateral rectus muscle* courses along the lateral orbital wall.

## Vertical Rectus Muscles

The vertical rectus muscles are the superior and inferior rectus muscles. The *superior rectus muscle* originates from the annulus of Zinn and courses anteriorly, upward over the eyeball, and laterally, forming an angle of 23° with the visual axis or the midplane of the eye in primary position (Fig 3-2; see also Chapter 4, Fig 4-3). The *inferior rectus muscle* also arises from the annulus of Zinn, and it then courses anteriorly, downward, and laterally along the floor of the orbit, forming an angle of 23° with the visual axis or midplane of the eye in primary position (see Chapter 4, Fig 4-4).

## Oblique Muscles

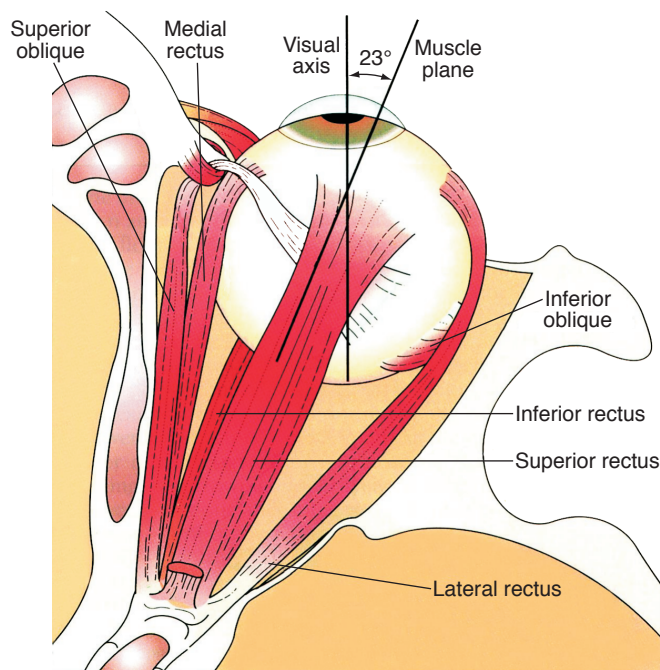
The *superior oblique muscle* originates from the orbital apex, above the annulus of Zinn, and passes anteriorly and upward along the superomedial wall of the orbit. The muscle becomes tendinous before passing through the trochlea, a cartilaginous saddle attached to the frontal bone in the superior nasal orbit. The combination of the trochlea and the superior oblique tendon is known as the *tendon-trochlea complex*. The function of the trochlea is to redirect the tendon inferiorly, posteriorly, and laterally, with the tendon forming an angle of 51° with the visual axis or midplane of the eye in primary position (see Chapter 4, Fig 4-5). The tendon penetrates the Tenon capsule 2 mm nasally and 5 mm posteriorly to the nasal insertion of the superior rectus muscle. Passing under the superior rectus muscle, the tendon inserts posterior to the equator in the superotemporal quadrant of the eyeball, almost or entirely laterally to the midvertical plane or center of rotation.

The *inferior oblique muscle* originates from the periosteum of the maxillary bone, just posterior to the orbital rim and lateral to the orifice of the lacrimal fossa. It courses laterally, superiorly, and posteriorly, going inferior to the inferior rectus muscle and inserting under the lateral rectus muscle in the posterolateral portion of the globe, in the area of the macula. The inferior oblique muscle forms an angle of 51° with the visual axis or midplane of the eye in primary position (see Chapter 4, Fig 4-6). A stiff neurofibrovascular

**Table 3-1 Extraocular Muscles**

Muscle	Approx. Length of Active Muscle, mm	Origin	Anatomical Insertion and Distance From Limbus, mm	Direction of Pull	Length of Tendon, mm	Arc of Contact, mm	Innervation
Medial rectus (MR)	40	Annulus of Zinn	Up to 5.5 mm from medial limbus	90°	4.5	7.0	Lower CN III
Lateral rectus (LR)	40	Annulus of Zinn	Up to 6.9 mm from lateral limbus	90°	7.0	12.0	CN VI
Superior rectus (SR)	40	Annulus of Zinn	Up to 7.7 mm from superior limbus	23°	6.0	6.5	Upper CN III
Inferior rectus (IR)	40	Annulus of Zinn	Up to 6.5 mm from inferior limbus	23°	7.0	6.5	Lower CN III
Superior oblique (SO)	32	Orbital apex, above annulus of Zinn (functional origin at the trochlea)	Posterior to equator in superotemporal quadrant	51°	26.0	7–8	CN IV
Inferior oblique (IO)	37	Behind inferior orbital rim, lateral to lacrimal fossa	Lateral to area of macula	51°	1.0	15.0	Lower CN III
Levator palpebrae superioris (LPS)	40	Orbital apex, above annulus of Zinn	Septa of pretarsal orbicularis and anterior surface of tarsus	—	14–20	—	Upper CN III

CN = cranial nerve.  
See also Figures 4-2 through 4-6 in Chapter 4.



**Figure 3-2** The extrinsic muscles of the right eyeball in primary position, seen from above. Note that only the origin and insertion of the inferior oblique muscle are visible in this view. (Modified with permission from Yanoff M, Duker J, eds. *Ophthalmology*. 2nd ed. London: Mosby; 2004:549.)

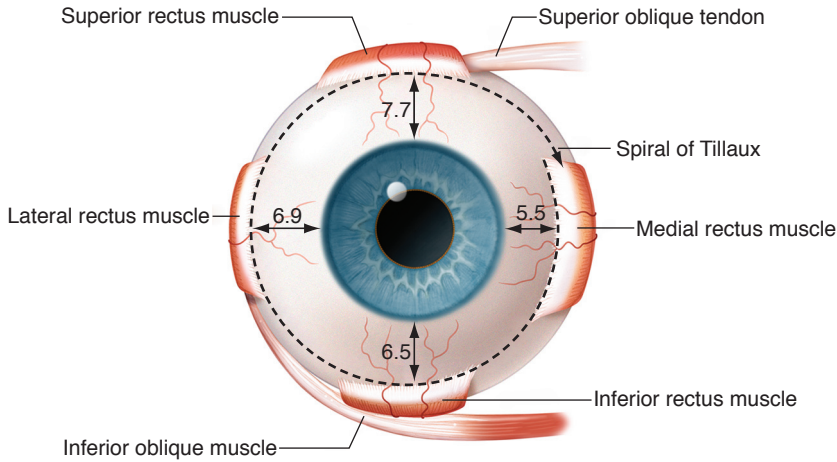
bundle containing the nerve to the inferior oblique runs anteriorly, along the lateral border of the inferior rectus muscle, to the myoneural junction. Most inferior oblique muscles have a single belly, but approximately 10% have 2 bellies; in rare cases, there are 3.

### Levator Palpebrae Superioris Muscle

The levator palpebrae superioris muscle arises at the orbital apex from the lesser wing of the sphenoid bone, just superior to the annulus of Zinn. At its origin, the muscle blends with the superior rectus muscle inferiorly and with the superior oblique muscle medially. The levator palpebrae superioris passes anteriorly, lying just above the superior rectus muscle; the fascial sheaths of these 2 muscles are connected. The levator palpebrae superioris muscle becomes an aponeurosis in the region of the superior fornix. This muscle has both a cutaneous and a tarsal insertion. BCSC Section 7, *Oculofacial Plastic and Orbital Surgery*, discusses this muscle in detail.

### Relationship of the Rectus Muscle Insertions

Starting at the medial rectus and proceeding to the inferior rectus, lateral rectus, and superior rectus muscles, the rectus muscle tendons insert progressively farther from the limbus. Drawing a continuous curve through these insertions yields a spiral, known as the *spiral of Tillaux* (Fig 3-3). The temporal side of each vertical rectus muscle insertion is farther from the limbus (ie, more posterior) than is the nasal side.



**Figure 3-3** Spiral of Tillaux, right eye. Note: The insertion distances, given in millimeters, are maximum values. Insertion distances vary among individuals. (Illustration by Christine Gralapp.)

## Blood Supply of the Extraocular Muscles

### Arterial System

The muscular branches of the ophthalmic artery provide the most important blood supply to the EOMs. The *lateral muscular branch* supplies the lateral rectus, superior rectus, superior oblique, and levator palpebrae superioris muscles; the *medial muscular branch*, the larger of the 2, supplies the inferior rectus, medial rectus, and inferior oblique muscles.

The lateral rectus muscle is partially supplied by the *lacrimal artery*; the *infraorbital artery* partially supplies the inferior oblique and inferior rectus muscles. The muscular branches give rise to the *anterior ciliary arteries* accompanying the rectus muscles; each rectus muscle has 1–4 anterior ciliary arteries. These pass to the episclera of the globe and then supply blood to the anterior segment. The commonly held notion that the lateral rectus has fewer ciliary vessels than the other rectus muscles has been challenged by anatomical work showing that the number of ciliary vessels is similar for the lateral rectus and the other rectus muscles and that these vessels may, in fact, contribute substantially to the blood supply of the anterior segment.

Johnson MS, Christiansen SP, Rath PP, et al. Anterior ciliary circulation from the horizontal rectus muscles. *Strabismus*. 2009;17(1):45–48.

### Venous System

The venous system parallels the arterial system, emptying into the *superior* and *inferior orbital veins*. Generally, 4 or more *vortex veins* are located posterior to the equator; these are often found near the nasal and temporal margins of the superior rectus and inferior rectus muscles. Although the number and position of the vortex veins vary, the location of 2 of them in the orbit is consistent: the inferotemporal quadrant, just posterior to the

inferior oblique muscle; and the superotemporal quadrant, just posterior to the superior oblique tendon.

## Structure of the Extraocular Muscles

---

The important functional characteristics of muscle fibers are contraction speed and fatigue resistance. The eye muscles participate in motor acts that are among the fastest (saccadic eye movements) in the human body and among the most sustained (gaze fixation and vergence movements). Like skeletal muscle, EOM is voluntary striated muscle. However, EOM differs from typical skeletal muscle developmentally, biochemically, structurally, and functionally. In the EOMs, the ratio of nerve fibers to muscle fibers is very high (1:3–1:5)—up to 10 times higher than the ratio of nerve axons to muscle fibers in skeletal muscle. This high ratio may enable accurate eye movements that are controlled by an array of systems ranging from the primitive vestibular-ocular reflex to highly evolved vergence movements.

The EOMs exhibit a distinct 2-layer organization: an outer *orbital layer*, which acts only on connective tissue pulleys (see the section The Pulley System, later in the chapter), and an inner *global layer*, whose tendon inserts on the sclera to move the globe (Fig 3-4). The muscle fibers of the orbital and global layers can be either singly or multiply innervated.

Singly innervated fibers are fast-twitch generating and resistant to fatigue. In the orbital layer, approximately 80% of the fibers are singly innervated. In the global layer, about 90% of the fibers are singly innervated. They can be subdivided into 3 groups (red, intermediate, and white), based on mitochondrial content. The red fibers are the most fatigue resistant; the white fibers, the least. The orbital singly innervated fibers are considered the major contributor to sustained EOM force in primary and deviated positions. Of all muscle fiber types, this type is the most affected by denervation from damage to the motor nerves or the end plates, as occurs after botulinum toxin injection.

The function of the multiply innervated fibers of the orbital and global layers is not clear. These fibers are not seen in the levator palpebrae superioris. They are thought to be involved in the finer control of fixation and in smooth and finely graded eye movements, particularly vergence control.

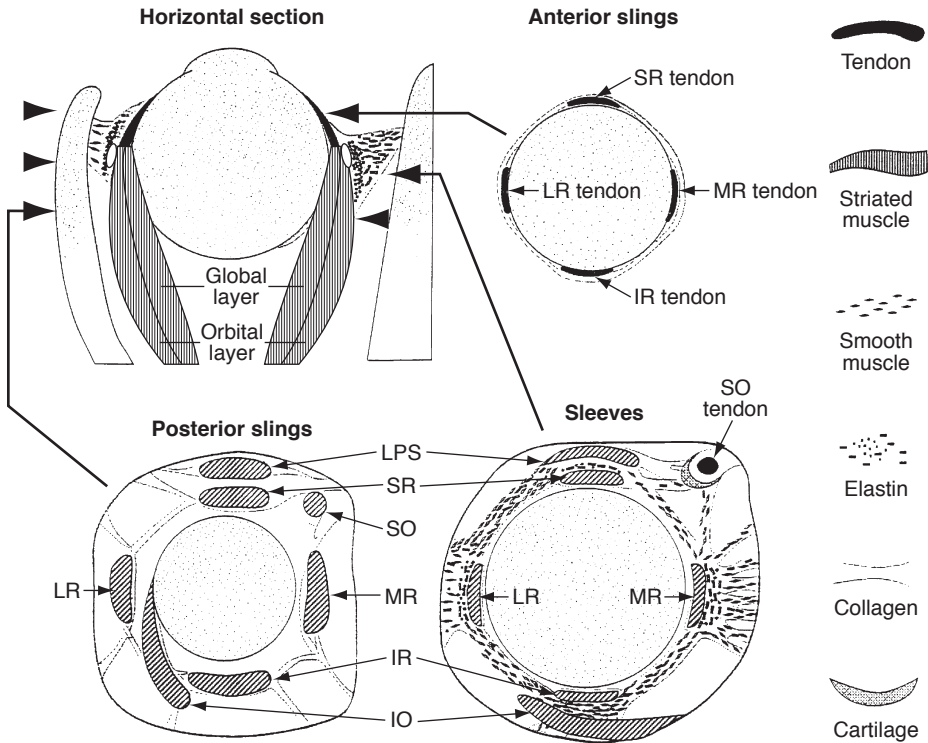
These novel properties of eye muscles lead to differential responses to local anesthetics and pharmaceuticals such as botulinum toxin and calcium channel blockers, as well as to disease processes such as myasthenia gravis and muscular dystrophy.

Finally, there is evidence for compartmentalization of rectus muscle innervation. For example, studies in primates and humans have shown distinct superior and inferior zones within the horizontal rectus muscles. The clinical significance of these observations is being investigated.

da Silva Costa RM, Kung J, Poukens V, Yoo L, Tychsen L, Demer JL. Intramuscular innervation of primate extraocular muscles: unique compartmentalization in horizontal recti.

*Inv Ophthalmol Vis Sci.* 2011;52(5):2830–2836.

Demer JL. Compartmentalization of extraocular muscle function. *Eye (Lond).* 2015;29(2):157–162.



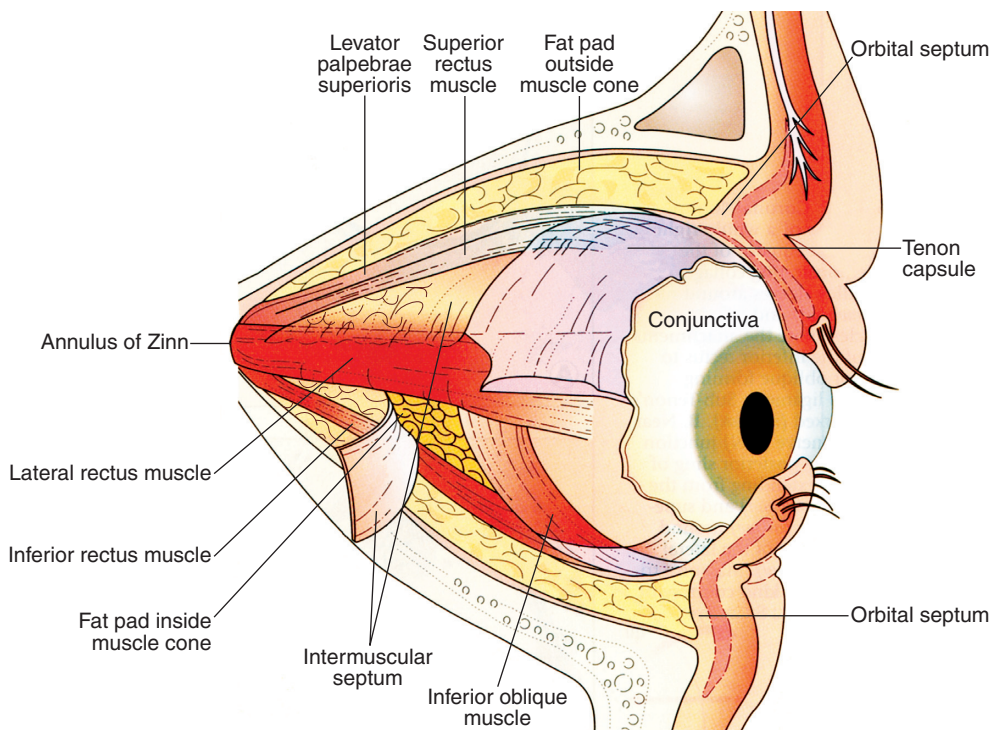
**Figure 3-4** Structure of orbital connective tissues. IO, inferior oblique; IR, inferior rectus; LPS, levator palpebrae superioris; LR, lateral rectus; MR, medial rectus; SO, superior oblique; SR, superior rectus. The 3 coronal views are represented at the levels indicated by arrows in horizontal section. (Modified with permission from Demer JL, Miller JM, Poukens V. Surgical implications of the rectus extraocular muscle pulleys. *J Pediatr Ophthalmol Strabismus*. 1996;33(4):208–218.)

## Orbital and Fascial Relationships

Within the orbit, a complex musculofibroelastic structure suspends the globe, supports the EOMs, and compartmentalizes the fat pads (Fig 3-5). In recent years, the interconnectedness of the orbital tissues, as well as the extent and complexity of these connections, has come to light. The intense fibrous connections existing throughout the orbit can be illustrated clinically by the consequences of tissue entrapment in blowout fractures and of fibrosis of delicate fibrous septa after retrobulbar hemorrhage. The nature of these relationships remains under investigation.

### Adipose Tissue

The eye is supported and cushioned within the orbit by a large amount of fatty tissue. External to the muscle cone, fatty tissue comes forward with the rectus muscles, stopping about 10 mm from the limbus. Fatty tissue is also present inside the muscle cone, kept away from the sclera by the Tenon capsule (see Fig 3-5).



**Figure 3-5** The muscle cone contains 1 fat pad and is surrounded by another; these 2 fat pads are separated by the rectus muscles and intermuscular septum. Note that the intermuscular septum does not extend all the way back to the apex of the orbit. (Modified with permission from Yanoff M, Duker J, eds. *Ophthalmology*. 2nd ed. London: Mosby; 2004:553.)

### Muscle Cone

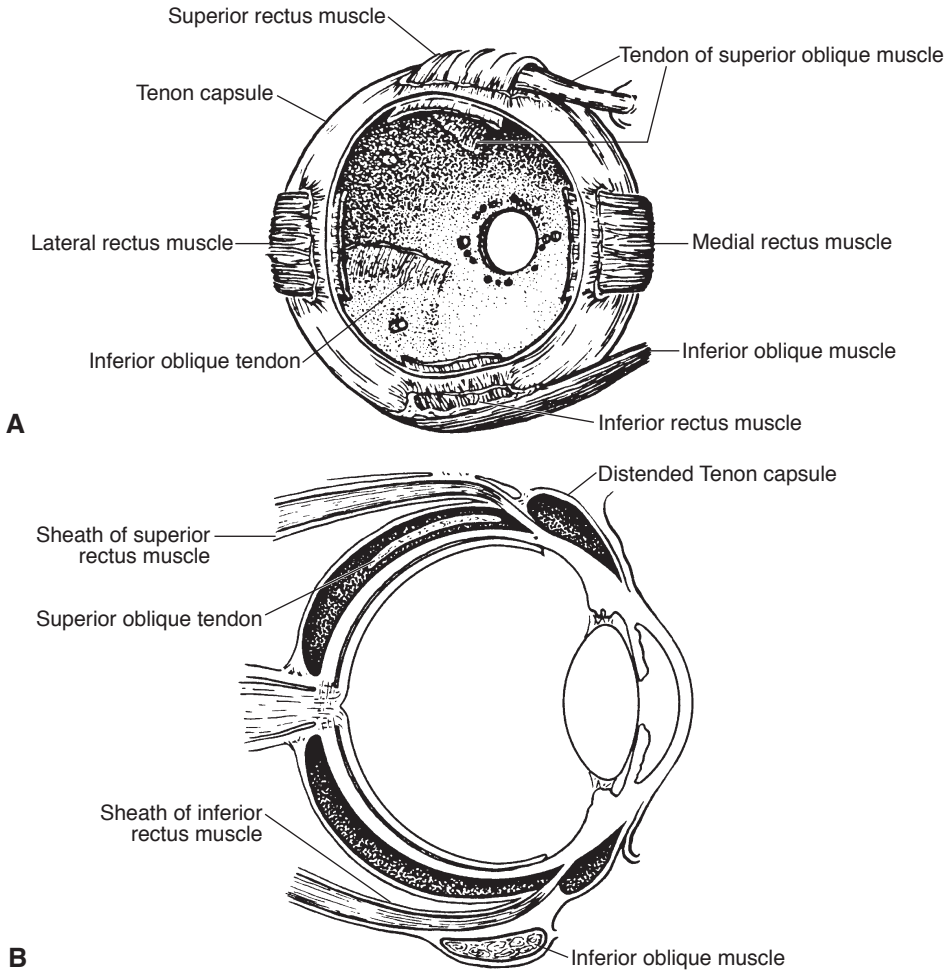
The muscle cone lies posterior to the equator. It consists of the EOMs, their sheaths, and the intermuscular septum (see Fig 3-5).

### Muscle Capsule

Each rectus muscle has a surrounding fascial capsule that extends with the muscle from its origin to its insertion. These capsules are thin posteriorly, but near the equator they thicken as they pass through the sleeve of the Tenon capsule, continuing anteriorly with the muscles to their insertions. Anterior to the equator, between the undersurface of the muscle and the sclera, there is almost no fascia, only connective tissue footplates that connect the muscle to the globe. The smooth, avascular surface of the muscle capsule allows the muscles to slide easily over the globe.

### The Tenon Capsule

The Tenon capsule (*fascia bulbi*) is the principal orbital fascia and forms the envelope within which the eyeball moves (Fig 3-6). The Tenon capsule fuses posteriorly with the



**Figure 3-6** **A**, Anterior and posterior orifices of the Tenon capsule shown after enucleation of the globe. **B**, The Tenon space shown by injection with India ink. (Modified with permission from von Noorden GK, Campos EC. *Binocular Vision and Ocular Motility: Theory and Management of Strabismus*. 6th ed. St Louis: Mosby; 2002:45.)

optic nerve sheath and anteriorly with the intermuscular septum at a position 3 mm from the limbus. The posterior portion of the Tenon capsule is thin and flexible, enabling free movement of the optic nerve, ciliary nerves, and ciliary vessels as the globe rotates, while separating the orbital fat inside the muscle cone from the sclera. At and just posterior to the equator, the Tenon capsule is thick and tough, suspending the globe like a trampoline by means of connections to the periorbital tissues. The global layer of the 4 rectus muscles penetrates this thick fibroelastic tissue approximately 10 mm posterior to their insertions. The oblique muscles penetrate the Tenon capsule anterior to the equator. The Tenon capsule continues forward over these 6 EOMs and separates them from the orbital fat and structures lying outside the muscle cone.



## The Pulley System

The 4 rectus muscles are surrounded by fibroelastic pulleys that maintain the position of the EOMs relative to the orbit. The pulleys consist of collagen, elastin, and smooth muscle, enabling them to contract and relax. Dynamic magnetic resonance imaging (MRI) studies show that, in some cases, the pulleys act mechanically as the rectus muscle origins. The pulleys may also serve to stabilize the muscle path, preventing sideslipping or movement perpendicular to the muscle axis (see Fig 3-4). Anteriorly, the pulleys merge with the *intermuscular septum*, which fuses with the conjunctiva 3 mm posterior to the limbus. The posterior section of the intermuscular septum separates the intraconal fat pads from the extraconal fat pads (see Fig 3-5). Numerous extensions from the EOM sheaths attach to the orbit and help support the globe.

The inferior oblique muscle originates inferonasally from the periosteum of the maxillary bone, near the orbital rim, adjacent to the anterior lacrimal crest, and it continues laterally, entering its connective tissue pulley inferior to the inferior rectus muscle, at the site where the inferior oblique muscle also penetrates the Tenon capsule. The inferior oblique pulley and inferior rectus pulley join to form the Lockwood ligament (see Fig 3-7). Attached to the conjoined inferior oblique and inferior rectus pulley complex is the dense neurofibrovascular bundle containing the inferior oblique motor nerve.

The *active pulley hypothesis* proposes that the pulley positions are shifted by the contraction of the orbital layer against the elasticity of the pulley suspension. This concept remains controversial: whether there is actual innervational control of the pulleys is still debated. However, high-resolution MRI scans have shown that the pulleys are located only a short distance from the globe center; therefore, small shifts in pulley position would confer large shifts in EOM pulling direction. Normal pulleys shift only slightly in the coronal plane, even during large eye movements. *Heterotopy (malpositioning)* of the rectus pulleys may cause some cases of incomitant strabismus and A or V patterns (see Chapter 10), and these anomalies can mimic oblique muscle dysfunction by misdirecting the forces of the rectus muscles. Bony abnormalities, such as those seen with craniosynostosis, can also alter the direction of pull of rectus muscles by causing malpositioning of the pulleys.

The pulley model and its implications have been challenged by other high-resolution MRI studies, which show that during eye movements into eccentric fields, the posterior portions of rectus muscles shift. These findings are consistent with the more traditional model of eye muscle function, which is the “restrained shortest-path model.”

Peragallo JH, Pineles SL, Demer JL. Recent advances clarifying the etiologies of strabismus. *J Neuroophthalmol.* 2015;35(2):185–193.

## Anatomical Considerations for Ophthalmic Procedures

The nerves to the rectus muscles and the superior oblique muscle enter the muscles approximately one-third of the distance from the origin to the insertion (or trochlea, in the case of the superior oblique muscle). Damaging these nerves during anterior surgery is unlikely but not impossible. An instrument thrust more than 26 mm posterior to a rectus muscle's insertion may injure the nerve.

Cranial nerve IV is outside the muscle cone and is usually not affected by a retrobulbar block. However, any EOM could be reached by a retrobulbar needle and injured by injection of local anesthetic.

The nerve supplying the inferior oblique muscle enters the lateral portion of the muscle, where it crosses the inferior rectus muscle; surgery performed in this area can damage the nerve. Because parasympathetic fibers to the sphincter pupillae (for pupil constriction) and the ciliary muscle (for accommodation) accompany the nerve to the inferior oblique muscle, with a synapse in the ciliary ganglion, surgery in this area may also result in an enlarged pupil. In addition, an inferotemporal retrobulbar block can injure these nerves and the inferior oblique muscle.

An operation on the inferior oblique muscle requires careful inspection of the inferolateral quadrant to ensure that all bellies are identified. If, during a weakening or strengthening procedure, the presence of a second or third belly is not recognized, the action of the muscle may not be sufficiently altered, and additional surgery may be required.

The neurofibrovascular bundle along the lateral border of the inferior rectus muscle can become an ancillary insertion site for the inferior oblique muscle when the muscle is anteriorly or medially transposed. Anterior transposition of the inferior oblique creates an anti-elevation effect.

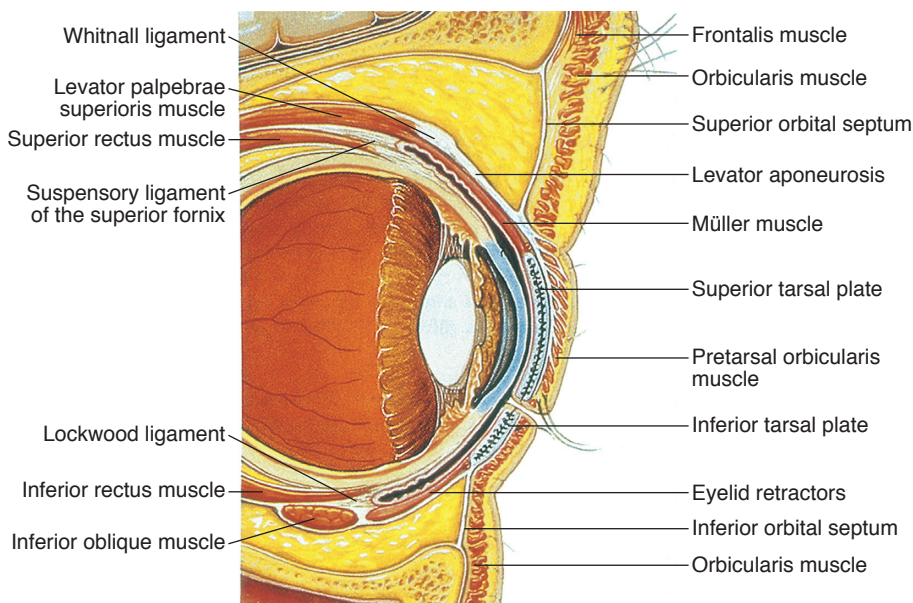
Maintaining the integrity of the muscle capsules during surgery reduces intraoperative bleeding and provides a smooth muscle surface with less risk of adhesion formation. If only the muscle capsule is sutured to the globe, the muscle can retract backward, causing a slipped muscle.

The surgeon can use the intermuscular septum (between the rectus muscles and especially the section between the rectus and oblique muscles) as a point of reference in locating a muscle that has been “lost” during surgery or as a result of trauma. Extensive dissections of the intermuscular septum are not necessary for rectus muscle recession surgery. However, during resection surgery, these connections should be severed to prevent unexpected consequences, such as the inferior oblique muscle being advanced with the lateral rectus muscle. Often, there are 2 frenula: one that connects the lateral rectus muscle to the underlying inferior oblique at its insertion and another that connects the superior rectus to the underlying superior oblique tendon. Usually, these must be disconnected during recessions and resections of either of these 2 rectus muscles.

The medial rectus is the only rectus muscle that does not have an oblique muscle running tangential to it. This makes surgery on the medial rectus less complicated but means that there is neither a point of reference if the surgeon becomes disoriented nor a point of attachment if the muscle is lost.

The inferior rectus muscle is distinctly bound to the lower eyelid by the fascial extension from its sheath. *Recession*, or weakening, of the inferior rectus muscle tends to widen the palpebral fissure and result in lower eyelid retraction. *Resection*, or strengthening, of the inferior rectus muscle tends to narrow the fissure by elevating the lower eyelid. Therefore, any alteration of the inferior rectus muscle may be associated with a change in the palpebral fissure (Fig 3-7).

The superior rectus muscle is loosely bound to the levator palpebrae superioris muscle. The eyelid may be pulled downward after resection of the superior rectus muscle, thus



**Figure 3-7** Attachments of the upper and lower eyelids to the vertical rectus muscles. (Modified with permission from Buckley EG, Freedman S, Shields MB, eds. Atlas of Ophthalmic Surgery, Vol III: Strabismus and Glaucoma. St Louis: Mosby-Year Book; 1995:15.)

narrowing the palpebral fissure. In contrast, the eyelid is not usually retracted upward with small or moderate recessions. In hypotropia, a pseudoptosis may be present because the upper eyelid tends to follow the superior rectus muscle (see Fig 3-7).

The blood supply to the EOMs provides almost all of the temporal half of the anterior segment circulation and most of the nasal half of the anterior segment circulation, which also receives some blood from the long posterior ciliary artery. Therefore, simultaneous surgery on 3 rectus muscles may induce anterior segment ischemia, particularly in older or vasculopathic patients.

Whenever muscle surgery is performed, special care must be taken to avoid penetration of the Tenon capsule 10 mm or more posterior to the limbus. If the integrity of the Tenon capsule is violated posterior to this point, fatty tissue may prolapse through the capsule and form a restrictive adhesion to sclera, muscle, intermuscular septum, or conjunctiva, limiting ocular motility.

When surgery is performed near the vortex veins, accidental severing of a vein is possible. The procedures that present the greatest risk of damaging a vortex vein are recession or resection of the inferior rectus or superior rectus muscle, weakening of the inferior oblique muscle, and exposure of the superior oblique muscle tendon. Hemostasis can be achieved with cautery or with an absorbable hemostatic sponge.

The sclera is thinnest just posterior to the 4 rectus muscle insertions, an area that is the site of most eye muscle surgery, especially recession procedures. Thus, scleral perforation is always a risk during eye muscle surgery. See Chapter 14 for further discussion of EOM surgery.

# Motor Physiology

## Basic Principles and Terms

---

### Ocular Rotations

While there are several coordinate systems that are useful for mathematical modeling of rotations of the eye, ocular rotations are clinically considered as *horizontal rotations* about a vertical axis, corresponding to medial and lateral gaze; *vertical rotations* about a horizontal axis, corresponding to upward and downward gaze; and *torsional rotations* about the line of sight. If a change in gaze position is broken down into a series of separate rotations about the horizontal and vertical axes, the final torsion of the eye for a given gaze direction could theoretically vary, depending on the sequence in which the rotations are applied. In practice, the final torsion of the eye is always the same for a given gaze direction, regardless of the sequence by which it arrives there (*Donders's law*). *Listing's law* specifies this relationship by stipulating that the orientation in a given gaze position is equivalent to that which would result from a single rotation around an axis lying in *Listing's plane*.

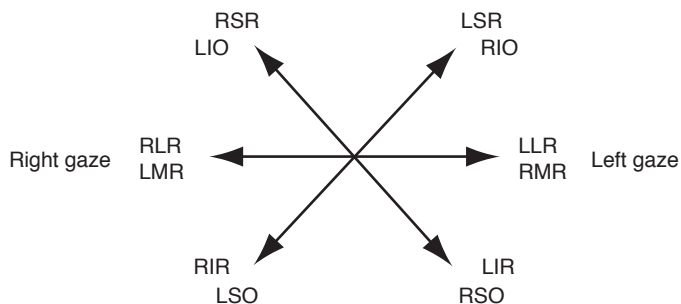
### Positions of Gaze

- *Primary position* is the position of the eyes when they are fixating straight ahead.
- *Secondary diagnostic positions* are straight up, straight down, right gaze, and left gaze.
- *Tertiary diagnostic positions* are the 4 oblique positions of gaze: up and right, up and left, down and right, down and left, as well as the right and left head-tilt positions.
- *Cardinal positions*, which correspond to the primary fields of action of the extraocular muscles (EOMs) (see the section “Field of action”), are up and right, up and left, right, left, down and right, down and left (Fig 4-1).

See Chapter 7 for additional discussion of the positions of gaze.

### Extraocular Muscle Action

The width of the insertion of each EOM serves to stabilize the eye and mitigate changes in action that would otherwise occur in different eye positions. For example, when the eye looks upward, the insertion of the medial rectus muscle also shifts upward. But this also tightens the inferior fibers and slackens the superior fibers, in effect shifting the net



**Figure 4-1** The 6 cardinal positions, which correspond to the primary fields of action of the extraocular muscles. RSR, right superior rectus; LIO, left inferior oblique; LSR, left superior rectus; RIO, right inferior oblique; RLR, right lateral rectus; LMR, left medial rectus; LLR, left lateral rectus; RMR, right medial rectus; RIR, right inferior rectus; LSO, left superior oblique; LIR, left inferior rectus; RSO, right superior oblique.

vector from the muscle downward toward its original position. See also Activity 3-1 in Chapter 3.

**Muscle pulleys**

Regardless of eye position or whether the insertion points have been moved surgically, the rectus muscles are still constrained to pass through the same openings in the Tenon capsule as they course from the orbital apex to the eye. The orbital connective tissue sheaths surrounding these openings have been described as muscle pulleys and have a specialized structure, including smooth muscle, that may provide active modulation of muscle action. See Chapter 3 for further discussion of muscle pulleys.

**Arc of contact**

In primary position, each muscle wraps around the globe for several millimeters before reaching its insertion on the sclera. The length of muscle in contact with the globe is called the *arc of contact* (see Chapter 3, Table 3-1, which gives the arc of contact for the EOMs). The point where the muscle first contacts the globe is the effective insertion of the muscle. As the muscle contracts and the eye rotates toward the muscle, the effective insertion moves forward on the globe, toward the scleral insertion point, as the arc of contact decreases. The muscle remains tangential to the globe at its effective insertion, maintaining the same torque through much of the eye movement.

**Eye Movements**

---

**Motor Units**

An individual motor nerve fiber and its several muscle fibers constitute a motor unit. The electrical activity of motor units can be recorded by *electromyography (EMG)*. An electromyogram is a useful research tool in the investigation of normal and abnormal innervation of eye muscles. A portable EMG device connected to an insulated needle is

often used during injection of botulinum toxin into eye muscles to help the surgeon localize the appropriate muscle within the orbit, especially when the muscle has been operated on previously.

### ***Recruitment during fixation or following movement***

*Recruitment* is the orderly increase in the number of activated motor units, thus increasing the strength of muscle contraction. For example, as the eye moves farther into abduction, more and more lateral rectus motor units are activated and brought into play by the brain to help pull the eye temporally. In addition, as the eye fixates farther into abduction, the firing frequency of each motor unit increases until it reaches a peak (several hundred per second, for some motor units).

## **Monocular Eye Movements**

### ***Ductions***

Ductions are monocular rotations of the eye. *Adduction* is movement of the eye nasally; *abduction* is movement of the eye temporally. *Elevation* (*supraduction* or *sursumduction*) is an upward rotation of the eye; *depression* (*infraduction* or *deorsumduction*) is a downward rotation of the eye. *Intorsion* (*incycloduction*) is defined as a nasal rotation of the superior pole of the vertical meridian. *Extorsion* (*excycloduction*) is a temporal rotation of the superior pole of the vertical meridian.

The following are important terms relating to the muscles used in monocular eye movements:

- *agonist*: the primary muscle moving the eye in a given direction
- *synergist*: the muscle in the same eye as the agonist that acts with the agonist to produce a given movement (eg, the inferior oblique muscle is a synergist with the agonist superior rectus muscle for elevation of the eye)
- *antagonist*: the muscle in the same eye as the agonist that acts in the direction opposite to that of the agonist (eg, the medial rectus and lateral rectus muscles are antagonists)

*Sherrington's law of reciprocal innervation* states that increased innervation of a given EOM is accompanied by a reciprocal decrease in innervation of its antagonist. For example, as the right eye abducts, innervation of the right lateral rectus muscle increases and innervation of the right medial rectus muscle decreases.

### ***Field of action***

*Field of action* refers to the gaze position (one of the cardinal positions) in which the effect of the EOM is most readily observed. For the lateral rectus muscle, the direction of rotation and the position of gaze are both abduction; for the medial rectus muscle, they are both adduction. However, the direction of rotation and the gaze position are not the same for the vertical muscles. For example, the inferior oblique muscle, acting alone, is an abductor and elevator, pulling the eye up and out—but its elevating action is best observed in adduction. Similarly, the superior oblique muscle, acting alone, is an abductor

and depressor, pulling the eye down and out—but its depressing action is best observed in adduction.

The clinical significance of fields of action is that a deviation (strabismus) that increases with gaze in some directions may result from weakness of the muscle normally pulling the eye in that direction, from restriction of its action by its antagonist muscle, or from a combination of these 2 factors.

### **Primary, secondary, and tertiary actions**

With the eye in primary position, the medial and lateral rectus muscles move the eye only horizontally and therefore have a primary horizontal action. Anatomical studies have shown compartmentalization of the innervation to the horizontal rectus muscles in some patients; this may explain the finding of small vertical actions of these muscles in these cases (see Chapter 3). The vertical rectus muscles have a direction of pull that is mostly vertical as their primary action, but in primary position, the angle of pull from origin to insertion is inclined 23° to the visual axis (or midplane of the eye), giving rise to a *torsional* effect as well. Intorsion is the secondary action of the superior rectus, and extorsion is the secondary action of the inferior rectus; because the net positions of the insertions are medial to the center of rotation of the eye, adduction is the tertiary action of both muscles. Because the oblique muscles are inclined 51° to the visual axis, torsion is their primary action, vertical rotation (depression/elevation) is their secondary action, and abduction is their tertiary action. The levator palpebrae superioris is also an EOM, and its sole action is elevation of the upper eyelid. See Table 4-1 for a summary of the EOM actions.

### **Changing muscle action with different gaze positions**

The gaze position can alter the effect of EOM contractions on the rotation of the eye. In each of the cardinal positions, each of the 6 oculorotatory EOMs has different effects on the eye's rotation, based on the relationship between the visual axis of the eye and the orientation of the muscle plane to the visual axis. In each cardinal position, the angle between the visual axis and the direction of pull of the muscle being tested is minimized, thus maximizing the horizontal effect of the medial or lateral rectus or the vertical effect

**Table 4-1 Action of the Extraocular Muscles Referenced to Primary Position**

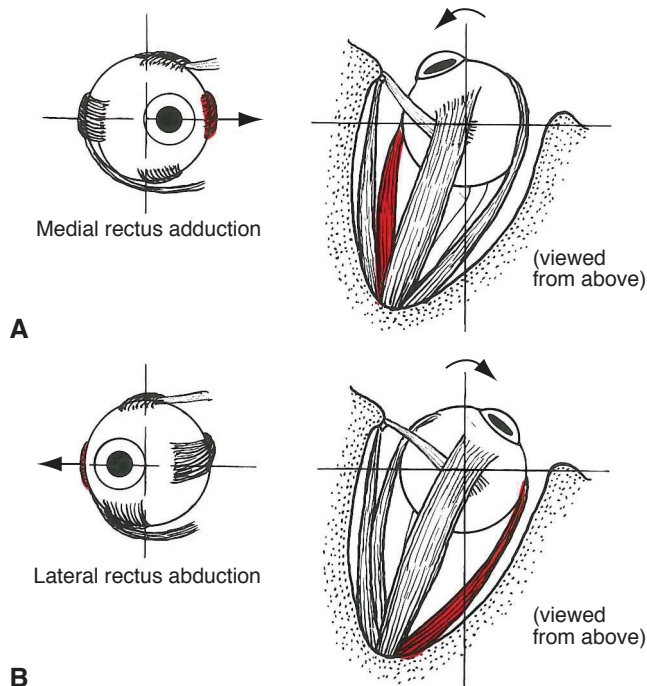
<b>Muscle<sup>a</sup></b>	<b>Primary</b>	<b>Secondary</b>	<b>Tertiary</b>
Medial rectus	Adduction	—	—
Lateral rectus	Abduction	—	—
Inferior rectus	Depression	Extorsion	Adduction
Superior rectus	Elevation	Intorsion	Adduction
Inferior oblique	Extorsion	Elevation	Abduction
Superior oblique	Intorsion	Depression	Abduction
Levator palpebrae superioris	Elevation of upper eyelid	—	—

<sup>a</sup> The superior muscles are intortors; the inferior muscles, extortors. The vertical rectus muscles are adductors; the oblique muscles, abductors.

of the superior rectus, inferior rectus, superior oblique, or inferior oblique. By having the patient move the eyes to the 6 cardinal positions, the clinician can isolate and evaluate the ability of each of the 6 oculorotatory EOMs to move the eye. See also the section Binocular Eye Movements.

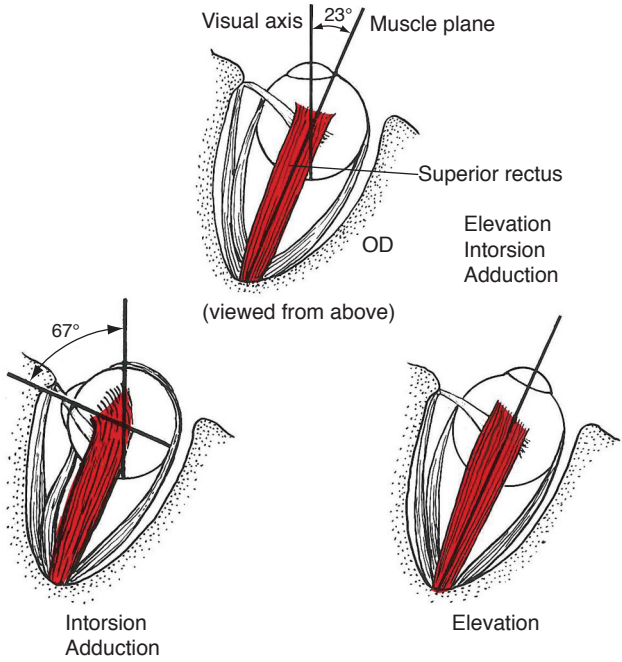
With the eye in primary position, the horizontal rectus muscles share a common horizontal plane that contains the visual axis (Fig 4-2). The clinician can assess the relative strength of the horizontal rectus muscles by observing the horizontal excursion of the eye as it moves medially from primary position to test the medial rectus and laterally to test the lateral rectus. The actions of the vertical rectus and oblique muscles are more complex.

With insertions anterior to the center of rotation of the globe and, in primary position, the  $23^\circ$  angle between the muscle planes and the visual axis (Figs 4-3, 4-4), the superior and inferior rectus muscles have 3 actions: primary vertical, secondary torsion, and tertiary adduction. The relative vertical strength of the vertical rectus muscles can be most readily observed by aligning the visual axis parallel to the muscle plane axis—that is, when the eye is rotated  $23^\circ$  into abduction. In this position, the superior rectus becomes a pure elevator and the inferior rectus a pure depressor. To minimize the vertical action of these muscles, the visual axis should be perpendicular to the muscle axis at a position of  $67^\circ$  of adduction. In this position, the superior rectus action would be

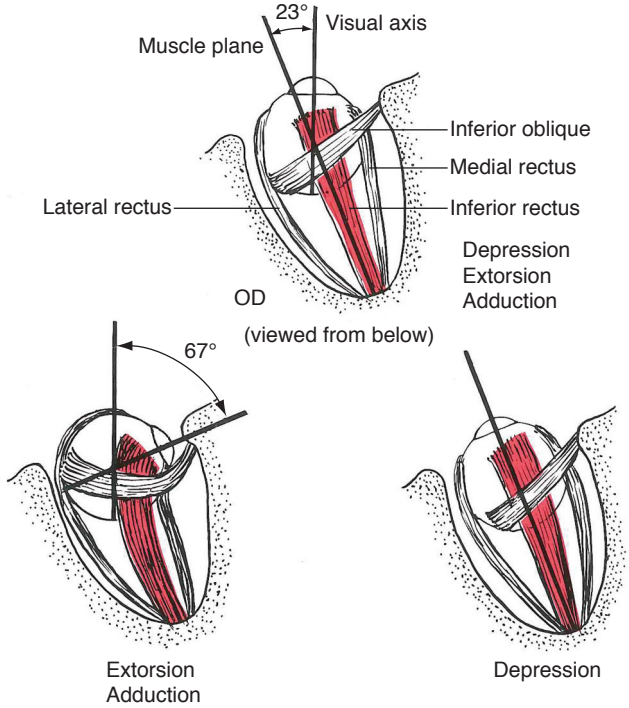


**Figure 4-2** The right horizontal rectus muscles. **A**, Right medial rectus muscle. **B**, Right lateral rectus muscle. (Modified with permission from von Noorden GK. *Atlas of Strabismus*. 4th ed. St Louis: Mosby; 1983:3.)

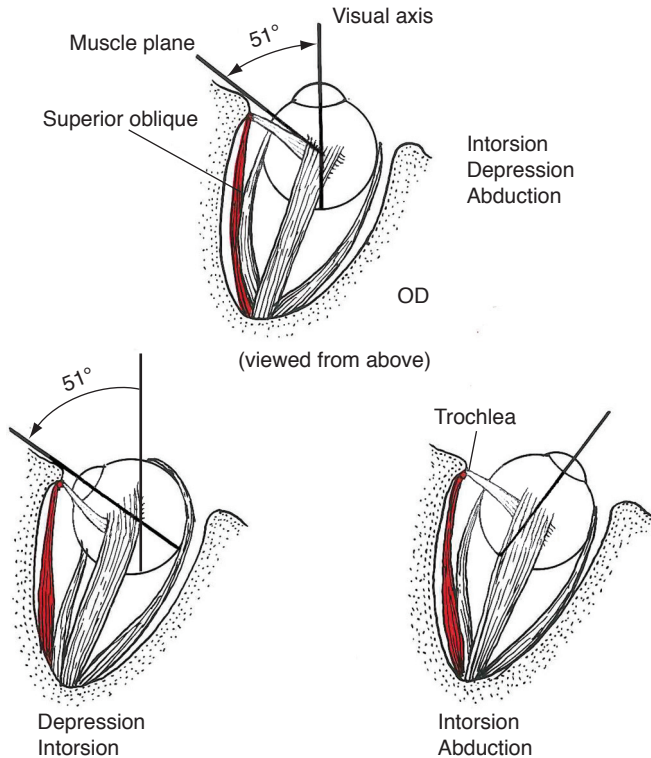




**Figure 4-3** The right superior rectus muscle, viewed from above. (Modified with permission from von Noorden GK. Atlas of Strabismus. 4th ed. St Louis: Mosby; 1983:3.)



**Figure 4-4** The right inferior rectus muscle, viewed from below. (Modified with permission from von Noorden GK. Atlas of Strabismus. 4th ed. St Louis: Mosby; 1983:5.)



**Figure 4-5** The right superior oblique muscle, viewed from above. (Modified with permission from von Noorden GK. Atlas of Strabismus. 4th ed. St Louis: Mosby; 1983:7.)

pure intorsion, and the inferior rectus action would be pure extorsion. Because the globe cannot adduct this far, the vertical rectus muscles maintain significant elevating and depressing action even in maximal voluntary adduction.

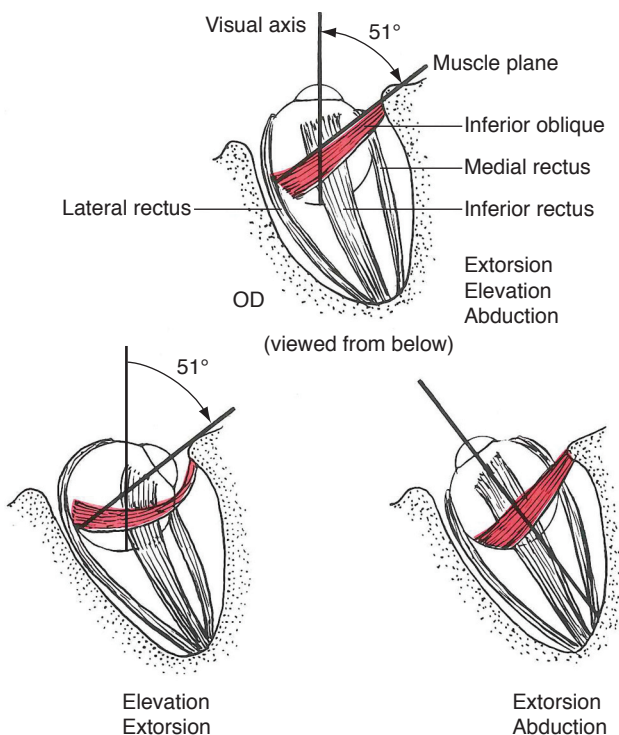
With insertions posterior to the center of rotation of the globe and, in primary position, the 51° angle between the muscle planes and the visual axis (Figs 4-5, 4-6), the superior and inferior oblique muscles have 3 actions: primary torsion, secondary vertical, and tertiary abduction. In 51° adduction, the muscle plane is aligned with the visual axis, and the vertical action of the oblique muscle can be most readily observed. When the eye abducts 39°, the visual axis becomes perpendicular to the muscle plane, and the muscle action is mainly torsion.

## Binocular Eye Movements

When binocular eye movements are conjugate and the eyes move in the same direction, such movements are called *versions*. When the eye movements are dysconjugate and the eyes move in opposite directions, such movements are known as *vergences*.

### Versions

Right gaze (*dextroversion*) is movement of both eyes to the patient's right. Left gaze (*levo-version*) is movement of both eyes to the patient's left. *Elevation*, or *upgaze* (*sursumversion*),



**Figure 4-6** The right inferior oblique muscle, viewed from below. (Modified with permission from von Noorden GK. Atlas of Strabismus. 4th ed. St Louis: Mosby; 1983:9.)

is an upward rotation of both eyes. *Depression*, or *downgaze* (*deorsumversion*), is a downward rotation of both eyes. *Dextrocycloverision* is rotation of the superior pole of the vertical meridian of both eyes to the patient’s right. Similarly, *levocycloverision* is movement of both eyes so that the superior pole of the vertical meridian rotates to the patient’s left.

The term *yoke muscles* is used to describe 2 muscles (1 in each eye) that are the prime movers of their respective eyes into a given position of gaze. For example, when the eyes move into right gaze, the right lateral rectus muscle and the left medial rectus muscle are simultaneously innervated and contracted. These muscles are said to be “yoked” together. Each EOM in one eye has a yoke muscle in the other eye. See Figure 4-1, which shows the 6 cardinal positions of gaze and the yoke muscles whose primary actions are in those fields of gaze.

*Hering’s law of motor correspondence* states that when the eyes move into a gaze direction, there is a simultaneous and equal increase in innervation to the yoke muscles for that direction. Hering’s law has important clinical implications when the practitioner is evaluating a paralytic or restrictive strabismus. Because the amount of innervation supplied to both eyes is always determined by the fixating eye, the angle of deviation varies according to which eye is fixating. When the sound eye is fixating (prism over the affected eye when the prism alternate cover test is performed), the amount of misalignment is called the *primary deviation*. When the affected eye is fixating (prism over the sound eye when the prism alternate cover test is performed), the amount of misalignment is called

the *secondary deviation*. The secondary deviation is larger than the primary deviation because of the increased innervation necessary to move the affected eye to the position of fixation. This extra innervation is shared by the yoke muscle in the sound eye, which causes excessive action of that muscle and a larger angle of deviation.

### **Vergences**

*Convergence* is movement of both eyes nasally relative to a given starting position; *divergence* is movement of both eyes temporally relative to a given starting position. The medial rectus muscles are yoke muscles for convergence, and the lateral rectus muscles are yoked for divergence. With *vertical vergence* movements, one eye moves upward, and the other moves downward. *Incyclovergence* is a rotation of both eyes such that the superior pole of the vertical meridian is rotated nasally; *excyclovergence* is a rotation of both eyes such that the superior pole of the vertical meridian rotates temporally. Vergence movements are described in the following sections; see Table 4-2 for a classification of these movements.

**Accommodative convergence of the visual axes** Part of the near reflex (also called *near synkinesis*, *near triad*), which consists of accommodation, convergence, and miosis. A certain amount of accommodative convergence (AC) occurs with each diopter of accommodation (A), giving the *accommodative convergence/accommodation (AC/A) ratio*.

Abnormalities of this ratio are common and are important causes of strabismus (see Chapter 8). With an abnormally high AC/A ratio, the excess convergence tends to produce esotropia during near fixation that is greater than esotropia at distance. An abnormally low AC/A ratio tends to make the eyes less esotropic, or even exotropic, when the patient looks at near targets. Techniques for measuring this ratio are discussed in Chapter 7 under Convergence.

**Fusional convergence** A movement to converge and position the eyes so that similar retinal images project on corresponding retinal areas. Fusional convergence is activated when a target in the midline is seen with bitemporal retinal image disparity. See also Chapter 5.

**Proximal (instrument) convergence** An induced convergence movement caused by a psychological awareness that the object of fixation is near. This movement is particularly apparent when a person looks through an instrument such as a binocular microscope.

**Table 4-2 Classification of Vergence Movements**

<b>Convergence</b>	<b>Divergence</b>	<b>Vertical Vergence</b>	<b>Cyclovergence</b>
Accommodative convergence of the visual axes	Fusional divergence	Fusional vertical vergence	Fusional excyclovergence
Fusional convergence			Fusional incyclovergence
Proximal (instrument) convergence			
Tonic convergence			
Voluntary convergence			

**Tonic convergence** The constant innervational tone to the EOMs when a person is awake and alert. Because of the anatomical shape of the bony orbits and the position of the rectus muscle origins, the position of the eyes during complete muscle paralysis is divergent. Therefore, convergence tone is normally necessary in the awake state for the eyes to be aligned. For example, an esotropic patient under general anesthesia may become less esotropic or even exotropic with suspension of tonic convergence.

**Voluntary convergence** A conscious application of the near reflex.

**Fusional divergence** A movement to diverge and position the eyes so that similar retinal images project on corresponding retinal areas. Fusional divergence is activated when a target in the midline is seen with binasal retinal image disparity. See also Chapter 5.

**Fusional vertical vergence** A superior movement of one eye and inferior movement of the other to reduce vertical disparity so that similar retinal images project on corresponding retinal areas.

**Fusional cyclovergence** Intorsion of both eyes (incyclovergence) or extorsion of both eyes (excyclovergence) to reduce torsional disparity so that similar retinal images project on corresponding retinal areas. While it can be enhanced by special training, cyclovergence is normally very limited, and fusion of torsional disparity is mostly accomplished by sensory adaptation.

### Supranuclear Control Systems for Eye Movement

Eye movements are directed and coordinated by several supranuclear systems. The *saccadic system* generates fast (up to  $400^{\circ}$ – $500^{\circ}$  per second) eye movements, such as eye movements of refixation. This system functions to place the image of an object of interest on the fovea or to shift gaze from one object to another. Saccadic movements require a sudden strong pulse of force from the EOMs to move the eye rapidly against the viscosity produced by the fatty tissue and the fascia in which the globe lies.

The *smooth-pursuit system* generates following, or pursuit, eye movements that maintain the image of a moving object on the fovea. Pursuit latency is shorter than saccade latency, but the maximum peak velocity of these slow pursuit movements is limited to  $30^{\circ}$ – $60^{\circ}$  per second. The involuntary *optokinetic system* utilizes smooth pursuit to track a moving object and then introduces a compensatory saccade to refixate. Tests of this system, performed with an optokinetic stimulus, are often used to detect visual responses in an infant or child with apparent vision loss, such as with ocular motor apraxia (see Chapter 12). The *vergence system* controls dysconjugate eye movement, as in convergence or divergence. Supranuclear control of vergence eye movements is not yet fully understood. There are also systems that integrate eye movements with body movements in order to stabilize the image on the retinas. The most clinically important of these systems is the *vestibular-ocular system*. Vestibular-ocular reflex responses are driven by the labyrinth, which involves the semicircular canals and otoliths (utricle and saccule) of the inner ears. The cervical, or neck, receptors also provide input for this reflex control. See BCSC Section 5, *Neuro-Ophthalmology*, for in-depth discussion of these systems.

# Sensory Physiology and Pathology

## The Physiology of Normal Binocular Vision

---

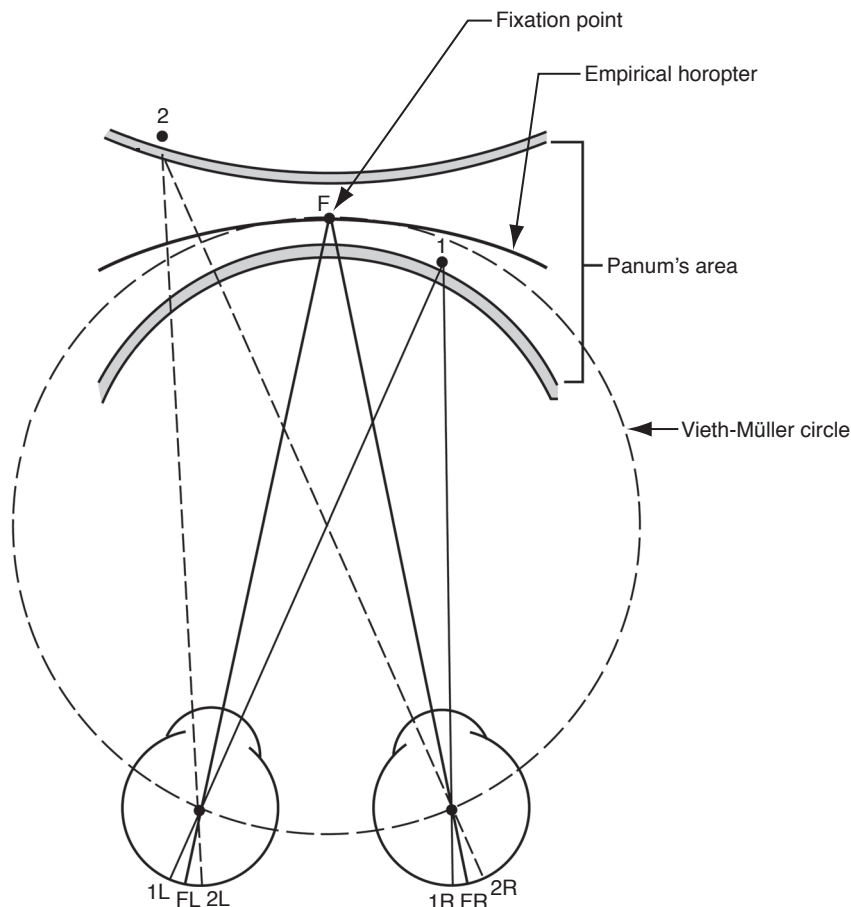
If an area of the retina is stimulated by any means—externally by light or internally by mechanical pressure or electrical processes—the resulting sensation is always one of light, and the light is subjectively localized as coming from a specific visual direction in space. The imaginary line connecting the fixation point and the fovea is termed the *visual axis*, and normally, with central fixation, it is subjectively localized straight ahead.

### Retinal Correspondence

If the stimulated areas of the retinas in the 2 eyes, or retinal locations, share a common subjective visual direction—that is, if stimulation of these 2 points results in the subjective sensation that the stimulating target or targets lie in the same direction—these retinal locations are said to be *corresponding*. When the image of an object in space falls on corresponding points, it is perceived as a single object. On the other hand, stimulation of *noncorresponding* or *disparate* retinal points results in the sensation of 2 visual directions for the same target, or diplopia.

With *normal retinal correspondence*, the foveae of the 2 eyes are corresponding points. Retinal areas in each eye that are essentially equidistant to the right or left and above or below the fovea are also corresponding points. The locus of points in space that stimulate corresponding points in each retina is known as the *horopter*. With symmetric convergence, the geometric relationship between corresponding points—for example, a point 1° nasal to the fovea in 1 eye would correspond to a point 1° temporal to the fovea in the other eye—gives a circle that passes through the nodal point of each eye and the point of fixation. This theoretical horopter is known as the *Vieth-Müller circle*. When the horopter is determined experimentally, the locus of points that are seen singly falls not on a circle but on a curve called the *empirical horopter* (Fig 5-1).

The horopter exists in both the horizontal and vertical planes. Although it might seem that the horopter would be a surface in space, the horizontal separation of the eyes causes points in the oblique quadrants to be vertically disparate. For symmetric convergence, the 3-dimensional horopter of points having both horizontal and vertical correspondence consists of a curved horizontal line and a sloped vertical line that intersect at the fixation point. Each fixation point has a unique horopter centered on that point.



**Figure 5-1** Empirical horopter. F = fixation point; FL and FR = left and right foveae, respectively. Point 1, falling within Panum's area, is seen singly and stereoscopically. Point 2 falls outside Panum's area and is therefore seen doubly.

If the horopter includes all points in space that stimulate corresponding retinal points, double vision would be expected when the target does not lie on the horopter. However, the visual system can combine slightly disparate points within a limited area surrounding the horopter, called *Panum's area of single binocular vision* (see Fig 5-1). Objects within Panum's area do not result in diplopia. Objects outside Panum's area stimulate widely disparate retinal points, resulting in physiologic diplopia. If an object is distal to Panum's area, uncrossed physiologic diplopia will result; if an object is proximal to Panum's area, crossed physiologic diplopia will result.

### Fusion

*Fusion* is the cortical unification of 2 images of an object, 1 from each eye, into a single percept. For retinal images to be fused, they must be similar in size and shape. For fusion of macular images (*central fusion*) to occur, there can be very little dissimilarity between

the images in each eye, because of the small receptive fields in the area near the fovea; otherwise, diplopia results. More image dissimilarity is tolerated in the periphery (peripheral fusion), where the receptive fields are larger. Fusion has been artificially subdivided into sensory fusion, motor fusion, and stereopsis.

### **Sensory fusion**

Sensory fusion is based on the innate, orderly topographic relationship between the retinas and the visual cortex, whereby images falling on corresponding (or nearly corresponding) retinal points in the 2 eyes are combined to form a single visual percept.

### **Motor fusion**

Motor fusion is a vergence movement that allows similar retinal images to be maintained on corresponding retinal areas despite natural conditions (eg, heterophorias) or artificial causes that induce disparities. For example, when a progressive base-out prism is introduced before both eyes while a target is viewed, the retinal images move temporally over both retinas if the eyes remain in fixed position. However, because of a response called *fusional convergence* (see Chapter 4), the eyes instead converge, repositioning so that similar retinal images are projected on corresponding retinal areas. Measurement of fusional vergence amplitudes is discussed in Chapter 7.

### **Stereopsis**

Stereopsis occurs when horizontal retinal disparity between the 2 eyes produces a subjective ordering of images of objects in depth, or 3 dimensions. It is the highest form of binocular cooperation and adds a unique quality to vision. The region of points with binocular disparities that result in stereopsis is slightly wider than Panum's area, so stereopsis is not simply a by-product of combining the disparate images from a point into a single visual percept. The brain interprets nasal disparity between 2 similar retinal images of an object in the midline as indicating that the object is farther away from the fixation point, and temporal disparity as indicating that the object is nearer. Binasal or bitemporal images are not a requirement for stereopsis; objects not in the midline in front of or behind the horopter also elicit stereopsis, even though their images fall on the nasal retina in 1 eye and the temporal retina in the other.

Stereopsis and depth perception (*bathopsis*) are not synonymous. Monocular cues—which include object overlap, relative object size, highlights and shadows, motion parallax, and perspective—also contribute to depth perception. Monocular patients can have excellent depth perception using these cues. Stereopsis is a *binocular* sensation of relative depth caused by horizontal disparity of retinal images.

## **Selected Aspects of the Neurophysiology of Vision**

---

The decussation of the optic nerves at the chiasm is essential for the development of binocular vision and stereopsis. With decussation, visual information from corresponding retinal areas in each eye runs through the lateral geniculate body (lateral geniculate nucleus) and optic tracts to the visual cortex, where the information from both eyes is



commingled and modified by the integration of various inputs. See BCSC Section 5, *Neuro-Ophthalmology*, Chapter 1, for further discussion.

### Visual Development

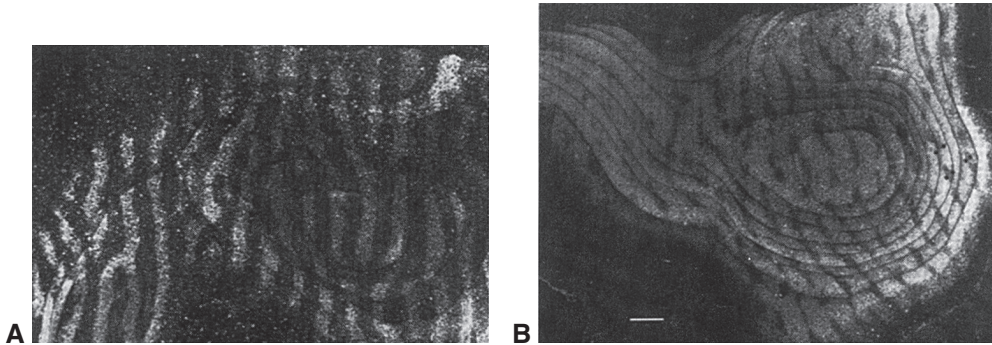
In the human retina, most of the ganglion cells are generated between 8 and 15 weeks' gestation, reaching a plateau of 2.2–2.5 million by week 18. After week 30, the retinal ganglion cell (RGC) population decreases dramatically during a period of rapid cell death (a process termed *apoptosis*) that lasts 6–8 weeks. Thereafter, RGC death continues at a low rate into the first few postnatal months. The RGC population is reduced to a final count of approximately 1.0–1.5 million. The loss of about 1 million RGC axons may serve to refine the topography and specificity of the retinogeniculate projection by eliminating inappropriate connections.

The continued development of visual function after birth is accompanied by major anatomical changes, which occur at all levels of the central visual pathways. The fovea is still covered by multiple cell layers and is sparsely packed with cones, which, in addition to neural immaturity, contributes to the estimated visual acuity of 20/400 in the newborn. During the first years of life, the photoreceptors redistribute within the retina, and foveal cone density increases fivefold to achieve the configuration found in the mature retina. In newborns, the white matter of the visual pathways is not fully myelinated. Myelin sheaths enlarge rapidly in the first 2 years after birth and then more slowly through the first decade of life. At birth, the neurons of the lateral geniculate body are only 60% of their average adult size. Their volume gradually increases until age 2 years. Refinement of synaptic connections in the striate cortex continues for many years after birth. The density of synapses declines by 40% over several years, attaining final adult levels at approximately age 10 years.

See BCSC Section 2, *Fundamentals and Principles of Ophthalmology*, for further discussion of ocular development.

### Effects of Abnormal Visual Experience on the Retinogeniculocortical Pathway

Abnormal visual experience resulting from visual deprivation, anisometropia, or strabismus can powerfully affect retinogeniculocortical development. In studies of baby macaque monkeys, single-eyelid suturing usually produces axial myopia but no other significant anatomical changes in the eye. The lateral geniculate laminae that receive input from the deprived eye experience minor shrinkage, but these cells respond rapidly to visual stimulation, suggesting that a defect in the lateral geniculate body is not likely to account for amblyopia. In the striate cortex, monocular visual deprivation causes the regions of the visual cortex driven predominantly by the closed eye (ocular dominance columns) to radically narrow (Fig 5-2). This occurs because the 2 eyes compete for synaptic contacts in the cortex. As a result, the deprived eye loses many of the connections already formed at birth with postsynaptic cortical targets. The open eye profits by the sprouting of terminal arbors beyond their usual boundaries to occupy territory relinquished by the deprived eye (Fig 5-3). However, the benefit derived from invading the cortical territory of the deprived eye is unclear because visual acuity does not improve beyond normal. Positron emission



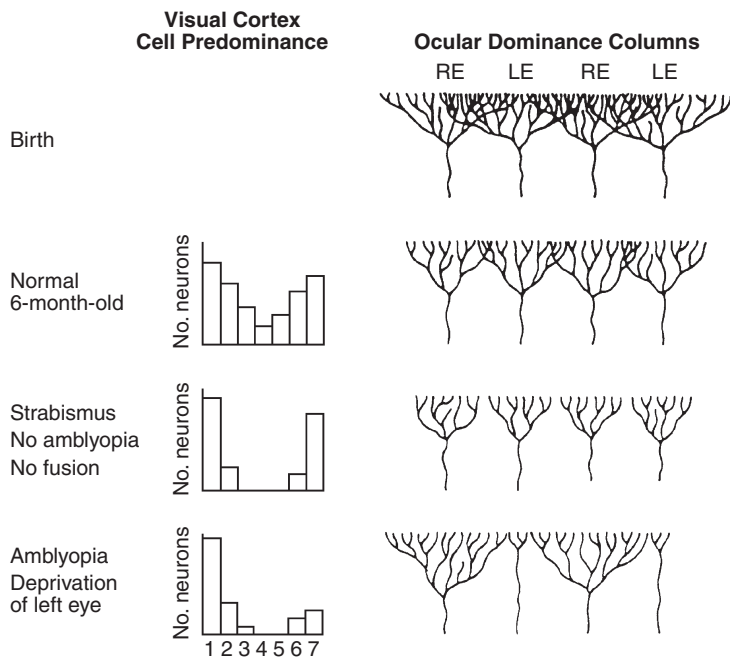
**Figure 5-2** Change in ocular dominance columns in macaque visual cortex after monocular deprivation. Radioactive proline was injected into the normal eye and transported to the visual cortex to reveal the projections of that eye. In these sections, cut parallel to the cortical surface, white areas show labeled terminals. **A**, Normal monkey. There is roughly equal spacing of the stripes, which represent the injected eye (*bright*) and noninjected eye (*dark*). **B**, Monkey that had 1 eye sutured closed from birth for 18 months. The bright stripes (open, injected eye) are widened and the dark ones (closed eye) are greatly narrowed, showing the devastating physical effect of deprivation amblyopia. (Scale bar = 1 mm.) (Reproduced with permission from Kaufman PL, Alm A. *Adler's Physiology of the Eye*. 10th ed. St Louis: Mosby; 2002:699. Originally from Hubel DH, Wiesel TN, LeVay S. *Plasticity of ocular dominance columns in monkey striate cortex*. *Philos Trans R Soc Lond B Biol Sci*. 1977;278(961):377–409.)

tomography has shown that cortical blood flow and glucose metabolism are lower during stimulation of the amblyopic eye compared with the normal eye, suggesting the visual cortex as the primary site of amblyopia. Monocular deprivation also devastates binocularity because few cells can be driven by both eyes.

There is a critical period in which visual development in the macaque is vulnerable to the effects of eyelid suturing. This period corresponds to the stage in which wiring of the striate cortex is still vulnerable to the effects of visual deprivation. During the critical period, the deleterious effects of suturing the right eyelid, for example, are correctable by reversal—that is, opening the sutured right eye and closing the left eye. After this reversal, the ocular dominance columns of the initially closed right eye appear practically normal, indicating that anatomical recovery of the initially shrunken columns was induced by opening the right eye and closing the left eye. However, when the right eye is sewn closed beyond the critical period, the columns of the right eye do not re-expand if the right eye is opened and the left eye closed.

Eyelid suturing in the baby macaque is a good model for visual deprivation amblyopia. In children, this condition can be caused by any dense opacity of the ocular media or occlusion by the eyelid. Visual deprivation can rapidly cause profound amblyopia.

There are other causes of amblyopia in children. Optical defocus resulting from anisometropia causes the cortical neurons driven by the defocused eye to be less sensitive (particularly to higher spatial frequencies, because they are most affected by blur) and to send out a weaker signal. This results in reduced binocular activity. The critical period for anisometropic amblyopia occurs later than that for strabismic amblyopia, and a prolonged period of unilateral blur is necessary before anisometropic amblyopia develops.



**Figure 5-3** Anatomical and physiologic maturation of ocular dominance columns of the primary visual cortex in normal and deprived monkeys. *Birth*: Broad overlap of afferents from the lateral geniculate nucleus, hence little dominance by right eye (RE) versus left eye (LE). *Normal 6-month-old*: Regression of overlapping afferents from both eyes with distinct areas of monocular dominance. The bar graph shows the classic U-shaped distribution obtained by single-cell recordings from the visual cortex. About half the cells are driven predominantly by the right eye and the other half by the left eye. A small number are driven equally by the 2 eyes. 1 = driven only by right eye; 2–6 = driven binocularly; 7 = driven only by left eye. *Strabismus*: Effect of artificial eye misalignment in the neonatal period on ocular dominance. The monkey alternated fixation (no amblyopia) and lacked fusion. Lack of binocularity is evident as exaggerated segregation into dominance columns. The bar graph shows the results of single-cell recordings obtained from this animal after age 1 year. Almost all neurons are driven exclusively by the right or left eye, with little binocular activity. *Amblyopia*: Effect of suturing the left eyelid shut shortly after birth. Dominance columns of the normal right eye are much wider than those of the deprivationally amblyopic left eye. The bar graph shows markedly skewed ocular dominance and little binocular activity. (Modified with permission from Tychsen L. *Binocular vision*. In: Hart WM, ed. *Adler's Physiology of the Eye: Clinical Application*. 9th ed. St Louis: Mosby; 1992:810.)

Meridional (astigmatic) amblyopia does not develop during the first year of life and may not develop until age 3 years.

Strabismus can be artificially created in monkeys by the sectioning of an extraocular muscle. Alternating fixation develops in some monkeys after this procedure; they maintain normal acuity in each eye. Examination of the striate cortex reveals cells with normal receptive fields and an equal number of cells responsive to stimulation of either eye. However, the cortex is bereft of binocular cells (see Fig 5-3). After 1 extraocular muscle is cut, some monkeys do not alternately fixate; instead, they constantly fixate with the same eye, and amblyopia develops in the deviating eye. An important factor in the

development of strabismic amblyopia is interocular suppression due to uncorrelated images in the 2 eyes. Strabismus prevents synchronous attainment of correlated images from the 2 foveae, resulting in abnormal input to the striate cortex. Another factor is the optical defocus of the deviated eye. The dominant eye is focused on the object of regard, while the deviated eye is oriented in a different direction; for the deviated eye, the object may be too near or too far to be in focus. Either mechanism can cause asynchrony or inhibition of 1 set of signals in the striate cortex. The critical period for development of strabismic amblyopia begins at approximately 4 months of age, during the time of ocular dominance segregation and sensitivity to binocular correlation.

Abnormal sensory input alone is sufficient to alter the normal anatomy of the visual cortex. Other areas of the cerebral cortex may also depend on sensory stimulation to form the proper anatomical circuits necessary for normal adult visual function, underscoring the importance of providing children with a stimulating sensory environment.

## Abnormalities of Binocular Vision


When a manifest deviation of the eyes occurs, the corresponding retinal elements of the eyes are no longer directed at the same object. This places the patient at risk for 2 distinct visual phenomena: visual confusion and diplopia.

### Visual Confusion

Visual confusion is the perception of a common visual direction for 2 separate objects. The 2 foveal areas are physiologically incapable of simultaneous perception of dissimilar objects. The closest foveal equivalent is *retinal rivalry*, wherein there is rapid alternation of the 2 perceived images (Fig 5-4). Confusion may be a phenomenon of extrafoveal retinal areas only. Clinically significant visual confusion is rare.

### Diplopia

Double vision, or *diplopia*, usually results from an acquired misalignment of the visual axes that causes an image to fall simultaneously on the fovea of one eye and on a



**Figure 5-4** Rivalry pattern. **A**, Pattern seen by the left eye. **B**, Pattern seen by the right eye. **C**, Pattern seen with binocular vision. (Reproduced with permission from von Noorden GK, Campos EC. Binocular Vision and Ocular Motility: Theory and Management of Strabismus. 6th ed. St Louis: Mosby; 2002:12.)

nonfoveal point in the other eye. As stated earlier, the object that falls on these disparate retinal points must be outside Panum's area to appear double. The same object is perceived as having 2 locations in subjective space, and the foveal image is always clearer than the nonfoveal image of the nonfixating eye. The perception of diplopia depends on the age at onset, its duration, and the patient's subjective awareness of it. The younger the child, the greater the ability to suppress, or inhibit, the nonfoveal image. Adults with acquired strabismus commonly present to the ophthalmologist because of diplopia.

The loss of normal binocular fusion in an individual unable to suppress disparate retinal images results in intractable diplopia, referred to as *central fusion disruption (horror fusionis)*. This condition is typically seen in adults or visually mature children and can occur in a number of clinical settings, including prolonged visual deprivation due to monocular occlusion or a mature cataract, traumatic brain injury, or long-standing strabismus. Management is challenging.

El-Sahn MF, Granet DB, Marvasti A, Roa A, Kinori M. Strabismus in adults older than 60 years. *J Pediatr Ophthalmol Strabismus*. 2016;53(6):365–368.

## Sensory Adaptations in Strabismus

---

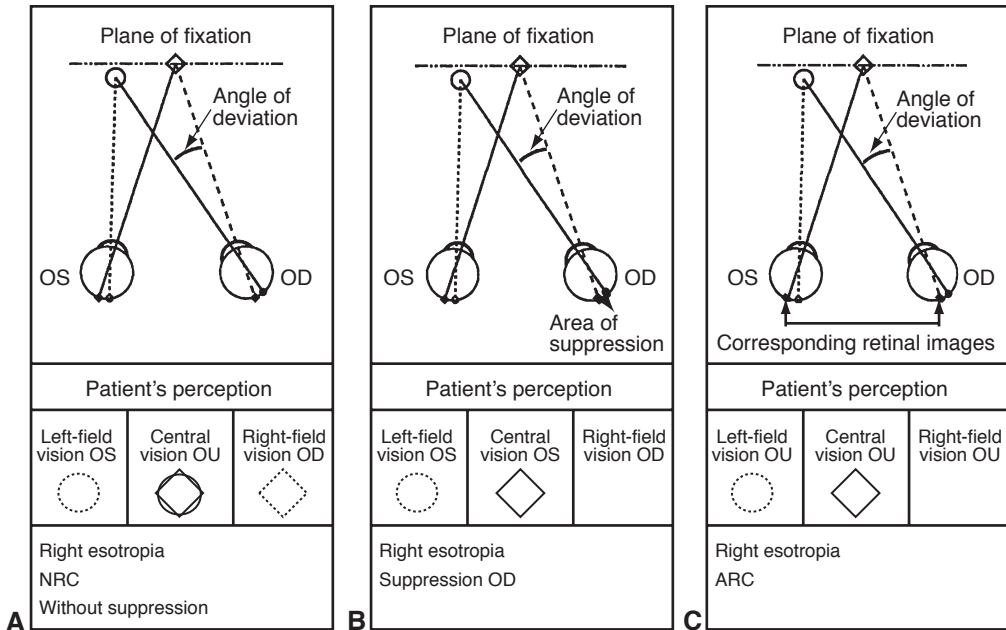
To avoid visual confusion and diplopia, the visual system uses the mechanisms of suppression and anomalous retinal correspondence (Fig 5-5). Pathologic suppression and anomalous retinal correspondence develop only in the immature visual system.

### Suppression

Suppression is the alteration of visual sensation that occurs when an eye's retinal image is inhibited or prevented from reaching consciousness during binocular visual activity. Physiologic suppression is the mechanism that prevents physiologic diplopia (diplopia elicited by objects outside Panum's area) from reaching consciousness. Pathologic suppression may develop because of strabismic misalignment of the visual axes or other conditions resulting in discordant images in each eye, such as cataract or anisometropia. Such suppression can be regarded as an adaptation within the immature visual system to avoid diplopia. If a patient with strabismus and normal retinal correspondence (NRC) does not have diplopia, suppression is present, provided the sensory pathways are intact. In less obvious situations, several simple tests are available for clinical diagnosis of suppression (see Chapter 7).

The following classification of suppression may be useful for the clinician:

- *Central versus peripheral*. *Central suppression* is the mechanism that keeps the foveal image of the deviating eye from reaching consciousness, thereby preventing visual confusion. *Peripheral suppression*, another mechanism, eliminates diplopia by preventing awareness of the image that falls on the peripheral retina in the deviating eye, which corresponds to the image falling on the fovea of the fixating eye. This form of suppression is clearly pathologic, developing as a cortical adaptation



**Figure 5-5** Retinal correspondence and suppression in strabismus. **A**, A patient with right esotropia with normal retinal correspondence (NRC) and without suppression would have diplopia and visual confusion, which is the perception of a common visual direction for 2 separate objects (represented by the superimposition of the images of the fixated diamond and the circle, which is imaged on the fovea of the deviating eye). **B**, The elimination of diplopia and confusion by suppression of the retinal image of the deviating/esotropic right eye. **C**, The elimination of diplopia and confusion by anomalous retinal correspondence (ARC), an adaptation of visual directions in the deviated right eye. (Adapted with permission from Kaufman PL, Alm A. *Adler's Physiology of the Eye*. 10th ed. St Louis: Mosby; 2003:490.)

only within an immature visual system. When strabismus develops after visual maturation/in adults, peripheral suppression does not develop and the patient is thus unable to eliminate the peripheral second image without closing or occluding the deviating eye.

- *Nonalternating versus alternating*. If suppression always causes the image from the dominant eye to be predominant over the image from the deviating eye, the suppression is *nonalternating*. This may lead to amblyopia. If the process switches between the 2 eyes, the suppression is described as *alternating*.
- *Facultative versus constant*. Suppression may be considered *facultative* if it is present only when the eyes are deviated and is absent in all other states. Patients with intermittent exotropia, for instance, often experience suppression when the eyes are divergent but may experience high-grade stereopsis when the eyes are straight. In contrast, *constant suppression* denotes suppression that is always present, whether the eyes are deviated or aligned. The suppression scotoma in the deviating eye may be either *relative* (permitting some visual sensation) or *absolute* (permitting no perception of light).

### Management of suppression

Therapy for suppression often includes the following:

- proper refractive correction
- amblyopia therapy using occlusion or pharmacologic treatment
- alignment of the visual axes, to permit simultaneous stimulation of corresponding retinal elements by the same object

Antisuppression orthoptic exercises may result in intractable diplopia and are not typically recommended.

### Anomalous Retinal Correspondence

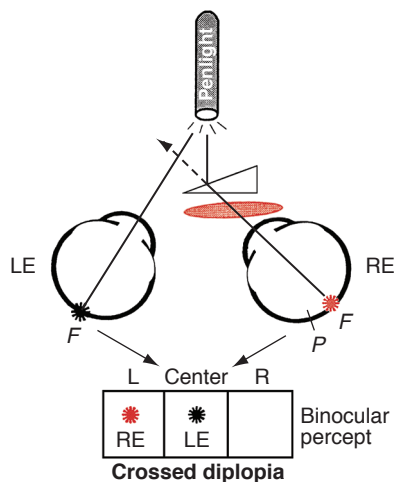
*Anomalous retinal correspondence (ARC)* is a condition wherein the fovea of the fixating eye has acquired an anomalous common visual direction with a peripheral retinal element in the deviating eye. ARC is an adaptation that restores some degree of binocular cooperation despite manifest strabismus. Anomalous binocular vision is a functional state that is superior to total suppression. In the development of ARC, normal sensory development is replaced only gradually and not completely. The more long-standing the deviation, the more deeply rooted the ARC may become. The period during which ARC may develop probably extends through the first decade of life.

*Paradoxical diplopia* can occur when ARC persists after strabismus surgery. For example, when esotropic patients with proper or nearly proper ocular alignment after surgery report symptoms of a crossed diplopic localization of foveal or parafoveal stimuli, they are experiencing paradoxical diplopia (Fig 5-6). Paradoxical diplopia is typically a fleeting postoperative phenomenon, seldom lasting longer than a few days or weeks, but in rare cases it can persist much longer.

### Testing for anomalous retinal correspondence

Testing for ARC is performed to determine how affected patients use their eyes in everyday life and to seek any vestiges of normal correspondence. As discussed earlier, ARC is a

**Figure 5-6** Paradoxical diplopia. Diagram of esotropia and ARC, wherein the deviation is being neutralized with a base-out prism. A red glass and base-out prism are placed over the right eye. The prism neutralizes the deviation by moving the retinal image of the penlight temporarily, off the pseudofovea (*P*) to the true fovea (*F*). Because the pseudofovea is the center of orientation, the image is perceived to fall on the temporal retina and is projected to the opposite field, thus resulting in crossed diplopia. (Modified with permission from Wright KW, Spiegel PH. Pediatric Ophthalmology and Strabismus. St Louis: Mosby; 1999:219.)



sensory adaptation to abnormal ocular alignment. Because the depth of the sensory rearrangement can vary widely, an individual can test positive for both NRC and ARC. Tests that closely simulate everyday use of the eyes are more likely to give evidence of ARC. The more dissociative the test, the more likely it is to produce an NRC response, unless the ARC is deeply rooted. Some of the more common tests (discussed at length in Chapter 7), in order of most to least dissociative, are the afterimage test, the Worth 4-dot test, the red-glass test (dissociation increases with the density of the red filter), amblyoscope testing, and testing with Bagolini striated lenses. If an anomalous localization response occurs in the more dissociative tests, the depth of ARC is greater.

Note that ARC is a binocular phenomenon, tested for and documented in both eyes simultaneously. It is not necessarily related to eccentric fixation (see Chapter 6), which is a monocular phenomenon found in testing 1 eye alone. Because some tests for ARC depend on separate stimulation of each fovea, the presence of eccentric fixation can significantly affect the test results (see also Chapter 7).

### **Monofixation Syndrome**

The term *monofixation syndrome* is used to describe a particular presentation of a sensory state in strabismus. The essential feature of this syndrome is the presence of peripheral fusion with the absence of bifoveal fusion due to a central scotoma. The term *microtropia* was introduced separately to describe small-angle strabismus with a constellation of findings that largely overlap those of monofixation syndrome.

A patient with monofixation syndrome may have no manifest deviation but usually has a small ( $\leq 8$  prism diopters [ $\Delta$ ]) heterotropia; the heterotropia is most commonly an esotropia but is sometimes an exotropia or hypertropia. Stereoacuity is present but reduced. Amblyopia is a common finding.

Monofixation syndrome is a favorable outcome of infantile strabismus surgery and is present in a substantial minority of patients with intermittent exotropia. It can also be a primary condition that causes unilaterally decreased vision when no obvious strabismus is present. Monofixation syndrome can result from anisometropia or macular lesions as well.

### **Diagnosis**

To diagnose monofixation syndrome, the clinician must demonstrate the absence of binocular fusion by documenting a macular scotoma in the nonfixating eye under binocular conditions and the presence of peripheral binocular vision (peripheral fusion).

Vectographic projections of Snellen letters can be used to document the facultative scotoma of monofixation syndrome. Snellen letters are viewed through polarized analyzers or goggles equipped with liquid-crystal shutters so that some letters are seen with only the right eye, some with only the left eye, and some with both eyes. Patients with monofixation syndrome omit letters that are imaged only in the nonfixating eye. Various other tests for central suppression are more commonly used (see Chapter 7).

Testing stereoacuity is an important part of the monofixation syndrome evaluation. Any amount of gross stereopsis confirms the presence of peripheral fusion. Most patients with monofixation syndrome demonstrate stereopsis of 200–3000 seconds of arc. However, because some patients with this syndrome have no demonstrable stereopsis, other



tests for peripheral fusion, such as the Worth 4-dot test and testing with Bagolini lenses, must be used in conjunction with stereoacuity measurement. Fine stereopsis (better than 67 seconds of arc) is present only in patients with bifoveal fixation.

**Management**

If associated amblyopia is clinically significant, occlusion therapy is indicated. Monofixation may decompensate to a larger heterotropia in adulthood, resulting in diplopia. Strabismus surgery may be required to restore fusion.

Ing MR, Roberts KM, Lin A, Chen JJ. The stability of the monofixation syndrome. *Am J Ophthalmol.* 2014;157(1):248–253.

# Amblyopia

Amblyopia is a unilateral or, less commonly, bilateral reduction of best-corrected visual acuity (also referred to as *corrected distance visual acuity*) that cannot be attributed directly to the effect of any structural abnormality of the eye or visual pathways. Amblyopia signifies a failure of normal neural development in the immature visual system (see Chapter 5) and is caused by abnormal visual experience early in life resulting from one or a combination of the following:

- strabismus
- refractive error: anisometropia or bilateral high refractive error (isoametropia)
- visual deprivation in 1 or both eyes

## Epidemiology

---

Amblyopia is responsible for more cases of childhood-onset unilateral decreased vision than all other causes combined, with a prevalence of 2%–4% in North America. It is also the most common cause of unilateral visual impairment in adults younger than 60 years. Amblyopia prevalence is increased in the setting of prematurity, developmental delay, or family history of amblyopia.

## Pathophysiology

---

In early postnatal development, there are critical periods of cortical development during which neural circuits display a heightened sensitivity to environmental stimuli and are dependent on natural sensory experience for proper formation (see also Chapter 5). During these periods, the developing visual system is vulnerable to abnormal input due to visual deprivation, strabismus, or significant blur resulting from anisometropia or isoametropia. Conversely, the visual system's plasticity early in development allows the greatest opportunity for amblyopia reversal. The window of opportunity for treatment depends on the type of amblyopia (see the next section, Classification). For example, the critical period for reversal of visual deprivation amblyopia (eg, due to infantile cataracts) is shorter than that for reversal of infantile strabismic or anisometropic amblyopia.

Amblyopic visual deficits result primarily from visual cortical changes. With abnormal visual experience early in life, cells of the primary visual cortex can lose their ability

to respond to stimulation of 1 or both eyes, and the cells that remain responsive show significant functional deficiencies, including abnormally large receptive fields. Visual cortex deficiencies may account for the crowding phenomenon, in which optotypes are easier to recognize when isolated than when surrounded by similar forms (see Chapter 1). Abnormalities are also found in neurons within the lateral geniculate body, but the retina in amblyopia is essentially normal. Amblyopia is primarily a defect of central vision; the peripheral visual field is usually normal.

## Classification

---

### Strabismic Amblyopia

Strabismic amblyopia results from competitive or inhibitory interaction between neurons carrying nonfusible input from the 2 eyes. Constant, nonalternating heterotropias are the most likely deviations to cause amblyopia. The visual cortex becomes dominated by input from the fixating eye, with reduced responsiveness to input from the nonfixating eye. In young children with strabismus, suppression develops rapidly. This visual adaptation serves to avoid diplopia and visual confusion (see Chapter 5), but in a child who does not alternate fixation, constant suppression of input from the same eye can lead to amblyopia.

Several features distinguish strabismic amblyopia from other types of amblyopia. *Grating acuity* (see Chapter 1), the ability to resolve uniformly spaced stripes, is often reduced less than recognition acuity. Measurements obtained with Teller Acuity Cards II (Stereo Optical, Inc, Chicago, IL) and the LEA Grating Acuity Test (Good-Lite Company, Elgin, IL) may overestimate recognition visual acuity. Visual acuity measured through a neutral density filter declines less sharply for patients with strabismic amblyopia than for those with ocular disease (*neutral density filter effect*).

*Eccentric fixation* is the consistent use of a nonfoveal region of the retina during monocular viewing. Minor degrees of eccentric fixation, detectable only with special tests such as visuoscopy, are present in many patients with strabismic amblyopia. Clinically evident eccentric fixation results in a decentered position of the corneal light reflex when the amblyopic eye is fixating monocularly and implies visual acuity of 20/200 or worse, as well as a poorer prognosis. It should not be confused with an abnormal angle kappa (see Chapter 7).

### Refractive Amblyopia

Refractive amblyopia results from consistent retinal defocus in 1 or both eyes. Anisometropia causes unilateral amblyopia; isoametropia causes bilateral amblyopia.

#### ***Anisometropic amblyopia***

In anisometropic amblyopia, dissimilar refractive errors in the 2 eyes cause 1 retinal image to be chronically defocused. Considered more prevalent than strabismic amblyopia in some recent US studies, this condition is thought to result partly from the direct effect of image blur and partly from interocular competition or inhibition similar (but not identical)

to that responsible for strabismic amblyopia. Levels of anisometropia that commonly lead to amblyopia are greater than 1.50 diopters (D) of anisohyperopia, 2.00 D of anisoastigmatism, and 3.00 D of anisomyopia. Higher levels are associated with greater risk. The eyes of a child with anisometropic amblyopia usually appear normal to the family and primary care physician, which may delay detection and treatment.

McKean-Cowdin R, Cotter SA, Tarczy-Hornoch K, et al; Multi-ethnic Pediatric Eye Disease Study Group. Prevalence of amblyopia or strabismus in Asian and non-Hispanic white preschool children: Multi-ethnic Pediatric Eye Disease Study. *Ophthalmology*. 2013;120(10):2117–2124.

Multi-ethnic Pediatric Eye Disease Study Group. Prevalence of amblyopia and strabismus in African American and Hispanic children ages 6 to 72 months: The Multi-ethnic Pediatric Eye Disease Study. *Ophthalmology*. 2008;115(7):1229–1236.e1.

### ***Isoametropic amblyopia***

Isoametropic amblyopia (bilateral ametropic amblyopia) is bilaterally decreased visual acuity resulting from chronically defocused retinal images, which are due to similarly large uncorrected refractive errors in both eyes. Hyperopia exceeding 4.00–5.00 D and myopia exceeding 5.00–6.00 D are risk factors. Bilateral high astigmatism may cause loss of resolving ability specific to the chronically blurred meridians (*meridional amblyopia*). Most ophthalmologists recommend correction for eyes with more than 2.00–3.00 D of cylinder.

### **Visual Deprivation Amblyopia**

The least common form of amblyopia, but the most severe and difficult to treat, is visual deprivation amblyopia (also known as *stimulus deprivation amblyopia*, *deprivation amblyopia*, *visual stimulus deprivation amblyopia*, and *form-vision deprivation amblyopia*), which is due to an eye abnormality that obstructs the visual axis or otherwise interferes with central vision. The most common cause is congenital or early-acquired cataract; other causes include blepharoptosis, periocular lesions obstructing the visual axis, corneal opacities, and vitreous hemorrhage. Visual deprivation amblyopia develops faster, and is deeper, than strabismic or anisometropic amblyopia. Unilateral visual deprivation tends to cause vision deficits in the affected eye that are more severe than the bilateral amblyopic deficits produced by bilateral deprivation of the same degree because interocular competition adds to the direct impact of image degradation (see Chapter 5). Even in bilateral cases, visual acuity can be 20/200 or worse if not treated early.

In children younger than 6 years, dense cataracts occupying the central 3 mm or more of the lens can cause severe visual deprivation amblyopia. Similar lens opacities acquired after age 6 years are generally less harmful. Small anterior polar cataracts, around which retinoscopy can be readily performed, and lamellar cataracts, through which a reasonably good view of the fundus can be obtained, may cause mild to moderate amblyopia or have no effect on visual development. Unilateral anterior polar cataracts, however, are associated with anisometropia and subtle optical distortion of the surrounding clear portion of the lens, which may cause anisometropic and/or mild visual deprivation amblyopia.

*Reverse amblyopia* (occlusion amblyopia) is a form of visual deprivation amblyopia that can develop in the initially dominant eye if it is patched excessively during treatment

of amblyopia in the other eye. See the section “Reverse amblyopia and new strabismus” for further discussion.

## Detection and Screening

---

Amblyopia is preventable or reversible with timely detection and intervention. Risk factors for amblyopia include strabismus, anisometropia, isoametropia, and visual deprivation (eg, from ocular media opacities). Regular childhood screening through primary care or community-based programs facilitates early detection of amblyopia and amblyopia risk factors. Screening techniques include direct visual acuity measurement and testing for risk factors. Corneal light reflex tests and cover testing detect strabismus; the Brückner test (see Chapter 7) can reveal media opacities, strabismus, anisometropia, and isoametropia. Instrument-based vision screening is effective in preschool-aged and younger children: portable autorefractors identify refractive errors, while photoscreening devices detect strabismus, refractive errors, and abnormal red reflexes.

Donahue SP, Baker CN; Committee on Practice and Ambulatory Medicine, Section on Ophthalmology, American Academy of Pediatrics; American Association of Certified Orthoptists; American Association for Pediatric Ophthalmology and Strabismus; American Academy of Ophthalmology. Procedures for the evaluation of the visual system by pediatricians. *Pediatrics*. 2016;137(1):e20153597. doi: 10.1542/peds.2015-3597.

## Evaluation

---

Amblyopia is diagnosed when a patient has a condition known to cause amblyopia and has decreased best-corrected visual acuity that cannot be explained by other diseases of the eye or visual pathways. Vision characteristics alone cannot differentiate amblyopia from other forms of vision loss. The crowding phenomenon, for example, is typical of amblyopia but not pathognomonic or uniformly demonstrable. Subtle afferent pupillary defects may occur in severe amblyopia, but only rarely. Amblyopia sometimes coexists with vision loss that is directly caused by an uncorrectable structural abnormality of the eye such as optic nerve hypoplasia or coloboma. If amblyopia is suspected in such a case, it is appropriate to undertake a trial of amblyopia treatment. Improvement in vision confirms that amblyopia was indeed present.

Multiple assessments of visual acuity are sometimes required to determine the presence and severity of amblyopia. (Assessment of visual acuity is discussed in Chapter 1.) In some cases, the clinician may assume that amblyopia is present and initiate treatment before decreased vision can be demonstrated. For example, if a clinician does not have access to a grating acuity test such as Teller Acuity Cards II, occlusion therapy may be started in a preverbal child in the presence of a high degree of anisometropia or shortly after surgery for a unilateral cataract.

When determining the severity of amblyopia in a young patient, the clinician should remember that both false-positive and false-negative errors may occur with fixation preference testing; a strabismic child may show a strong fixation preference despite having equal visual acuity, whereas an anisometric child may alternate fixation despite

having significant amblyopia. In addition, the young child's brief attention span frequently results in grating or recognition acuity measurements that fall short of the true limits of acuity; these measurements can mimic those of bilateral amblyopia or mask or falsely suggest a significant interocular difference. Finally, because test-retest variability can be up to a full line of letters in children, it is important for the clinician to evaluate trends when assessing response to treatment.

## Treatment

---

Treatment of amblyopia involves the following steps:

1. Eliminate (if needed) any obstruction of the visual axis, such as a cataract.
2. Correct any significant refractive error.
3. Promote use of the amblyopic eye.

### Cataract Removal

Cataracts capable of producing dense amblyopia require timely surgery. Removal of unilateral, visually significant congenital lens opacities within the first 6 weeks of life is necessary for optimal recovery of vision. In young children, significant cataracts with uncertain time of onset also deserve prompt and aggressive treatment if recent development is at least a possibility. For bilateral, dense congenital cataracts, surgery is recommended within the first 10 weeks of life. However, small partial cataracts may sometimes be managed nonsurgically; pharmacologic pupillary dilation may permit good vision despite a central opacity (see also the section Visual Deprivation Amblyopia, earlier in the chapter). Childhood cataract is discussed further in Chapter 23.

### Refractive Correction

Refractive correction plays a key role in the treatment of all types of amblyopia, not just refractive amblyopia. Anisometropic, isoametropic, and even strabismic amblyopia may improve or resolve with refractive correction alone. Many ophthalmologists thus initiate amblyopia treatment with refractive correction, adding occlusion or pharmacologic or optical treatment later if necessary (see the following sections). Refractive correction for aphakia following cataract surgery in childhood is initiated promptly to avoid prolonging visual deprivation. For patients with high refractive error that is amblyogenic who will not or cannot wear glasses or contact lenses, refractive surgery may be an alternative in select cases.

In general, refractive correction in amblyopia should be based on the cycloplegic refraction. Often, full hyperopic correction is necessary to treat coexisting accommodative esotropia (see Chapter 8). Furthermore, because an amblyopic eye tends to have an impaired ability to control accommodation, it cannot reliably compensate for uncorrected hyperopia as would a child's normal eye. Thus, children with unilateral or bilateral amblyopia may need full or nearly full correction of their hyperopia during amblyopia treatment even if they do not have accommodative esotropia. Also, by ensuring clear distance vision in the fellow eye even under cycloplegia, full hyperopic correction may reduce the

risk of reverse amblyopia, which can result from pharmacologic treatment with atropine (see the section “Reverse amblyopia and new strabismus”). Sometimes, however, symmetric reductions in plus-lens power help foster acceptance of glasses.

Writing Committee for the Pediatric Eye Disease Investigator Group; Cotter SA, Foster NC, Holmes JM, et al. Optical treatment of strabismic and combined strabismic-anisometropic amblyopia. *Ophthalmology*. 2012;119(1):150–158.

## Occlusion Therapy

Occlusion therapy (patching) is commonly used to treat unilateral amblyopia. The sound eye is covered, obligating the child to use the amblyopic eye. Adhesive patches are usually employed, but spectacle-mounted occluders or opaque contact lenses are alternatives if skin irritation or inadequate adhesion is a problem. With spectacle-mounted occluders, close supervision is necessary to ensure that the patient does not peek around the occluder.

*Full-time occlusion*, defined as occlusion during all waking hours, can cause reverse amblyopia and strabismus (see the section Complications and Challenges of Therapy). For severe amblyopia, *part-time occlusion* of 6 hours per day achieves results similar to those obtained with prescribed full-time occlusion. The relative duration of patch-on and patch-off intervals should reflect the degree of amblyopia. For severe deficits (visual acuity of 20/125–20/400), 6 hours per day is preferred. For moderate deficits (visual acuity of 20/100 or better), 2 hours of daily patching may be effective. It is not necessary for the patient to engage in specific activities (eg, near work) while patched.

Follow-up timing depends on patient age and treatment intensity. Part-time treatment permits less frequent follow-up; reexamination 2–3 months after initiating treatment is typical. Subsequent visits can be at longer intervals, based on early response.

The desired endpoint of therapy for unilateral amblyopia is free alternation of fixation and/or linear recognition acuity that differs by no more than 1 line between the 2 eyes. The time required to complete treatment depends on amblyopia severity, treatment intensity, and patient adherence and age. More severe amblyopia and older children require more intensive or longer treatment. Occlusion during infancy may reverse substantial strabismic amblyopia in less than 1 month. In contrast, an older child who wears a patch only after school and on weekends may require several months to overcome a moderate deficit.

Adherence to occlusion therapy for amblyopia declines with increasing age. However, studies in older children and teenagers with strabismic or anisometropic amblyopia show that treatment can still be beneficial beyond the first decade of life. This is especially true in children who have not previously undergone treatment.

## Pharmacologic or Optical Treatment

Alternatives to occlusion therapy involve pharmacologic and/or optical degradation of the better eye’s vision such that it becomes temporarily inferior to the amblyopic eye’s vision, promoting use of the amblyopic eye. For patients with orthotropia or small-angle strabismus, an advantage of these treatments over occlusion therapy is that they allow a degree of binocularity, which is particularly beneficial in children with latent nystagmus.

Pharmacologic treatment of moderate amblyopia (visual acuity of 20/100 or better) is as effective as patching and may also be successful in more severe amblyopia (visual acuity of 20/125–20/400), particularly in younger children. A cycloplegic agent (usually atropine sulfate solution, 1%) is administered to the better-seeing eye so that it is unable to accommodate. Vision in the better eye is thus blurred at near and, if hyperopia is undercorrected, also for distance viewing. Atropine may be administered daily, but weekend administration is as effective for milder amblyopia. Regular follow-up is important to monitor for reverse amblyopia (see the section Complications and Challenges of Therapy).

Pharmacologic treatment is difficult for the child to thwart. It may not work well for myopic patients, however, because clear near vision persists in the dominant eye despite cycloplegia if the distance correction is not worn. In some children, attempts to accommodate with the dominant eye in the face of cycloplegia can increase accommodative convergence, worsening any underlying esotropia during treatment. Parents and caregivers should be counseled regarding the adverse effects of atropine, including light sensitivity, and potential systemic toxicity, the symptoms of which include fever, tachycardia, delirium, and dry mouth and skin (see Chapter 1).

Optical treatment involves the prescription of excessive plus lenses (fogging) or diffusing filters for the sound eye. This form of treatment avoids potential pharmacologic adverse effects and may be able to induce greater blur than cycloplegic agents. If the child wears glasses, a translucent filter, such as Scotch Magic Tape (3M, St Paul, MN) or a Bangerter foil (Ryser Optik AG, St Gallen, Switzerland), can be applied to the spectacle lens. Optical treatment may be more acceptable than occlusion therapy to many children and their parents, but patients must be closely monitored to ensure proper use (no peeking) of spectacle-borne devices.

## Binocular Treatment

Binocular amblyopia treatments have recently shown some promise in amblyopic children with orthotropia or small-angle strabismus. In these treatments, the child engages in active or passive visual tasks that require simultaneous perception and are performed on an electronic device under dichoptic viewing conditions. The relative salience of amblyopic and fellow eye input can be adjusted over the course of treatment.

Birch EE, Li SL, Jost RM, et al. Binocular iPad treatment for amblyopia in preschool children. *J AAPOS*. 2015;19(1):6–11.

Holmes JM, Manh VM, Lazar EL, et al; for the Pediatric Eye Disease Investigator Group. Effect of a binocular iPad game vs part-time patching in children aged 5 to 12 years with amblyopia: a randomized clinical trial. *JAMA Ophthalmol*. 2016;134(12):1391–1400.

## Complications and Challenges of Therapy

### **Reverse amblyopia and new strabismus**

Both occlusion therapy and pharmacologic treatment carry a risk of overtreatment, which can result in reverse amblyopia in the sound eye. Strabismus can also develop or worsen with amblyopia treatment (although strabismus can also improve with amblyopia treatment).



Full-time occlusion carries the greatest risk of reverse amblyopia and thus requires close monitoring. Consequently, most ophthalmologists do not use full-time occlusion in younger children. Children with binocular fusion, especially, may benefit from time spent viewing binocularly. The family of a strabismic child should be instructed to watch for a reversal of fixation preference with full-time occlusion and to report its occurrence promptly. Usually, iatrogenic reverse amblyopia can be treated successfully by judicious patching of the formerly worse-seeing, now better-seeing, eye. Sometimes, simply stopping treatment leads to equalization of vision.

During pharmacologic treatment, the risk of reverse amblyopia is greatest if daily treatment is coupled with undercorrection of hyperopic refractive error in the sound eye undergoing cycloplegia (see the section Refractive Correction, earlier in the chapter).

### ***Poor adherence***

Lack of adherence to the therapeutic regimen is a common problem that can prolong the treatment period or lead to outright failure. If difficulties derive from a particular treatment method, the clinician should seek a suitable alternative. Adhesive and cloth patches may not be covered by medical insurance in the United States; if treatment cost is a burden, pharmacologic treatment may facilitate adherence. If the skin becomes irritated from patch adhesives, switching to a different brand or applying skin lotion after patching may help. A barrier application of tincture of benzoin can protect the skin from contact with adhesive and help when patches do not adhere because of perspiration; however, it can make patch removal more traumatic.

Families who seem to lack sufficient motivation should be counseled concerning the importance of the therapy and the need for consistency in carrying it out. They can be reassured that once an appropriate routine is established, the daily effort required is likely to diminish, especially if the amblyopia improves. For an older child, it can also be helpful for the physician to explain and emphasize the importance of treatment adherence directly to the child in an age-appropriate manner. Further, it is important for the family to understand that amblyopia treatment is performed primarily to improve vision rather than ocular alignment (even though ocular alignment may sometimes improve) and, conversely, that improving ocular alignment (with surgery or glasses) does not obviate the need for treatment of associated amblyopia.

Adherence to a patching regimen in older children can be improved by creating goals and offering rewards or by linking patching to play activities (eg, decorating the patch or patching while the child plays a video game). For infants and toddlers, adherence to a patching regimen depends greatly on parental engagement and commitment. Arm splints and mittens are sometimes used as a last resort.

### ***Unresponsiveness***

Sometimes even conscientious application of an appropriate therapeutic program fails to improve vision at all or beyond a certain level. Complete or partial unresponsiveness to treatment occasionally affects younger children but more often occurs in patients older than 5 years. When there is a significant deviation from the expected treatment response despite good adherence, reexamination may reveal subtle optic nerve or retinal anomalies. Neuroimaging may be considered if an occult compressive optic neuropathy is suspected.

In a prognostically unfavorable situation, decisions about treatment should take into account the patient's and parents' wishes. Amblyopia is not always fully correctable, even in younger children. Primary therapy may reasonably be terminated if there is a lack of demonstrable progress over 3–6 months despite good treatment adherence. Progress or lack thereof may be harder to quantify in preverbal children, however, so longer treatment is appropriate in this setting.

### **Recurrence**

When amblyopia treatment is discontinued after complete or partial improvement of vision, up to one-third of patients show some degree of recurrence. Reducing the occlusion regimen (to 1–2 hours per day) or the frequency of pharmacologic treatment for a few months before cessation is associated with a decreased incidence of recurrence, although no randomized trial has compared tapered and nontapered cessation. If recurrence occurs, vision can usually be improved again with resumption of therapy. In a study of children who were between 7 and 12 years of age when treated for amblyopia, the vision improvements that occurred seemed to be mostly sustained after cessation of treatment other than spectacles. Younger patients may require periodic monitoring until vision is stable with spectacle treatment alone (eg, until age 8–10 years). With stable vision, 12-month examination intervals are acceptable.

Hertle RW, Scheiman MM, Beck RW, et al; Pediatric Eye Disease Investigator Group. Stability of visual acuity improvement following discontinuation of amblyopia treatment in children aged 7 to 12 years. *Arch Ophthalmol*. 2007;125(5):655–659.



## Diagnostic Evaluation of Strabismus and Torticollis



*This chapter includes related videos, which can be accessed by scanning the QR codes provided in the text or going to [www.aaopt.org/bcscvideo\\_section06](http://www.aaopt.org/bcscvideo_section06).*

### Obtaining a History in Cases of Strabismus or Torticollis

Both strabismus and torticollis are common presenting complaints to the pediatric ophthalmologist. Torticollis is an abnormal head position (AHP), such as a head turn or tilt. Although torticollis can be caused by a wide variety of ocular and nonocular conditions (discussed later in the chapter) and is not always associated with strabismus, it is a common presenting sign of strabismus. Thus, there is broad overlap in the diagnostic assessment of strabismus and torticollis.

Key questions for the clinician to ask when obtaining a strabismus or torticollis history include the following:

- At what age did the deviation or AHP appear? (Reviewing old photographs may be helpful.)
- Did onset coincide with trauma or illness?
- Is the deviation or AHP constant or intermittent?
- Is it present for distance or near vision or both?
- Is it present only when the patient is inattentive or fatigued?
- Is it associated with double vision or eyestrain?
- If a deviation is noted, is it present in all positions of gaze?
- If a deviation is noted, is it unilateral or alternating?
- Does the patient close 1 eye (squint)?
- Is there a history of other ocular disease or ocular surgery?

The clinician should review previous treatment, including amblyopia therapy, spectacle correction, and eye muscle surgery. The initial assessment should also include observation of the patient's habitual head position, head movement, and attentiveness. See Chapter 1 for a general discussion of examination of children.

## Assessment of Ocular Alignment

### Diagnostic Positions of Gaze

The *diagnostic positions of gaze* are a core set of 9 different gaze positions used in the comprehensive assessment of ocular alignment. They consist of

- *primary position*: The eyes fixate straight ahead on an object at infinity, which, for practical purposes, is considered to be 6 m, or 20 ft. For this position, the head should be straight.
- *6 cardinal positions*: Two muscles (1 in each eye) are the prime movers of their respective eyes into each of these positions of gaze (see Chapter 4).
- *straight up and straight down*: These do not isolate any single muscle, because the actions of both oblique and vertical rectus muscles affect elevation and depression from primary position; see Chapter 4.

For patients with vertical strabismus, the diagnostic positions of gaze also include forced head tilt toward the right shoulder and the left shoulder (see the section The 3-Step Test, later in this chapter). Near fixation (usually 33 cm in the primary position) and reading position (depending on the patient's symptoms) complete the list of clinically important test positions.

Tests for measuring ocular alignment can be grouped into 3 basic types: cover tests, corneal light reflex tests, and subjective tests.

### Cover Tests

Foveal fixation in each eye, patient attention and cooperation, and the ability to make eye movements are all necessary for cover testing. If the patient is unable to maintain constant fixation on an accommodative target, cover tests should not be used. There are 3 main types of cover tests: cover-uncover, alternate cover, and simultaneous prism and cover. All can be performed at distance or near fixation.

The monocular *cover-uncover test* is the most important test for detecting manifest strabismus and for distinguishing a heterophoria from a heterotropia (Fig 7-1; Video 7-1). As the target is viewed, one eye is covered and the opposite eye observed for any movement, which would indicate a heterotropia. The occluder is then removed. If there is no movement of the noncovered eye when the occluder is introduced, movement of the *covered* eye in one direction with application of the occluder and then in the opposite direction (a fusional movement) with removal of the occluder would indicate a heterophoria. If the patient has a heterophoria, the eyes will be straight before and after the cover-uncover test; the deviation appears during the test because of interruption of binocular vision. A patient with a heterotropia, however, starts with a deviated eye and, after testing, ends with the same eye or—in the case of an *alternating heterotropia*—the opposite eye deviated. In patients with intermittent heterotropia, the eyes may be straight before testing but become dissociated after occlusion.

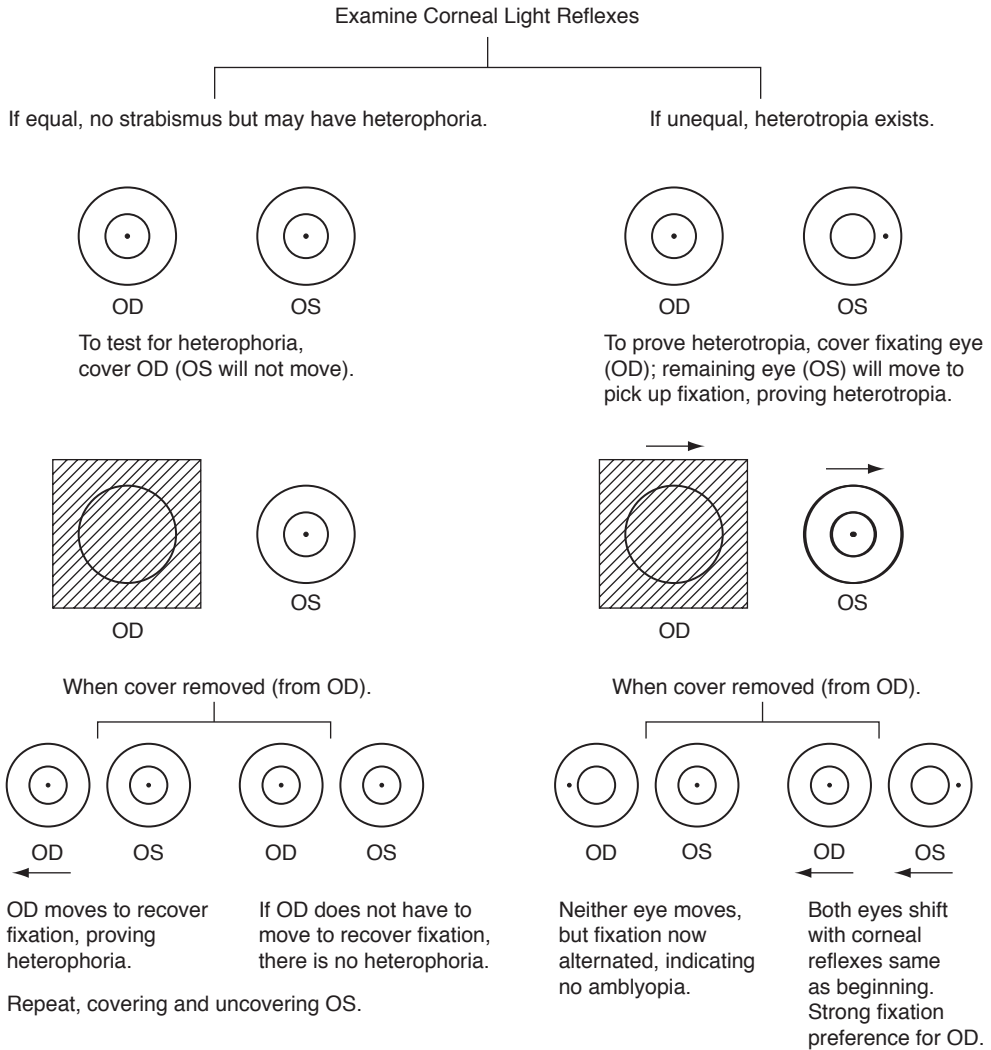


#### VIDEO 7-1 The cover-uncover test.

Animation developed by Steven M. Archer, MD, and Kristina Tarczy-Hornoch, MD, DPhil.

Access all Section 6 videos at [www.aao.org/bcscvideo\\_section06](http://www.aao.org/bcscvideo_section06).





**Figure 7-1** The monocular cover-uncover test.

The *alternate cover test* (Fig 7-2A; Video 7-2) detects both latent (heterophoria) and manifest (heterotropia) deviations. As the patient views the target, the examiner moves the occluder from one eye to the other, observing the direction of movement of each eye when it is uncovered. Because this test disrupts binocular fusion, dissociating the eyes, it does not distinguish between latent and manifest components. Testing should be performed at both distance and near fixation.

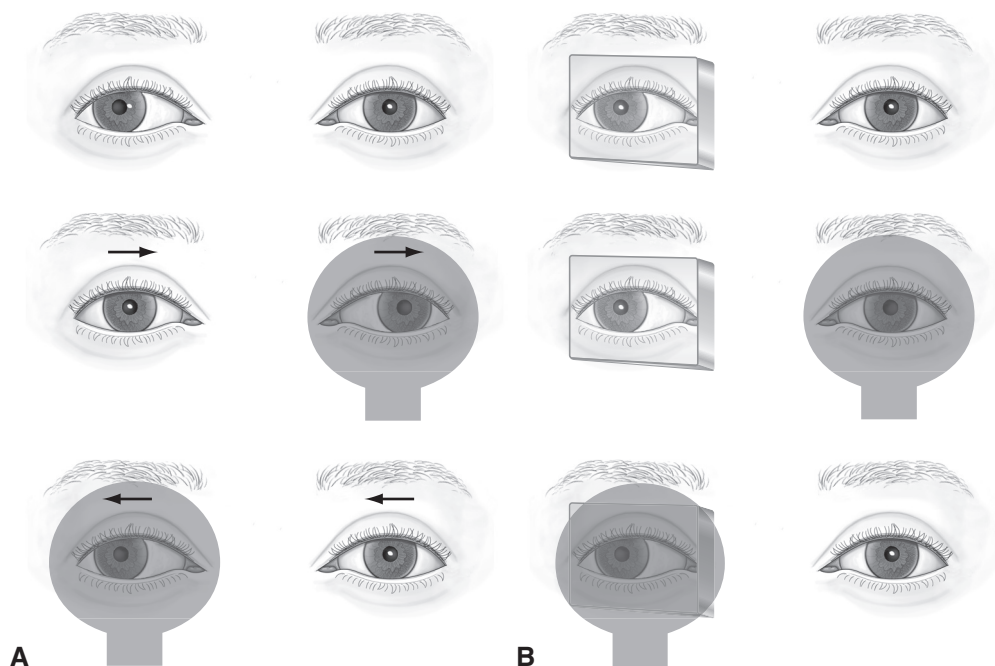


**VIDEO 7-2** The alternate cover test.

Animation developed by Steven M. Archer, MD, and Kristina Tarczy-Hornoch, MD, DPhil.



In the *prism alternate cover test*, prisms of varying amount are held over one eye or both eyes during alternate cover testing; the amount of prism that neutralizes the



**Figure 7-2** **A**, The alternate cover test. *Top*: Exotropia, left eye fixating. *Middle and bottom*: Both eyes move each time the cover alternates from one eye to the other. **B**, The prism alternate cover test. *Top*: The exotropia is neutralized with a prism of the correct power. *Middle and bottom*: The eyes do not move as the cover alternates from one eye to the other. (Illustration developed by Steven M. Archer, MD; original illustration by Mark Miller.)

deviation, such that eye movement is no longer seen as the occluder is moved from one eye to the other, represents the magnitude of the deviation (Fig 7-2B; Video 7-3). It may be necessary to use both horizontal and vertical prisms. This test measures the total deviation (heterotropia plus heterophoria).



**VIDEO 7-3** The prism alternate cover test.

Animation developed by Steven M. Archer, MD, and Kristina Tarczy-Hornoch, MD, DPhil.



Two horizontal or 2 vertical prisms should not be stacked; such stacking can induce significant measurement errors. Deviations larger than the largest-available single prism are best measured by placing 1 prism in front of each eye, although this is not perfectly additive either. A horizontal prism and a vertical prism may be stacked over the same eye, however. Plastic prisms should always be held with the back surface (closest to the patient) in the patient's frontal plane. If the head is tilted, the prisms must be tilted accordingly. With incomitant (parietic or restrictive) strabismus, the primary and secondary deviations are measured by holding the prism over the parietic or restricted eye and the sound eye, respectively.

The *simultaneous prism and cover test* (Video 7-4) measures the manifest deviation during binocular viewing (only the heterotropia). The test is performed by placing a prism in front of the deviating eye and covering the fixating eye at the same time. The test is

repeated using increasing prism powers until the deviated eye no longer shifts. This test has special application in monofixation syndrome. Under binocular conditions, patients with this syndrome often use peripheral fusion to exert some control over their deviation. The heterotropia alone is smaller than the total deviation (heterotropia plus heterophoria) measured by the prism alternate cover test. The simultaneous prism and cover test provides the best indication of the size of the deviation under real-life conditions.



**VIDEO 7-4** The simultaneous prism and cover test.

Animation developed by Steven M. Archer, MD, and Kristina Tarczy-Hornoch, MD, DPhil.



Thompson JT, Guyton DL. Ophthalmic prisms. Measurement errors and how to minimize them. *Ophthalmology*. 1983;90(3):204–210.

### Corneal Light Reflex and Red Reflex Tests

Corneal light reflex tests assess eye alignment using the location of the first Purkinje image, the image formed from reflection of a fixation light by the anterior corneal surface, which acts as a curved mirror. The Hirschberg and Krimsky tests are the main tests of this type. Though not as accurate as cover tests, they are useful for uncooperative patients and those with poor or eccentric fixation, in whom cover testing is not possible.

The *Hirschberg test* is based on the correlation between the decentration of the corneal light reflection and the ocular deviation. The ratio is about 22 prism diopters ( $\Delta$ ) per millimeter of decentration but can vary between 12 $\Delta$  and 27 $\Delta$  from one individual to the next. With an uncooperative child, it is not always possible to accurately measure the light reflex displacement, so gross estimates of the deviation are often used (although these are highly dependent on pupil size): 30 $\Delta$  if the reflex is at the pupil margin, 60 $\Delta$  if the reflex is in the middle of the iris, and 90 $\Delta$  if the reflex is at the limbus (Fig 7-3).

The *Krimsky test* uses prisms to quantify the decentration of the corneal reflections from a handheld torch. This is done by holding a prism over either eye and adjusting the prism power until the corneal reflection is positioned symmetrically in each eye to approximate the near deviation (Fig 7-4; Video 7-5).



**VIDEO 7-5** The Krimsky test.

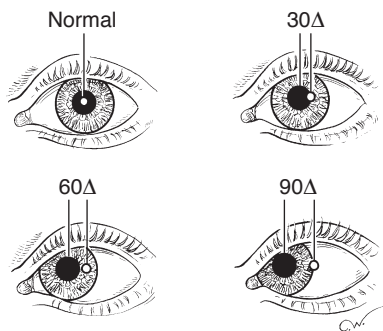
Animation developed by Steven M. Archer, MD, and Kristina Tarczy-Hornoch, MD, DPhil.



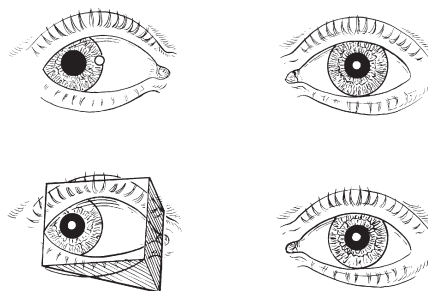
The *angle kappa*, the angle between the visual axis and the anatomical pupillary axis of the eye (Fig 7-5), can affect corneal light reflex measurements. The fovea is usually slightly temporal to the pupillary axis, making the corneal light reflection slightly nasal to the center of the cornea. This is termed *positive angle kappa*. A large positive angle kappa (eg, from temporal dragging of the macula in cicatricial retinopathy of prematurity) can simulate exotropia. If the position of the fovea is nasal to the pupillary axis, the corneal light reflection will be temporal to the center of the cornea. This *negative angle kappa* simulates esotropia. The angle kappa does not affect any of the cover tests.

In the *Brückner test*, the direct ophthalmoscope is used to obtain a red reflex simultaneously in both eyes. Foveation of the ophthalmoscope filament dims the red reflex. If strabismus is present, the deviated eye will have a lighter and brighter reflex than the

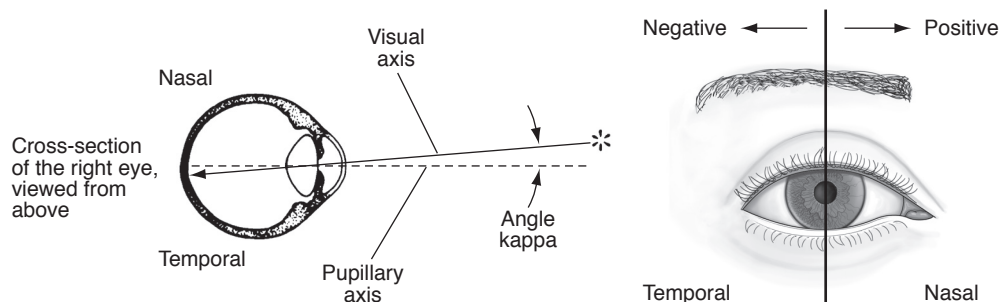




**Figure 7-3** Hirschberg test, left eye. The extent to which the corneal light reflex is displaced from the center of an average-sized pupil provides an approximation of the angular size of the deviation (here, a left esotropia).  $\Delta$  = prism diopter. (Modified with permission from Simon JW, Calhoun JH. *A Child's Eyes: A Guide to Pediatric Primary Care*. Gainesville, FL: Triad Publishing Company; 1997:72.)



**Figure 7-4** Krinsky test. The magnitude of the right exotropia is estimated by the power of the prism required to produce symmetric pupillary reflexes, as shown at bottom. (Reprinted with permission from Simon JW, Calhoun JH. *A Child's Eyes: A Guide to Pediatric Primary Care*. Gainesville, FL: Triad Publishing Company; 1997:72.)



**Figure 7-5** Angle kappa. A positive angle kappa (in which the corneal light reflex is nasally displaced; shown in cross-section for the right eye), if large enough, simulates exotropia, whereas a negative angle (in which the light reflex is temporally displaced) simulates esotropia. (Modified with permission from Parks MM. *Ocular Motility and Strabismus*. Hagerstown, MD: Harper & Row; 1975.)

fixating eye. Media opacities and refractive errors can also cause unequal red reflexes. Simultaneously, the positions of the corneal light reflexes can be assessed. This test is used mainly by primary care practitioners to screen for vision disorders.

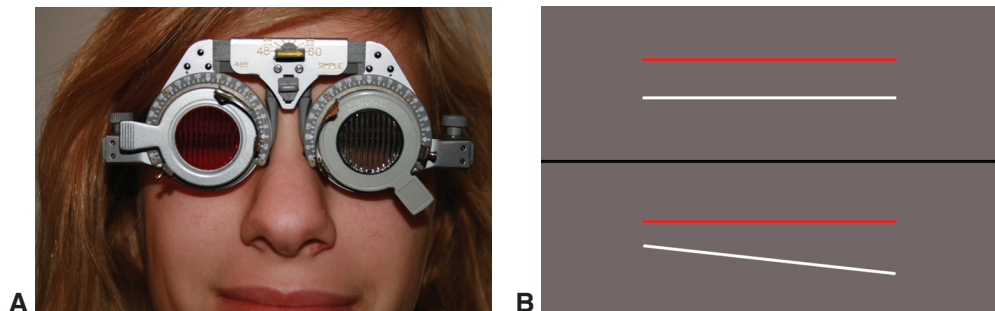
### Subjective Tests of Ocular Alignment

The *Maddox rod test* assesses ocular alignment using the patient's perception of the relative position of the images seen by each eye. For the eye viewing through the Maddox rod, a series of parallel cylinders convert a point source of light into a line image perpendicular to the cylinders. Like alternate cover testing, the test is dissociating and precludes fusion; thus, heterophorias and heterotropias cannot be differentiated. The test cannot assess alignment in patients with anomalous retinal correspondence (ARC) or suppression.

To test for horizontal deviations, the Maddox rod is held in front of 1 eye (eg, right eye) so that the cylinders are horizontal. The patient, fixating on a point source of light, sees a vertical line with the right eye and the point source of light with the left. Assuming normal retinal correspondence (NRC), in orthophoria, the point superimposes on the line; in esodeviations, the light is seen to the left of the line; and in exodeviations, the light is to the right of the line (see the section The Red-Glass (Diplopia) Test). The deviation is measured by finding the prism power that superimposes the point source on the line. Note, however, that unlike in cover testing with an accommodative target, accommodative convergence is not controlled by this technique. Vertical deviations can be assessed by orienting the cylinders vertically.

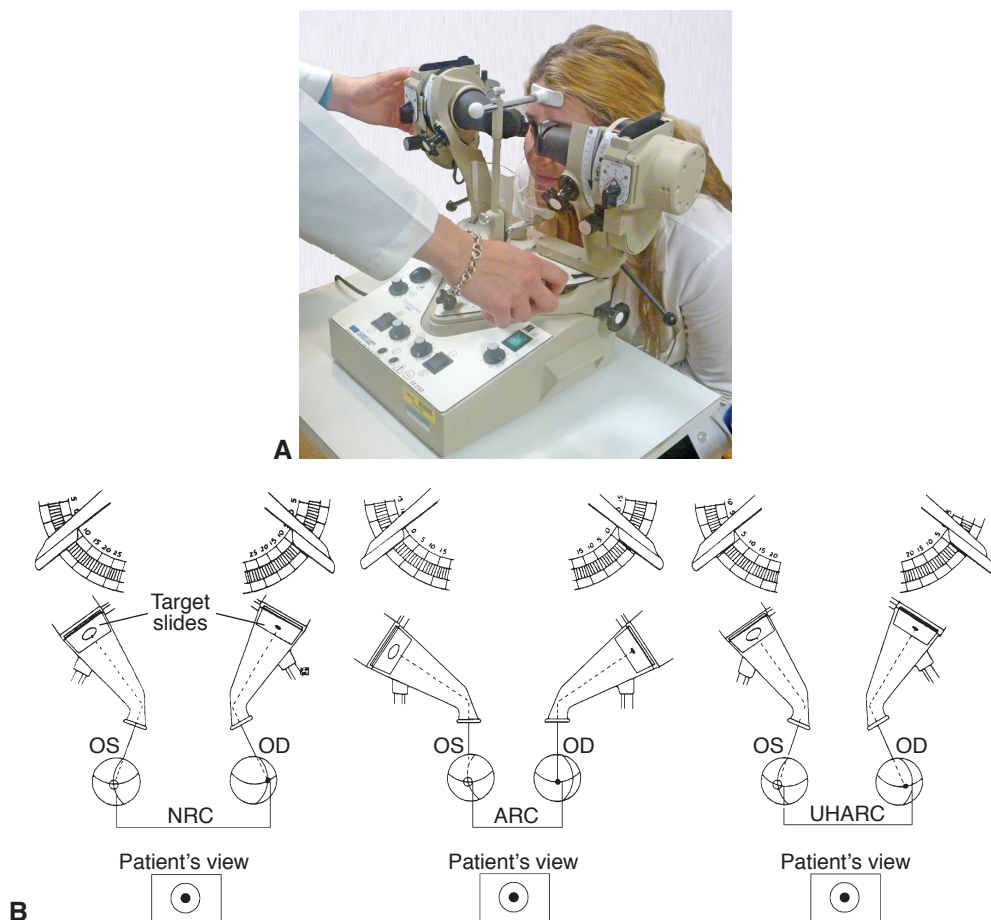
The *double Maddox rod test* (Fig 7-6) is used to measure cyclodeviations. Two Maddox rods are placed in a trial frame or phoropter and aligned vertically so that the patient sees 2 horizontal lines. A small vertical prism may be introduced to help separate the lines. The rod axes are rotated until the patient sees parallel lines. The angle of rotation indicates the magnitude and direction (intorsion or extorsion) of cyclodeviation. Traditionally, a red Maddox rod and a clear one were paired, but this was thought to bias the patient's localization of the cyclodeviation toward the eye with the red rod. Using the same color bilaterally avoids this bias. In congenital conditions such as congenital superior oblique palsy, the patient may not subjectively appreciate torsion or indicate any torsion with the double Maddox rod test. In these cases, seeing fundus torsion on indirect ophthalmoscopy can aid diagnosis.

The *Lancaster red-green test* (and variations such as the Hess, Harms, and Lees screen tests) is useful for assessing ocular alignment in complicated incomitant strabismus in cooperative patients with NRC and no suppression (see Chapter 5), such as adults with acquired strabismus. Reversible red-green goggles, red-slit and green-slit projectors, and a grid projected or marked on a screen or wall are used in the test. With the red filter in front of the patient's right eye, the examiner projects a red slit onto the grid; the patient places the green slit so that it appears superimposed on the red slit. The relative positions of the streaks are recorded. The test is repeated for the 9 diagnostic positions of gaze, and the goggles are reversed to record deviations with the fellow eye fixating.



**Figure 7-6** Double Maddox rod test. **A**, The cylinders are aligned vertically, such that a patient with normal binocular vision sees 2 superimposed horizontal lines. **B**, *Top*: View seen by a patient with a small left hypertropia and no torsion. *Bottom*: View seen by a patient with a small left hypertropia and extorsion. (Part A courtesy of Scott Olitsky, MD; part B courtesy of Steven M. Archer, MD.)

The *major amblyscope* (Fig 7-7A) can be used to measure ocular alignment both objectively and subjectively. It may be particularly useful in adult strabismus, as it allows neutralization of torsional diplopia to assess fusional responses and can help characterize ARC. Separate, dissimilar targets are presented to each eye simultaneously, and the amblyscope is adjusted until the patient sees the images superimposed. If the patient has NRC, the horizontal, vertical, and torsional deviations can be read directly from the calibrated scale of the amblyscope (Fig 7-7B). See also the section Amblyscope Testing, later in this chapter.



**Figure 7-7** **A**, The major amblyscope. Targets can be placed in each arm of the device to be presented separately to each eye. The arms can then be moved to compensate for ocular misalignment. **B**, Testing with a major amblyscope for retinal correspondence in a patient with  $20\Delta$  of esotropia. NRC = normal retinal correspondence, with a fused percept when the angle of strabismus is fully compensated, presenting targets to the fovea of each eye; ARC = anomalous retinal correspondence (harmonious), with a fused percept in the absence of any compensation for the angle of strabismus, with one eye viewing the target foveally and the other extrafoveally; UHARC = unharmonious anomalous retinal correspondence, with a fused percept when the angle of strabismus is partially compensated. (Part A courtesy of Steven M. Archer, MD; part B modified with permission from von Noorden GK, Campos EC. *Binocular Vision and Ocular Motility: Theory and Management of Strabismus*. 6th ed. St Louis: Mosby; 2002:229.)

## Assessment of Eye Movements

### Ocular Rotations

Generally, versions are tested first; both eyes' movements into the 9 diagnostic positions of gaze are assessed. Limitations of movement and asymmetric excursion of the 2 eyes (such as "overaction") are noted. Spinning the child or the doll's head maneuver may be used to elicit vestibular-stimulated eye movements. If versions are not full, the examiner should test duction movements for each eye separately (Video 7-6). BCSC Section 5, *Neuro-Ophthalmology*, also discusses testing of the ocular motility system.



**VIDEO 7-6** Versions and ductions.



### Convergence

To determine the *near point of convergence*, the patient fixates on an object in the midsagittal plane, and the object, positioned initially at 40 cm, is moved toward the patient until 1 eye loses fixation and turns out. The distance from the object to the patient is then measured, giving the *near point of convergence*, which is normally 8–10 cm or less. The eye that maintains fixation is considered the dominant eye. This test does not distinguish between fusional convergence and accommodative convergence.

### **Accommodative convergence/accommodation ratio**

The *accommodative convergence/accommodation (AC/A) ratio* is defined as the amount of convergence (in prism diopters) per unit change in accommodation (in diopters). There are 2 methods of clinical measurement (see also BCSC Section 3, *Clinical Optics*):

1. The *gradient method* derives the AC/A ratio by stimulating a change in accommodation using lenses, and dividing the resulting change in deviation (in prism diopters) by the change in lens power. An accommodative target must be used, and the working distance (typically 33 cm or 6 m) is held constant. Plus or minus lenses (eg, +1.00, +2.00, +3.00, -1.00, -2.00, -3.00) are used to vary the accommodative requirement (plus lenses at distance can be used only with uncorrected hyperopia). This method measures the *stimulus AC/A ratio*, which may differ from the *response AC/A ratio*. The latter can be determined only by simultaneously measuring the refractive state of the eyes to quantify the change in accommodation actually produced.
2. In the *heterophoria method*, the measurements of the distance and near deviations are used, along with the interpupillary distance, to calculate the AC/A ratio. Comparing distance and near deviations gives a rough clinical estimate. In accommodative esotropia, a near deviation exceeding distance deviation by 10Δ or more is considered to represent a high AC/A ratio. Note, however, that in intermittent exotropia, the near deviation may be smaller than the distance deviation despite a normal AC/A ratio, because of *tenacious proximal fusion* (see Chapter 9).

## Fusional Vergence

Vergences are movements of the 2 eyes in opposite directions (see Chapter 4). Fusional vergences are motor responses that eliminate horizontal, vertical, and, to a limited degree, torsional image disparity.

- *Fusional convergence* eliminates bitemporal retinal image disparity and controls an exophoria.
- *Fusional divergence* eliminates binasal retinal image disparity and controls an esophoria.
- *Vertical fusional vergence* controls a hyperphoria or hypophoria.
- *Torsional fusional vergence* is cyclovergence that controls an incyclophoria or excyclophoria.

Fusional vergence can be measured using an amblyoscope, rotary prism, or bar prism; the prism power is gradually increased until diplopia occurs. Accommodation must be controlled during fusional vergence testing. Normal fusional vergence amplitudes are listed in Table 7-1. Fusional vergence can be altered by the following:

- *Compensatory mechanisms*: As a deviation evolves, a larger-than-normal fusional vergence develops. Large fusional vergences are common in compensated, long-standing vertical deviations and exodeviations.
- *Change in vision*: An improvement in vision may facilitate the fusional vergence mechanism and change a symptomatic intermittent deviation to an asymptomatic heterophoria.
- *State of awareness*: Fatigue, illness, or drug or alcohol ingestion may decrease the fusional vergence mechanism, converting a heterophoria to a heterotropia.
- *Orthoptics*: Orthoptic exercises may increase the magnitude of the fusional vergence mechanism (mainly fusional convergence). This treatment works best for near fusional convergence, particularly in convergence insufficiency.
- *Optical stimulation of fusional vergence*: In controlled accommodative esotropia, reducing the strength of the hyperopic or bifocal correction induces an esophoria that stimulates compensatory fusional divergence. In convergence insufficiency, base-out prism stimulates fusional convergence. Similarly, the power of prisms used to control diplopia may be decreased gradually to stimulate compensatory fusional vergence.

**Table 7-1 Average Normal Fusional Vergence Amplitudes in Prism Diopters ( $\Delta$ )**

Testing Distance	Convergence	Divergence	Vertical
6 m	14	6	2.5
25 cm	38	16	2.6

## Forced Duction, Active Force Generation, and Saccadic Velocity

- In the *forced duction test*, the eye is moved into various positions with the use of forceps to detect resistance to passive movement. This is usually done intraoperatively but can be done in clinic with topical anesthesia in cooperative patients.
- In the *active force generation test*, the awake patient is asked to move a topically anesthetized eye while the examiner grasps it with forceps. If the muscle tested is paretic, the examiner feels less-than-normal tension.
- *Saccadic velocity* can be measured with instruments that track and record eye movement (eg, using magnetic search coils or video-based eye tracking). This measurement is useful for distinguishing paresis from restriction. For paretic muscles, saccadic velocity is low throughout the movement, whereas for restricted muscles, the velocity is initially normal but drops rapidly when the eye reaches the limit of its excursion. Clinical observation of saccadic velocity is qualitative: slow, “floating” saccades indicate muscle paresis.

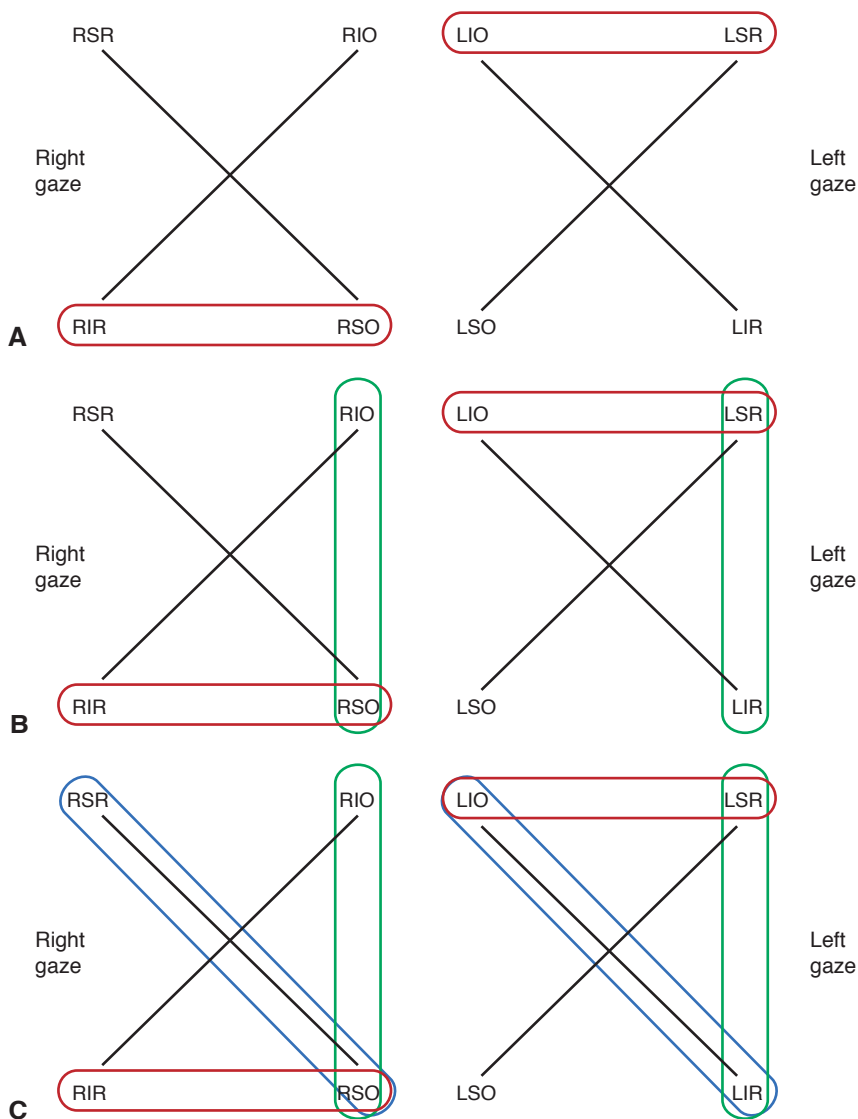
See also BCSC Section 5, *Neuro-Ophthalmology*.

## The 3-Step Test

---

There are 8 cyclovertical extraocular muscles (4 in each eye): the 2 *depressors* of each eye are the *inferior rectus (IR)* and *superior oblique (SO) muscles*; the 2 *elevators* of each eye are the *superior rectus (SR)* and *inferior oblique (IO) muscles*. Cyclovertical (especially superior oblique) muscle weakness often causes vertical deviations. The *3-step test* (also called the *Parks-Bielschowsky 3-step test*) is an algorithm that helps identify a weak cyclovertical muscle. However, it is not always diagnostic, and results can be misleading, especially in patients with 1 of the following: more than 1 paretic muscle, previous strabismus surgery, skew deviation, or restrictions or dissociated vertical deviation (see Chapter 11). The 3-step test is performed as follows (Fig 7-8; see also Chapter 11, Fig 11-4):

- *Step 1*: Determine which eye is higher using the cover-uncover test (see Fig 7-1). Step 1 narrows the number of possible underacting muscles from 8 to 4. In the example shown in Figure 7-8, the right eye is higher than the left eye. This indicates weakness in 1 of the 2 depressors of the right eye (RIR, RSO) or 1 of the 2 elevators of the left eye (LIO, LSR). Draw an oval around these 2 muscle groups (see Fig 7-8A).
- *Step 2*: Determine whether the vertical deviation is greater in right gaze or in left gaze. In the example, the deviation is larger in left gaze. This implicates 1 of the 4 vertically acting muscles used in left gaze. Draw an oval around these (see Fig 7-8B). At the end of step 2, the 2 remaining possible muscles (1 in each eye) are either both intortors or both extortors and are either both superior or both inferior muscles (1 rectus and 1 oblique). In the example shown in Figure 7-8B, the increased left-gaze deviation eliminates 2 inferior muscles and implicates 2 superior muscles.



**Figure 7-8** The 3-step test. The cyclovertical muscles are represented in their fields of action. **A**, Step 1: Right eye higher than left suggests weakness in 1 of the 2 depressors of the right eye (RIR or RSO) or in 1 of the 2 elevators of the left eye (LIO or LSR). **B**, Step 2: If the deviation furthermore worsens on left gaze, this implicates either the RSO or the LSR. Note that at the end of step 2, 1 depressor and 1 elevator of opposite eyes will be identified as the possible weak muscle. **C**, Step 3: If the right eye is furthermore higher in right head tilt than left head tilt, there is weakness of the RSO: right head tilt induces intorsion of the right eye, which depends on activation of both the RSO (a depressor) and the RSR (an elevator), and extorsion of the left eye, from activation of both the LIO (an elevator) and the LIR (a depressor). This rules out the LSR (which was still a candidate at the end of Step 2), and identifies the RSO as the weak muscle. LIO = left inferior oblique; LIR = left inferior rectus; LSR = left superior rectus; RIR = right inferior rectus; RSO = right superior oblique; RSR = right superior rectus.

- *Step 3:* Known as the *Bielschowsky head tilt test*, the final step involves tilting the head toward the right shoulder and the left one during distance fixation. Head tilt to the right stimulates intorsion of the right eye (RSR, RSO) and extorsion of the left eye (LIR, LIO). Head tilt to the left stimulates extorsion of the right eye (RIR, RIO) and intorsion of the left eye (LSR, LSO). Normally, the 2 intortors and the 2 extortors of each eye have *opposite* vertical actions that cancel one another. If 1 intortor or 1 extortor is weak, the vertical action of the other ipsilateral torting muscle becomes manifest during the torsional response to head tilt.

In the example shown in Figure 7-8C, the right hypertropia increases when the head is tilted to the right. This suggests that the vertical action of the right superior rectus muscle is unopposed, causing the right eye to move upward as it attempts to intort to maintain fixation; this indicates that the right superior oblique muscle is the weak muscle. (See also Chapter 11, Fig 11-3.)

## Tests of Sensory Adaptation and Binocular Function

---

Sensory binocularity involves the use of both eyes together to form a unified perception. Ideally, testing of this function is performed before binocularity or ocular alignment is disrupted by occlusion. The sensory response to strabismus is diplopia, suppression, or ARC (see Chapter 5). While a variety of sensory tests demonstrate these adaptations, the Worth 4-dot and stereopsis tests are the ones most commonly used in clinical practice. Sensory tests must be performed in conjunction with cover tests to determine whether a fusion response is due to normal alignment or ARC. Also, the clinician should remember that no sensory test can perfectly replicate habitual viewing conditions; the more dissociative the test, the greater the risk that it does not reflect habitual binocular function.

### The Red-Glass (Diplopia) Test

In a strabismic patient, placing a red glass or filter before the fixating eye while the patient views a white light stimulates the fovea of the fixating eye and an extrafoveal area of the fellow eye. If the patient sees only 1 light (either red or white), suppression is present (Fig 7-9A). A  $5\Delta$  or  $10\Delta$  base-up prism placed in front of the deviated eye can move the image out of the suppression scotoma, causing the patient to experience diplopia. With NRC, the white light will be localized below and to one side of the red light (Fig 7-9B). Incorrect localization of the white light, for example, directly below the red light, indicates ARC (Fig 7-9C).

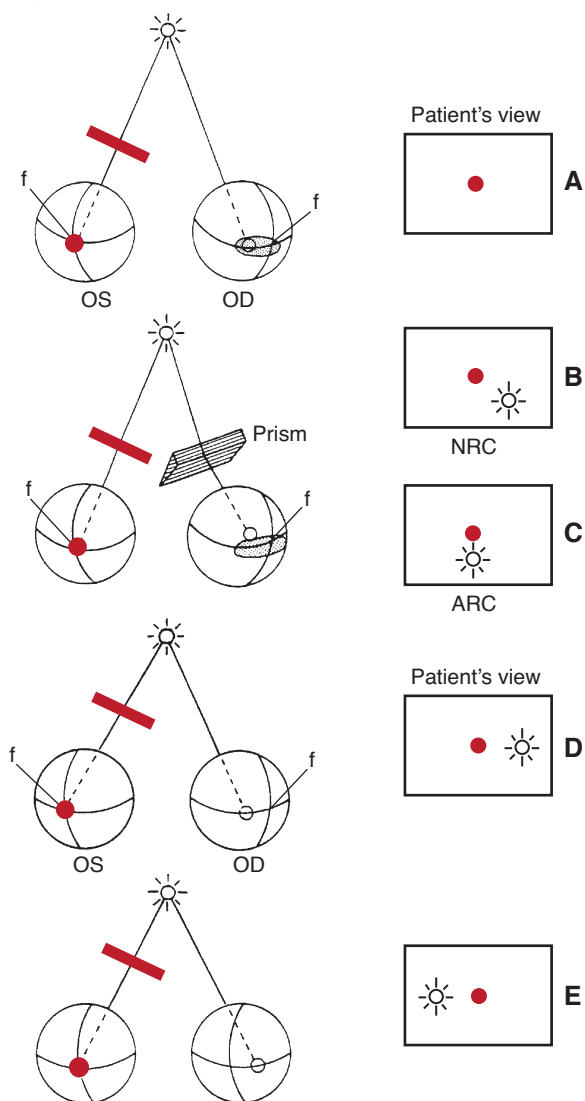
In the absence of suppression, the following results are possible:

- An esotropic patient without harmonious ARC experiences *homonymous* or *uncrossed* diplopia (see Chapter 5) (with the red glass over the *left* eye, the red light is perceived to the *left* of the white light—the *same* side as the red lens; Fig 7-9D). A patient with exotropia has *heteronymous* or *crossed* diplopia (with the red glass over the *left* eye, the red light is perceived to the *right* of the white light—the side *opposite*



that of the red lens; Fig 7-9E). If the degree of separation between the 2 images is consistent with the magnitude of the deviation measured by cover testing, the patient has NRC.

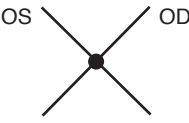
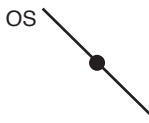
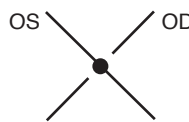
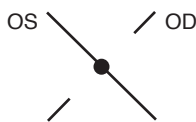

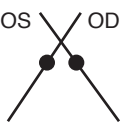
- If the patient sees the 2 lights superimposed so that they appear pinkish despite a measurable deviation, there is *harmonious ARC*.
- If the patient sees 2 lights (with uncrossed diplopia in esotropia and with crossed diplopia in exotropia) but the image separation is less than expected based on the measured deviation, there is *unharmonious ARC*. Some investigators consider this to be a testing artifact.



**Figure 7-9** Red-glass test findings in diplopia, suppression, and ARC (see text for explanation; see also Chapter 5, Fig 5-5). (Modified with permission from von Noorden GK, Campos EC. Binocular Vision and Ocular Motility: Theory and Management of Strabismus. 6th ed. St Louis: Mosby; 2002:223.)

### Bagolini Lenses

Bagolini lenses have many narrow, parallel striations that, like Maddox rods, cause a point source of light to appear as a streak perpendicular to the striations. The lenses are usually placed with the striations at an angle of 135° (patient's view) for the right eye and at an angle of 45° for the left eye, and the patient fixates on a distant light. Orthotropic patients will see 2 line segments crossing at their centers, forming an "X." Figure 7-10 illustrates a range of possible subjective results. For a patient with monofixation syndrome and a central scotoma, 1 of the lines will be perceived as having a gap, corresponding to the scotoma.

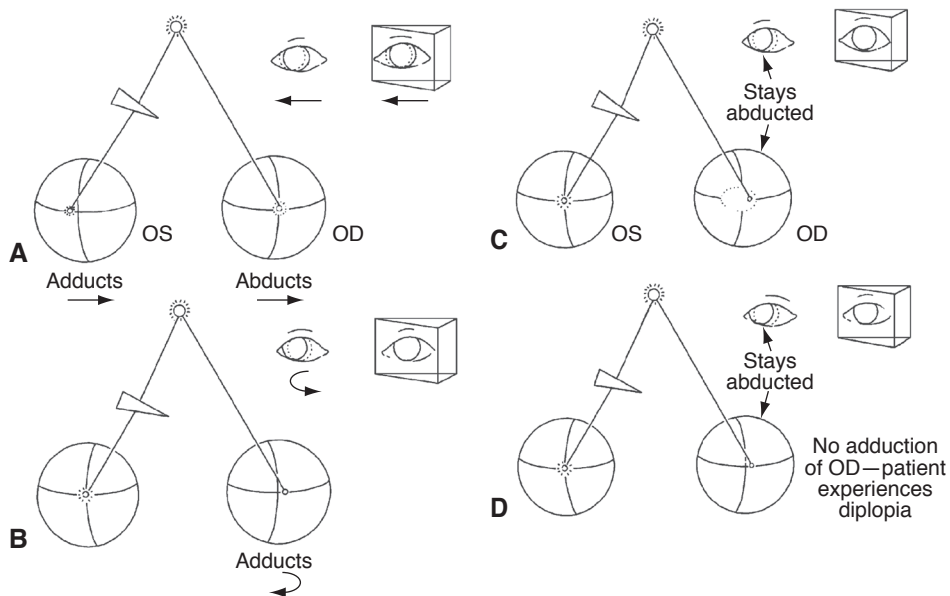
<b>Type of ocular deviation</b>	Orthotropia	Esotropia or Exotropia left eye preferred for fixation
<b>Patient's perception</b>		
<b>Cover test</b>	No shift	Shift
<b>Retinal correspondence and/or suppression</b>	NRC	Suppression (Total) OD
<hr/>		
<b>Type of ocular deviation</b>	Monofixation Syndrome (fixating OS)	Esotropia
<b>Patient's perception</b>		
<b>Cover test</b>	Small shift ( $\leq 8\Delta$ ) or no shift	Large shift ( $> 10\Delta$ )
<b>Retinal correspondence and/or suppression</b>	Peripheral fusion with central suppression (NRC or ARC)	ARC with Suppression (larger scotoma than monofixation syndrome)
<hr/>		
<b>Type of ocular deviation</b>	Esotropia	Exotropia
<b>Patient's perception</b>		
<b>Cover test</b>	Shift	Shift
<b>Retinal correspondence and/or suppression</b>	NRC with Diplopia No Suppression	NRC with Diplopia No Suppression

**Figure 7-10** Bagolini striated lens test for retinal correspondence and suppression. For these figures, the Bagolini lens striations are oriented at 135° in front of the right eye (patient's view) and at 45° in front of the left eye, such that the patient sees a line segment at an angle of 45° with the right eye and a line segment at an angle of 135° with the left eye. The perception of the oblique lines seen by each eye under binocular conditions is shown. Examples of the types of strabismus in which these responses are commonly found are given.

Like Maddox rods, parallel Bagolini lenses can also assess torsion, but unlike Maddox rods, which are more dissociating, Bagolini lenses permit close-to-normal viewing and fusion and therefore reveal only manifest torsion; they also allow simultaneous cover testing.

### The 4 $\Delta$ Base-Out Prism Test

The 4 $\Delta$  base-out prism test can identify a small facultative scotoma in a patient with monofixation syndrome and no manifest deviation (see Chapter 5). A 4 $\Delta$  base-out prism is placed before 1 eye during binocular viewing, while motor responses are observed (Fig 7-11); the test is then repeated with the prism over the other eye. Patients with bifixation usually show a version movement toward the apex of the prism, followed by a fusional convergence movement in which the eye with the prism maintains fixation while the fellow eye moves nasally to restore fusion. A similar response occurs regardless of which eye has the prism. In patients with monofixation, typically no movement is seen when the prism is placed before the nonfixating eye. When the prism is placed before the fixating eye, a refixation version movement occurs, but without any subsequent fusional convergence.



**Figure 7-11** The 4 $\Delta$  base-out prism test. **A**, When a prism is placed over the left eye, dextroversion occurs during refixation of that eye, indicating absence of foveal suppression in the left eye. If a suppression scotoma is present in the left eye, neither eye will move when the prism is placed before the left eye. **B**, Slow fusional adduction movement of the right eye is then observed, indicating absence of foveal suppression in the right eye. **C**, In a second patient, the absence of any such adduction movement (the right eye stays abducted after the dextroversion) suggests foveal suppression in the right eye. The patient does not experience diplopia. **D**, Weak fusion can also cause absence or delay of adduction movement, but in this case the patient experiences diplopia. (Modified with permission from von Noorden GK, Campos EC. Binocular Vision and Ocular Motility: Theory and Management of Strabismus. 6th ed. St Louis: Mosby; 2002:220.)

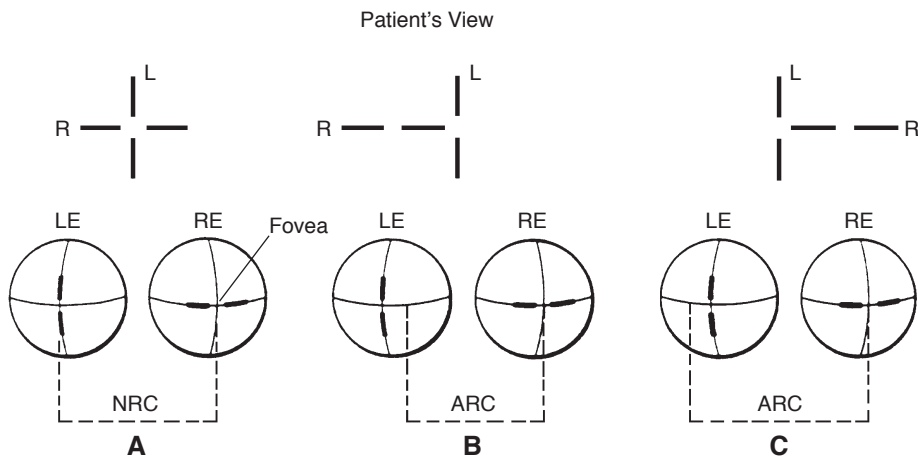
The  $4\Delta$  base-out prism test is the least reliable method of documenting a central suppression scotoma. Patients with bifixation may recognize diplopia when the prism is placed before an eye but make no convergence movement to correct for it. Patients with monofixation may switch fixation each time the prism is placed and show no version movement, regardless of which eye is tested.

### The Afterimage Test

This test involves stimulating the macula of each eye so as to produce a different linear afterimage in each eye, 1 horizontal and 1 vertical, by having each eye fixate on a linear light filament separately. The test can also be performed by covering a camera flash with black paper and exposing only a narrow slit; the center of the slit is covered with black tape to serve as a fixation point, as well as to protect the fovea from exposure. Because suppression scotomata extend along the horizontal retinal meridian and may obscure most of a horizontal afterimage, the vertical afterimage is induced in the deviating eye and the horizontal afterimage in the fixating eye. The patient is then asked to draw the relative positions of the perceived afterimages. Possible perceptions are shown in Figure 7-12. In patients with eccentric fixation (see Chapter 6), the afterimage is extrafoveal, and the test cannot be interpreted.

### Amblyoscope Testing

Although its use has declined, the major amblyoscope (discussed earlier; see Fig 7-7) was for decades a mainstay in the assessment and treatment of strabismus. The amblyoscope can measure horizontal, vertical, and torsional deviations and can be particularly helpful in adult strabismus. Because it can neutralize torsion, this instrument is useful for distinguishing between central fusion disruption (see Chapter 5) and inability to fuse because of a large cyclodeviation. The amblyoscope can also assess fusion ability, suppression, retinal



**Figure 7-12** Afterimage test. **A**, Normal retinal correspondence. **B**, ARC in a case of esotropia. **C**, ARC in a case of exotropia. (Modified with permission from von Noorden GK, Campos EC. *Binocular Vision and Ocular Motility: Theory and Management of Strabismus*. 6th ed. St Louis: Mosby; 2002:227.)

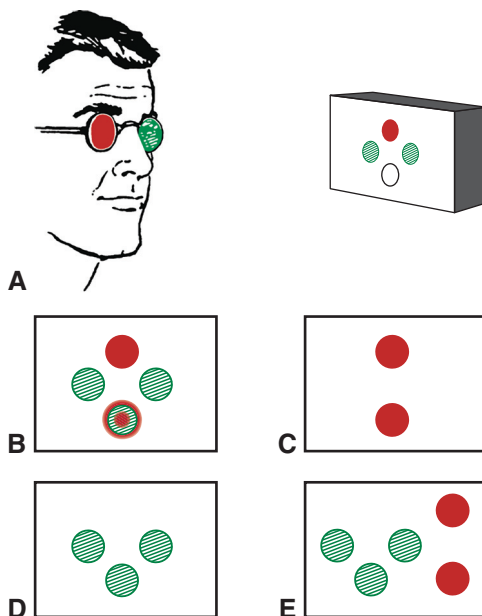
correspondence, fusional amplitudes, and stereopsis. In addition, it may be used in exercises designed to overcome suppression and increase fusional amplitudes.

### The Worth 4-Dot Test

The Worth 4-dot test (Fig 7-13) is often considered a test of sensory fusion; however, it does not evaluate sensory fusion directly as there is no fusible feature in the test. Its best use is to identify a suppression scotoma. The test uses red-green glasses and a target consisting of 4 illuminated dots: 1 red, 2 green, and 1 white. By convention, the red lens is placed in front of the right eye and the green lens in front of the left. The red lens blocks the green light, and the green lens blocks the red light, so the red and green dots are each seen by only 1 eye. The white dot is the only feature seen by both eyes, but it is seen in color rivalry in a patient with fusion. The *polarized Worth 4-dot test* uses polarized glasses rather than red and green ones. The stimulus lights can be presented in a wall-mounted display or with a Worth 4-dot flashlight. The test should be administered in good ambient light so that peripheral features in the room can stimulate motor fusion. The patient reports the number of dots seen:

- Seeing 2 dots indicates a suppression scotoma in the left eye.
- Seeing 3 dots indicates a suppression scotoma in the right eye.
- Seeing 4 dots indicates that if there is a suppression scotoma, it must subtend a smaller visual angle than the test target. The perception of 4 dots indicates some degree of sensory fusion, either NRC (if there is no manifest strabismus, or small-angle strabismus consistent with monofixation and peripheral fusion; see below) or harmonious ARC (if there is larger-angle manifest strabismus).
- Seeing 5 dots indicates diplopia, usually from larger-angle manifest strabismus without suppression or ARC.

**Figure 7-13** Worth 4-dot test. **A**, Looking through a pair of red-green glasses, the patient views 4 illuminated dots (1 red, 2 green, 1 white) at 6 m (projected, or mounted in a box) and at 33 cm (on a Worth 4-dot flashlight). The possible responses are given in parts B through E. **B**, Patient sees all 4 dots: peripheral fusion with orthophoria or strabismus with ARC. The dot in the 6 o'clock position is seen in color rivalry or, depending on ocular dominance, as predominantly red or predominantly green. **C**, Patient sees 2 red dots: suppression in left eye. **D**, Patient sees 3 green dots: suppression in right eye. **E**, Patient sees 5 dots: uncrossed diplopia with esotropia if the red dots appear to the right of the green dots, as in this figure; crossed diplopia with exotropia if the red dots appear to the left. (Modified with permission from von Noorden GK, Campos EC. *Binocular Vision and Ocular Motility: Theory and Management of Strabismus*. 6th ed. St Louis: Mosby; 2002:221.)



In monofixation syndrome (see Chapter 5), the Worth 4-dot test can demonstrate both the presence of peripheral fusion and the absence of bifixation. The standard Worth 4-dot flashlight projects onto a central retinal area of  $1^\circ$  or less when viewed at 3 m (10 ft), well within the  $1^\circ$ – $4^\circ$  scotoma characteristic of monofixation syndrome, so patients with monofixation syndrome report seeing 2 or 3 lights, depending on fixation preference. As the Worth 4-dot flashlight is brought closer to the patient, the dots project onto more peripheral retina outside the central monofixation scotoma and a fusion response (4 lights) is obtained. This usually occurs between 0.67 and 1 m (2–3 ft).

### Stereoacuity Tests

Stereopsis occurs when the 2 retinal images of an object in front of or behind the plane of fixation—which have small disparities due to the horizontal separation of the eyes—are cortically integrated, resulting in a perception of relative depth. Both *contour stereopsis* and *random-dot stereopsis tests* present horizontally displaced copies of the same stimulus to each eye separately (usually by having the patient wear polarized or red-green glasses). Contour stereopsis tests present horizontally displaced figures (one to each eye) that are recognizable to each eye individually. For contour stereoscopic figures with larger disparities, monocular cues in the form of decentration of the image seen by 1 eye are present, which could enable some patients to falsely pass. *Random-dot stereopsis tests* avoid such artifacts by embedding the stereoscopic figure in a background of similarly random dots; the dots in the area of the figure but not those in the background are shifted between the eyes, such that there is a stereoscopic percept, but neither eye alone can perceive the figure.

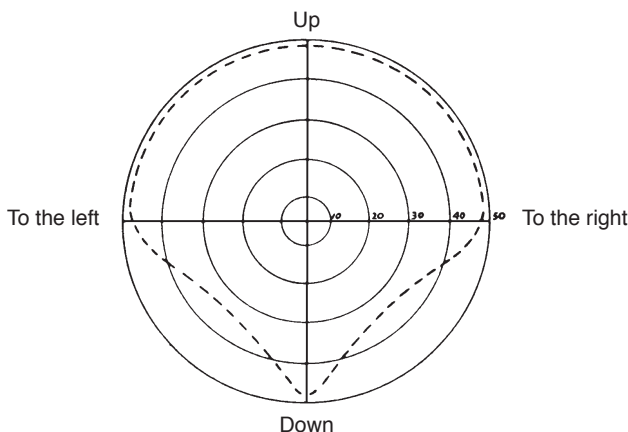
In the *Titmus test*, contour stereopsis is tested at near using polarized glasses. The ability to detect elevation of the fly's wings above the plane of the card indicates gross stereopsis (3000 seconds of arc). Finer levels of stereoacuity can also be demonstrated using stereoscopic images employing less horizontal disparity; at each level, the patient must identify the one stereoscopically presented figure out of a group of otherwise similar figures.

Clinically useful random-dot near stereopsis tests include the *Randot test*, which requires polarized glasses and measures stereoacuity down to 20 seconds of arc; the *TNO test*, which requires red-green glasses and measures stereoacuity down to 15 seconds of arc; the *Random-Dot E test*, a forced-choice test also requiring polarized glasses and employed mainly in pediatric vision-screening programs; and the *Lang stereopsis tests*, which do not require glasses to produce a random-dot stereoscopic effect and therefore may be useful in children who are not willing to put on glasses for testing.

Stereopsis can also be measured at distance using a chart projector with a vectographic slide, the Smart System PC-Plus (M&S Technologies, Inc.; Niles, IL), or the Frisby Davis Distance Stereotest (Stereotest Ltd, Sheffield, United Kingdom). Distance stereoacuity tests may be helpful in monitoring control of intermittent exotropia.

### Assessment of the Field of Single Binocular Vision

The field of single binocular vision may be tested using a Goldmann perimeter. This assessment is useful for following recovery of a paretic muscle or measuring the outcome of surgery to alleviate diplopia. A small, white test object is followed by both eyes in the cardinal positions throughout the visual field. When the patient indicates that the test



**Figure 7-14** The normal field of single binocular vision.

object is seen double, the point is plotted. The field of binocular vision normally measures about 45°–50° from the fixation point except where it is blocked by the nose (Fig 7-14). Weighted templates reflecting the greater importance of single binocular vision in primary and reading positions can be used to quantify the findings.

Sullivan TJ, Kraft SP, Burack C, O'Reilly C. A functional scoring method for the field of binocular single vision. *Ophthalmology*. 1992;99(4):575–581.

### The Prism Adaptation Test

In the prism adaptation test, binocular function is tested with prisms to align the visual axes to help predict whether fusion may be restored with surgical or prismatic alignment, especially in adults. This test is distinct from the use of prolonged prism adaptation to unmask a larger angle of deviation in acquired esotropia, as described in Chapter 8.

## Torticollis: Differential Diagnosis and Evaluation

Torticollis is an abnormal head position (AHP): head turn, chin-up or chin-down, tilt, or any combination of these. Ocular torticollis, as opposed to nonocular torticollis, results from strabismus or other eye conditions; see Table 7-2 for the differential diagnosis of both ocular and nonocular torticollis.

Early diagnosis and correction of ocular conditions resulting in torticollis is important because prolonged AHP (primarily head tilt) in children can cause facial asymmetry or secondary musculoskeletal changes. Note, however, that facial asymmetry coexisting with head tilt is not always caused by the head tilt. For example, unicoronal craniosynostosis can result in strabismus with ocular torticollis and also directly cause facial asymmetry independent of the torticollis.

### Ocular Torticollis

Sometimes an AHP and associated ocular abnormality simply have a shared underlying cause (eg, ocular tilt reaction), but more often, the AHP compensates for the ocular condition.

**Table 7-2 Differential Diagnosis of Torticollis**

Ocular Torticollis	Nonocular Torticollis
Nystagmus	Congenital muscular torticollis
Infantile nystagmus syndrome (congenital motor or sensory nystagmus; null point)	Skeletal abnormalities
Fusion maldevelopment nystagmus syndrome (manifest latent nystagmus; less in adduction)	Congenital abnormalities (eg, Klippel-Feil syndrome)
Periodic alternating nystagmus (alternating null point)	Traumatic abnormalities
Spasmus nutans	Neurologic conditions
Acquired adult jerk nystagmus	Syringomyelia
A- or V-pattern esotropia or exotropia	Dystonia
Paretic strabismus	Posterior fossa lesions
Superior oblique palsy	Deafness in one ear
Duane retraction syndrome	Sandifer syndrome
Sixth nerve palsy	Psychogenic disease
Third nerve palsy	
Inferior oblique palsy	
Restrictive strabismus	
Brown syndrome	
Thyroid eye disease	
Orbital fracture	
Congenital fibrosis of extraocular muscles	
Supranuclear disorders	
Monocular elevation deficiency	
Dorsal midbrain syndrome	
Gaze palsy	
Dissociated vertical deviation	
Ocular tilt reaction	
Monocular blindness (with fusion maldevelopment nystagmus syndrome, or for centration of remaining field)	
Homonymous hemianopia	
Ptosis	
Refractive error	

Incomitant strabismus (eg, superior oblique palsy, Duane retraction syndrome, Brown syndrome, blowout fractures, thyroid eye disease) can cause an AHP that improves binocularity. Chin-up positioning in unilateral ptosis likewise enables binocularity. In rare cases, patients with superior oblique palsy show paradoxical head tilt to the wrong side, possibly to increase the separation between diplopic images when fusion is not possible.

In infantile nystagmus syndrome (congenital motor or sensory nystagmus) with a null point away from primary position, an AHP improves vision. In fusion maldevelopment nystagmus syndrome (manifest latent nystagmus), vision improves with an AHP that brings the fixating eye into adduction. With bilateral duction deficits (eg, congenital fibrosis of extraocular muscles) or bilateral ptosis, an AHP may be needed for foveation. Refractive errors may also cause an AHP.

Finally, monocular individuals and patients with homonymous hemianopia may have a variable head turn toward their blind side, perhaps to better center the total field of view accessible with saccadic eye movements.



***Diagnostic evaluation of ocular torticollis***

To identify ocular causes of an AHP, motility testing should be done, with particular attention to gaze positions opposite those favored. Nystagmus is usually obvious, but subtle nystagmus may be visible only during slit-lamp or fundus examination. Fundus examination may reveal extorsion suggestive of superior oblique palsy, or conjugate torsion (extorsion in one eye and intorsion in the other), as seen in the ocular tilt reaction. If placing the patient in the supine position eliminates the head tilt, a musculoskeletal etiology is unlikely. If monocular occlusion eliminates the AHP, the torticollis probably serves binocular fusion.

## Esodeviations

An *esodeviation* is a latent or manifest convergent misalignment of the visual axes. Esodeviations are the most common type of childhood strabismus, accounting for more than 50% of ocular deviations in the pediatric population. In adults, esodeviations and exodeviations are equally prevalent.

Repka MX, Yu F, Coleman A. Strabismus among aged fee-for-service Medicare beneficiaries. *J AAPOS*. 2012;16(6):495–500.

### Epidemiology

---

Esodeviations occur with equal frequency in males and females and are more common in African Americans and white ethnic groups than in Asian ethnic groups in the United States. Risk factors for the development of esotropia include anisometropia, hyperopia, neurodevelopmental impairment, prematurity, low birth weight, craniofacial or chromosomal abnormalities, maternal smoking during pregnancy, and family history of strabismus. The prevalence of esotropia increases with age (higher prevalence at 48–72 months compared with 6–11 months), moderate anisometropia, and moderate hyperopia. In some families, a mendelian inheritance pattern has been observed. Amblyopia develops in approximately 50% of children who have esotropia.

Esodeviations can result from innervational, anatomical, mechanical, refractive, or accommodative factors. There are several major types of esodeviations, and they can be classified as comitant or incomitant (Table 8-1).

Cotter SA, Varma R, Tarczy-Hornoch K, et al; Joint Writing Committee for the Multi-Ethnic Pediatric Eye Disease Study and the Baltimore Pediatric Eye Disease Study Groups. Risk factors associated with childhood strabismus. *Ophthalmology*. 2011; 118(11):2251–2261.

### Pseudoesotropia

---

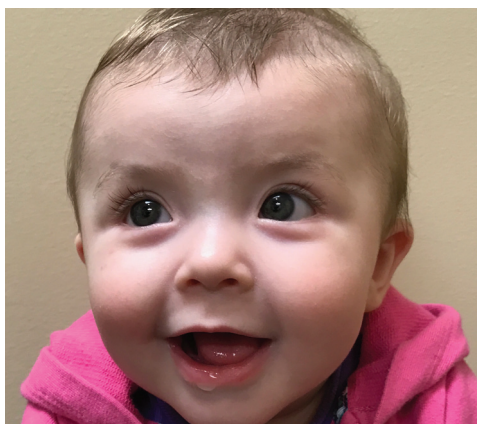*Pseudoesotropia* refers to the appearance of esotropia when the visual axes are in fact aligned. The appearance may be caused by a flat and broad nasal bridge, prominent epicanthal folds, a narrow interpupillary distance, or a negative angle kappa (see Chapter 7). Less than the expected amount of sclera is seen nasally, creating the impression that the eye is deviated inward (Fig 8-1). This is especially noticeable when the child gazes to either

**Table 8-1 Major Types of Esodeviation**

<b>Comitant Esotropia</b>
<b>Infantile (congenital) esotropia</b>
Ciancia syndrome
<b>Accommodative esotropia</b>
Refractive (normal AC/A ratio)
Nonrefractive (high AC/A ratio)
Partially accommodative
<b>Acquired nonaccommodative esotropia</b>
Basic
Cyclic
Sensory (deprivation)
Divergence insufficiency
Primary (age-related distance esotropia)
Secondary
Spasm of the near reflex
Consecutive esotropia
Spontaneous
Postsurgical
<b>Nystagmus and esotropia</b>
Fusion maldevelopment nystagmus syndrome
Nystagmus blockage syndrome
<b>Incomitant Esotropia</b>
Sixth nerve palsy
Medial rectus muscle restriction following excessive resection
Slipped or lost lateral rectus muscle following surgery
Thyroid eye disease
Medial orbital wall fracture with entrapment
Congenital fibrosis of the extraocular muscles
Esotropia associated with high myopia
Duane retraction syndrome
Möbius syndrome

AC/A = accommodative convergence/accommodation.

**Figure 8-1** Infant girl with pseudoesotropia. The child is looking to right gaze, and the broad epicanthal folds create the appearance of a left esotropia. (Courtesy of Katherine A. Lee, MD, PhD.)



side. Because no real deviation exists, results of both corneal light reflex testing and cover testing are normal.

## Infantile (Congenital) Esotropia

---

*Infantile esotropia* is defined as an esotropia that is present by 6 months of age. Some ophthalmologists refer to this disorder as *congenital esotropia*, although the deviation is usually not manifest at birth.

Variable, transient, intermittent strabismus is commonly noted in the first 2–3 months of life. Also, it is common to see both intermittent esotropia and exotropia in the same infant (termed *ocular instability of infancy*). This condition should resolve by 3 months of age but sometimes persists, especially in premature infants. If an esotropia is present after age 2 months, is constant, and measures 30 prism diopters ( $\Delta$ ) or more, it is unlikely to resolve and will probably require surgical intervention.

Patients with infantile esotropia often have a family history of esotropia or other strabismus, but well-defined genetic patterns are unusual. Infantile esotropia occurs more frequently in children born prematurely and in up to 30% of children with neurologic and developmental problems, including cerebral palsy and hydrocephalus. Infantile esotropia has been associated with an increased risk of development of mental illness by early adulthood (2.6 times higher in patients with infantile esotropia than in controls).

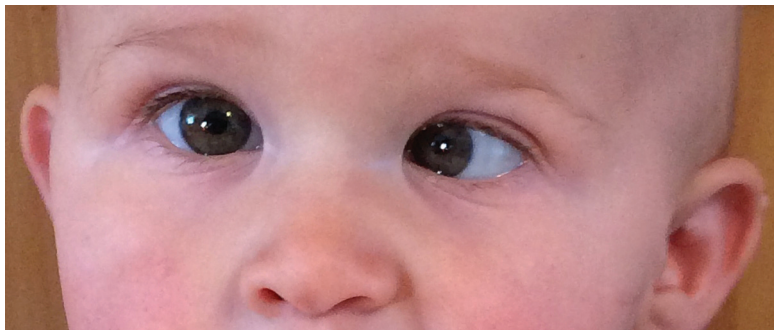Olson JH, Louwagie CR, Diehl NN, Mohny BG. Congenital esotropia and the risk of mental illness by early adulthood. *Ophthalmology*. 2012;119(1):145–149.

### Pathogenesis

The cause of infantile esotropia remains unknown. The debate regarding its etiology has focused on the implications of 2 conflicting theories. The Worth “sensory” concept proposes that infantile esotropia results from a congenital deficit in a “fusion center” in the brain. According to this theory, the goal of restoring binocularity is futile. In contrast, the Chavasse theory proposes that the primary problem in infantile esotropia is one of motor development, which is potentially curable if ocular alignment is achieved in infancy. Several authors have reported favorable sensory results in infants operated on between 6 months and 2 years of age, and these encouraging results have become the basis for the practice of early surgery for infantile esotropia.

### Clinical Features and Evaluation

The eyes may have equal vision, in which case alternate fixation or cross-fixation will be present. Cross-fixation, the use of the adducted eye for fixation of objects in the contralateral visual field, is associated with large-angle esotropias (Fig 8-2). Amblyopia is, however, commonly associated with infantile esotropia, and when it is present, a fixation preference can be observed.



**Figure 8-2** Infant boy with left esotropia. Cross-fixation of the right eye from the adducted position. (Courtesy of Katherine A. Lee, MD, PhD.)

Versions and ductions are often normal initially. The deviation is comitant and characteristically larger than  $30\Delta$ . Overelevation in adduction and dissociated strabismus complex develop in more than 50% of patients, usually after 1–2 years of age. There may be an apparent abduction deficit because of cross-fixation; children with equal vision in both eyes have no need to abduct either eye on side gaze. If amblyopia is present, the better-seeing eye will fixate in all fields of gaze, making the amblyopic eye appear to have an abduction deficit. The infant's ability to abduct each eye can be demonstrated with the doll's head maneuver or by observation after patching either of the patient's eyes. The clinician can also hold the infant and spin in a circle, which stimulates the vestibular-ocular reflex and helps demonstrate full abduction.

Asymmetry of monocular horizontal smooth pursuit is normal in infants up to age 6 months, with the nasal-to-temporal direction less well developed than the temporal-to-nasal. Patients with infantile esotropia, however, have persistent smooth-pursuit asymmetry throughout their lives. Fusion maldevelopment nystagmus syndrome (also known as *latent* and *manifest latent nystagmus*) is also a commonly associated motility anomaly. Cycloplegic refraction characteristically reveals low hyperopia (+1.00 to +2.00 diopters [D]). Hyperopia greater than 2.00 D should prompt consideration of spectacle correction; reduction of the strabismic angle with glasses indicates the presence of an accommodative component.

A severe form of infantile esotropia, referred to as *Ciancia syndrome*, consists of large-angle esotropia ( $>50\Delta$ ), abducting nystagmus, and mild abduction deficits. Children with this syndrome uniformly use cross-fixation.

## Management

Significant hyperopic refractive error should be corrected by prescribing the full cycloplegic refraction. A small-angle esotropia that is variable in degree or intermittent may be more likely to respond to hyperopic correction than would a large-angle or constant esotropia.

Ocular alignment is rarely achieved without surgery in early-onset esotropia. Previously, it was thought that concurrent amblyopia should be fully treated before surgery. However, it has recently been shown that successful postoperative alignment is as likely to

occur in patients with mild to moderate amblyopia at the time of surgery as it is in those whose amblyopia has been fully treated preoperatively. When ocular alignment is achieved earlier, there may be the added benefits of better fusion, stereopsis, and long-term stability.

The goal of surgical treatment of infantile esotropia is to reduce the deviation to orthotropia or as close to it as possible. In the presence of normal vision, this ideally results in the development of some degree of sensory fusion. Alignment within  $8\Delta$ – $10\Delta$  of orthotropia frequently results in the development of the monofixation syndrome, characterized by peripheral fusion, central suppression, and favorable appearance (see Chapter 5). This small-angle strabismus generally represents a stable, functional surgical outcome even though bifoveal fusion is not achieved; it is therefore considered a successful surgical result. In addition, the child's psychological and motor development may improve and accelerate after the eyes are straightened.

Most ophthalmologists in North America agree that surgery should be undertaken early. The belief is that the eyes should be aligned by 2 years of age, preferably earlier, to optimize binocular cooperation. Surgery can be performed in healthy children as early as age 4 months. The Congenital Esotropia Observational Study showed that when patients present with constant esotropia of at least  $40\Delta$  after 10 weeks of age, the deviations are unlikely to resolve spontaneously. Smaller angles can be monitored, as they may improve spontaneously. A prospective, multicenter European study (ELISSS) comparing early (age 6–24 months) versus delayed (age 32–60 months) strabismus surgery showed a small improvement in gross binocularity in the early-surgery group; however, a higher number of procedures were performed in the early-surgery group.

Various surgical approaches have been suggested for infantile esotropia. The most commonly performed initial procedure is recession of both medial rectus muscles. Recession of a medial rectus muscle combined with resection of the ipsilateral lateral rectus muscle is also effective. Two-muscle surgery spares the other horizontal rectus muscles for subsequent surgery should it be necessary, which is not uncommon. For infants with large deviations (typically  $>60\Delta$ ), some surgeons operate on 3 or even 4 horizontal rectus muscles at the time of the initial surgery, or they add botulinum toxin injection to the medial rectus muscle recession. Significant inferior oblique muscle overaction can be treated at the time of the initial surgery. Chapter 14 discusses surgical procedures in detail.

Injection of botulinum toxin to the medial rectus muscles has also been used as primary treatment of infantile esotropia. In a recent study, botulinum toxin injection was associated with a substantially higher reoperation rate than was strabismus surgery, and children treated with botulinum toxin were found to have a higher rate of postoperative abnormal binocularity. Botulinum toxin may be most useful for smaller deviations.

Leffler CT, Vaziri K, Schwartz SG, et al. Rates of reoperation and abnormal binocularity following strabismus surgery in children. *Am J Ophthalmol.* 2016;162:159–166.e9.

Pediatric Eye Disease Investigator Group. The clinical spectrum of early-onset esotropia: experience of the Congenital Esotropia Observational Study. *Am J Ophthalmol.* 2002; 133(1):102–108.

Simonsz HJ, Kolling GH, Unnebrink K. Final report of the early vs. late infantile strabismus surgery study (ELISSS), a controlled, prospective, multicenter study. *Strabismus.* 2005; 13(4):169–199.

## Accommodative Esotropia

---

*Accommodative esotropia* is defined as a convergent deviation of the eyes associated with activation of the accommodative reflex. All accommodative esodeviations are acquired and can be characterized as follows:

- onset typically between 6 months and 7 years of age, averaging 2½ years of age (can be as early as age 4 months)
- usually intermittent at onset, becoming constant
- comitant
- often hereditary
- sometimes precipitated by trauma or illness
- frequently associated with amblyopia
- possibly occurring with diplopia (especially with onset at an older age), which usually disappears with development of a facultative suppression scotoma in the deviating eye

Types of accommodative esotropia are listed in Table 8-1 and discussed in the following sections.

### Pathogenesis and Types of Accommodative Esotropia

#### ***Refractive accommodative esotropia***

The mechanism of refractive accommodative esotropia involves 3 factors: uncorrected hyperopia, accommodative convergence, and insufficient fusional divergence. Because of uncorrected hyperopia, the patient must accommodate to focus the retinal image. Accommodation is accompanied by the other components of the near reflex, namely convergence and miosis. If the patient's fusional divergence mechanism is insufficient to compensate for the increased convergence tonus, esotropia results. The angle of esotropia is approximately the same at distance and near fixation and is generally between 20Δ and 30Δ. Patients with refractive accommodative esotropia have an average of +4.00 D of hyperopia.

#### ***High AC/A ratio accommodative esotropia***

Patients with a *high accommodative convergence/accommodation (AC/A) ratio* (see Chapter 7) have an excessive convergence response for the amount of accommodation required to focus while wearing their full cycloplegic correction. In this form of esotropia, the deviation is present only at near or is much larger at near.

The refractive error in high AC/A ratio accommodative esotropia (also called *non-refractive accommodative esotropia*) averages +2.25 D. However, this esotropia can occur in patients with a normal level of hyperopia or high hyperopia, with emmetropia, or even with myopia.

#### ***Partially accommodative esotropia***

Patients with partially accommodative esotropia show reduction in the angle of esotropia when wearing glasses but have a residual esotropia despite provision of the full hyperopic

correction. This is more likely to occur if there is a long delay in refractive correction. In some cases, partially accommodative esotropia results from decompensation of a pure refractive accommodative esotropia; in other instances, an initial nonaccommodative esotropia subsequently develops an accommodative component.

## Evaluation

The 2 eyes can have equal vision, or amblyopia can be present. Versions and ductions may be normal, or overelevation in adduction or dissociated strabismus complex (discussed in Chapter 11) may be present. The examiner should measure the deviation using an accommodative target at distance and at near. Alternate cover testing at the initial examination typically reveals an intermittent comitant esotropia that is larger at near than at distance.

## Management

### ***Refractive accommodative esotropia***

Treatment of refractive accommodative esotropia consists of correction of the full amount of hyperopia, as determined under cycloplegia. If binocular fusion is maintained, the refractive correction can later be decreased to 1.00–2.00 D less than the full cycloplegic refraction. Amblyopia, if present, may respond to spectacle correction alone, but treatment with occlusion or atropine may be necessary if the amblyopia persists after a period of spectacle wear (see Chapter 6).

Parents must understand not only that full-time wear of the glasses is important but also that the refractive correction can only help control the strabismus, not “cure” it. Once full-time wear has begun, the esotropia may increase when the child is not wearing glasses, because the child makes a strong accommodative effort to produce an image that is as clear as the one experienced with refractive correction. Discussing these issues with the parents at the time the prescription is given is helpful.

Strabismus surgery may be required when a patient with presumed refractive accommodative esotropia does not achieve an ocular alignment within the fusion range (up to  $8\Delta$ – $10\Delta$ ) with correction (partially accommodative esotropia). Before proceeding with surgery, the ophthalmologist should recheck the cycloplegic refraction to rule out latent uncorrected hyperopia.

### ***High AC/A ratio accommodative esotropia***

A high AC/A ratio can be managed optically or surgically; it can also be observed.

- *Bifocals.* Plus lenses for hyperopia reduce accommodation and therefore accommodative convergence. Bifocal glasses further reduce or eliminate the need to accommodate for near fixation. If bifocals are used, the initial prescription should be for flat-top style bifocals (see the chapter on refraction in BCSC Section 3, *Clinical Optics*) with the lowest plus power needed (up to +3.00 D) to achieve ocular alignment at near fixation. To increase the likelihood that the child will use the bifocal segment, it should be set high enough that the top of the bifocal segment bisects the pupil. Progressive bifocal lenses have been used successfully in older children who



know how to use bifocal glasses. An ideal response to bifocal glasses is restoration of normal binocular function (fusion and stereopsis) at both distance and near fixation. An acceptable response is fusion at distance and less than  $10\Delta$  of residual esotropia at near with bifocals (signifying the potential for fusion). While some children improve spontaneously with time, others need to be slowly weaned from bifocal glasses. The process of reducing the bifocal power in 0.50–1.00 D steps can be started at about age 7 or 8 years and should be completed by age 10–12 years. If a child cannot be weaned from bifocals, surgery may be considered.

- *Surgery.* Surgical management of high AC/A ratio accommodative esotropia is controversial. Some ophthalmologists advocate surgery (medial rectus muscle recessions with or without posterior or pulley fixation) to normalize the AC/A ratio, which may allow discontinuation of bifocals. The risk of overcorrection at distance is low (<10%). Some ophthalmologists use prism adaptation, which entails using prisms preoperatively to neutralize a deviation for a certain length of time. The prism neutralization can then be used to predict the outcome of surgery and determine the maximum deviation.
- *Observation.* Many patients show a decrease in the near deviation with time, and binocular vision at both distance and near fixation ultimately develops. Some ophthalmologists observe the near deviation as long as the distance alignment allows for the development of peripheral fusion.

For the long-term management of both refractive and high AC/A ratio accommodative esotropia, it is important to remember that hyperopia usually increases until age 5–7 years before it starts to decrease. Therefore, if the esotropia with correction increases, the cycloplegic refraction should be repeated and the full correction prescribed.

If glasses correct all or nearly all the esotropia and if some degree of sensory binocular cooperation or fusion is present, the clinician may begin to reduce the hyperopic correction to create a small esophoria, which is thought to stimulate fusional divergence. An increase in the fusional divergence, combined with the natural decrease of both the hyperopia and the high AC/A ratio, may enable the patient to eventually maintain straight eyes without bifocals or glasses altogether.

### ***Partially accommodative esotropia***

Treatment of partially accommodative esotropia consists of strabismus surgery for the deviation that persists while the patient wears the full hyperopic correction. It is important that the patient and parents understand *before* surgery that its purpose is to produce straight eyes with spectacle wear—not to enable the child to discontinue wearing glasses altogether. In older patients, refractive surgery may be considered to both reduce the hyperopic refractive error and improve the ocular alignment.

## **Acquired Nonaccommodative Esotropia**

---

Several types of comitant esotropia not associated with activation of the accommodative reflex may develop in later infancy (>6 months), childhood, or even adulthood. The causes of these acquired nonaccommodative esotropias are varied.

### Basic Acquired Nonaccommodative Esotropia

Basic acquired nonaccommodative esotropia is a comitant esotropia that develops after age 6 months and is not associated with an accommodative component. As in infantile esotropia, the amount of hyperopia is not significant, and the angle of deviation is similar when measured at distance and near. Acquired esotropia may be acute in onset. In such cases, the patient immediately becomes aware of the deviation and may have diplopia. A careful evaluation is important to rule out an accommodative or paretic component. Temporary but prolonged disruption of binocular vision—such as may result from a hyphema, preseptal cellulitis, mechanical ptosis, or prolonged patching for amblyopia—is a known precipitating cause of acquired nonaccommodative esotropia. In patients with acquired nonaccommodative esotropia, fusion is thought to be tenuous, so this temporary disruption of binocular vision upsets the balance, resulting in esotropia. Because the onset of nonaccommodative esotropia in an older child may be a sign of an underlying neurologic disorder, neuroimaging and neurologic evaluation may be indicated, especially when other symptoms or signs of neurologic abnormality are present, such as lateral incomitance, deviation greater at distance than near, abnormal head position, or concomitant headache.

Many patients with acquired nonaccommodative esotropia have a history of normal binocular vision; thus, the prognosis for restoration of single binocular vision with prisms and/or surgery is good. Therapy consists of amblyopia treatment, if necessary, and surgical correction or botulinum toxin injection as soon as possible after the onset of the deviation. The Prism Adaptation Study showed a smaller undercorrection rate (approximately 10% less) when the amount of surgery was based on the prism-adapted angle.

Jacobs SM, Green-Simms A, Diehl NN, Mohny BG. Long-term follow-up of acquired nonaccommodative esotropia in a population-based cohort. *Ophthalmology*. 2011;118(6):1170–1174.

Repka MX, Connett JE, Scott WE. The one-year surgical outcome after prism adaptation for the management of acquired esotropia. *Ophthalmology*. 1996;103(6):922–928.

### Cyclic Esotropia

Cyclic esotropia is a rare form of strabismus; other forms of cyclic strabismus occur but are even rarer. Onset of cyclic esotropia is typically during the preschool years. The esotropia is comitant and intermittent, usually occurring every other day (48-hour cycle). Variable intervals and 24-hour cycles have also been documented.

Fusion and binocular vision are usually absent or defective on the strabismic day, with marked improvement or normalization on the orthotropic day. Occlusion therapy may convert the cyclic deviation into a constant one.

Surgical treatment of cyclic esotropia is usually effective. The amount of surgery is based on the maximum angle of deviation present when the eyes are esotropic.

### Sensory Esotropia

Monocular vision loss (due to cataract, corneal clouding, optic nerve or retinal disorders, or various other entities) may cause sensory (deprivation) esotropia. Conditions preventing

clear and focused retinal images and symmetric visual stimulation must be identified and remedied promptly, if possible, to prevent irreversible amblyopia. If surgery or botulinum toxin injection is indicated for strabismus, it is generally performed only on the eye with a significant vision deficit.

### **Divergence Insufficiency**

In divergence insufficiency, the characteristic finding is an esodeviation that is greater at distance than at near. The deviation is horizontally comitant, and fusional divergence is reduced. There are 2 forms of divergence insufficiency: a primary, isolated form; and a secondary form that is rare and associated with neurologic abnormalities, including pontine tumors, increased intracranial pressure, or severe head trauma. In these secondary cases, the divergence insufficiency is probably due to a mild sixth nerve paresis. Patients with secondary divergence insufficiency require neuroimaging to rule out treatable intracranial lesions.

Primary divergence insufficiency is an increasingly diagnosed type of adult strabismus. More recently termed *age-related distance esotropia*, the entity is a slowly progressing, benign condition that occurs predominantly in patients older than 50 years. Affected individuals report a gradual onset of horizontal diplopia that is present at distance but not at near. Imaging may demonstrate thinning, elongation, and rupture of the connective tissue between the lateral and superior rectus muscles and sagging and elongation of the lateral rectus muscles. Management consists of base-out prisms, botulinum toxin injection of the medial rectus muscles, and strabismus surgery. In patients with age-related distance esotropia, reestablishment of binocular fusion generally occurs following treatment.

Chaudhuri Z, Demer JL. Sagging eye syndrome: connective tissue involution as a cause of horizontal and vertical strabismus in older patients. *JAMA Ophthalmol.* 2013;131(5):619–625.

### **Spasm of the Near Reflex**

Spasm of the near reflex (also known as *ciliary spasm* or *convergence spasm*) is a spectrum of abnormalities of the near response. The etiology is generally thought to be functional, related to psychological factors such as stress and anxiety. In rare cases, it can be associated with organic disease. Patients present with varying combinations of excessive convergence, increased accommodation, and miosis. Patients may present with acute esotropia alternating with orthotropia. Substitution of a convergence movement for a gaze movement with horizontal versions is characteristic. Monocular abduction is normal despite marked limitation of abduction on version testing. Pseudomyopia may occur.

Treatment consists of cycloplegic agents such as atropine or homatropine, hyperopic correction, and bifocal glasses. Counseling to address underlying psychological issues may be helpful. If the spasm cannot be broken, botulinum toxin injection of the medial rectus muscles and strabismus surgery may be considered with caution.

Kaczmarek BB, Dawson E, Lee JP. Convergence spasm treated with botulinum toxin. *Strabismus.* 2009;17(1):49–51.

## Consecutive Esotropia

*Consecutive esotropia* refers to an esotropia that follows a history of exotropia. It can arise spontaneously, or it can develop after surgery for exotropia. Spontaneous consecutive esotropia is rare and almost always occurs in the setting of neurologic disorders or with very poor vision in 1 eye. Postsurgical consecutive esotropia, on the other hand, is not uncommon. Fortunately, it often resolves over time without treatment. In fact, an initial small overcorrection is desirable after surgery for exotropia, as it is associated with an improved long-term success rate. Treatment options for consecutive esotropia include base-out prisms, hyperopic correction, alternating occlusion, botulinum toxin injection, and strabismus surgery. In postsurgical consecutive esotropia, unless the deviation is very large or a slipped or “lost” muscle is suspected, surgery or botulinum toxin injection may be postponed for several months after onset because of the possibility of spontaneous improvement.

A slipped or lost lateral rectus muscle (discussed in Chapter 14) produces various amounts of esotropia and incomitance, depending on the amount of slippage, and should be suspected in consecutive esotropia following lateral rectus recession surgery if a significant abduction deficit is present. However, if the ipsilateral medial rectus muscle was resected at the time of the lateral rectus recession, the consecutive esotropia could be due to a tight medial rectus muscle. Forced duction testing helps differentiate between these 2 causes. In cases of a slipped or lost lateral rectus muscle, surgical exploration is required. (See Chapter 14, Fig 14-1, and the accompanying discussion.)

## Nystagmus and Esotropia

---

Several types of nystagmus are associated with esotropia. *Fusion maldevelopment nystagmus syndrome* (also known as *latent* and *manifest latent nystagmus*) is a common feature of infantile esotropia. Ciancia syndrome (discussed earlier in this chapter) is a severe form of infantile esotropia associated with an abducting nystagmus. *Nystagmus blockage syndrome* occurs in children with congenital motor nystagmus, who use convergence to “damp,” or decrease the amplitude or frequency of, their nystagmus, resulting in esotropia. See also Chapter 13.

## Incomitant Esotropia

---

There are several positional, restrictive, and innervational abnormalities of the extraocular muscles that may result in incomitant esotropia (see Table 8-1).

## Sixth Nerve Palsy

Weakness of the lateral rectus muscle due to palsy of the abducens nerve results in incomitant esotropia. Sixth cranial nerve palsy occurring in the neonatal period is rare and usually transient. Most cases of suspected congenital sixth nerve palsy are actually infantile esotropia with cross-fixation. Congenital sixth nerve palsy may be difficult to differentiate from esotropic Duane retraction syndrome, which is more common in young

infants (see Chapter 12), as the unique retraction feature of this syndrome may not yet be evident. A distinguishing characteristic is that for an equal amount of abduction deficit, the deviation in primary position is usually much larger in sixth nerve palsy than it is in esotropic Duane retraction syndrome.

### **Pathogenesis**

Congenital sixth nerve palsy is usually benign and transient and may be caused by the increased intracranial pressure associated with the birth process. Sixth nerve palsy in older children is associated with intracranial lesions in approximately one-third of cases, which may have additional neurologic findings. Other cases may be related to infectious or immunologic processes involving cranial nerve VI. The most common cause of isolated, transient sixth nerve palsy in a child is thought to be a virus; in an adult, a microvascular occlusive event.

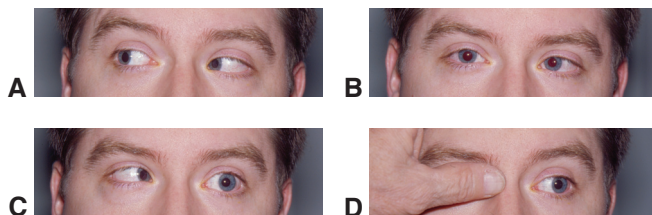
### **Clinical features and evaluation**

Older children and adults may report diplopia. Often there is a compensatory head turn toward the side of the paralyzed lateral rectus muscle, adopted to place the eyes in a position where they are best aligned. If a child presents soon after onset of the deviation, vision in the eyes is usually equal. The esotropia increases in gaze toward the side of the paralyzed lateral rectus muscle, and versions show limited or no abduction of the affected eye (Fig 8-3). Results of the saccadic velocity test show slowing of the affected lateral rectus muscle, and active force generation tests document weakness of that muscle.

A careful history should be taken, including antecedent infections, head trauma, and hydrocephalus, as well as hypertension and diabetes mellitus in adults. In light of the high prevalence of associated intracranial lesions in children with sixth nerve palsy, neurologic evaluation and magnetic resonance imaging of the head and orbit are usually indicated, even in the absence of other focal neurologic findings.

### **Management**

Patching may be necessary to prevent or treat amblyopia if the child is not using a compensatory head posture or if the child is very young. Press-on prisms are sometimes used to correct diplopia in primary position. Correction of a significant hyperopic refractive error may help prevent the development of an associated accommodative esotropia. Botulinum



**Figure 8-3** Sixth nerve palsy, left eye. **A**, Right gaze. **B**, Esotropia in primary position. **C**, Limited abduction, left eye. **D**, Abduction is still incomplete, but there is further abduction when the left eye is fixating, a finding that is important in the plan for surgical correction. (Courtesy of Edward L. Raab, MD.)

toxin injection of the ipsilateral medial rectus muscle is sometimes employed to temporarily decrease the esotropia. If the deviation does not resolve after 6 months of treatment, surgery may be indicated. Options include horizontal rectus muscle surgery if abduction is at least partially preserved or vertical rectus muscle transposition surgery if abduction is absent (see Chapter 14).

See BCSC Section 5, *Neuro-Ophthalmology*, for further discussion of sixth nerve palsy.

### **Other Forms of Incomitant Esotropia**

*Medial rectus muscle restriction* may result from thyroid eye disease, orbital myositis, medial orbital wall fracture with medial rectus entrapment, excessive medial rectus muscle resection, or congenital fibrosis of the extraocular muscles. Duane retraction syndrome and Möbius syndrome begin as paralytic disorders, and secondary restriction of the medial rectus may develop later. In patients with high myopia, esotropia may develop because of prolapse of the posterior globe between displaced lateral and superior rectus muscles.

For further discussion of these special forms of strabismus, see Chapter 12 in this volume and BCSC Section 5, *Neuro-Ophthalmology*.



# Exodeviations

An exodeviation is a manifest (exotropia) or latent (exophoria) divergent strabismus. Risk factors for exotropia include maternal substance abuse and smoking during pregnancy, premature birth, perinatal morbidity, genetic anomalies, family history of strabismus, and uncorrected refractive errors.

## Pseudoexotropia

---

The term *pseudoexotropia* refers to an appearance of exodeviation when in fact the eyes are properly aligned. Pseudoexotropia is much less common than pseudoesotropia (see Chapter 8 for discussion of pseudoesotropia) and may occur when there is a wide interpupillary distance or a positive angle kappa with or without other ocular abnormalities (see the discussions of angle kappa in Chapter 7 of this volume and in BCSC Section 3, *Clinical Optics*).

## Exophoria

---

Exophoria is an exodeviation controlled by fusion under normal binocular viewing conditions. An exophoria is detected when binocular vision is interrupted, as during an alternate cover test or monocular visual acuity testing. Exophoria is relatively common, and patients are usually asymptomatic, although with prolonged near work, they may experience asthenopia. Decompensation of an exophoria to an exotropia may occur when the patient is ill or under the influence of sedatives or alcohol. Treatment is recommended when an exophoria becomes symptomatic.

## Intermittent Exotropia

---

Intermittent exotropia is the most common type of manifest exodeviation.

### Clinical Characteristics

The onset of intermittent exotropia is usually before age 5 years, and the exotropia typically continues into adulthood. The exodeviation becomes manifest during times of visual inattention, fatigue, stress, or illness. Parents of affected children often report that the exotropia occurs late in the day or when the child is daydreaming or tired. Exposure to bright



light often causes exodeviation and a reflex closure of 1 eye (which is why strabismus is sometimes referred to as a “squint”).

Exodeviations are usually larger when the patient views distant targets, and they may be difficult to elicit at near. Because most parental interactions with young children occur at near, parents of a child with intermittent exotropia may not notice it initially. Intermittent exotropia can be associated with small hypertropias, A and V patterns (see Chapter 10), and overelevation and underelevation in adduction (see Chapter 11).

Left untreated, intermittent exotropia may remain stable, resolve, or progress, sometimes to constant exotropia. Because of suppression, children younger than 10 years with intermittent exotropia rarely report diplopia. They retain normal retinal correspondence and good binocular function when orthotropic. Amblyopia may occur if the strabismus is poorly controlled or becomes constant. Adults with poorly controlled intermittent or constant exotropia often experience significant psychological stress, anxiety, and depression because of their strabismus. Adults with strabismus often report reduced quality of life, obtain lower levels of education, and may have limited career choices and advancement opportunities.

## Evaluation

The clinical evaluation begins with a history, including the age at onset of the strabismus, frequency and duration of misalignment, circumstances under which the deviation is manifest, and whether the exotropia is becoming more frequent with time. The clinician should determine whether symptoms such as diplopia, asthenopia, or difficulty with interpersonal interactions secondary to ocular misalignment are present.

Exodeviation control may be categorized as follows:

- *Good control:* Exotropia manifests only after cover testing, and the patient resumes fusion rapidly without blinking or refixating.
- *Fair control:* Exotropia manifests after fusion is disrupted by cover testing, and the patient resumes fusion only after blinking or refixating.
- *Poor control:* Exotropia manifests spontaneously and may remain manifest for an extended time.

Some ophthalmologists use the Newcastle Control Score for Intermittent Exotropia to quantitatively grade the control exhibited by patients with this deviation.

Because visual acuity and alignment tests are dissociating and may adversely affect assessment of strabismus control, they should be performed after sensory tests for stereopsis and fusion. Prism and alternate cover testing should be used to evaluate the exodeviation at fixation distances of 6 m and 33 cm. A far-distance measurement at 30 m or greater (eg, at the end of a long hallway or out a window) may uncover a latent deviation or elicit an even larger one. The deviation at near fixation is often smaller than the deviation at distance fixation. This difference is usually due to *tenacious proximal fusion*, a slow-to-dissipate fusion mechanism at near. The difference may sometimes be due to a high accommodative convergence/accommodation (AC/A) ratio, but a high AC/A ratio occurs much less commonly in exotropia than in esotropia (see Chapter 7, which discusses measurement

of AC/A ratios). The exodeviation is termed *basic intermittent exotropia* when the size of the deviation at distance fixation is within 10 prism diopters ( $\Delta$ ) of the deviation size at near fixation. Some children have a larger deviation at near than at distance; this is distinct from convergence insufficiency (discussed later in the chapter).

When the exodeviation at distance is larger than the deviation at near fixation by  $10\Delta$  or more, the near exodeviation should be remeasured after 1 eye is occluded for 30–60 minutes (the patch test). The patch test eliminates the effects of tenacious proximal fusion, helping distinguish between pseudodivergence excess and true divergence excess. A patient with pseudodivergence excess has similar distance and near measurements after the patch test. A patient with true divergence excess continues to have a significantly larger exodeviation at distance. Many patients with true divergence excess also have a high AC/A ratio. For these patients, the AC/A ratio can be determined by measuring the near deviation with and without +3.00 diopter (D) lenses (while the patient wears corrective lenses, if necessary), after the patch test is completed. The measurements are then compared. Alternatively, the distance deviation can be measured with and without  $-2.00$  D lenses to determine the AC/A ratio.

American Academy of Ophthalmology Pediatric Ophthalmology/Strabismus Panel. Preferred Practice Pattern Guidelines. *Esotropia and Exotropia*. San Francisco, CA: American Academy of Ophthalmology; 2012. For the latest guidelines, go to [www.aao.org/ppp](http://www.aao.org/ppp).

## Treatment

All patients with exodeviations should be monitored as some will require treatment. Opinions vary widely regarding the timing of surgery and the use of nonsurgical treatments. Patients who have well-controlled, asymptomatic intermittent exotropia and good binocular fusion can be observed. Untreated strabismus often results in poor self-esteem in adults and children. Adults with strabismus report a wide range of difficulties with social interactions, which improve significantly after surgery.

### **Nonsurgical management**

**Correction of refractive errors** Corrective lenses should be prescribed for significant refractive errors. Correction of even mild myopia may improve control of the exodeviation. Mild-to-moderate degrees of hyperopia are not routinely corrected in children with intermittent exotropia because refractive correction may worsen the deviation. Children with marked hyperopia ( $>+4.00$  D) may be unable to sustain accommodation, which results in a blurred retinal image and manifest exotropia. In these patients, correction of refractive errors with glasses or contacts may improve retinal image clarity and help control the exodeviation.

In some cases, overcorrection of myopia by 2.00–4.00 D can stimulate accommodative convergence to help control the exodeviation. It can be effective as a temporizing measure to promote fusion and delay surgery in children with an immature visual system. This therapy may cause asthenopia in school-aged children, however. For patients whose initial overcorrection results in control, the prescription can be gradually tapered and surgery may be avoided.

**Occlusion therapy** Occlusion therapy (patching) for amblyopia may improve exotropic deviations. For patients without amblyopia, part-time patching of the dominant (non-deviating) eye or alternate patching (alternating which eye is patched each day) in the absence of a strong ocular preference can improve control of small- to moderate-sized deviations, particularly in young children. The improvement is often temporary, however, and many patients eventually require surgery.

**Prisms** Although they can be used to promote fusion in intermittent exotropia, base-in prisms are seldom chosen for long-term management because they can cause a reduction in fusional vergence amplitudes.

### **Surgical treatment**

Factors influencing the decision to proceed with surgery include strabismus that is frequently manifest, poorly controlled, worsening (especially at near), symptomatic; poor self-image; and difficulty with personal or professional relationships. Strabismus surgery in adults is reconstructive, not cosmetic, and may alleviate anxiety and depression in some patients.

Surgical treatment of exotropia typically consists of bilateral lateral rectus muscle recession or unilateral lateral rectus muscle recession combined with medial rectus muscle resection. Large ( $>50\Delta$ ) deviations may require surgery on 3 or 4 muscles; for small deviations, single-muscle recession is sometimes performed. The optimal age for surgery and the choice of procedure are debatable. Caution is advised when surgery is considered for patients with true divergence excess exotropia, as they are at risk for postoperative diplopia and esotropia at near.

Adams GG, McBain H, MacKenzie K, Hancox J, Ezra DG, Newman SP. Is strabismus the only problem? Psychological issues surrounding strabismus surgery. *J AAPOS*. 2016;20(5):383–386.

Joyce KE, Beyer F, Thomson RG, Clarke MP. A systematic review of the effectiveness of treatments in altering the natural history of intermittent exotropia. *Br J Ophthalmol*. 2015;99(4):440–450.

**Postoperative alignment** A small-angle esotropia in the immediate postoperative period tends to resolve and is desirable because of its association with a reduced risk of recurrent exotropia. Patients may experience diplopia while esotropic, and they should be advised of this possibility preoperatively. An esodeviation that persists beyond 3–4 weeks or that develops 1–2 months after surgery (*postsurgical esotropia*) may need further treatment, such as hyperopic correction, base-out prisms, patching to prevent amblyopia, or additional surgery. Bifocal glasses can be used for a high AC/A ratio and should be discussed preoperatively with patients who have true divergence excess. Unless deficient ductions suggest a slipped or “lost” muscle, a delay of a few months is recommended before reoperation for postsurgical esotropia, as spontaneous improvement may occur.

Because of the possibility of persistent consecutive esodeviations, some ophthalmologists prefer to delay surgery in young children who have good preoperative visual acuity and stereopsis. Others, however, consider surgical delay a risk factor for recurrence of strabismus. Long-term follow-up studies of the effectiveness of surgical treatment of

intermittent exotropia show high recurrence rates. Patients may require multiple surgeries to maintain ocular alignment long term.

## Convergence Insufficiency

---

Convergence insufficiency (CI) is an exodeviation that is greater at near fixation than at distance fixation. It is characterized by poor fusional convergence amplitudes and a remote near point of convergence (normal fusional vergence amplitudes are given in Chapter 7, Table 7-1). This sometimes results in symptoms of asthenopia, blurred near vision, and diplopia during near work, usually in older children or adults. Convergence insufficiency is a common complication of Parkinson disease. Rarely, accommodative spasms occur when accommodation and convergence are stimulated in an effort to overcome the CI.

Treatment of symptomatic CI typically involves orthoptic exercises. Base-out prisms can be used to stimulate and strengthen fusional convergence amplitudes. Stereograms, “pencil push-ups,” and computer-based or office-based convergence training programs are all viable options. If these exercises fail, base-in prism reading glasses may alleviate symptoms. Surgical treatment, usually medial rectus muscle resection, may be indicated in patients whose problems persist despite medical therapy.

## Constant Exotropia

---

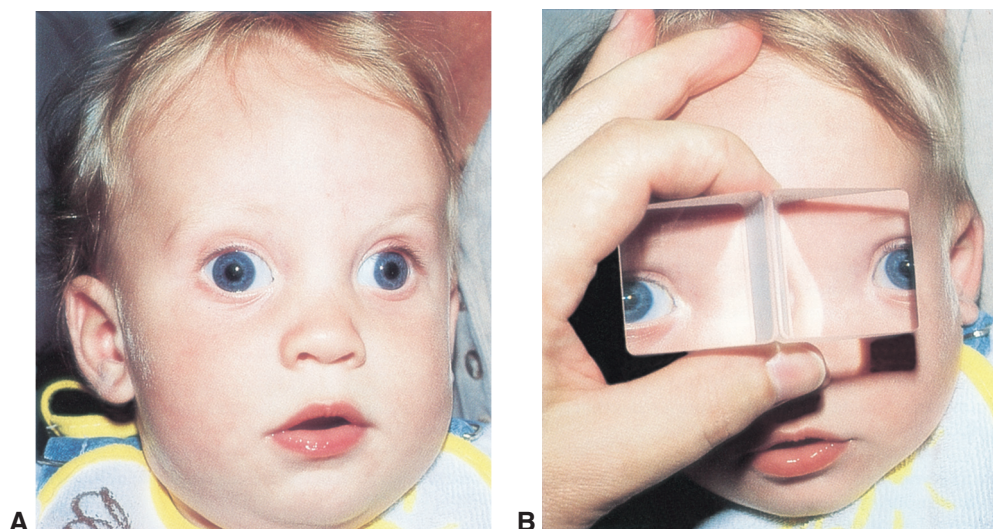
Constant exotropia is encountered most often in older patients with sensory exotropia or in patients with a history of long-standing intermittent exotropia, which has decompensated. Constant exotropia also occurs in persons with infantile or consecutive exotropia. A patient with an exotropia that is constant can have basic, pseudodivergence excess, or true divergence excess exotropia—the same forms seen in intermittent exotropia.

Surgical treatment is the same as that for intermittent exotropia, discussed earlier in the chapter.

Some patients with constant exotropia have an enlarged field of peripheral vision because they have large areas of nonoverlapping visual fields. These patients may notice a field constriction when the eyes are straightened.

## Infantile Exotropia

Infantile exotropia is much less common than infantile esotropia. Constant infantile exotropia is apparent before age 6 months as a large-angle deviation (Fig 9-1). The risk of amblyopia is higher in constant exotropia than in intermittent exotropia. Although infants with constant exotropia may be otherwise healthy, the risk of associated neurologic impairment or craniofacial disorders is increased in these patients. A careful developmental history is thus important, and referral for neurologic assessment should be considered if there are indications of developmental delay. Patients with constant infantile exotropia are operated on early in life, and outcomes are similar to those for infantile esotropia (see Chapter 8). Early surgery can lead to monofixation with gross binocular vision, but



**Figure 9-1** Infantile exotropia. **A**, This 10-month-old infant with infantile exotropia also shows developmental delay. **B**, Krimsky test. Two base-in prisms are used to measure the large exotropia. (Reproduced from Wilson ME. *Exotropia*. Focal Points: Clinical Modules for Ophthalmologists. San Francisco: American Academy of Ophthalmology; 1995, module 11.)

restoration of normal binocular function is rare. Dissociated vertical deviations and over-elevation in adduction may develop (see Chapter 11).

### Sensory Exotropia

Esotropia or exotropia may develop as a result of any condition that severely reduces vision or the visual field in 1 eye. It is not known why some individuals become esotropic and others exotropic after unilateral vision loss. In addition, although both sensory esotropia and sensory exotropia occur in infants and young children, the latter predominates in older children and adults. If the vision in the exotropic eye can be improved, peripheral fusion may be reestablished after surgical realignment, provided the sensory exotropia has not been present for an extended period. Loss of fusional abilities, known as *central fusion disruption*, can lead to constant and permanent diplopia despite anatomical realignment when adult-onset sensory exotropia has been present for several years before vision rehabilitation.

### Consecutive Exotropia

Exotropia that occurs after a period of esotropia is called *consecutive exotropia*. Rarely, exotropia may develop spontaneously in a patient who was previously esotropic and never underwent strabismus surgery. Much more commonly, consecutive exotropia develops after previous surgery for esotropia (*postsurgical exotropia*), usually within a few months or years after the initial surgery. However, in some patients who had surgery for infantile esotropia, consecutive exotropia may not develop until adulthood. Consecutive exotropia may be intermittent or constant.

## Other Forms of Exotropia

### Exotropic Duane Retraction Syndrome

The most widely used classification of Duane retraction syndrome defines 3 types. Patients with type 2 can present with exotropia, usually accompanied by deficient adduction and a head turn away from the affected side. See Chapter 12 for further discussion.

### Neuromuscular Abnormalities

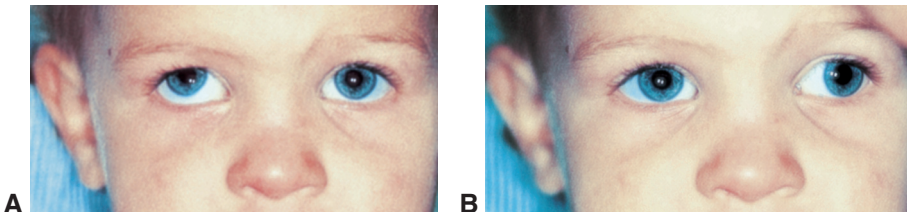
A constant exotropia may result from third nerve palsy, internuclear ophthalmoplegia, or myasthenia gravis. These conditions are discussed in Chapter 12 of this volume and in BCSC Section 5, *Neuro-Ophthalmology*.

### Dissociated Horizontal Deviation

Dissociated strabismus complex may include vertical, horizontal, and/or torsional components (see Chapter 2 and Chapter 11). It may be associated with infantile esotropia. When a dissociated abduction movement is predominant, the condition is called *dissociated horizontal deviation (DHD)*. Though not a true exotropia, DHD can be confused with a constant or intermittent exotropia. Dissociated vertical deviation and latent nystagmus often coexist with DHD (Fig 9-2). In rare cases, patients may manifest both DHD and intermittent esotropia. DHD must be differentiated from anisohyperopia associated with intermittent exotropia, in which the exotropic deviation is present during fixation with the normal eye but is masked during fixation with the hyperopic eye because of accommodative convergence. Treatment of DHD usually consists of unilateral or bilateral lateral rectus recession in addition to any necessary oblique or vertical muscle surgery.

### Convergence Paralysis

Convergence paralysis is distinct from convergence insufficiency and usually secondary to an intracranial lesion, most commonly in association with dorsal midbrain syndrome (see BCSC Section 5, *Neuro-Ophthalmology*). It is characterized by normal adduction and



**Figure 9-2** Dissociated strabismus complex. **A**, When the patient fixates with the left eye, a prominent vertical deviation is observed in the right eye. **B**, However, when the patient fixates with the right eye, a prominent horizontal deviation is noted in the left eye. (Reproduced from Wilson ME. *Exotropia. Focal Points: Clinical Modules for Ophthalmologists*. San Francisco: American Academy of Ophthalmology; 1995, module 11.)

accommodation, with exotropia and diplopia present at attempted near fixation only. Apparent convergence paralysis due to malingering or lack of effort can be distinguished from true convergence paralysis by the absence of pupillary constriction with attempted near fixation.

Treatment of convergence paralysis is difficult and often limited to use of base-in prisms at near to alleviate the diplopia. Plus lenses may be required if accommodation is limited. Monocular occlusion is indicated if diplopia cannot be otherwise treated.

# Pattern Strabismus

*Pattern strabismus* is a horizontal deviation in which there is a difference in the magnitude of deviation between upgaze and downgaze. The term *V pattern* describes a horizontal deviation that is more divergent (less convergent) in upgaze than in downgaze, while the term *A pattern* describes a horizontal deviation that is more divergent (less convergent) in downgaze than in upgaze. An A or V pattern is found in 15%–25% of horizontal strabismus cases. Less common variations of pattern strabismus include Y, X, and  $\lambda$  (lambda) patterns.

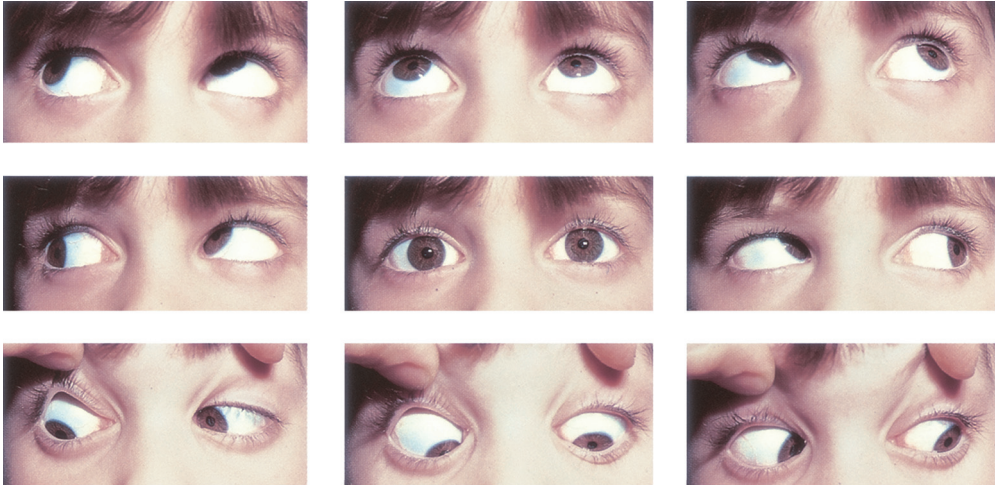## Etiology

---

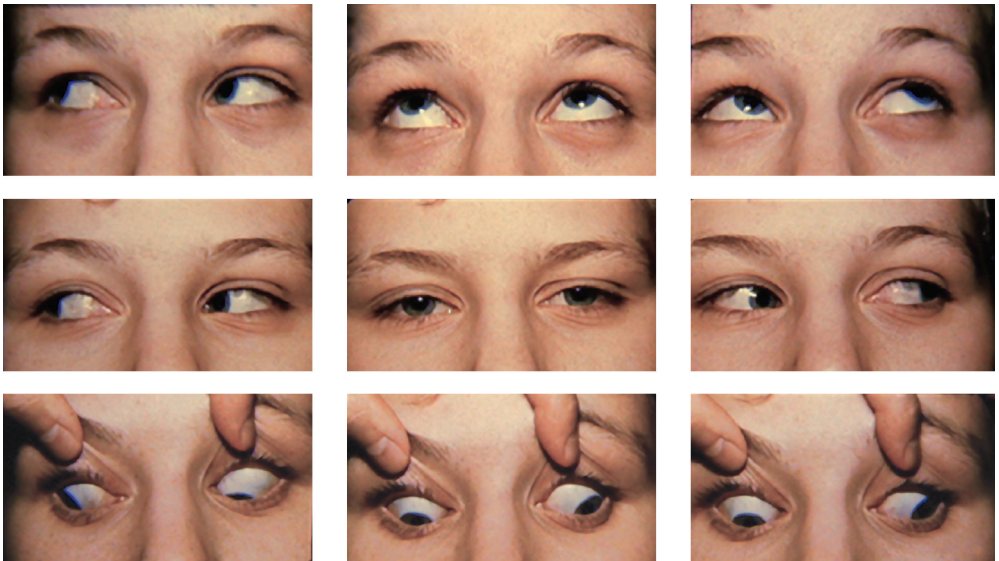The following conditions are associated with various types of pattern strabismus or considered causes of these patterns.

- *Oblique muscle dysfunction.* Apparent inferior oblique muscle overaction (*overelevation in adduction [OEAd]*; see Chapter 11) is associated with V patterns (Fig 10-1), and apparent superior oblique muscle overaction (*overdepression in adduction [ODAd]*) with A patterns (Fig 10-2). These associations may be due to the tertiary abducting action of these muscles in upgaze and downgaze, respectively; however, oblique dysfunction is frequently associated with ocular torsion that can also contribute to A or V patterns (see below).
- *Orbital pulley system abnormalities.* Abnormalities (heterotopia) of the orbital pulley system (see Chapter 3) have been described as a cause of simulated oblique muscle overactions and of altered rectus muscle pathways and functions that can result in A or V patterns. These pulley effects may help explain the observation that patients with upward- or downward-slanting palpebral fissures (Fig 10-3) may show A or V patterns because of an underlying variation in orbital configuration, which is reflected in the orientation of the fissures. Similarly, patients with craniofacial anomalies (see Chapter 18) may have a V-pattern strabismus with marked elevation of the adducting eye as a manifestation of rotation of the orbits, pulley system, and muscle pathways.
- *Ocular torsion.* While not as consequential as pulley dystopia, ocular torsion displaces the anterior path of the vertical rectus muscles. Extorsion displaces the superior rectus muscle temporally and the inferior rectus muscle nasally, which tends to produce a V pattern. Intorsion displaces the superior rectus nasally and the inferior rectus temporally, which tends to produce an A pattern.



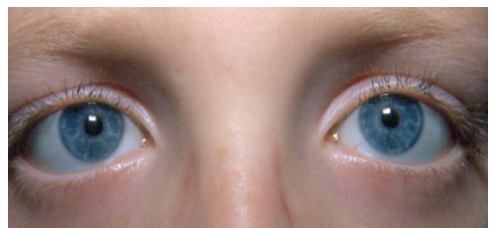

**Figure 10-1** V pattern with exotropia in upgaze and esotropia in downgaze. Note overelevation in adduction and limitation of depression in adduction.



**Figure 10-2** A-pattern exotropia with overdepression and under-elevation in adduction. (Modified with permission from Levin A, Wilson T, eds. *The Hospital for Sick Children's Atlas of Pediatric Ophthalmology and Strabismus*. Philadelphia: Lippincott Williams & Wilkins; 2007:11.)

**Figure 10-3** Palpebral fissures that slant downward temporally, sometimes associated with a V-pattern horizontal deviation. (Courtesy of Edward L. Raab, MD.)



- *Restricted horizontal rectus muscles.* Contracture of the lateral rectus muscles in large-angle exotropia may result in an X pattern, with globe slippage in adduction.
- *Anomalous innervation.* Sometimes seen in isolation and sometimes associated with other congenital cranial dysinnervation disorders (see Chapter 12), this most commonly produces a Y pattern.
- *Selective innervation of superior or inferior compartments of the horizontal rectus muscles.* This is a possible contributing factor to A and V patterns and is under investigation (see Chapter 3).

## Clinical Features and Identification of Pattern Strabismus

---

The presence of A and V patterns is determined by measuring alignment while the patient fixates on an accommodative target at distance, with fusion prevented with the prism alternate cover test, in primary position and in straight upgaze and downgaze, approximately 25° from the primary position. Proper refractive correction is necessary during measurement because an uncompensated accommodative component can induce exaggerated convergence in downgaze. The examiner should look specifically for apparent oblique muscle overaction (OEAd or ODAd) because of its frequent association with pattern strabismus.

An A pattern is considered clinically significant when the difference in measurement between upgaze and downgaze is at least 10 prism diopters ( $\Delta$ ). For a V pattern, this difference must be at least 15 $\Delta$  because there is normally some physiologic convergence in downgaze.

### V Pattern

The most common type of pattern strabismus, V pattern occurs most frequently in patients with infantile esotropia. The pattern is usually not present when the esotropia first develops but becomes apparent during the first year of life or later. V patterns may also occur in patients with superior oblique palsies, particularly if they are bilateral, and in patients with craniofacial malformations.

### A Pattern

A pattern is the second most common type of pattern strabismus and occurs most frequently in patients with exotropia and in persons with spina bifida.

### Y Pattern

Patients with Y patterns (pseudo-overaction of the inferior oblique muscle) have normal ocular alignment in primary position and downgaze, but the eyes diverge in upgaze. These patients appear to have overacting inferior oblique muscles, but the deviation is thought to be due to anomalous innervation of the lateral rectus muscles in upgaze. Clinical characteristics that help identify this form of strabismus include the following: the overelevation is not seen when the eyes are moved directly horizontally, but it becomes manifest when the eyes are directed horizontally and slightly into upgaze; there is no fundus torsion; there is

no difference in vertical deviation with head tilts; and there is no superior oblique muscle underaction.

Kushner BJ. Pseudo inferior oblique overaction associated with Y and V patterns. *Ophthalmology*. 1991;98(10):1500–1505.

## X Pattern

In X-pattern strabismus, an exodeviation is present in primary position and increases in both upgaze and downgaze. This pattern is usually associated with overelevation and overdepression in adduction when the eye moves slightly above or below direct side gaze. X patterns are most commonly seen in patients with large-angle exotropia.

## $\lambda$ Pattern

This rare pattern is a variant of A-pattern exotropia. In  $\lambda$ -pattern strabismus, the horizontal deviation is the same in primary position and upgaze but increases in downgaze. The  $\lambda$  pattern is usually associated with ODAd.

## Management

---

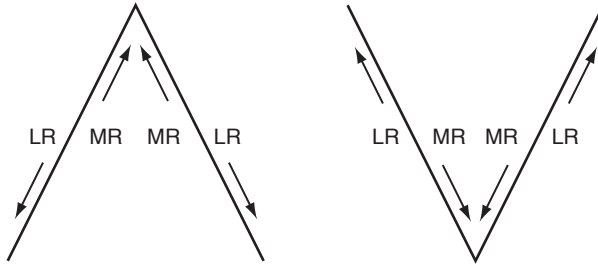
Clinically significant patterns (see the section Clinical Features and Identification of Pattern Strabismus) are typically treated surgically, in combination with correction of the underlying horizontal deviation.

### Surgical Correction of Pattern Deviations: General Principles

The following are strategies for surgical correction of pattern deviations. See Chapter 14 for further discussion of some of the procedures and concepts mentioned here.

- For pattern strabismus associated with apparent overaction of the oblique muscles (OEAd, ODAd), weakening of the oblique muscles is performed.
- For patients with no apparent overaction of the oblique muscles or a pattern inconsistent with oblique dysfunction, vertical transposition of the horizontal muscles is performed. The muscles are transposed from one-half to a full tendon width. The medial rectus muscles are always moved toward the “apex” of the pattern (ie, upward in A patterns and downward in V patterns). The lateral rectus muscles are moved toward the open end (ie, upward in V patterns and downward in A patterns). A useful mnemonic is MALE: *m*edial rectus muscle to the *a*pex, *l*ateral rectus muscle to the *e*mpy space. These rules apply whether the horizontal rectus muscles are weakened or tightened (Fig 10-4).

If transposition of horizontal rectus muscles is used to treat pattern strabismus when there is associated ocular torsion, it will exacerbate the torsion (extorsion with V pattern and intorsion with A pattern), which itself can contribute to the pattern. Conversely, when rectus muscle transposition is used to treat torsion, it will make any associated pattern strabismus worse.



**Figure 10-4** Direction of displacement of medial rectus (MR) and lateral rectus (LR) muscles in procedures to treat A-pattern (*left*) and V-pattern (*right*) deviations. (Reprinted with permission from von Noorden GK, Campos EC. *Binocular Vision and Ocular Motility: Theory and Management of Strabismus*. 6th ed. St Louis: Mosby; 2002:388.)

- When horizontal rectus muscle recession-resection surgery is the preferred choice because of other pertinent factors (eg, prior surgery, unimprovable vision in 1 eye), displacement of the rectus muscle insertions should be in mutually opposite directions, according to the rules stated previously. Unlike what occurs when both horizontal rectus muscles of an eye are moved in the same direction, this displacement has little, if any, vertical effect in the primary position. This procedure should be used with caution in patients with binocular fusion as it can produce symptomatic torsion.
- Some surgeons adjust the amount of horizontal surgery because of the potential effect of oblique muscle weakening on the horizontal deviation, particularly for superior oblique muscle surgery, but this is controversial. Some believe that bilateral superior oblique weakening causes a change of  $10\Delta$ – $15\Delta$  toward convergence in primary position and suggest modifying the amount of horizontal surgery to compensate for this expected change. For inferior oblique muscle weakening procedures, the amount of horizontal rectus muscle surgery does not need to be altered, because the inferior oblique muscle weakening does not substantially change primary position alignment.
- Surgery on the vertical rectus muscles (eg, temporal displacement of the superior rectus muscles for A-pattern esotropia or temporal displacement of the inferior rectus muscles for V-pattern esotropia) is rarely used because transposition of the horizontal rectus muscles that are being operated on for the underlying esotropia or exotropia is usually sufficient.

## Surgical Treatment of Specific Patterns

Table 10-1 summarizes the surgical treatment of pattern strabismus (see also Chapter 14).

### **V pattern**

For V-pattern esotropia or exotropia associated with OEAd, weakening of the inferior oblique muscles is performed. For patients who also have dissociated vertical deviation (DVD; see Chapter 11), anterior transposition of the inferior oblique muscle may improve

**Table 10-1 Surgical Treatment of Pattern Strabismus**

Type of Pattern	Most Common Clinical Association	Treatment		
		With OEAd or ODAd	Without OEAd or ODAd	Other
V Pattern	Infantile esotropia	Weakening of inferior oblique muscles	Vertical transposition of horizontal rectus muscles	If DVD present, anterior transposition of inferior oblique muscles
A Pattern	Exotropia	Weakening of superior oblique muscles	Vertical transposition of horizontal rectus muscles	
Y Pattern	Pseudo-inferior oblique overaction			Superior transposition of lateral rectus muscles
X Pattern	Large-angle exotropia (pseudo-overaction due to contracture of lateral rectus muscles)			Recession of lateral rectus muscles
$\lambda$ Pattern	Variant of A-pattern exotropia	Weakening of superior oblique muscles		

DVD=dissociated vertical deviation; ODAd=overdepression in adduction; OEAd=overelevation in adduction.

both the V pattern and the DVD. Because patients with V-pattern infantile esotropia who are younger than 2 years are at risk of developing DVD, anterior transposition of the inferior oblique may be considered preemptively for this group.

For patients with V-pattern esotropia or exotropia not associated with OEAd, appropriate vertical transposition of the horizontal rectus muscles is performed (see Fig 10-4).

### **A pattern**

For A-pattern exotropia or esotropia associated with ODAd, weakening of the superior oblique muscles is performed. Tenotomy of the posterior 7/8 of the insertions is an effective method for treating up to  $20\Delta$  of A pattern, without a significant effect on torsion. Lengthening of the oblique tendon by recession, insertion of a spacer, or a split-tendon lengthening procedure may also be used to weaken the superior oblique muscles. Bilateral superior oblique tenotomy is a very powerful procedure that may correct up to  $40\Delta$ – $50\Delta$  of A pattern. There is a risk of induced torsion with this procedure, which may be symptomatic for patients with binocular fusion.

For patients with A-pattern exotropia or esotropia not associated with ODAd, appropriate vertical transposition of the horizontal rectus muscles is performed (see Fig 10-4).

***Y pattern***

Because Y patterns are not due to overaction of the inferior oblique muscles, weakening these muscles is not an effective treatment. Superior transposition of the lateral rectus muscles can improve this pattern but does not eliminate it.

***X pattern***

X patterns are usually due to pseudo-overaction of the oblique muscles, which is caused by contracture of the lateral rectus muscles in large-angle exotropia. Recession of the lateral rectus muscles alone usually improves the pattern.

***λ pattern***

As stated earlier, these patterns are typically associated with ODAd. Appropriate superior oblique weakening procedures may be used in patients with this pattern.



# Vertical Deviations



This chapter includes a related video, which can be accessed by scanning the QR code provided in the text or going to [www.aaopt.org/bcscvideo\\_section06](http://www.aaopt.org/bcscvideo_section06).

A vertical deviation can be termed a hyperdeviation of the higher eye or a hypodeviation of the lower, fellow eye. By convention, vertical deviations are named according to the hypertropic eye. However, the term *hypotropia of the nonfixating eye* is used to describe the patient who has a strong fixation preference for the hypertropic eye.

Surgical treatment of these conditions is discussed in Chapter 14.

## A Clinical Approach to Vertical Deviations

---

The evaluation and diagnosis of vertical deviations are complicated by the need to consider *dissociated vertical deviation (DVD)*. In a patient with a completely comitant deviation, there is no movement of either eye on prism alternate cover testing with the same amount of prism used for either eye (prism placed base down over one eye or base up over the other). When there is an incomitant hyperdeviation due to restriction or cyclovertical muscle paresis, the amount of prism needed to neutralize the deviation may be different depending on which eye is fixating. This is the difference between a primary and secondary deviation according to Hering's law (see Chapter 4). Once the neutralizing prism for a given eye is found, however, neither eye moves when alternate cover testing is performed.

In some cases, the examiner encounters a more confusing situation that appears to violate Hering's law. For example, suppose the examiner finds the prism that neutralizes a patient's right hypertropia. That is, if the prism is held over an occluded right eye with the left eye fixating, there is no movement of the right eye when the occluder is moved to the left eye, and fixation switches to the right eye. However, when the occluder is moved back to the right eye, the left eye moves (either upward from a hypotropic position under cover or downward from a hypertropic position) as it resumes fixation. This inability to find a single prism that neutralizes the refixation movement for both eyes indicates the presence of DVD.

Some patients have both "true" hypertropia and DVD. In these patients, there is no way to quantify how much of the deviation is DVD and how much is true hypertropia, although several estimation methods have been advocated. Often, however, one is predominant and



the other, smaller component can be ignored. For the sake of simplicity, this chapter does not discuss true hypertropia and DVD in combination but only as separate entities.

## Vertical Deviations With Marked Horizontal Incomitance

---

Many vertical deviations are characterized by a hypertropia that is much greater on gaze to one side. They are often, but not exclusively, associated with oblique muscle abnormalities.

### Overelevation and Overdepression in Adduction

There are several causes of overelevation in adduction (OEAd) and overdepression in adduction (ODAd) (Tables 11-1, 11-2). These include true overaction and underaction of the oblique muscles, as well as several conditions that can simulate oblique muscle overactions. These cases have also been termed *oblique muscle pseudo-overactions*.

In some patients, such as those with large-angle exotropia or thyroid eye disease, clinical examination of versions appears to show overaction of both the superior and the inferior oblique muscles. In such cases, elevation or depression of the vertical rectus muscle of the opposite, abducting eye is restricted in the lateral portion of the bony orbit. The clinical findings can be explained as an attempt by the vertical rectus muscle to overcome this restriction through extra innervation, which, according to Hering's law, is distributed to the yoke oblique muscle as well (see Chapter 4). Alternatively, overelevation may be due to slippage of a tight lateral rectus muscle as the eye adducts and rises above or below the midline (see Chapter 10).

---

**Table 11-1 Causes of Overelevation in Adduction**

---

Inferior oblique muscle overaction (primary or secondary)
Dissociated vertical deviation
Large-angle exotropia
Rectus muscle pulley heterotopia
Orbital dysmorphism (eg, craniofacial syndromes)
Duane retraction syndrome
Anti-elevation syndrome after contralateral inferior oblique muscle anterior transposition
Contralateral inferior rectus muscle restriction (eg, after orbital floor fracture, in thyroid eye disease)
Skew deviation

---



---

**Table 11-2 Causes of Overdepression in Adduction**

---

Superior oblique muscle overaction (primary or secondary)
Large-angle exotropia
Rectus muscle pulley heterotopia
Orbital dysmorphism (eg, craniofacial syndromes)
Duane retraction syndrome
Brown syndrome (rarely)
Contralateral superior rectus muscle contracture (eg, after muscle resection)
Skew deviation

---

Malposition of the rectus muscle pulleys can lead to anomalous movements that can simulate oblique muscle overactions. This can be seen in craniofacial syndromes. For example, an inferiorly displaced lateral rectus muscle pulley can cause depression in abduction or, if this is the fixating eye, OEAd of the contralateral eye and a V-pattern deviation that simulate inferior oblique muscle overaction. Conversely, a superiorly displaced lateral rectus muscle can produce ODAd—simulating a superior oblique overaction—along with an A-pattern deviation. Lateral and medial malpositioning of vertical rectus muscles can also create pseudo-overactions of oblique muscles. The treatment implication is that apparent oblique dysfunction or A and V patterns associated with anomalous pulley positions respond poorly to oblique muscle surgery.

Other causes of OEAd and ODAd include the upshoots and downshoots of Duane retraction syndrome, superior or inferior rectus muscle restriction (causing extra innervation of contralateral oblique muscles), limitation of elevation in abduction after inferior oblique anterior transposition (anti-elevation syndrome), and rare cases of Brown syndrome.

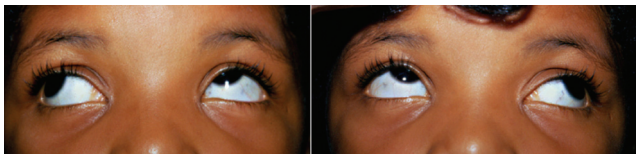### ***Inferior oblique muscle overaction***

Overaction of the inferior oblique muscle is one cause of OEAd. The overaction is termed *primary* when it is not associated with superior oblique muscle palsy. It is called *secondary* when it accompanies palsy of the superior oblique muscle or the contralateral superior rectus muscle. The eye is elevated in adduction, both on horizontal movement and in upgaze (Fig 11-1).

One explanation of primary overaction relates to vestibular factors governing postural tonus of the extraocular muscles. Some authors have questioned whether primary inferior oblique overaction truly exists, preferring to describe the movement merely as OEAd.

**Clinical features** Primary inferior oblique muscle overaction has been reported to develop between ages 1 and 6 years in up to two-thirds of patients with infantile strabismus (esotropia or exotropia). It also occurs, less frequently, in association with acquired esotropia or exotropia and, occasionally, in patients with no other strabismus. Bilateral overaction can be asymmetric, often in patients with poor vision in 1 eye, which leads to greater overaction in that eye.

With the eyes in lateral gaze, alternate cover testing shows that the higher (adducting) eye refixates with a downward movement and that the lower (abducting) eye refixates with an upward movement. When inferior oblique muscle overaction is bilateral, the higher and lower eyes reverse their direction of movement in the opposite lateral gaze. These features differentiate inferior oblique overaction from DVD, in which neither eye refixates



**Figure 11-1** Bilateral inferior oblique muscle overaction. Overelevation in adduction, seen best in the upper fields of gaze. (Courtesy of Edward L. Raab, MD.)

with an upward movement, whether adducted, abducted, or in primary position. A V-pattern horizontal deviation (see Chapter 10) and extorsion are common with overacting inferior oblique muscles.

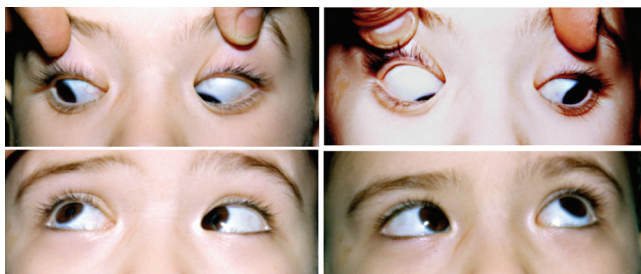**Management** For cases in which inferior oblique overaction produces a functional problem—V-pattern strabismus, hypertropia in primary position, or symptomatic hypertropia in side gaze—a procedure to weaken the inferior oblique muscle (recession, disinsertion, myectomy, or anterior transposition) is indicated. Some surgeons grade the weakening procedure according to the severity of the overaction. Weakening of the inferior oblique muscles generally has an insignificant effect on horizontal alignment in primary position.

### **Superior oblique muscle overaction**

Superior oblique muscle overaction is one of several causes of ODAd.

**Clinical features** A vertical deviation in primary position often occurs with unilateral or asymmetric bilateral overaction of the superior oblique muscles. The lower eye has the overacting superior oblique muscle in unilateral overaction and the more prominently overacting superior oblique in bilateral cases. The overacting superior oblique muscle causes a hypotropia of the adducting eye, which is accentuated in the lower field of gaze (Fig 11-2). A horizontal deviation, most often exotropia, may be present and may lead to an A pattern (see Chapter 10). Intorsion is common with superior oblique muscle overaction. Most cases of bilateral superior oblique overaction are primary overactions.

**Management** In a patient with clinically significant hypertropia or hypotropia or an A pattern, a procedure to weaken the superior oblique tendon (recession, tenotomy, tenectomy, or lengthening by insertion of a silicone spacer or nonabsorbable suture or by split-tendon lengthening) is appropriate. Significant intorsion will also be reduced with any of these procedures. Many surgeons are reluctant to perform superior oblique tendon weakening in patients with fusion because torsional or asymmetric vertical effects can cause diplopia. As with inferior oblique muscle overaction, the horizontal deviation can be corrected during the same operative session. Some surgeons, anticipating a convergent effect in primary position, alter the amount of horizontal rectus muscle surgery when simultaneously weakening the superior oblique muscles.



**Figure 11-2** Top row, Bilateral superior oblique muscle overaction. Overdepression in adduction, seen best in the lower fields of gaze. Bottom row, Associated bilateral inferior oblique underaction. (Courtesy of Edward L. Raab, MD.)

## Superior Oblique Muscle Palsy

The most common paralysis of a single cyclovertical muscle is fourth nerve (trochlear) palsy, which involves the superior oblique muscle. The palsy can be congenital or acquired; if the latter, it is usually a result of closed head trauma or, less commonly, vascular problems of the central nervous system, diabetes mellitus, or a brain tumor. Direct trauma to the tendon or the trochlear area is an occasional cause of unilateral superior oblique muscle palsy. Results of one study showed that most patients with congenital superior oblique muscle palsy had an absent ipsilateral trochlear nerve and varying degrees of superior oblique muscle hypoplasia.

The same clinical features (discussed in the next section) can be observed when there is a congenitally lax, attenuated, or even absent superior oblique tendon or an unusual course of the muscle, or when there are malpositioned orbital pulleys—although, strictly speaking, these are not paralytic entities. Superior oblique muscle underaction can also occur in several craniofacial abnormalities (see Chapter 18).

To differentiate congenital from acquired superior oblique muscle palsy, the clinician can examine childhood photographs of the patient for a preexisting compensatory head tilt, although manifestations of congenital palsy sometimes become apparent only later in life. The presence of a large vertical fusional amplitude supports a diagnosis of congenital superior oblique palsy, whereas associated neurologic disorders suggest an acquired condition. Facial asymmetry from long-standing head tilting indicates chronicity. Diagnostic evaluation, including neuroimaging, often fails to identify an etiology but may still be warranted for acquired superior oblique palsy without a history of trauma. Neurologic aspects of superior oblique muscle palsy are discussed in BCSC Section 5, *Neuro-Ophthalmology*.

Yang HK, Kim JH, Hwang JM. Congenital superior oblique palsy and trochlear nerve absence: a clinical and radiological study. *Ophthalmology*. 2012;119(1):170–177.

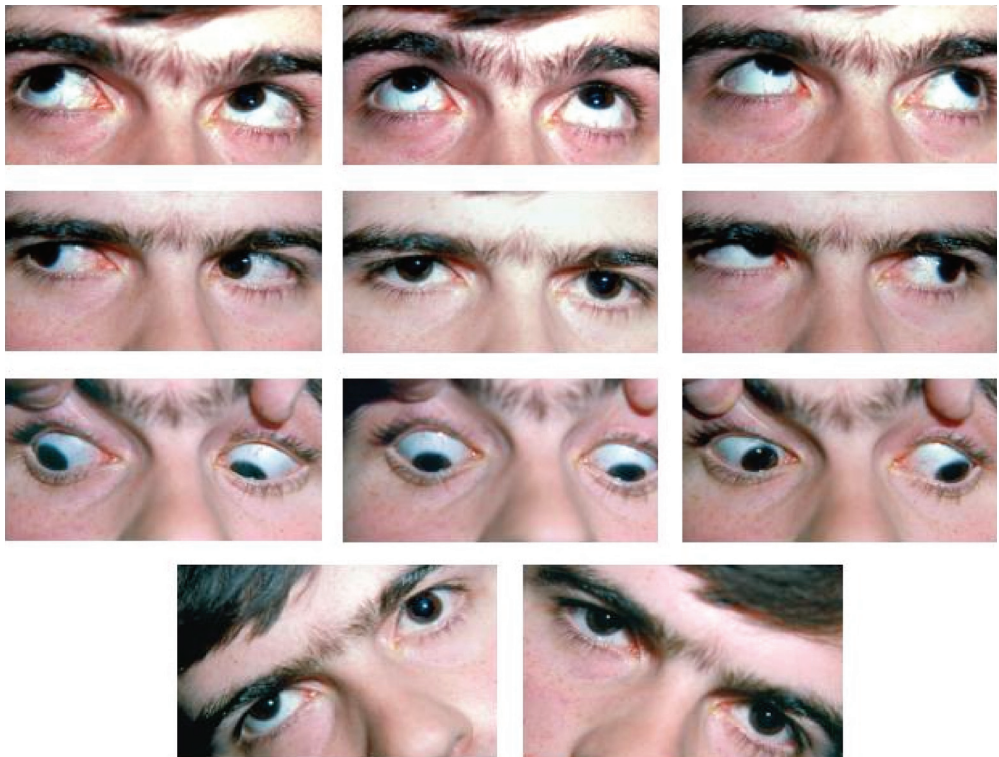### **Clinical features, evaluation, and diagnosis**

Either the normal or the affected eye can be preferred for fixation. Examination of versions usually reveals underaction of the involved superior oblique muscle and overaction of its antagonist inferior oblique muscle; however, the action of the superior oblique muscle can appear normal.

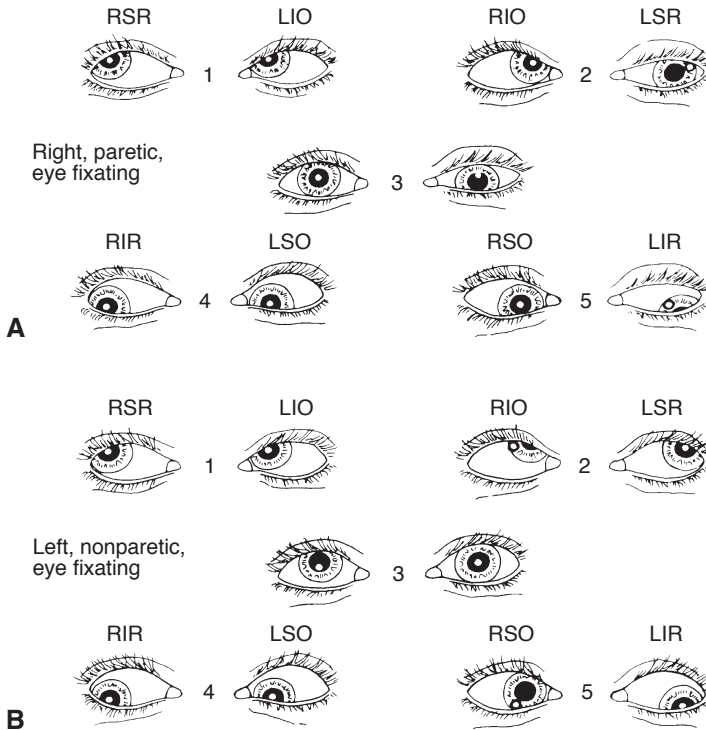
**Unilateral superior oblique palsy** In a unilateral palsy, the hyperdeviation is typically incomitant, especially in the acute stages. Over time, contracture of the ipsilateral superior rectus or contralateral inferior rectus muscle can lead to “spread of comitance,” with the result that there is minimal difference in the magnitude of the hypertropia when the patient looks from one side to the other. If depression cannot be evaluated because of the eye’s inability to adduct (eg, in third nerve palsy), superior oblique muscle function can be evaluated by observing whether the eye intorts, as judged by the movement of surface landmarks or examination of the fundus, when the patient attempts to look downward and inward from primary position. Weakness of the superior oblique muscle also results in extorsion of the eye. If the degree of extorsion is large enough, subjective incyclodiplopia, in which the patient describes the image as appearing to tilt inward, can occur.

The diagnosis of unilateral superior oblique muscle palsy is further established by results of the 3-step test (also called the *Parks-Bielschowsky 3-step test*) (Fig 11-3; see also Chapter 7, Fig 7-8) and the double Maddox rod test to measure torsion. However, results of the 3-step test can be confounded in patients with DVD, entities involving restriction, additional paretic muscles, previous strabismus surgery, or skew deviation. Intorsion of the higher eye on fundus examination—instead of the expected extorsion—suggests skew deviation, especially when there are associated neurologic findings. In addition, if the patient is placed in a supine position, the vertical tropia is more likely to decrease with skew deviation than with superior oblique palsy. Some ophthalmologists document serial changes in the deviation by means of the Hess screen or the Lancaster red-green test or by plotting the field of single binocular vision. (See Chapter 7 for further discussion of some of the tests mentioned in this section.)

**INHIBITIONAL PALSY OF THE CONTRALATERAL ANTAGONIST** Patients who fixate with the paretic eye can exhibit so-called *inhibitional palsy of the contralateral antagonist* (Fig 11-4). If a patient with right superior oblique palsy uses the right eye to fixate on an object that is located up and to the left, the innervation of the right inferior oblique muscle required to



**Figure 11-3** Right superior oblique palsy. There is a right hypertropia in primary position that increases in left gaze and with head tilt to the right. Note accompanying overaction of the right inferior oblique muscle. (Courtesy of Edward L. Raab, MD.)



**Figure 11-4** Palsy of right superior oblique muscle. **A**, With the palsied right eye fixating, little or no vertical difference appears between the 2 eyes in the right field of gaze (1 and 4). In primary position (3), a left hypotropia may be present because the right elevators require less innervation to stabilize the eye in primary position, and thus the left elevators will receive less-than-normal innervation. When gaze is up and left (2), the RIO needs less-than-normal innervation to elevate the right eye because its antagonist, the RSO, is palsied. Consequently, its yoke, the LSR, will be apparently underacting, and pseudoptosis with pseudopalsy of the LSR will be present. When gaze is toward the field of action of the palsied RSO muscle (5), maximum innervation is required to move the right eye down during adduction, and thus the yoke LIR will be overacting. **B**, With the unaffected left eye fixating, no vertical difference appears in the right field of gaze (1 and 4). In primary position (3), the right eye is elevated because of unopposed elevators. When gaze is up and left (2), the RIO shows marked overaction because its antagonist is palsied. The action of the LSR is normal. When gaze is down and left (5), normal innervation required by the fixating normal eye does not suffice to fully move the palsied eye into that field of gaze. (See also Chapter 7, Fig 7-8.) LIO = left inferior oblique; LIR = left inferior rectus; LSO = left superior oblique; LSR = left superior rectus; RIO = right inferior oblique; RIR = right inferior rectus; RSO = right superior oblique; RSR = right superior rectus. (Reproduced with permission from von Noorden GK. Atlas of Strabismus. 4th ed. St Louis: Mosby; 1983:24–25.)

move the eye into this gaze position is reduced because the right inferior oblique muscle does not have to overcome the normal antagonistic effect of the right superior oblique muscle (Sherrington's law). According to Hering's law, less innervation is also received by the yoke muscle of the right inferior oblique muscle, which is the left superior rectus muscle. This decreased innervation can lead to the impression that the left superior rectus muscle is paretic.

**Bilateral superior oblique palsy** Bilateral superior oblique palsy occurs commonly after head trauma but is sometimes congenital. It can be differentiated from unilateral superior oblique muscle palsy by the following criteria:

- *Unilateral* cases usually show little if any V pattern and less than 10° of extorsion in downgaze. Subjective incyclodiplopia is uncommon. The Bielschowsky head-tilt test (step 3 of the 3-step test) yields positive results for the involved side only. Abnormal head positions—usually a tilt toward the shoulder opposite the side of the weakness—are common. The oblique muscle dysfunction is confined to the involved eye.
- *Bilateral* cases usually show a V pattern. Extorsion is 10° or more in downgaze; more than 15° of extorsion in primary position is highly suggestive of bilateral involvement. Subjective incyclodiplopia is common in acquired bilateral cases. The Bielschowsky head-tilt test yields positive results on tilt to each side—that is, right head tilt produces a right hypertropia and left head tilt, a left hypertropia. There is bilateral oblique muscle dysfunction. Patients may exhibit a chin-down head position. Symmetric palsies may show little or no hypertropia in primary position.

**MASKED BILATERAL SUPERIOR OBLIQUE PALSY** Markedly asymmetric bilateral superior oblique palsy that initially appears to be unilateral is called *masked bilateral palsy*. Signs of masked bilateral palsy include bilateral objective fundus extorsion, esotropia in downgaze, and even the mildest degree of oblique muscle dysfunction on the presumably uninvolved side. Masked bilateral palsy is more common in patients with head trauma. Surgical overcorrection of unilateral superior oblique palsy can produce a pattern of hypertropia and 3-step-test findings similar to those of superior oblique palsy in the contralateral eye and should not be mistaken for masked bilateral palsy.

### **Management**

For small, symptomatic deviations that lack a prominent torsional component—especially those that have become comitant—prisms that compensate for the hyperdeviation in primary position may be used to overcome diplopia. Abnormal head position, significant vertical deviation, diplopia, and asthenopia are indications for surgery. Common operative strategies are discussed in the following sections (see Chapter 14 for details of the procedures and for related videos).

**Unilateral superior oblique muscle palsy** There are many options for surgical treatment of a unilateral palsy. Any of the 4 cyclovertical muscles in each eye could potentially be operated on to correct the hypertropia. Some surgeons use a uniform approach and weaken the ipsilateral antagonist inferior oblique muscle. For other surgeons, the surgical plan is informed by superior oblique tendon laxity. Tendon laxity is assessed at the time of surgery by forced duction testing, in which the globe is pushed (translated) posteriorly into the orbit while it is simultaneously extorted, thus placing the superior oblique tendon on stretch (Video 11-1). If the tendon is lax, they perform a superior oblique tightening procedure; if it is not, they usually perform an inferior oblique weakening procedure. Other ophthalmologists use tendon laxity only as diagnostic confirmation of superior oblique palsy.



**VIDEO 11-1** Oblique muscle forced duction testing.  
Access all Section 6 videos at [www.aao.org/bcscvideo\\_section06](http://www.aao.org/bcscvideo_section06).



Many surgeons take a tailored approach, reflecting the variety of hypertropia patterns that may occur with superior oblique palsy. For example, if underaction of an affected right superior oblique muscle is the most prominent feature, then the deviation will be greatest in down-left gaze. Another patient, by contrast, may predominantly exhibit overaction of the antagonist inferior oblique muscle, with the greatest deviation in up-left gaze. Because each of the 8 cyclovertical muscles has a somewhat different field of action, surgery involving some muscles will be more appropriate than others, depending on the field of gaze in which the deviation is largest (Table 11-3). In addition, some surgeons believe that superior oblique tightening is the most effective procedure for addressing a marked head tilt in children with congenital superior oblique palsy. Extorsion in unilateral superior oblique palsy rarely produces symptoms, but when it does, it can be corrected with a Harada-Ito procedure.

If the hyperdeviation is greater than 15 prism diopters ( $\Delta$ ) in primary position, surgery usually involves at least 2 muscles. Ipsilateral inferior oblique weakening and superior oblique tightening represent a particularly powerful combination but carry an increased risk of problematic iatrogenic Brown syndrome or overcorrection. In the unusually severe case with a vertical deviation greater than  $35\Delta$  in primary position, 3-muscle surgery is usually required.

Whatever the approach, it is important to avoid overcorrection of a long-standing unilateral superior oblique muscle palsy. Because there are often no sensory or motor adaptations to hypertropia in the opposite direction, disabling diplopia can result.

**Bilateral superior oblique muscle palsy** Surgical planning for treatment of bilateral superior oblique muscle palsy can be complex. If the paresis is asymmetric, hypertropia in primary position may be present and require many of the same considerations as hypertropia in unilateral palsy. In addition, there is often symptomatic extorsion or a V pattern that needs to be addressed.

If the palsies are symmetric (minimal hypertropia in primary position), both inferior oblique muscles can be weakened if they are overacting and hypertropia is present in side gaze. Bilateral superior oblique muscle tightening should be performed when hypertropia

**Table 11-3 Surgical Treatment of Unilateral Superior Oblique Palsy**

Characteristic	Difference in Hypertropia Between Right and Left Gaze	
	Large ( $>15\Delta$ )	Moderate ( $<15\Delta$ )
Greater deviation in (contralateral) upgaze	Inferior oblique weakening	Inferior oblique weakening Ipsilateral superior rectus recession Contralateral superior rectus tightening (rarely)
Greater deviation in (contralateral) downgaze	Superior oblique tightening	Contralateral inferior rectus recession Ipsilateral superior rectus recession (if restricted)

$\Delta$  = prism diopters.



in side gaze is accompanied by V-pattern esotropia or symptomatic extorsion, especially in downgaze. If there is symptomatic extorsion but minimal hypertropia in side gaze, bilateral Harada-Ito procedures can be performed. Other, less commonly used approaches, such as bilateral inferior rectus muscle recessions, serve to add extra innervational drive on downgaze to help overcome the superior oblique deficits.

### Inferior Oblique Muscle Palsy

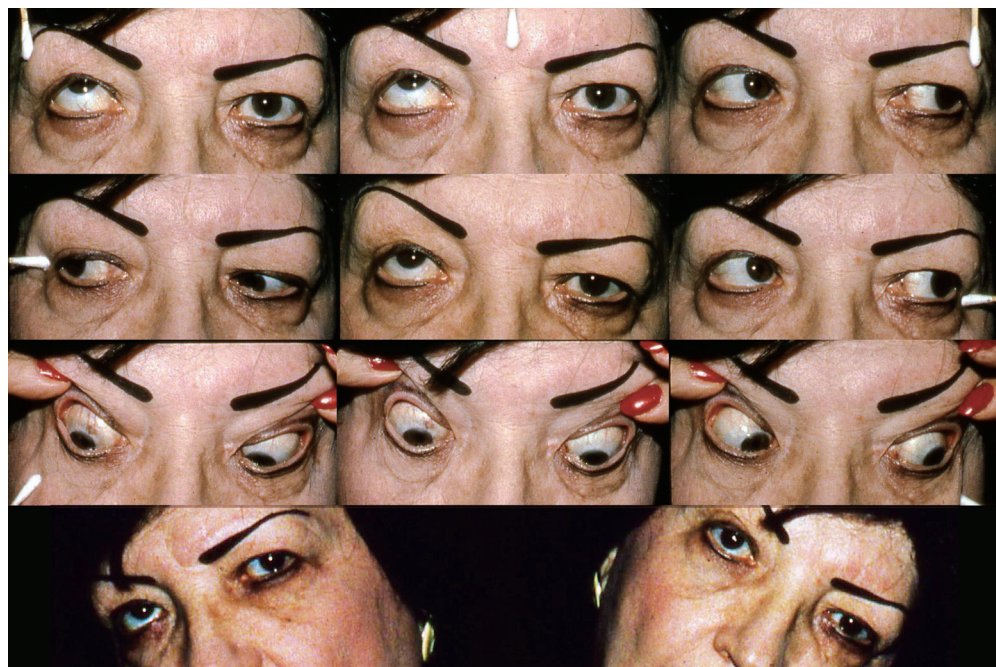Whether inferior oblique muscle palsy (Fig 11-5) actually exists has been questioned. Most cases are considered to be congenital or posttraumatic.

#### *Clinical features*

Inferior oblique palsy is suspected when the patient has hypotropia and 3-step-test results consistent with this diagnosis. As with Brown syndrome, a prominent feature is deficient elevation when the eye is in adduction. The features that distinguish inferior oblique palsy from Brown syndrome are listed in Table 11-4.

#### *Management*

Indications for treatment of inferior oblique muscle palsy are abnormal head position, vertical deviation in primary position, and diplopia. Management consists of weakening either the ipsilateral superior oblique muscle or the contralateral superior rectus muscle.



**Figure 11-5** Left inferior oblique palsy. When the patient fixates with the paretic eye, there is a right hypertropia in primary position that is also most prominent in right gaze and with head tilt to the right—the 3-step test is consistent with this diagnosis. This patient had no abnormal neurologic findings. (Courtesy of Steven M. Archer, MD.)

**Table 11-4 Comparison of Inferior Oblique Muscle Palsy and Brown Syndrome**

Features	Inferior Oblique Muscle Palsy	Brown Syndrome
Forced duction test	Negative	Positive
Strabismus pattern	A pattern	None or V pattern
Superior oblique muscle overaction	Usually significant	None or minimal
Torsion	Intorsion	None
Head-tilt test	Positive	Negative

### Skew Deviation

Skew deviation is an acquired vertical strabismus that can mimic superior or inferior oblique palsy. The deviation is due to peripheral or central asymmetric disruption of supranuclear input from the otolith organs. Intorsion of the hypertropic eye on fundus examination—rather than the expected extorsion in superior oblique palsy—suggests skew deviation, particularly when there are associated neurologic findings. In addition, if the patient is placed in a supine position, the vertical tropia is more likely to decrease with skew deviation than with superior oblique palsy. Similarly, if there is extorsion of the hypotropic eye on fundus examination—instead of the expected intorsion in inferior oblique palsy—then skew deviation is the likely diagnosis. See BCSC Section 5, *Neuro-Ophthalmology*, for additional discussion.

### Other Conditions With Incomitant Vertical Deviations

Incomitant hypertropia may occur in several other conditions. These include innervational problems, such as third nerve palsy with aberrant regeneration and the upshoots and downshoots in Duane retraction syndrome, and mechanical disorders, such as Brown syndrome and thyroid eye disease or those due to orbital tumors and orbital implants (eg, tube shunts, scleral buckles). These topics are discussed elsewhere in this book and in other BCSC volumes.

### Vertical Deviations With Horizontal Comitance

Most patients with vertical deviations demonstrate some lateral incomitance. However, in vertical deviations not associated with apparent oblique muscle dysfunction, the difference between the deviations in right gaze and left gaze is usually less than  $10\Delta$ .

### Monocular Elevation Deficiency

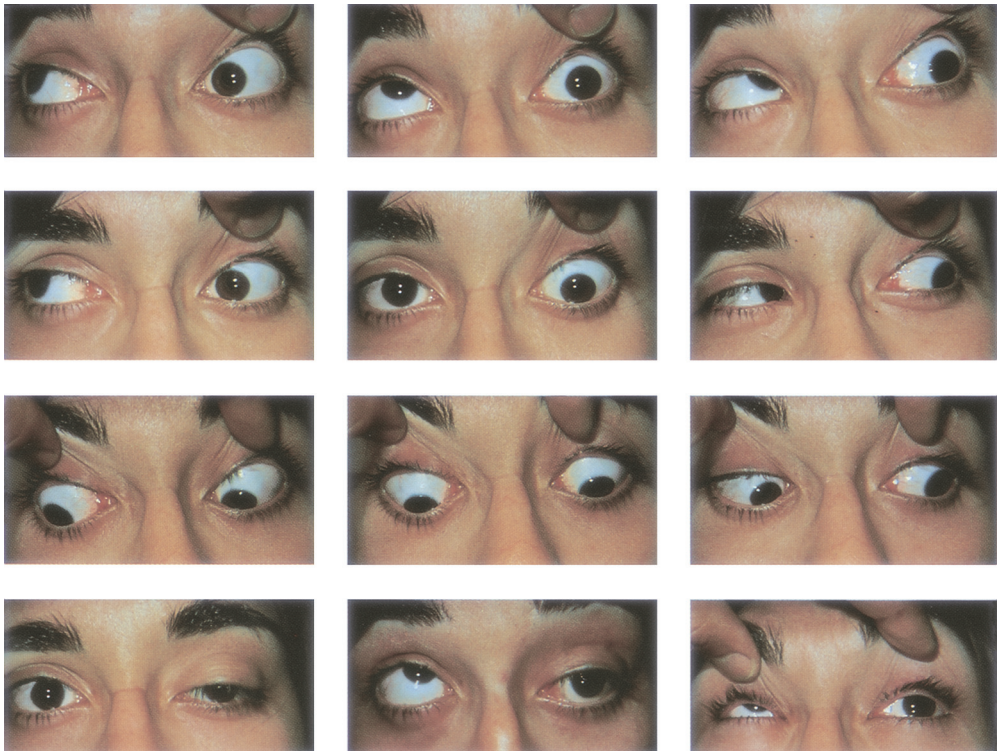Monocular elevation deficiency (previously termed *double-elevator palsy*) involves a limitation of upward gaze with a hypotropia that is similar in adduction and abduction. There are 3 forms of this motility pattern, each with a different cause: restriction of the inferior rectus muscle; deficient innervation of elevator muscles (paresis of 1 or both elevator muscles or a monocular supranuclear gaze disorder); a combination of restriction and elevator muscle deficit.

**Clinical features**

All 3 forms of monocular elevation deficiency are characterized by hypotropia of the involved eye with limited elevation, a chin-up head position with binocular fusion in downgaze, and ptosis or pseudoptosis (Fig 11-6). True ptosis is present in 50% of affected patients. These are features of third nerve palsy, as well. Therefore, if any other feature of third nerve palsy is present, that condition should be suspected rather than monocular elevation deficiency.

The clinical features of each form of monocular elevation deficiency are as follows:

- restriction
  - positive forced duction on elevation
  - normal force generation and saccadic velocity (no muscle paralysis)
  - often an extra or deeper lower eyelid fold on attempted upgaze
  - poor or absent Bell phenomenon



**Figure 11-6** Monocular elevation deficiency of the left eye. *Top row*, No voluntary elevation of the left eye above horizontal. *Second row*, Hypotropia of the left eye across the horizontal fields of gaze. *Third row*, Depression of the left eye is unaffected. *Bottom row, left*, Ptosis (true and pseudo-) of the left upper eyelid during fixation with the right eye (in the top 3 rows, the left upper eyelid is elevated manually). *Bottom row, center*, Persistence of ptosis and marked secondary overelevation of the right eye during fixation with the left eye. *Bottom row, right*, Bell phenomenon, with the left eye elevating above the horizontal on forced eyelid closure.

- elevator muscle innervational deficit
  - negative forced duction on elevation
  - reduced force generation and saccadic velocity
  - preservation of Bell phenomenon (indicating a supranuclear cause) in many cases
- combination of restriction and elevator muscle deficit
  - positive forced duction on elevation
  - reduced force generation and saccadic velocity

In support of this classification, studies using magnetic resonance imaging have shown either focal thickening of the inferior rectus muscle, supporting a restrictive etiology, or normal ocular motor nerves, suggesting a central unilateral disorder of upgaze.

Kim JH, Hwang JM. Congenital monocular elevation deficiency. *Ophthalmology*. 2009;116(3):580–584.

### **Management**

Indications for treatment include a large vertical deviation in primary position, with or without ptosis, and an abnormal chin-up head position. If restriction originating inferiorly is present, the inferior rectus muscle should be recessed. If there is no restriction, the medial and lateral rectus muscles can be transposed toward the superior rectus muscle (*Knapp procedure*). Alternatively, the surgeon can recess the ipsilateral inferior rectus and either recess the contralateral superior rectus muscle or resect the ipsilateral superior rectus muscle. Ptosis surgery should be deferred until the vertical deviation has been corrected and the pseudoptosis component eliminated.

### **Orbital Floor Fractures**

Clinical features and management of orbital floor fractures are discussed in Chapter 27 of this volume and in BCSC Section 7, *Oculofacial Plastic and Orbital Surgery*. The discussion in this chapter focuses on motility abnormalities in patients with these fractures.

#### **Clinical features**

Diplopia in the immediate postinjury stage is common and not necessarily an indication for urgent intervention. Indications and timing for surgical repair are discussed in Chapter 27 of this volume and in BCSC Section 7, *Oculofacial Plastic and Orbital Surgery*. Depending on the site of the bony trauma, muscles can be either restricted due to entrapment or paretic due to muscle contusion or nerve damage. “Flap tears” of the inferior rectus muscle have also been described by some authors as a cause of limitation of elevation, depression, or both. Paresis of a muscle may resolve over several months. If the fracture requires surgery, the range of eye movements may improve. By contrast, fibrosis after trauma may cause restriction to persist even after successful repair of the fracture.

#### **Management**

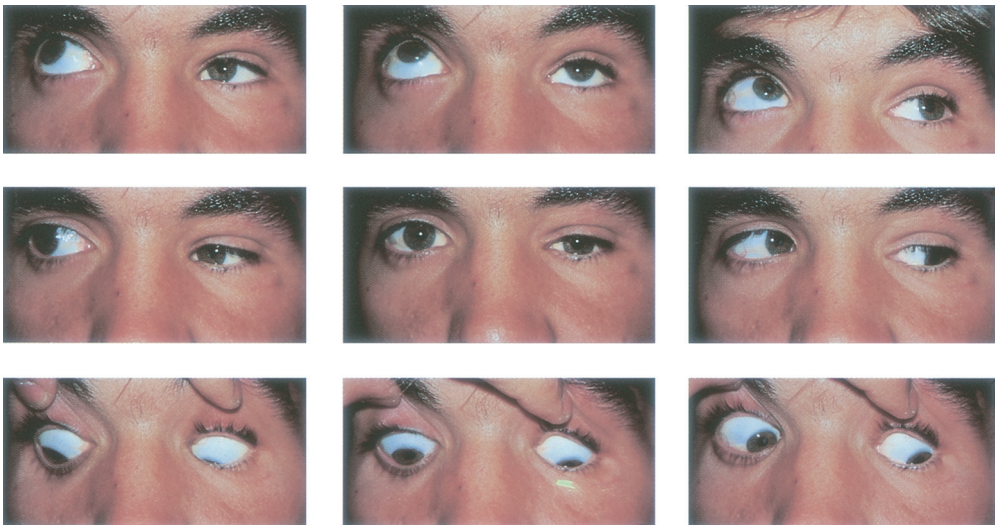
Treatment of strabismus is usually necessary when diplopia persists in primary position or downgaze or there is an associated compensatory head position. Some mild limitations of eye movements can be managed with prisms.

Planning of eye muscle surgery depends on the fields where diplopia is present and on the relative contributions of muscle restriction and paresis. Any flap tear discovered on exploration of the inferior rectus muscle should be repaired. For hypotropia in primary position (Fig 11-7), recession of the ipsilateral inferior rectus muscle can be effective, especially if the muscle is restricted on forced duction testing. Similarly, an incomitant esotropia (with diplopia on side gaze) due to restriction on the medial side may be improved by recession of the ipsilateral medial rectus muscle.

Initially, hypertropia due to weakness of the inferior rectus muscle without entrapment is managed with observation because the weakness may improve with time. If recovery is not complete within 6–12 months of the injury and there is at least a moderate degree of active force, resection of the affected muscle can be performed. If the hypertropia is large, the procedure can be combined with recession of the ipsilateral superior rectus muscle or recession of the contralateral inferior rectus muscle, with or without the addition of a posterior fixation suture (*fadenoperation*). Transposition of the ipsilateral medial and lateral rectus muscles to the inferior rectus muscle (*inverse Knapp procedure*) may be necessary for treatment of complete, chronic inferior rectus muscle palsy or when a crippling amount of recession has been necessary to relieve restriction.

### Other Conditions With Comitant Vertical Deviations

Other conditions and disorders featuring a hypertropia that does not change markedly from right to left gaze include innervational problems, such as superior division (partial) palsy of the third cranial nerve; and mechanical disorders, such as thyroid eye disease, congenital fibrosis of the extraocular muscles, and orbital tumors. These topics are discussed elsewhere in this volume and in other BCSC Sections.



**Figure 11-7** Old orbital floor fracture, left eye, with inferior rectus muscle entrapment. Note limitation of elevation of the left eye and pseudoptosis from enophthalmos. The eyelids are elevated manually in the bottom row.

## Dissociated Vertical Deviation

Dissociated vertical deviation (DVD) is an innervational disorder found in more than 50% of patients with infantile strabismus (esotropia or exotropia). There are 2 explanations for the origin of DVD. One theory is that DVD is a vertical vergence movement to damp latent nystagmus, with the oblique muscles playing the principal role. An alternative theory suggests that deficient fusion allows the primitive dorsal light reflex, which is prominent in other species, to emerge.

Brodsky MC. Dissociated vertical divergence: a righting reflex gone wrong. *Arch Ophthalmol*. 1999;117(9):1216–1222.

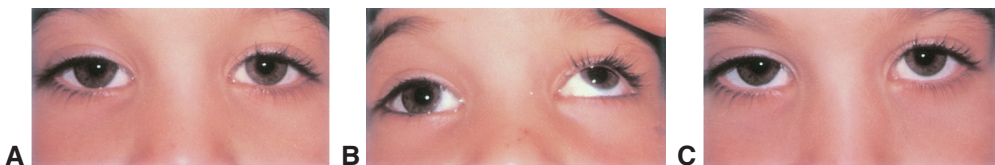Guyton DL. Ocular torsion reveals the mechanisms of cyclovertical strabismus: the Weisenfeld lecture. *Invest Ophthalmol Vis Sci*. 2008;49(3):847–857.

### Clinical Features

Dissociated vertical deviation usually presents by age 2 years, whether or not any horizontal deviation has been surgically corrected. Either eye slowly drifts upward and outward, with simultaneous extorsion, when occluded or during periods of visual inattention (Fig 11-8). Some patients attempt to compensate by tilting the head, for reasons that still have not been conclusively identified.

DVD is usually the most prominent component of the *dissociated strabismus complex* (DSC), but sometimes the principal dissociated movement is one of abduction (*dissociated horizontal deviation, DHD*), and occasionally it is almost entirely a torsional movement (*dissociated torsional deviation, DTD*). DVD is usually bilateral but is frequently asymmetric. It may occur spontaneously (manifest DVD) or only when 1 eye is occluded (latent DVD). An eye with latent DVD can give the appearance of inferior oblique overaction when it is occluded by the nose during adduction. In addition to DHD, latent nystagmus and horizontal strabismus are often associated with DVD. These entities are manifestations of deficient binocular vision.

Measurement of DVD is difficult and imprecise. In one method, a base-down prism is placed in front of the upwardly deviating eye while it is behind an occluder. The occluder is then switched to the fixating lower eye. The prism power is adjusted until the deviating eye shows no downward movement to refixate. These steps are then repeated for the other eye. Measurements obtained with this technique are confounded by any coexisting true hypertropia, but it does provide a rough estimate for surgical planning.



**Figure 11-8** Dissociated vertical deviation, left eye. **A**, Straight eyes during binocular viewing conditions. **B**, Large left hyperdeviation immediately after the eye is covered and then uncovered. **C**, The left eye comes back down to primary position without a corresponding right hypotropia.

## Management

Treatment of DVD is indicated if the deviation is noticeable (generally more than  $6\Delta$ – $8\Delta$ ) and occurs frequently during the day. When DVD is unilateral or highly asymmetric, encouraging fixation by the eye with greater DVD by optically blurring the fellow eye is sometimes sufficient. Because DVD can mimic OEAd, distinguishing it from overaction of the inferior oblique muscles is important, as the surgical approaches to these 2 conditions are different in most cases.

Surgery on the vertical muscles often improves the condition but rarely eliminates it. Recessions of the superior rectus muscle, ranging from 6 to 10 mm according to the size of the hypertropia, can be effective. If there is residual DVD after superior rectus muscle recession, inferior rectus muscle resection or plication can be performed. Inferior oblique muscle anterior transposition is also effective in treating DVD, especially if it is accompanied by inferior oblique muscle overaction. Bilateral surgery is performed whenever both eyes can fixate; asymmetric surgery is an option if the DVD is asymmetric.

# Special Motility Disorders

See BCSC Section 5, *Neuro-Ophthalmology*, for additional discussion of several entities covered in this chapter, and see Chapter 14 in this volume for discussion of some of the surgical procedures mentioned in this chapter.

## Congenital Cranial Dysinnervation Disorders

---

Congenital cranial dysinnervation disorders (CCDDs) are a group of strabismus entities that have in common a developmental defect of one or more cranial nerves. There can be nuclear hypoplasia, nerve misdirection, and/or absence of the nerves themselves. These anomalies lead to various patterns of abnormal innervation of the eye muscles that often result in secondary abnormal structural changes to the affected muscles, usually stiffening or contracture. Onset of the innervation anomalies can be as early as the first trimester in utero. Included in this group are Duane retraction syndrome, congenital fibrosis of the extraocular muscles, Möbius syndrome, and some cases of congenital fourth nerve palsy (see Chapter 11). In recent work, congenital Brown syndrome has been postulated to be a form of CCDD.

Gutowski NJ, Chilton JK. The congenital cranial dysinnervation disorders. *Arch Dis Child*. 2015;100(7):678–681.

### Duane Retraction Syndrome

Duane retraction syndrome is a spectrum of ocular motility disorders characterized by anomalous co-contraction of the medial and lateral rectus muscles on actual or attempted adduction of the involved eye or eyes; this co-contraction causes the globe to retract. Horizontal eye movement can be limited to various degrees in both abduction and adduction. An upshoot or downshoot often occurs when the affected eye is innervated to adduct; vertical slippage of a tight lateral rectus muscle by 1–2 mm, which has been demonstrated by magnetic resonance imaging (MRI) studies, is the typical cause. Less commonly, anomalous vertical rectus muscle activity is responsible for upshoots and downshoots.

Although most affected patients have Duane retraction syndrome alone, many associated systemic defects have been noted, such as Goldenhar syndrome (hemifacial microsomia, ocular dermoids, ear anomalies, preauricular skin tags, and eyelid colobomas) and Wildervanck syndrome (sensorineural hearing loss and Klippel-Feil anomaly with fused cervical vertebrae). Studies of patients with Duane retraction syndrome related to prenatal



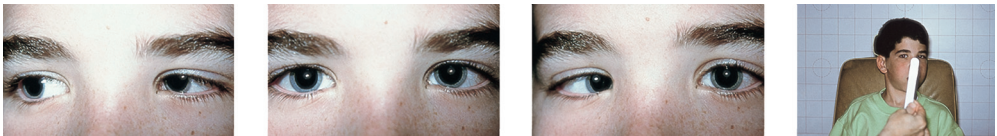thalidomide exposure show that the underlying defect in development occurs between the fourth and sixth weeks of gestation.

Most cases of Duane retraction syndrome are sporadic, but approximately 5%–10% show autosomal dominant inheritance. Instances of links to more generalized disorders have been reported. Discordance in monozygotic twins raises the possibility that the intrauterine environment may play a role in the development of this syndrome. A higher prevalence in females is reported in most series, and there is a predilection for the left eye.

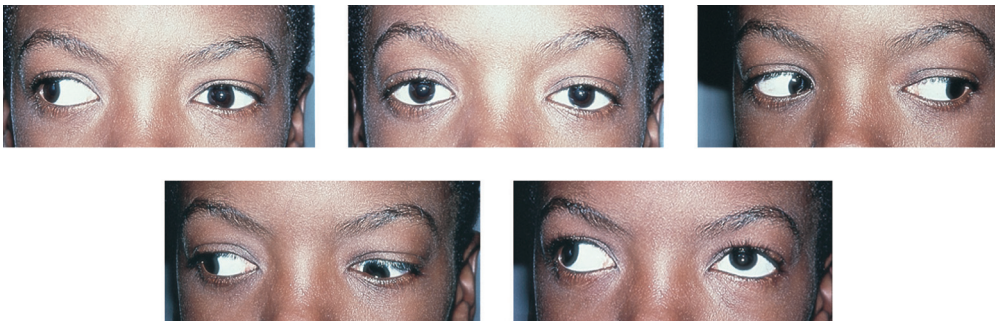In most anatomical and imaging studies, the nucleus of the sixth cranial nerve is absent or hypoplastic and an aberrant branch of the third cranial nerve innervates the lateral rectus muscle. Results of electromyographic studies have been consistent with this finding. Although Duane retraction syndrome is considered an innervational anomaly, tight and broadly inserted medial rectus muscles and fibrotic lateral rectus muscles, with corresponding forced duction abnormalities, are often encountered during surgery.

### **Clinical features**

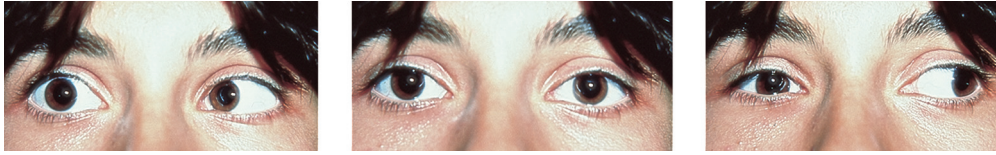
The most widely used classification of Duane retraction syndrome defines 3 types, but they may represent differences only in the severity of horizontal rotation limitations. Type 1 refers to poor abduction, frequently with esotropia in primary position (Fig 12-1); type 2 refers to poor adduction and exotropia (Fig 12-2); and type 3 refers to poor abduction and adduction, with esotropia, exotropia, or no primary position deviation (Fig 12-3). Approximately 15% of cases are bilateral; the type may differ between the 2 eyes. The spectrum of



**Figure 12-1** Type 1 Duane retraction syndrome with esotropia, left eye, showing limitation of abduction, almost full adduction, and retraction of the globe on adduction. *Far right*, Compensatory left head turn. (Courtesy of Edward L. Raab, MD.)



**Figure 12-2** Type 2 Duane retraction syndrome, left eye. *Top row*, Full abduction and marked limitation of adduction. *Bottom row*, Variable upshoot and downshoot of the left eye with extreme right-gaze effort. The typical primary position exotropia is not present in this patient. (Courtesy of Edward L. Raab, MD.)



**Figure 12-3** Type 3 Duane retraction syndrome, right eye. Severe limitation of abduction and adduction, with palpebral fissure narrowing even though adduction cannot be accomplished. There is no deviation in primary position. (Courtesy of Edward L. Raab, MD.)

dysinnervation among cases means that classification of patients based on these categories can be arbitrary in some situations, especially in deciding between type 1 and type 3. *Synergistic divergence* is a rare and bizarre motility disturbance that is often classified as a fourth type of Duane syndrome. There is usually exotropia, and when the affected eye looks in the direction that should result in adduction, it actually abducts even further—a finding colorfully described as “the ocular splits.” Synergistic divergence can be unilateral or bilateral and can be due to biallelic *COL25A1* mutations.

Type 1 (with esotropia and limited abduction) is the most common form of Duane retraction syndrome, accounting for 50%–80% of cases in several series. Affected individuals or their caregivers often incorrectly believe that the normal eye is turning in excessively, not realizing that the involved eye is failing to abduct. Observation of globe retraction on adduction obviates the need for neurologic investigation for sixth nerve palsy, from which it must be differentiated; however, retraction can be difficult to appreciate in an infant. Another indicator that the condition is not sixth nerve palsy is the relatively small esotropia in primary position (usually <30 prism diopters [ $\Delta$ ]) in the setting of a severe abduction deficit. A further point of differentiation is that even in esotropic Duane retraction syndrome, a small-angle exotropia is sometimes present on gaze to the side opposite that of the affected eye, a finding that does not occur in lateral rectus muscle paralysis. Finally, examination at the slit lamp can help confirm the diagnosis in mild cases: if the vertical slit-lamp beam cast from the cornea onto the lower eyelid is disrupted by globe retraction when the eye adducts, Duane retraction syndrome is present.

### **Management**

No surgical approach will normalize rotations. Surgery is reserved for cases with a primary position deviation, a head turn, marked globe retraction, or large upshoots or downshoots. Because Duane retraction syndrome is a spectrum of motility disorders, the surgical plan must be individualized for the patient. In many patients with this syndrome, the eyes are properly aligned in at least 1 position of gaze, allowing the development of binocular vision. The main goal of surgery is to centralize this field of single binocular vision to eliminate the need for a head turn. Expansion of the field of single binocular vision, while laudable, is more relevant in patients with sixth nerve palsy than in those with Duane syndrome, who rarely report diplopia in ipsilateral gaze.

For unilateral type 1 Duane retraction syndrome, recession of the medial rectus muscle on the involved side has been the procedure most often used to correct the primary position deviation and eliminate the head turn. Adding recession of the opposite medial rectus (bilateral surgery) has been advocated by some surgeons, but the rationale is

unclear, as this does not increase innervation to the lateral rectus muscle (as it would in sixth nerve palsy) and any decrease in medial rectus innervation is offset by a decrease in anomalous innervation to the lateral rectus muscle of the involved eye. These operations do not usually improve abduction significantly. Primary position overcorrection can occur due to excessive medial rectus recession, and the resulting exotropia will worsen in the field of gaze in which the involved eye is adducted. Recession of the lateral rectus muscle of the uninvolved eye can offset this effect to some extent.

Because of concern that lateral rectus muscle resection will exacerbate globe retraction, most surgeons do not favor this approach. Occasionally, however, there are patients with minimal co-contraction in whom a small resection (<3–4 mm) can produce dramatic improvement in abduction. Partial or full lateral transposition of both vertical rectus muscles or the superior rectus alone, usually with medial rectus recession, with or without posterior scleral fixation (myopexy), has been shown to improve abduction in some patients.

The most commonly recommended surgery for type 2 Duane retraction syndrome is recession of the lateral rectus muscle on the involved side; resection of the medial rectus muscle is avoided. Some surgeons recess both lateral rectus muscles if a large-angle exotropia is present, but when a fixating unaffected eye is operated on, the effect of increased contralateral medial rectus innervation (and associated lateral rectus anomalous innervation) must be considered.

Patients with type 3 Duane retraction syndrome often have straight eyes near the primary position and do not require surgical treatment for their minimal head turn or horizontal strabismus. Globe retraction may be severe enough to warrant treatment and can be lessened by recession of both the medial and the lateral rectus muscles, which may also reduce any upshoot or downshoot in adduction. This is also an option for treating retraction in type 1 and type 2 Duane retraction syndrome. The lateral recession must be large to improve the retraction. Other procedures to address an upshoot or downshoot include splitting of the lateral rectus muscle in a Y configuration, retroequatorial fixation of the lateral rectus muscle and, more recently, deactivation of the lateral rectus muscle, such as by disinsertion and reattachment to the lateral periosteum of the orbit with a subsequent transposition procedure.

Rosenbaum AL. Costenbader Lecture. The efficacy of rectus muscle transposition surgery in esotropic Duane syndrome and VI nerve palsy. *J AAPOS*. 2004;8(5):409–419.

## **Congenital Fibrosis of the Extraocular Muscles**

Congenital fibrosis of the extraocular muscles (CFEOM), or congenital fibrosis syndrome, is a group of rare congenital disorders in which EOM restriction is present and fibrous tissue replaces these muscles. Some forms have been noted to be inherited, usually as an autosomal dominant trait but occasionally in an autosomal recessive fashion. Cases of CFEOM involve developmental defects of cranial nerve nuclei and of the nerves themselves, resulting in dysinnervation and abnormal structure of the EOMs.

Heidary G, Engle EC, Hunter DG. Congenital fibrosis of the extraocular muscles. *Semin Ophthalmol*. 2008;23(1):3–8.

**Clinical features**

Depending upon the type of CFEOM, there may be various combinations of esotropia with limited abduction, exotropia with limited adduction, limited elevation with chin-up head position, and ptosis.

*Strabismus fixus* involves the horizontal rectus muscles, usually the medial rectus muscles, causing severe esotropia. The condition is usually sporadic and can be acquired late.

*Vertical retraction syndrome* affects the superior rectus muscle and causes inability to depress the eye.

Diagnosis of CFEOM depends on finding limited voluntary motion with restriction, which is usually severe and can be confirmed with forced duction testing. The congenital onset is important in distinguishing the syndrome from thyroid eye disease.

**Management**

Surgery for CFEOM is difficult and requires release of the restricted muscles (ie, weakening procedures). Fibrosis of the adjacent tissues may be present as well. A good surgical result aligns the eyes in primary position, but full ocular rotations cannot be restored and the outcome is unpredictable.

Sener EC, Taylan Sekeroglu H, Ural O, Oztürk BT, Sanaç AS. Strabismus surgery in congenital fibrosis of the extraocular muscles: a paradigm. *Ophthalmic Genet.* 2014;35(4):208–225.

**Möbius Syndrome****Clinical features**

Möbius syndrome (or “sequence”; see Chapter 15 discussion of sequence) is a rare condition characterized by the association of both sixth and seventh nerve palsies, the latter causing masklike facies. Patients may also manifest gaze palsies that can be attributed to abnormalities in the paramedian pontine reticular formation or the sixth cranial nerve nucleus. Many patients also have limb, chest, and tongue defects. Some geneticists believe that Möbius syndrome is one of a family of syndromes in which hypoplastic limb anomalies may be associated with orofacial and cranial nerve defects. Poland syndrome (absent pectoralis muscle) is another variant.

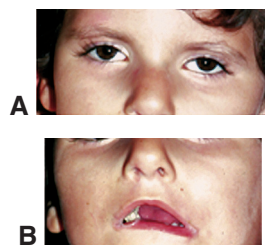
Patients with Möbius syndrome exhibit 1 of 3 patterns of ocular motility involvement, which are likely related to the severity and timing of the in utero insult:

- orthotropia in primary position with marked deficits in abduction and adduction (40% of cases) (Fig 12-4)
- esotropia with cross-fixation and sparing of convergence (50% of cases)
- large exotropia with absence of convergence (10% of cases)

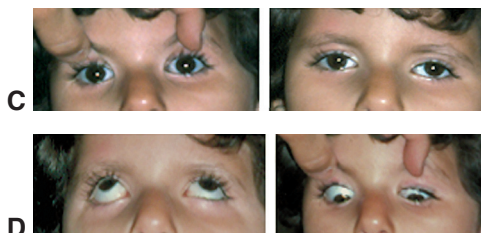
Some patients appear to have palpebral fissure changes on adduction or vertical EOM involvement. Those with exotropia and vertical limitation may harbor *TUBB3* mutations.

Carta A, Mora P, Neri A, Favilla S, Sadun AA. Ophthalmologic and systemic features in Möbius syndrome: an Italian case series. *Ophthalmology.* 2011;118(8):1518–1523.

MacKinnon S, Oystreck DT, Andrews C, Chan WM, Hunter DG, Engle EC. Diagnostic distinctions and genetic analysis of patients diagnosed with moebius syndrome. *Ophthalmology.* 2014;121(7):1461–1468.



**Figure 12-4** Möbius syndrome. **A**, Straight eyes in primary position. **B**, The patient cannot smile because of bilateral seventh nerve palsy. **C**, Bilaterally absent adduction and severely limited abduction. **D**, Vertical movements are not affected. (Courtesy of Edward L. Raab, MD.)



### **Management**

Medial rectus muscle recession has been advocated for patients with large-angle esotropia, but caution should be exercised in the presence of a significant limitation of adduction. Some surgeons have endeavored to improve abduction by performing vertical rectus muscle transposition procedures after medial rectus muscle restriction has been relieved.

## **Miscellaneous Special Forms of Strabismus**

### **Brown Syndrome**

Although it is included in most lists of vertical deviations (see Chapter 11), Brown syndrome is best considered a special form of strabismus. The characteristic restriction of elevation in adduction was originally thought to be caused by shortening of the supposed sheath of the superior oblique tendon. It is now attributed to various abnormalities of the tendon–trochlea complex (see Chapter 3), and evidence indicates that structural problems within the orbit but remote from the superior oblique tendon, including instability of the lateral rectus pulley, can present an identical clinical picture (pseudo–Brown syndrome). Recent work suggests that congenital Brown syndrome may be a form of CCDD.

Most cases are congenital. Prominent causes of the acquired form include trauma in the region of the trochlea, iatrogenic causes such as scleral buckles and tube shunts, orbital tumors, and systemic inflammatory conditions such as rheumatoid arthritis. The latter often results in intermittent Brown syndrome, which may resolve spontaneously. Sinusitis can also lead to Brown syndrome; thus, patients with acute-onset presentation of Brown syndrome of undetermined cause should undergo imaging of the orbits and paranasal sinuses to investigate this possibility. The condition is bilateral in approximately 10% of cases. Resolution of congenital Brown syndrome has been thought to be unusual, but a report by Dawson and colleagues describes spontaneous improvement in 75% of cases, often after many years.

Dawson E, Barry J, Lee J. Spontaneous resolution in patients with congenital Brown syndrome. *J AAPOS*. 2009;13(2):116–118.

### **Clinical features**

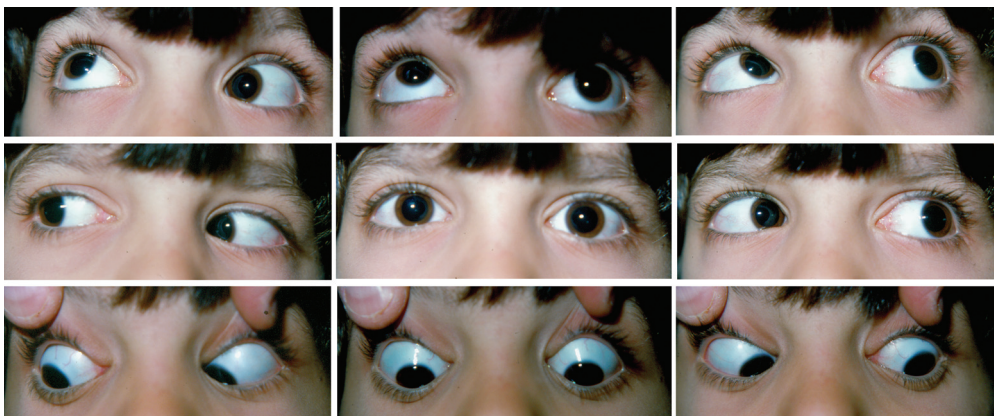Well-recognized clinical features of Brown syndrome include deficient elevation in adduction that improves in abduction but often not completely (Fig 12-5). Several findings differentiate Brown syndrome from inferior oblique muscle paralysis (see Chapter 11, Table 11-4).

An unequivocally positive forced duction test demonstrating restricted passive elevation in adduction is essential for the diagnosis. Retropulsion of the globe during this test stretches the superior oblique tendon and accentuates the restriction. In restrictions involving the inferior rectus muscle or its surrounding tissues, by contrast, the limitation of passive elevation is accentuated by forceps-induced proptosis of the eye rather than by retropulsion.

Attempts at elevation straight upward usually cause divergence (V pattern) due to lateral diversion of the globe as it meets resistance from the tight superior oblique tendon (see Fig 12-5). This finding is an important point of distinction from inferior oblique muscle paralysis, which is more likely to exhibit an A pattern. In adduction, the palpebral fissure widens and overdepression in adduction can be observed in severe cases of Brown syndrome (see Chapter 11, Table 11-2). This differs from overdepression in adduction in true superior oblique muscle overaction, which occurs less abruptly with increasing adduction. In mild Brown syndrome, no hypotropia is present in primary position. Severe cases of Brown syndrome with a primary position hypotropia are often accompanied by a chin-up head position or a head turn away from the side of the affected eye.

### **Management**

Observation alone is appropriate for mild congenital Brown syndrome. When Brown syndrome is secondary to rheumatoid arthritis or other systemic inflammatory diseases,



**Figure 12-5** Brown syndrome, left eye. No elevation of the left eye when adducted; left eye is depressed instead. Elevation is also severely limited in straight-up gaze and moderately so even in up-and-left gaze. Note the characteristic divergence in straight-up gaze and lack of ipsilateral superior oblique overaction. (Courtesy of Edward L. Raab, MD.)

resolution may occur as systemic treatment brings the underlying disease into remission or when corticosteroids are injected near the trochlea.

Surgery is indicated for more severe congenital cases. Superior oblique tenotomy nasal to the superior rectus muscle is definitive treatment; however, iatrogenic superior oblique muscle paresis occurs in a significant minority of patients after this procedure. Careful handling of the intermuscular septum during surgery can reduce the incidence of this sequela. To reduce the consequences of superior oblique muscle palsy after tenotomy, some surgeons perform simultaneous ipsilateral inferior oblique muscle weakening. Other current options include insertion of an inert spacer or suture between the cut ends of the superior oblique tendon, and split-tendon lengthening of the tendon (see Chapter 14).

Wright KW. Brown's syndrome: diagnosis and management. *Trans Am Ophthalmol Soc.* 1999; 97:1023–1109.

### Third Nerve Palsy

In children, third nerve palsy can be congenital (more appropriately termed *dysinnervation*) or can be caused by conditions such as trauma, inflammation, or viral infection. It can also occur as a manifestation of ophthalmoplegic migraine, after vaccination, or (infrequently) as a result of a neoplastic lesion. In adults, the usual causes are intracranial aneurysm, microvascular infarction, inflammation, trauma, infection, or tumor. See BCSC Section 5, *Neuro-Ophthalmology*, for detailed discussion of the causes and manifestations of third nerve palsy. This section is concerned primarily with the principles of treatment of the strabismus.

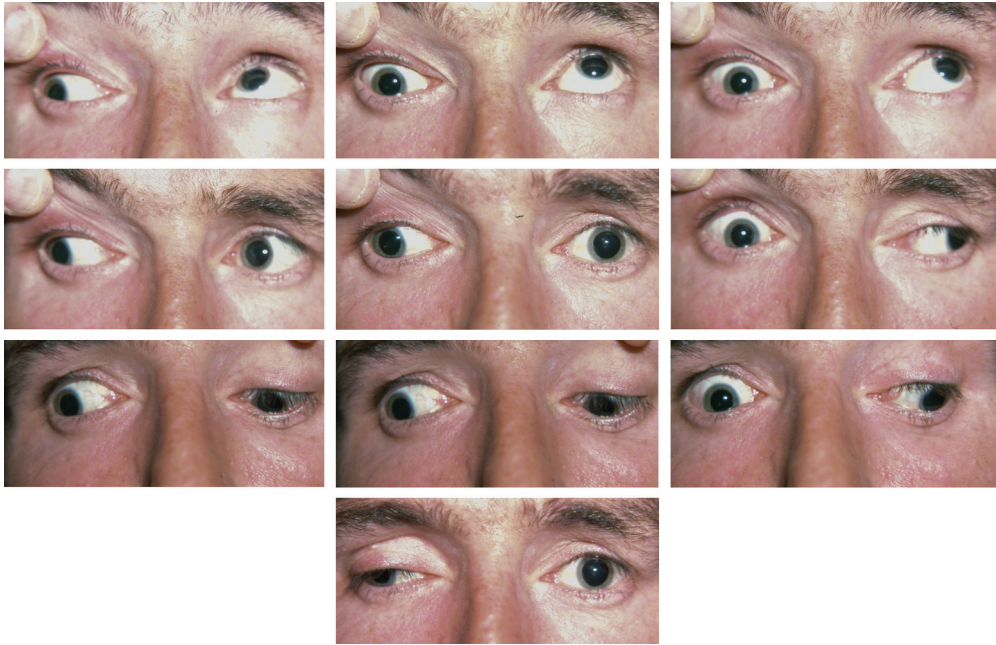#### **Clinical features**

Complete paralysis results in limited adduction, elevation, and depression of the eye, causing exotropia and often hypotropia. These findings are expected because the remaining unopposed muscles are the lateral rectus (abductor) and the superior oblique (abductor and depressor), except when the cause of the paralysis involves the nerves supplying these muscles as well. Upper eyelid ptosis is usually present, often with pseudoptosis due to the depressed position of the involved eye (Fig 12-6).

The clinical findings and treatment may be complicated by misdirection (aberrant regeneration) of the damaged nerve, presenting as anomalous eyelid elevation, pupil constriction, or vertical excursion of the globe—any or all of which can occur upon attempted rotation into the field of action of the EOMs supplied by the injured nerve. A miotic pupil is sometimes noted in congenital cases, irrespective of whether there is aberrant regeneration. Affected adults report incapacitating diplopia unless the involved eye is occluded by ptosis or other means.

#### **Management**

Except in congenital cases, it is advisable to wait at least 6 months, possibly even up to 12 months, for spontaneous recovery before proceeding with surgical correction. Patients with at least partial recovery are much better candidates for good functional and cosmetic results. Because the visual system is still developing in pediatric patients, amblyopia is a common finding that must be treated aggressively.



**Figure 12-6** Third nerve palsy, right eye, with ptosis (*bottom photo*) and limited adduction, elevation, and depression (upper eyelid elevated manually in top 9 photos). (Courtesy of Edward L. Raab, MD.)

In adults with previously good binocular vision, occlusion from associated ptosis may actually be beneficial by preventing incapacitating diplopia associated with a limited or absent field of single binocular vision; ptosis repair should not be done without prism adaptation testing to demonstrate that the patient can achieve satisfactory binocular vision with prism. The incidence of diplopia in patients younger than 8 years is low because of suppression (see Chapter 5).

Third nerve palsy presents difficult surgical challenges because multiple EOMs, including the levator muscle, are involved. Replacing all the lost rotational forces on the globe is impossible; therefore, the goal of surgery is adequate alignment for binocular function in primary position and in slight downgaze for reading.

Selection of the surgical procedure is dictated by the number of involved muscles and their condition, as well as by the presence or absence of noticeable paradoxical rotations. In a case of incomplete paralysis, a large recession-resection of the horizontal rectus muscles to correct the exodeviation, with supraplacement of both to correct the hypotropia, is effective. Some surgeons perform a concurrent superior oblique tenotomy to reduce the hypotropia. For complete paralysis, one suggested approach is a large recession of the lateral rectus muscle, combined with either a large medial rectus resection or fixation of the globe to the nasal orbital periosteum. Disinsertion of the lateral rectus muscle and reattachment to the lateral orbital periosteum can maximize inactivation of the muscle. Splitting and transposition of the lateral rectus muscle to the nasal side of the globe has also been described. Transfer of the superior oblique tendon to the upper nasal quadrant



of the globe has been used as well; however, anomalous eye movements can result from this procedure. Most surgeons reserve correction of ptosis for a subsequent procedure, which allows for more accurate positioning of the upper eyelid.

### **Fourth Nerve Palsy**

Paralysis of cranial nerve IV (trochlear) is discussed in Chapter 11 and BCSC Section 5, *Neuro-Ophthalmology*.

### **Sixth Nerve Palsy**

Paralysis of cranial nerve VI (abducens) is less common in children than in adults. This entity is discussed in Chapter 8. See BCSC Section 5, *Neuro-Ophthalmology*, for additional discussion.

### **Thyroid Eye Disease**

Thyroid eye disease (TED) affects the eye and the orbit in various ways. Only motility disturbances are covered in this volume.

Edema, inflammation, and fibrosis of the EOMs due to lymphocytic infiltration occur in this disease. Not only do these pathologies restrict motility, but the massively enlarged muscles can cause compressive optic neuropathy. Detection of muscle enlargement by orbital imaging helps confirm the diagnosis.

The myopathy is not caused by thyroid dysfunction. Rather, both conditions probably result from a common autoimmune disease. Thyroid-stimulating immunoglobulins likely mediate TED and may be regarded as a functional biomarker for this condition. Some patients also have myasthenia gravis (another autoimmune disease, discussed later in this chapter), complicating the clinical findings. An association between severity of TED and smoking has recently become apparent; the hazard ratio for strabismus surgery is almost double in patients with thyroid disease who smoke.

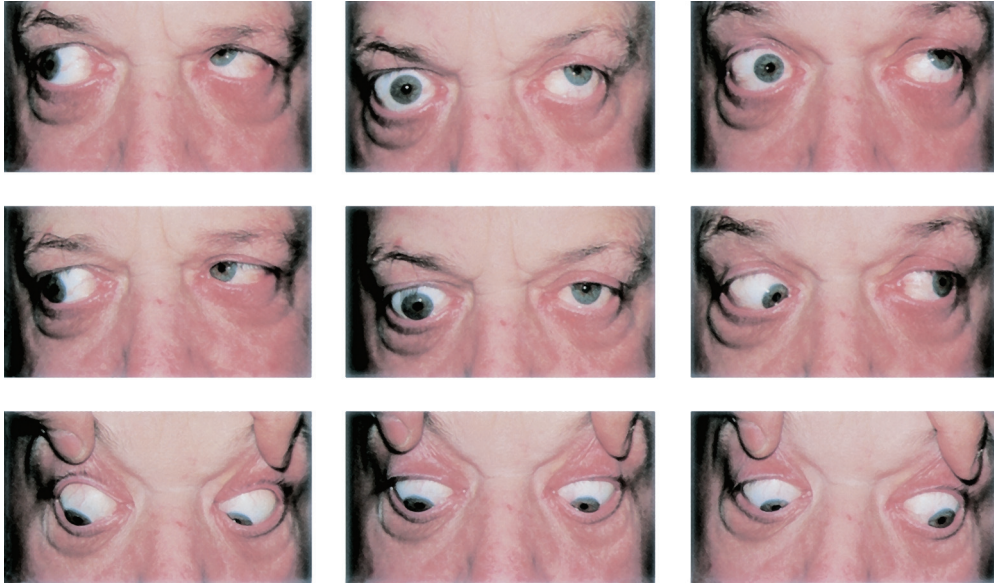#### ***Clinical features***

The muscles affected in TED, in decreasing order of severity and frequency, are the inferior rectus, medial rectus, superior rectus, and lateral rectus. The condition is usually bilateral but is often asymmetric. Forced duction testing almost always shows restriction in one or more directions.

Most often, the patient presents with some degree of upper eyelid retraction, proptosis, hypotropia, and esotropia (Fig 12-7). TED is a common cause of acquired vertical deviation in adults, especially women, but rarely causes motility problems in children.

#### ***Management***

Diplopia and abnormal head position are the principal indications for strabismus surgery. The operation may eliminate diplopia in primary gaze but rarely restores normal motility because of the restrictive myopathy, the need for large recessions in some cases to place the eye in primary position, and the ongoing underlying disease.



**Figure 12-7** Thyroid eye disease. Note right upper eyelid retraction and restrictive right hypotropia with very limited elevation. Other rotations are not affected in this patient.

It is best to perform surgery after strabismus measurements and thyroid function tests have stabilized. In cases in which orbital decompression is necessary, strabismus surgery should be delayed until after that has been done. In the meantime, prisms may alleviate diplopia. Botulinum toxin may reduce the severity of fibrosis when injected into tight muscles in the acute phase. In studies of surgery performed before stability was achieved in patients with severe head positions, the results were favorable, but half the patients required further surgery.

Recession of the affected muscles is the preferred surgical treatment, addressing the tight muscles in 1 or both eyes. Resection procedures usually worsen restriction, but in carefully selected cases they may be helpful as part of the surgical plan. Slight initial undercorrection of hypotropia is desirable because late progressive overcorrection is common, especially with inferior rectus muscle recessions. Limited depression of the eyes after inferior rectus muscle recessions can interfere with patients' bifocal use.

Because proptosis and eyelid retraction can increase after EOM surgery, eyelid surgery is best delayed until after all EOM surgery has been completed.

## **Chronic Progressive External Ophthalmoplegia**

### ***Clinical features***

Chronic progressive external ophthalmoplegia (CPEO) is a rare form of mitochondrial cytopathy that can affect various body systems. It usually begins in childhood with ptosis and slowly progresses to total paralysis of the eyelids and EOMs. CPEO may be sporadic or familial. Although a true pigmentary retinal dystrophy is rare, constricted visual fields and electrodiagnostic abnormalities can occur. The diagnosis of CPEO is confirmed when

muscle biopsy results show ragged red fibers or when specific alterations of mitochondrial DNA are detected. *Kearns-Sayre syndrome* is characterized by retinal pigmentary changes, CPEO, and cardiomyopathy (especially heart block).

See BCSC Section 2, *Fundamentals and Principles of Ophthalmology*, Section 5, *Neuro-Ophthalmology*, and Section 12, *Retina and Vitreous*, for additional information on these and other mitochondrial disorders.

### **Management**

It is important to ensure that the patient's cardiac status is evaluated, because life-threatening arrhythmias can occur in Kearns-Sayre syndrome. Treatment options for the ocular motility disorder are limited; small surgical series report a high rate of long-term undercorrections. Cautious surgical elevation (suspension) of the upper eyelids can lessen a severe chin-up head position.

### **Myasthenia Gravis**

Myasthenia gravis is a disorder in which antibodies directed against acetylcholine receptors cause muscle dysfunction. Onset in childhood is uncommon. A transient neonatal form, caused by the placental transfer of acetylcholine receptor antibodies of mothers with myasthenia gravis, exists but usually subsides rapidly. Another variant is not immune mediated and exhibits a familial predisposition.

The disease may be purely ocular. In its most severe form, it frequently occurs as part of a major systemic disorder that involves other skeletal muscles, especially in patients who have not received immunosuppressive therapy. Generalization to systemic myasthenia is less common in childhood-onset ocular myasthenia than in the adult-onset form.

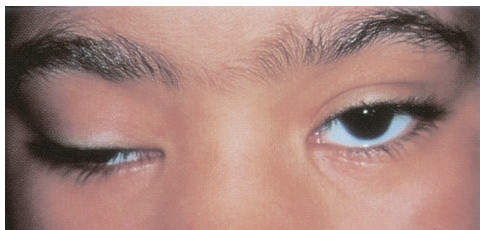
See BCSC Section 5, *Neuro-Ophthalmology*, for an in-depth discussion of the diagnosis of myasthenia gravis, along with its ocular and systemic aspects. Additional information is available on the website of the Myasthenia Gravis Foundation of America ([www.myasthenia.org](http://www.myasthenia.org)).

### **Clinical features**

The principal ocular manifestation of myasthenia gravis is weakening of the EOMs, including the levator muscle. Most cases (90%) exhibit both ptosis and limited ocular rotations (Fig 12-8). The ocular signs can resemble those of any unilateral or bilateral ophthalmoplegia, including internuclear ophthalmoplegia.

Table 12-1 compares the features of TED with those of CPEO and myasthenia gravis.

Ortiz S, Borchert M. Long-term outcomes of pediatric ocular myasthenia gravis. *Ophthalmology*. 2008;115(7):1245-1248.



**Figure 12-8** Myasthenia gravis. Bilateral ptosis (right more than left) with right hypotropia.

**Table 12-1 Differentiation of Conditions Producing Ptosis and Extraocular Muscle Involvement**

	<b>Thyroid Eye Disease</b>	<b>Chronic Progressive External Ophthalmoplegia</b>	<b>Myasthenia Gravis</b>
<b>Age</b>	Rare in children	Any age	Any age
<b>Muscle preferentially involved</b>	Inferior rectus muscles, medial rectus muscles	Levator palpebrae, all ocular motor muscles	Levator palpebrae, any ocular motor muscle
<b>Fatigability</b>	No, unless coexistent with myasthenia gravis	No	Yes
<b>Response to edrophonium</b>	No, unless coexistent with myasthenia gravis	No	Yes
<b>Other eye signs</b>	External eye signs	Pigmentary retinopathy, optic neuropathy	No
<b>Forced ductions</b>	Restriction	Restriction if long-standing	Normal
<b>Clinical course</b>	May resolve or progress	Slowly progresses	Fluctuates; may involve generalized weakness
<b>Eyelids</b>	Retraction	Ptosis	Ptosis
<b>Diplopia</b>	Yes	No	Yes
<b>Other signs and symptoms</b>	Tachycardia, arrhythmia, tremor, weight loss, diarrhea, heat intolerance	Heart block, retinopathy (manifestations of Kearns-Sayre syndrome)	Dysphagia, jaw weakness, limb weakness, dyspnea

### **Management**

A full discussion of treatment of the various forms of myasthenia gravis is beyond the scope of this chapter. In adults, the ocular manifestations are frequently resistant to the usual systemic myasthenia treatment. However, pediatric ocular myasthenia is often successfully managed with pyridostigmine alone. In adults and children in whom the ocular deviation has stabilized, standard eye muscle surgery can help restore binocular function in at least some gaze positions. Ptosis occasionally requires surgical repair.

### **Esotropia and Hypotropia Associated With High Myopia**

In highly myopic patients, extremely increased axial length can cause the elongated globe to herniate between the superior and lateral rectus muscles. High-resolution MRI studies have shown stretching and dehiscence of the intermuscular septum between these 2 muscles. They have also demonstrated inferior slippage of the lateral rectus pulley and other supporting tissues, along with medial displacement of the superior rectus. These anomalies cause a progressively worsening hypotropia and esotropia. The medial rectus is often tight, exacerbating the severity of the esotropia.

Various surgical procedures have been devised to overcome the defect by stabilizing the position of the lateral rectus muscle. An effective option is a joining of the superior

and lateral rectus muscles, usually with a nonabsorbable suture, to reposition the globe. Recession of the medial rectus muscle may also be necessary if the muscle is tight.

Yamaguchi M, Yokoyama T, Shiraki K. Surgical procedure for correcting globe dislocation in highly myopic strabismus. *Am J Ophthalmol.* 2010;149(2):341–346.

### **Internuclear Ophthalmoplegia**

The anatomical and functional features of the *medial longitudinal fasciculus (MLF)* are discussed in BCSC Section 5, *Neuro-Ophthalmology*. The MLF integrates the nuclei of the cranial nerves governing ocular motility and has major connections with the vestibular nuclei. An intact MLF is essential for production of conjugate eye movements. Lesions of the MLF result in a typical pattern of dysconjugate movement called *internuclear ophthalmoplegia (INO)*. Abnormalities of this pathway are frequently seen in patients with demyelinating disease, but they may also occur in patients who have had cerebrovascular accidents or brain tumors.

#### **Clinical features**

On horizontal versions, the eye ipsilateral to the MLF lesion adducts slowly and incompletely or not at all, whereas the abducting eye exhibits a characteristic horizontal jerk nystagmus (see Chapter 13). Both eyes adduct normally on convergence. Skew deviation may be present, in addition to exotropia.

#### **Management**

If exotropia persists, medial rectus muscle resection and unilateral or contralateral lateral rectus muscle recession (to limit exotropia in lateral gaze) can help eliminate diplopia, particularly in bilateral cases.

### **Ocular Motor Apraxia**

Ocular motor apraxia, also known as *saccadic initiation failure*, is a rare supranuclear disorder of ocular motility, sometimes including strabismus. The congenital form may be familial, most commonly autosomal dominant.

This condition has been associated with premature birth and developmental delay. Bilateral lesions of the frontoparietal cortex, agenesis of the corpus callosum, hydrocephalus, and Joubert syndrome (abnormal eye movements, developmental delay, microcephaly, hypoplasia of the cerebellar vermis, and retinal dysplasia, among several anomalies) also have been associated with the condition, as have type 3 Gaucher disease and ataxia-telangiectasia. Several case reports have identified mass lesions of the cerebellum that compress the rostral part of the brainstem. Neurodevelopmental evaluation and imaging of the brain are advisable for assessment of children with ocular motor apraxia, especially if there is an associated vertical apraxia. The differential diagnosis of acquired ocular motor apraxia includes conditions that affect the generation of voluntary saccades, including metabolic and degenerative diseases such as Huntington chorea.

#### **Clinical features**

In ocular motor apraxia, normal voluntary horizontal saccades cannot be generated. Instead, changes in horizontal fixation are accomplished by a head thrust that overshoots

the target, followed by a rotation of the head back in the opposite direction once fixation is established. The initial thrust serves to break fixation; an associated blink serves the same purpose. Vertical saccades and random eye movements are intact, but horizontal vestibular and optokinetic nystagmus are impaired. The head thrust may improve in late childhood. See also BCSC Section 5, *Neuro-Ophthalmology*.

### **Superior Oblique Myokymia**

Superior oblique myokymia is a rare entity whose cause is poorly understood. Some evidence indicates that it is caused by ephaptic transmission between fourth cranial nerve fibers perhaps due, in some cases, to damage by vascular compression.

#### ***Clinical features***

In superior oblique myokymia, there are abnormal torsional movements of the eye that cause diplopia and monocular oscillopsia. Usually, patients are otherwise neurologically normal. Recurrences may persist indefinitely.

#### ***Management***

Treatment is not necessary if the patient is not disturbed by the visual symptoms. Various systemic medications (such as carbamazepine, phenytoin, propranolol, baclofen, gabapentin) and topical timolol have produced inconsistent results but have been advocated as first-line treatment because some patients will benefit, at least in the short term. Effective surgical treatment requires that the superior oblique muscle be disconnected from the globe by generous tenectomy. Because this typically results in a superior oblique palsy, some surgeons perform simultaneous inferior oblique muscle weakening.

Williams PE, Purvin VA, Kawasaki A. Superior oblique myokymia: efficacy of medical treatment. *J AAPOS*. 2007;11(3):254–257.

### **Strabismus Associated With Other Ocular Surgery**

Refractive surgery that produces monovision, facilitating visual clarity at distance and near without optical aids (performed mainly in adults of presbyopic age; see BCSC Section 13, *Refractive Surgery*), can result in dissimilar sensory input to the 2 eyes. The dissimilarity can impair motor fusion, particularly in patients with marginally controlled heterophorias.

Retinal distortion due to an epiretinal membrane or after retinal detachment repair can also distort the retinal image (metamorphopsia, micropsia, or macropsia) to impair motor or sensory fusion. The diplopia rarely improves with surgery for the epiretinal membrane; fogging the eye with a translucent filter or tape (Bangerter; Ryser Optik AG, St Gallen, Switzerland) is the main treatment option.

The *dragged-fovea diplopia syndrome* occurs when an epiretinal membrane displaces the fovea, placing foveal fusion in conflict with peripheral fusion. Prism and alternate cover testing shows a small heterotropia corresponding to the foveal displacement. But under binocular conditions, that prism eliminates the diplopia only briefly, until a fusion movement brings the peripheral retinae back into alignment. Treatment involves fogging the eye, sometimes in combination with a small amount of prism.

Surgery for retinal detachment can lead to restricted rotations and scarring from dissection of the EOMs and the application of devices (such as a scleral buckle) required to bring about reattachment (see BCSC Section 12, *Retina and Vitreous*). Surgical correction of the resultant strabismus is often difficult. Consultation with a retina surgeon is recommended if removal of a scleral buckle is contemplated.

Tube shunts are another potential source of scarring and interference with ocular rotations (see BCSC Section 10, *Glaucoma*). Treatment may require removal, relocation, or substitution of the device, which creates a dilemma if it has been functioning well.

The EOMs can be damaged from retrobulbar injections, either by direct injury to the muscles or from toxicity of the injected material. Because of the usual site of these injections, the vertical rectus muscles are the most vulnerable.

Injection of botulinum toxin into the eyelids can result in diffusion of this substance and a transient paralyzing effect on any of the EOMs.

Laceration or inadvertent excision of an entire section of the medial rectus muscle is one of several serious ocular and orbital complications of pterygium removal or endoscopic sinus surgery. Restoration of function can be an extremely difficult surgical challenge.

Conjunctival scarring and symblepharon can also result in restrictive strabismus after pterygium surgery or other surgery or trauma involving the conjunctiva, particularly in the lateral canthal area. Treatment involves lysis or excision of the fibrotic band. The resulting defect can be managed with conjunctival recession, conjunctival transposition, or an amniotic membrane graft.

Kushner BJ, Kowal L. Diplopia after refractive surgery: occurrence and prevention. *Arch Ophthalmol.* 2003;121(3):315–321.

De Pool ME, Campbell JP, Broome SO, Guyton DL: The dragged-fovea diplopia syndrome. *Ophthalmology.* 2005;112(8):1455–1462.

# Childhood Nystagmus



This chapter includes related videos, which can be accessed by scanning the QR codes provided in the text or going to [www.aao.org/bcscvideo\\_section06](http://www.aao.org/bcscvideo_section06).

Nystagmus is an involuntary, rhythmic oscillation of the eyes. The prevalence of nystagmus in preschool children in the United States is estimated to be 0.35%. Nystagmus can be due to a motor defect that is compatible with relatively good vision, an ocular abnormality that impairs vision or fusion, or a neurologic abnormality. Distinguishing between these causes can be challenging. See BCSC Section 5, *Neuro-Ophthalmology*, for additional discussion of nystagmus.

## General Features

---

The plane of nystagmus can be horizontal, vertical, or torsional, or a combination of these. The condition is often characterized as either *jerk nystagmus*, which has a slow and a fast component, or *pendular nystagmus*, in which the eyes oscillate with equal velocity in each direction. By convention, jerk nystagmus is described by the direction of its fast-phase component; for example, a right jerk nystagmus consists of a slow movement to the left, followed by a fast movement (jerk) to the right. Nystagmus is conjugate (as opposed to dysconjugate) when its direction, frequency (number of oscillations per unit of time), and amplitude (magnitude of the eye movement) are the same in both eyes.

Nystagmus characteristics may change with gaze direction. Pendular nystagmus can become jerk nystagmus on side gaze. Jerk nystagmus can have a *null point* or *null zone* (gaze position in which the intensity [frequency  $\times$  amplitude] is diminished and the vision improves), or it can decrease in intensity with gaze in the direction opposite that of the fast-phase component (analogous to Alexander's law for vestibular nystagmus). The abnormal head position that patients assume in order to reduce nystagmus can be the most prominent manifestation of their condition.

## Nomenclature

---

The National Eye Institute (NEI) has reclassified eye movement abnormalities, including nystagmus. For abnormalities affected by changes in terminology, this chapter uses the terms recommended by the NEI-sponsored Committee for the Classification of Eye Movement Abnormalities and Strabismus (<https://www.nei.nih.gov/sites/default/files/nei-pdfs/cemas.pdf>), with traditional designations in parentheses.



## Types of Childhood Nystagmus

### Infantile Nystagmus Syndrome (Congenital Nystagmus)

#### ***Congenital motor nystagmus***

*Congenital motor nystagmus (CMN)* is a binocular, conjugate nystagmus with several distinctive features (Table 13-1; Video 13-1). It is often recognized in the first few months of life. CMN is not indicative of central nervous system abnormalities. Patients typically have nearly normal visual function. The nystagmus is uniplanar (ie, the plane of the nystagmus remains the same in all positions of gaze) and is most often horizontal. When CMN has a jerk waveform, it shows an exponential increase in velocity during the slow phase (Fig 13-1). A null point may be present, with right jerk nystagmus to the right of the null point and left jerk to the left of the null point. If the null point is not in primary position, the patient may adopt an abnormal head position to improve vision by placing the eyes near the null point. This head position becomes more pronounced as the child approaches school age. Head bobbing or movement may be present initially but usually decreases with age. Nystagmus amplitude may diminish with age. Oscillopsia is rare.



**VIDEO 13-1** Infantile nystagmus syndrome (congenital motor nystagmus).

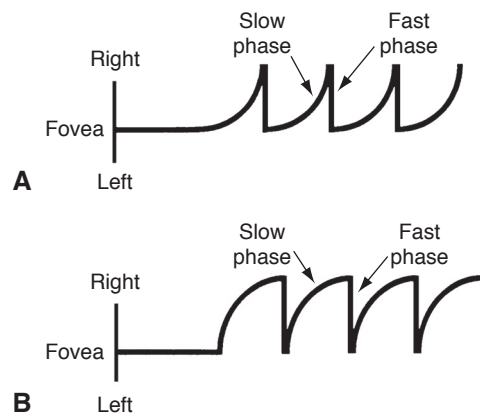
Courtesy of Agnes M.F. Wong, MD, PhD.

Access all Section 6 videos at [www.aao.org/bcscvideo\\_section06](http://www.aao.org/bcscvideo_section06).



CMN worsens with fixation and may worsen with illness or fatigue. Convergence damps (reduces the intensity of) the nystagmus. Thus, near visual acuity is often better than distance acuity. Occasionally, children with CMN overconverge to damp the nystagmus (*nystagmus blockage syndrome*), resulting in esotropia. Clinicians should take care not to confuse it with cases in which esotropia and nystagmus happen to coexist or cases of infantile strabismus with fusion maldevelopment nystagmus syndrome (latent nystagmus). Patients with nystagmus blockage syndrome characteristically present with an esotropia that “eats up prism” as the strabismic deviation increases upon attempted measurement, and with nystagmus that is least apparent when the deviation is largest.

Approximately two-thirds of CMN patients exhibit a paradoxical inversion of the optokinetic nystagmus (OKN) response, which is unique to CMN. Normally, when a patient with right jerk nystagmus views an optokinetic drum rotating to the patient’s left (eliciting



**Figure 13-1** Left jerk nystagmus. **A**, Electroneurophysiologic evaluation of infantile nystagmus syndrome (congenital motor nystagmus) shows an exponential increase in velocity during the slow phase. **B**, An exponential decrease in velocity during the slow phase is the waveform characteristic of fusion maldevelopment nystagmus syndrome (latent nystagmus).

**Table 13-1 Features of Congenital Motor Nystagmus**

Conjugate
Horizontal
Uniplanar
Worsens with attempted fixation
Improves with convergence
Null point often present with abnormal head position
“Inverted” optokinetic nystagmus response in two-thirds of patients
Oscillopsia usually not present
Severe visual impairment uncommon

a “pursuit left, jerk right” response), the intensity of the right jerk nystagmus increases. However, patients with CMN exhibit a damped right jerk nystagmus or possibly even a left jerk nystagmus when viewing an optokinetic drum rotating to the left.

X-linked mutations in the FERM domain-containing-7 gene (*FRMD7*) underlie many cases of typical CMN.

### ***Congenital sensory nystagmus***

*Congenital sensory nystagmus* is secondary to an early-onset, bilateral abnormality of the pregeniculate afferent visual pathway. Inadequate retinal image formation interferes with the normal development of the fixation reflex. If the visual deficit is present at birth, the resulting nystagmus becomes apparent in the first 3 months of life. Its severity is somewhat correlated with the degree of vision loss. The waveform of sensory nystagmus can be pendular or jerk and cannot be distinguished from that of CMN.

Searching, slow, or wandering conjugate eye movements may also be observed. Searching nystagmus—defined as a roving or drifting, typically horizontal movement of the eyes without fixation—is usually seen in children whose visual acuity is worse than 20/200. Pendular nystagmus typically occurs in patients with visual acuity better than 20/200 in at least 1 eye. Jerk nystagmus is often associated with visual acuity between 20/60 and 20/100.

Table 13-2 lists some conditions that are associated with congenital sensory nystagmus. The abnormality may be obvious, as with cataracts; subtle, as with optic nerve hypoplasia or foveal hypoplasia; or not visible on examination, as with some retinal dystrophies.

### **Central Vestibular Instability Nystagmus (Periodic Alternating Nystagmus)**

*Central vestibular instability nystagmus (periodic alternating nystagmus)* is an unusual form of jerk nystagmus that can be congenital (as a form of CMN) or acquired (especially with Arnold-Chiari malformation). The nystagmus periodically changes direction owing to a shifting null point (Video 13-2). The cycle begins with a typical jerk nystagmus, which slowly damps; this leads to a 10- to 20-second period of no nystagmus, followed by jerk nystagmus in the opposite direction. The cycle repeats every few minutes. Some children adopt an alternating head turn to take advantage of the changing null point.



**VIDEO 13-2** Central vestibular instability nystagmus (periodic alternating nystagmus).



**Table 13-2 Ocular Conditions Associated With Congenital Sensory Nystagmus****Bilateral anterior segment abnormalities**

Congenital cataract  
 Congenital glaucoma  
 Iridocorneal dysgenesis

**Primary retinal abnormalities**

Leber congenital amaurosis  
 Achromatopsia  
 Blue-cone monochromatism  
 Congenital stationary night blindness (X-linked and autosomal recessive)

**Bilateral vitreoretinal abnormalities**

Sequelae of severe retinopathy of prematurity  
 Coloboma involving macula  
 Familial exudative vitreoretinopathy  
 Norrie disease  
 Retinal dysplasia  
 Congenital retinoschisis  
 Retinoblastoma

**Foveal hypoplasia**

Albinism  
 Aniridia  
 Isolated foveal hypoplasia

**Bilateral optic nerve disorders**

Optic nerve hypoplasia  
 Optic nerve coloboma  
 Optic nerve atrophy

**Bilateral congenital infectious chorioretinitis**

Congenital toxoplasmosis involving macula  
 Congenital cytomegalovirus infection  
 Congenital rubella  
 Congenital lymphocytic choriomeningitis virus infection  
 Congenital syphilis

**Generalized central nervous system disorder**

Aicardi syndrome

**Fusion Maldevelopment Nystagmus Syndrome (Latent Nystagmus)**

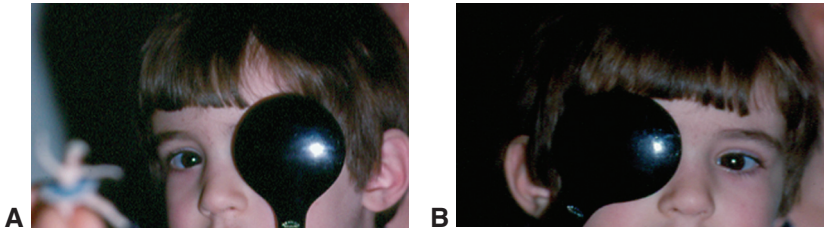
*Fusion maldevelopment nystagmus syndrome (FMNS) (latent nystagmus)* is a conjugate, horizontal jerk nystagmus and a marker of fusion maldevelopment, which occurs as a result of infantile-onset strabismus or (less commonly) decreased vision in 1 eye. When either eye is occluded, a conjugate jerk nystagmus develops, with the direction of the fast-phase component toward the uncovered eye. Left jerk nystagmus occurs upon covering the right eye, and right jerk nystagmus upon covering the left (Video 13-3). This is the only nystagmus that reverses direction depending on which eye is fixating. The nystagmus damps when the fixating eye is in adduction, so the preferred head turn also reverses direction with change of fixation (Fig 13-2). Amplitude, frequency, and velocity of the nystagmus can also vary depending on which eye is fixating.



**VIDEO 13-3** Fusion maldevelopment nystagmus syndrome (latent nystagmus).

*Courtesy of Robert W. Hered, MD.*





**Figure 13-2** Fusion maldevelopment nystagmus syndrome (latent nystagmus). **A**, A right head turn occurs during fixation with the right eye. **B**, The head turn reverses direction during fixation with the left eye. The nystagmus damps with the fixating eye in adduction. (Courtesy of Edward L. Raab, MD.)

Fusion or binocular viewing damps FMNS, and disruption of fusion (eg, by occlusion) increases it. FMNS may manifest even when both eyes are open if only 1 eye is being used for viewing (eg, the other eye is suppressed or amblyopic); this is sometimes referred to as *manifest latent nystagmus*. Electronystagmographic evaluation of both fully latent and manifest forms of FMNS shows similar waveforms, with a slow phase of constant or exponentially decreasing velocity (see Fig 13-1B). FMNS is distinct from infantile nystagmus syndrome that has a latent component, worsening when 1 eye is covered. Like other hallmarks of infantile strabismus with which it is associated (dissociated vertical deviation and oblique muscle overaction), FMNS becomes more prominent with age.

Richards M, Wong A, Foeller P, Bradley D, Tychsen L. Duration of binocular decorrelation predicts the severity of latent (fusion maldevelopment) nystagmus in strabismic macaque monkeys. *Invest Ophthalmol Vis Sci*. 2008;49(5):1872–1878.

## Acquired Nystagmus

### ***Spasmus nutans syndrome***

*Spasmus nutans syndrome* (*spasmus nutans*) is an idiopathic acquired nystagmus that manifests during the first 2 years of life, presenting as a triad of generally small-amplitude, high-frequency (“shimmering”), dysconjugate nystagmus; head nodding; and torticollis. The nystagmus is binocular but often asymmetric, sometimes appearing to be monocular. The plane of the nystagmus can be horizontal, vertical, or torsional; the nystagmus can vary with gaze position, and it is occasionally intermittent. The head nodding and torticollis appear to be compensatory movements that maximize vision. The natural history of spasmus nutans syndrome is diminution of the abnormal head and eye movements by 3–4 years of age. Spasmus nutans syndrome is a benign disorder in most cases, but there is a high incidence of associated strabismus, amblyopia, and developmental delay.

Spasmus nutans–like nystagmus has been seen with chiasmal or suprachiasmal tumors and retinal dystrophies such as congenital stationary night blindness. Neuroradiologic investigation is warranted when there is any evidence of optic nerve dysfunction (eg, disc pallor, relative afferent pupillary defect) or any sign of neurologic abnormality. Because subtle optic disc pallor and relative afferent pupillary defects can be difficult to

assess in children, some investigators prefer neuroimaging for all young children with nystagmus resembling spasmus nutans syndrome.

### **See-saw nystagmus**

*See-saw nystagmus* is an unusual but dramatic type of dysconjugate nystagmus that has both vertical and torsional components. If the 2 eyes are envisioned as being placed on an imaginary see-saw, one at either end, they “roll down the plank” as one end of the see-saw rises, with the high eye intorting and the low eye extorting. As the direction of the see-saw changes, so does that of the eye movement. Thus, the eyes make alternating movements of elevation and intorsion, followed by depression and extorsion (Video 13-4).



#### **VIDEO 13-4** See-saw nystagmus.

*Courtesy of Agnes M.F. Wong, MD, PhD.*



This type of nystagmus is often associated with rostral midbrain or suprasellar lesions, most often craniopharyngioma in children. Confrontation visual field testing may elicit a bitemporal defect. Neuroradiologic evaluation is necessary. A congenital form of see-saw nystagmus can be seen in disorders of decussation, such as Joubert syndrome.

### **Vertical nystagmus**

Vertical nystagmus is uncommon. Congenital vertical nystagmus is sometimes seen in infants with inherited retinal dystrophies. Downbeat nystagmus (upward slow phase with downward fast phase) (Video 13-5), which often features a null point in upgaze, may occur as a congenital disorder associated with good vision and normal neurologic findings. More commonly, vertical nystagmus is acquired, secondary to structural abnormalities such as Arnold-Chiari malformations or use of medications such as codeine, lithium, anxiolytics, and anticonvulsants. Neurologic evaluation is usually indicated in patients with unexplained acquired vertical nystagmus.



#### **VIDEO 13-5** Downbeat nystagmus.

*Courtesy of Janet C. Rucker, MD.*



### **Monocular nystagmus**

Monocular nystagmus has been reported to occur in severely amblyopic or blind eyes (*Heimann-Bielschowsky phenomenon*). The oscillations are pendular, chiefly vertical, slow, variable in amplitude, and irregular in frequency.

## **Nystagmus-Like Disorders**

---

### **Induced Convergence-Retraction (Convergence-Retraction Nystagmus)**

*Induced convergence-retraction (convergence-retraction nystagmus)* is not a true nystagmus; rather, the abnormal eye movements are saccades. In children and adults, induced convergence-retraction is part of the dorsal midbrain syndrome, which is associated

with paralysis of upward gaze, eyelid retraction, and pupillary light–near dissociation. In children, it commonly occurs secondary to congenital aqueductal stenosis or a pinealoma. The phenomenon is best elicited by having the patient attempt an upgaze saccade (Video 13-6) (eg, track a downward-rotating optokinetic drum). Co-contraction of all horizontal extraocular muscles occurs upon attempted upgaze, causing globe *retraction*. *Convergence* also occurs, because the medial rectus muscles overpower the lateral rectus muscles (voluntary convergence, however, may be impaired).



**VIDEO 13-6** Induced convergence-retraction (convergence-retraction nystagmus).



## Opsoclonus

Not a true nystagmus, *opsoclonus* consists of involuntary saccades that are rapid and multi-directional, often accompanied by somatic dyskinesias. Opsoclonus can occur intermittently and often presents as eye movements with very high frequency and large amplitude (Video 13-7). Causes of opsoclonus in children include acute postinfectious cerebellar ataxia, viral encephalitis, and paraneoplastic manifestations of neuroblastoma.



**VIDEO 13-7** Opsoclonus.  
Courtesy of Agnes M.F. Wong, MD, PhD.



## Evaluation

---

### History

Family history may aid diagnosis and provide prognostic information. Although CMN is often sporadic, X-linked recessive, X-linked dominant, autosomal recessive, and autosomal dominant inheritance occur as well. X-linked mutations in *FRMD7* underlie many cases of typical CMN and central vestibular instability nystagmus. Congenital sensory nystagmus can be associated with other inherited ocular conditions (see Table 13-2).

The history should include questions about the pregnancy and birth, because factors such as intrauterine exposure to infection, maternal use of drugs or alcohol, prematurity, and other prenatal or perinatal events can affect development of the visual system and contribute to nystagmus.

For children older than 3 months, parental observations regarding head tilts, head movements, gaze preference, and viewing distances can aid in diagnosis.

### Ocular Examination

#### *Visual acuity*

The level of visual function can help determine the cause of the nystagmus. Patients with nystagmus and nearly normal visual function usually have CMN, which is a benign

entity. Markedly decreased visual acuity usually suggests either retinal or optic nerve abnormalities.

Because monocular occlusion can increase nystagmus intensity, particularly in FMNS (latent nystagmus), monocular acuity should be tested with at least one of the following: a fogging lens (+5.00 diopters [D] greater than the refractive error) or translucent occluder placed over the nontested eye, polarizing lenses with a polarized chart, or an occluder positioned several inches in front of the nontested eye. Binocular visual acuity is often better than monocular acuity and should be measured at distance and near, with any desired head position permitted, to assess the child's true functional vision. Near visual acuity is usually better than distance. Children with a distance acuity below 20/400 can sometimes read as well as the 20/40 to 20/60 level at near.

In preverbal children, the optokinetic drum can be used to estimate visual acuity. If vertical rotation of an optokinetic drum elicits a vertical nystagmus superimposed on the child's underlying nystagmus, the visual acuity is usually 20/400 or better. Preferential looking tests such as Teller Acuity Cards II (described in Chapter 1) can also be used; in patients with horizontal nystagmus, the responses can be more easily assessed with the cards held vertically.

### ***Pupils***

Pupil responses are normal in CMN. Sluggish or absent responses to light, or a relative afferent defect in asymmetric cases, indicates a bilateral anterior visual pathway abnormality such as optic nerve or retinal dysfunction. However, normal responses can be seen with some sensory abnormalities such as foveal hypoplasia and achromatopsia. The normal response to darkness is the immediate dilation of the pupil. If, instead of dilating, the pupils paradoxically constrict, optic nerve or retinal disease may be present.

### ***Anterior segment***

Examination of the anterior segment may reveal a direct cause of decreased vision (eg, congenital cataracts, corneal opacities) or clues to the cause of decreased vision (such as aniridia, or iris transillumination in albinism, both of which are associated with foveal hypoplasia).

### ***Ocular motility***

Nystagmus may be associated with strabismus for a variety of reasons. Early-onset strabismus may cause FMNS (latent nystagmus); convergence may be used to damp nystagmus; or poor vision may be the underlying cause of both nystagmus and strabismus.

### ***Fundus***

Optic nerve hypoplasia and foveal hypoplasia are common causes of congenital sensory nystagmus that may be diagnosed on fundus examination. A child with congenital sensory nystagmus from a retinal dystrophy may have vascular attenuation or optic disc pallor but may have a normal fundus; electroretinography may be required for diagnosis in patients with nystagmus and decreased vision but normal-appearing fundi (see Table 13-2, which lists primary retinal abnormalities that cause nystagmus).

## Treatment

---

### Prisms

The use of prisms can improve anomalous head positions by shifting perceived object location toward the null point. For a patient with a left head turn and a null point in right gaze, the prism before the right eye should be oriented base-in, and the prism before the left eye oriented base-out. This shifts the retinal images to the patient's left and perceived object location to the right; objects in front of the patient are now imaged on the fovea when the patient is in right gaze, reducing the amount of head turn required to use the null point gaze position.

In patients with binocular fusion, bilateral base-out prisms can improve vision by inducing convergence, which damps nystagmus (amounts are determined by trial and error).

Prisms can be used as the sole treatment of nystagmus or as a trial to predict surgical success. With powers ranging up to 40 prism diopters, Press-On (Fresnel) prisms (3M, St Paul, MN), inexpensive plastic pieces that can be cut and then applied to glasses, can be used for both purposes. Ground-in prisms cause less distortion and are preferred for patients who require only small amounts of prism.

Other nonsurgical treatment options for nystagmus are discussed in Chapter 9 of BCSC Section 5, *Neuro-Ophthalmology*.

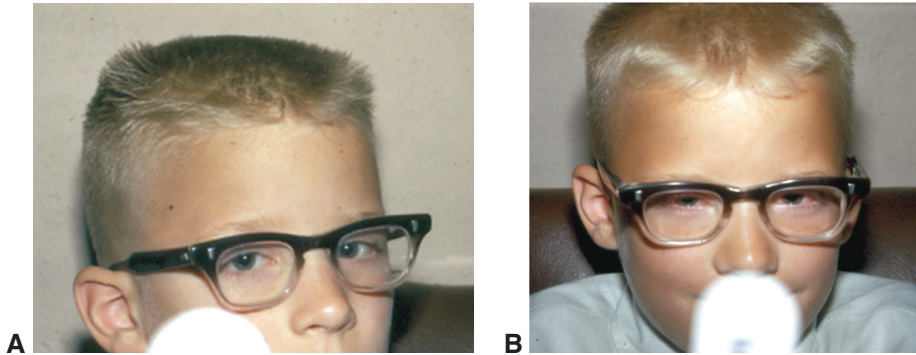
### Surgery

Extraocular muscle surgery for nystagmus may correct a stable anomalous head position by shifting the null point closer to the primary position; this is achieved with medial rectus recession in one eye and lateral rectus recession in the other (*Anderson procedure*) or a recess-resect procedure in both eyes (*Kestenbaum procedure*). Surgery can similarly alleviate compensatory head positions in adults with acquired nystagmus. Bilateral medial rectus recession can treat esotropia resulting from nystagmus blockage syndrome (using larger-than-normal recessions for the amount of esotropia, sometimes in combination with posterior fixation sutures). Extraocular muscle surgery may also improve vision in nystagmus by increasing foveation time, as reported with recession or tenotomy of all 4 horizontal rectus muscles. See Chapter 14 for further discussion of surgical procedures mentioned in this chapter.

In a Kestenbaum or Anderson procedure, the eyes are rotated toward the direction of the head turn and away from the preferred gaze position, moving both eyes in the same direction. For patients with infantile nystagmus syndrome (congenital nystagmus), a left head turn, and null point in right gaze, the eyes are surgically rotated to the left by recessing the right lateral and left medial rectus muscles and resecting the right medial and left lateral rectus muscles. The right-gaze effort, which damps nystagmus, now brings the eyes from this leftward-rotated position to primary position, instead of from primary position into right gaze; in other words, the null point has been shifted toward the primary position (Fig 13-3).

Suggested amounts of recession and resection are listed in Table 13-3. The total amount of surgery for each eye (in millimeters) is equal in order to rotate each globe an





**Figure 13-3** **A**, Infantile nystagmus syndrome with the null point in right gaze. **B**, Null point shifted by the Kestenbaum procedure, reducing the head turn. (Courtesy of Edward L. Raab, MD.)

**Table 13-3 Amount of Recession and Resection for Kestenbaum Procedure, With Modifications<sup>a</sup>**

Procedure	Kestenbaum, mm	40% Augmented, mm	60% Augmented, mm
<b>Eye adducted in null point</b>			
Recess medial rectus	5.0	7.0	8.0
Resect lateral rectus	8.0	11.0	12.5
<b>Eye abducted in null point</b>			
Recess lateral rectus	7.0	10.0	11.0
Resect medial rectus	6.0	8.5	9.5

<sup>a</sup> Amounts listed are for the original Kestenbaum procedure plus 2 modifications in which the amount of surgery is increased.

equal amount. For head turns of 30°, 40% augmentation is recommended; for turns of 45°, 60% augmentation is used. Augmentation may restrict motility, but this is usually necessary to achieve a satisfactory result.

Similarly, chin-up or chin-down positions may be ameliorated by use of a vertical prism (apex toward the null point) or surgery on vertical rectus or oblique muscles, rotating the eyes away from the preferred gaze position. For a chin-up, eyes-down position, the inferior rectus muscles are recessed and the superior rectus muscles are resected, usually by 8–10 mm in each eye. Alternatively, combined weakening of a vertical rectus muscle and an oblique muscle in each eye can be used. For a chin-up position, the inferior rectus and superior oblique muscles are weakened; for a chin-down position, the superior rectus and inferior oblique muscles are weakened. Improvement of head tilt in nystagmus has been reported with torsional surgery involving the oblique muscles or transposition of the vertical rectus muscles.

For nystagmus patients with strabismus, surgery to shift the null point is performed on the dominant eye; surgery on the nondominant eye is then adjusted to account for the strabismus. For example, a patient who is right-eye dominant with a right head turn and null point in left gaze would undergo right medial rectus recession and right lateral rectus resection, as shown in Table 13-3. This would contribute to reducing the angle of an

esodeviation or increasing the angle of an exodeviation. Surgery would then be performed on the nonpreferred eye to correct the residual or resultant deviation.

Other types of nystagmus surgery are less widely practiced. The goal of recession of all 4 horizontal rectus muscles to a position posterior to the equator (8- to 10-mm recessions of medial rectus muscles and 10- to 12-mm recessions of lateral rectus muscles) is to improve vision. Simple 4-muscle tenotomy, which involves disinserting and reattaching the horizontal rectus muscles without recession or resection, has produced similar results, improving recognition time and foveation time on electronystagmography, with modest improvements in visual acuity (approximately 1 line on average).

Hertle RW, Dell'Osso LF, FitzGibbon EJ, Thompson D, Yang D, Mellow SD. Horizontal rectus tenotomy in patients with congenital nystagmus: results in 10 adults. *Ophthalmology*. 2003; 110(11):2097–2105.



# Surgery of the Extraocular Muscles



*This chapter includes related videos, which can be accessed by scanning the QR codes provided in the text or going to [www.aaopt.org/bcscvideo\\_section06](http://www.aaopt.org/bcscvideo_section06).*

While orthoptic exercises or prism glasses are sufficient for some patients with strabismus, many require surgery in order to correct their alignment. Most often, this is achieved with incisional surgery. Chemodenervation, covered at the end of this chapter, is an alternative for some patients.

## Evaluation

---

The history and a detailed evaluation of ocular motility, as part of a complete ophthalmologic examination, provide the information necessary for the surgeon to plan optimal strabismus surgery. Evaluation, tailored to the type of case, may include sensory binocularity testing, forced duction testing, active force generation, and saccadic velocity measurement. Simulation of the target postoperative alignment with prisms or an amblyoscope may be used to assess the risk of diplopia and the potential for single binocular vision (see Chapter 7 for discussion of these tests). Preoperative discussions should address the expectations of the patient and family, as well as the risks and potential complications of strabismus surgery, especially if surgery on the only eye with good vision is considered.

## Indications for Surgery

---

Surgery of the extraocular muscles (EOMs) is performed to improve visual function, appearance, patient well-being, or any combination of these. It may relieve asthenopia (a sense of ocular fatigue) in patients with heterophorias or intermittent heterotropias, or it may relieve the diplopia that often accompanies adult-onset strabismus. Alignment of the visual axes can establish or restore binocular fusion and stereopsis, especially if the preoperative deviation is intermittent or of recent onset. Correction of esotropia expands the binocular visual field. Some patients require an abnormal head position to relieve diplopia or to improve vision. For these patients, surgical treatment may not only increase the field of binocular vision but also shift it to a more useful, centered location.

Correction of strabismus should be considered reconstructive rather than merely cosmetic, as it has many functional and psychosocial benefits.

Gunton KB. Impact of strabismus surgery on health-related quality of life in adults. *Curr Opin Ophthalmol.* 2014;25(5):406–410.

## Planning Considerations

### Vision

When a child has amblyopia, some surgeons prefer to treat the amblyopia before strabismus surgery, whereas others believe that the prognosis for binocular vision is better if surgery is not delayed. If a patient has dense amblyopia or permanent vision loss due to other causes, surgery is usually performed only on the eye with poor vision.

### General Considerations

#### *Symmetric surgery*

The amount of surgery is based on the size of the preoperative deviation. One commonly used surgical formula for medial rectus muscle recession or lateral rectus muscle resection for esodeviations is given in Table 14-1 (also see the section Rectus Muscle Tightening Procedures, later in this chapter). Surgical options for infants with large-angle esotropia ( $>60$  prism diopters  $[\Delta]$ ) include combined recession-resection of 3 or 4 horizontal rectus muscles or bilateral medial rectus muscle recessions of 7.0 mm. Augmentation of the latter with botulinum toxin has been advocated.

A commonly used surgical formula for exodeviation is provided in Table 14-2. Some surgeons use bilateral lateral rectus muscle recessions of 9.0 mm or greater for deviations larger than  $40\Delta$ . Others prefer to limit lateral rectus recession to no more than 8.0 mm and add resection of 1 or both medial rectus muscles for larger-angle exotropias.

Lueder GT, Galli M, Tychsen L, Yildirim C, Pegado V. Long-term results of botulinum toxin-augmented medial rectus recessions for large-angle infantile esotropia. *Am J Ophthalmol.* 2012;153(3):560–563.

**Table 14-1 Surgical Amounts for Esodeviation**

Angle of Esotropia, $\Delta$	Recession MR OU, mm	or	Resection LR OU, mm
15	3.0		4.0
20	3.5		5.0
25	4.0		6.0
30	4.5		7.0
35	5.0		8.0
40	5.5		9.0
50	6.0		9.0

LR = lateral rectus; MR = medial rectus; OU = both eyes (*oculi uterque*).

**Table 14-2 Surgical Amounts for Exodeviation**

Angle of Exotropia, $\Delta$	Recession LR OU, mm	or	Resection MR OU, mm
15	4.0		3.0
20	5.0		4.0
25	6.0		5.0
30	7.0		6.0
40	8.0		7.0

LR = lateral rectus; MR = medial rectus; OU = both eyes (*oculi uterque*).

### ***Monocular horizontal rectus recess-resect procedures***

The values given in Tables 14-1 and 14-2 may also be used in unilateral recess-resect procedures, with the surgeon selecting the appropriate number of millimeters for each muscle. For example, for an esotropia measuring  $30\Delta$ , the surgeon would recess the medial rectus muscle by 4.5 mm and resect the lateral rectus muscle by 7.0 mm. For an exodeviation measuring  $15\Delta$ , the surgeon would recess the lateral rectus muscle by 4.0 mm and resect the antagonist medial rectus muscle by 3.0 mm. Unilateral surgery for exotropia beyond the given values (ie,  $>40\Delta$ ) is likely to result in a limited rotation; thus, a 3- or 4-muscle procedure is preferable if there is at least moderately good vision in each eye.

### **Incomitance**

When the size of the deviation varies in different gaze positions, the surgical plan should be designed with a goal of making the postoperative alignment more comitant.

#### ***Vertical incomitance of horizontal deviations***

The treatment of horizontal deviations that differ in magnitude in upgaze and downgaze—such as *A* or *V patterns*—is discussed in Chapter 10.

#### ***Horizontal incomitance***

When the size of the esodeviation or exodeviation changes significantly between right and left gaze, paresis, paralysis, or restriction is suggested. In general, restrictions must be relieved for surgery to be effective, and the surgical amounts usually used to correct a misalignment of a given size may not be applicable.

When there is no restriction to account for an incomitant deviation, the deviation is treated as if it were caused by a weak muscle, whether from neurologic, traumatic, or other causes. If the weak muscle exhibits little or no force generation, transposition procedures are usually indicated. Otherwise, treatment consists of some combination of resection of the weak muscle (or advancement if it has been previously recessed) and weakening of its direct antagonist or yoke muscle.

In some cases, both restriction and weakness are present, particularly in long-standing parietic or paralytic strabismus, and a combination of treatment strategies is necessary. Forced duction and active force generation testing are helpful in these cases.

**Distance–near incomitance**

Treatment of horizontal distance–near incomitance has classically consisted of medial rectus muscle surgery for deviations greater at near and lateral rectus muscle surgery for deviations greater at distance. Evidence suggests that, regardless of which muscles are operated on, the improvement in distance–near incomitance is similar.

Archer SM. The effect of medial versus lateral rectus muscle surgery on distance–near incomitance. *J AAPOS*. 2009;13(1):20–26.

**Cyclovertical Strabismus**

In many patients with cyclovertical strabismus, the deviation differs between right and left gaze and, on the side of the greater deviation, often between upgaze and downgaze as well. In general, surgery should be performed on those muscles whose field of action corresponds to the greatest vertical deviation unless results of forced duction testing reveal contracture that requires a weakening procedure for a restricted muscle. For example, for a patient with a right hypertropia that is greatest down and to the patient's left, the surgeon should consider either tightening the right superior oblique muscle or weakening the left inferior rectus muscle. (Tightening and weakening of the oblique muscles are discussed later in this chapter.) If the right hypertropia is the same in left upgaze, straight left gaze, and left downgaze, then any of the 4 muscles whose greatest vertical action is in left gaze may be chosen for surgery. In this example, the left superior rectus muscle or right superior oblique muscle could be tightened, or the left inferior rectus muscle or right inferior oblique muscle could be weakened. Larger deviations may require surgery on more than 1 muscle.

**Prior Surgery**

In the surgical treatment of residual or recurrent strabismus after previous surgery, procedures on EOMs that have not undergone prior surgery are technically easier and somewhat more predictable than on those that have. Unfortunately, when previous surgery has resulted in muscle restriction or weakness with limited duction (due to excessive recession or slipped or “lost” muscle), reoperation on the involved muscle is usually necessary. If the restriction is a result of retinal detachment surgery, correction can usually be accomplished without removal of scleral explants. For an eye that has previously undergone glaucoma surgery such as trabeculectomy or implantation of a tube shunt, strabismus surgery should be planned to minimize the risk of disrupting the filtering bleb.

**Surgical Techniques for the Extraocular Muscles and Tendons**

Step-by-step descriptions of each surgical procedure are beyond the scope of this volume. See the Basic Texts section of this volume for a list of texts describing surgical technique.

**Approaches to the Extraocular Muscles****Fornix incision**

The fornix incision (Video 14-1) is made in either the superior or, more frequently, the inferior quadrant. The incision is located on bulbar conjunctiva, not actually in the fornix,

1–2 mm to the limbal side of the cul-de-sac, so that bleeding is minimized. The incision is made parallel to the fornix and is approximately 8–10 mm in length.



**VIDEO 14-1** Fornix incision.

Access all Section 6 videos at [www.aao.org/bcscvideo\\_section06](http://www.aao.org/bcscvideo_section06).



Bare sclera is exposed by incising the Tenon capsule deep to the conjunctival incision. Using this exposed bare sclera, the surgeon engages the muscle with a succession of muscle hooks. The conjunctival incision is pulled over the hook that has passed under the muscle. All 4 rectus muscles and both oblique muscles can be explored, if necessary, through inferotemporal and superonasal conjunctival incisions.

When properly placed, the 2-plane incision can be self-closing at the end of the operation by gentle massage of the tissues into the fornix, with the edges of the incision splinted by the overlying eyelid. Some surgeons prefer to close the incision with conjunctival sutures.

### **Limbal incision**

The fused layer of conjunctiva and Tenon capsule is cleanly severed from the limbus. Some surgeons make the limbal incision (*peritomy*) 1–2 mm posterior to the limbus to spare limbal stem cells (Video 14-2). A short radial incision is made at each end of the peritomy so that the flap of conjunctiva and Tenon capsule can be retracted to expose the muscle for surgery. At the completion of the operation, the flap is reattached, without tension, close to its original position with a single suture at each corner. If the conjunctiva is restricted from prior surgery or shortened by a long-standing deviation, closure should involve recession of the anterior edge.



**VIDEO 14-2** Limbal incision.



### **Rectus Muscle Weakening Procedures**

Table 14-3 defines various rectus muscle weakening procedures and describes when each is used. The most common is simple recession (Video 14-3), for which typical amounts of surgery for esotropia and exotropia are given in Tables 14-1 and 14-2, respectively. Because the conventional technique for rectus muscle recession involves passing sutures within thin sclera with the attendant risk of perforation, some surgeons prefer a *hang-back recession*, in which the recessed tendon is suspended by sutures that pass through the thicker stump of the original insertion. Although it is not known where the tendon reattaches to the sclera, empirical experience indicates that this method is usually reliable.



**VIDEO 14-3** Recession of extraocular rectus muscle.

Courtesy of Scott A. Larson, MD, Ronald Price, MD, and George Beauchamp, MD.



### **Rectus Muscle Tightening Procedures**

Although also referred to as strengthening procedures, muscle tightening procedures (defined in Table 14-4) do not actually give the muscles more strength. Rather, they produce a tightening effect that tends to offset the opposite action of the antagonist muscle. For



**Table 14-3 Weakening Procedures Used in Strabismus Surgery**

Procedure	Indications
<i>Myotomy</i> : cutting across a muscle	Used by some surgeons to weaken the inferior oblique muscles
<i>Myectomy</i> : removal of a portion of muscle	
<i>Marginal myotomy</i> : cutting partway across a muscle, usually following a maximal recession	Used to weaken a rectus muscle further
<i>Tenotomy</i> : cutting across a tendon	
<i>Tenectomy</i> : removal of a portion of tendon	Both used routinely to weaken the superior oblique muscle; some surgeons interpose silicone spacers to control the weakening effect
<i>Recession</i> : removal and reattachment of a muscle (rectus or oblique) so that its insertion is closer to its origin	The standard weakening procedure for rectus muscles
<i>Denervation and extirpation</i> : ablation of the entire portion of the muscle, along with its nerve supply, within the Tenon capsule	Used only on severely or recurrently overacting inferior oblique muscles
<i>Recession and anteriorization</i> : movement of the muscle's insertion anterior to its original position	Used primarily on the inferior oblique muscle to reduce its elevating action; particularly useful with coexisting inferior oblique overaction and DVD
<i>Posterior fixation suture (fadenoperation)</i> : attachment of a rectus muscle to the sclera 11–18 mm posterior to the insertion using a nonabsorbable suture; fixation to the muscle's pulley may be an alternative for medial rectus muscles	Used to weaken a muscle by decreasing its mechanical advantage; often used in conjunction with recession; sometimes used in high AC/A ratio accommodative esotropia and in incomitant strabismus

AC/A = accommodative convergence/accommodation; DVD = dissociated vertical deviation.

**Table 14-4 Tightening Procedures Used in Strabismus Surgery**

Procedure	Indication
<i>Resection</i> : removal of a segment of muscle followed by reattachment to the original insertion	The standard tightening procedure for rectus muscles
<i>Advancement</i> : movement of a previously recessed muscle toward its insertion	Used to correct a consecutive deviation
<i>Tuck</i> : folding and securing, reducing tendon length	Used on the superior oblique tendon
<i>Plication</i> : folding and securing to the sclera	Used on rectus muscles to impart a similar effect as resection

this purpose, surgeons usually use the *resection* technique (Video 14-4); typical amounts of surgery for esotropia and exotropia are given in Tables 14-1 and 14-2, respectively. *Plication* of the muscle can be used as an alternative to produce a similar effect. A previously recessed rectus muscle can also be tightened by *advancing* its insertion toward the limbus.



**VIDEO 14-4** Resection of extraocular rectus muscle.  
Courtesy of Scott A. Larson, MD, and Johanna Beebe, MD.



## Rectus Muscle Surgery for Hypotropia and Hypertropia

For reasonably comitant vertical deviations, recession and resection of vertical rectus muscles are appropriate. Recessions are generally preferred as a first procedure. Approximately

$3\Delta$  of correction in primary position can be expected for every millimeter of vertical rectus muscle recession. For comitant vertical deviations less than  $10\Delta$  that accompany horizontal deviations, displacement of the reinsertions of the horizontal rectus muscles in the same direction, by approximately one-half the tendon width (up for hypotropia, down for hypertropia), performed during a recess-resect procedure, is often sufficient.

### Adjustable Sutures

Some surgeons use adjustable sutures (Video 14-5) to avoid an immediately obvious poor result or to increase the likelihood of success with 1 operation, but this modification does not ensure long-term satisfactory alignment. The surgeon completes the operation using externalized sutures and slip knots that enable the position of the surgical muscle to be altered during the early postoperative period. This technique can be used in children; however, general anesthesia is usually required.

Another alternative, used mainly in adults, is performance of surgery with the patient awake. Anesthetic agents that might affect ocular motility are avoided, and the patient's dynamic ocular motility and ocular alignment are observed and adjusted at the time of surgery. This technique can be difficult in patients with significant scarring, individuals with thyroid eye disease, and children.



**VIDEO 14-5** Adjustable sutures for extraocular rectus muscles.  
*Courtesy of Scott A. Larson, MD.*



### Oblique Muscle Weakening Procedures

#### *Weakening the inferior oblique muscle*

Table 14-3 lists muscle weakening procedures, including those involving the inferior oblique muscle. These procedures are most commonly used for treatment of overelevation in adduction when it is believed to be due to inferior oblique muscle overaction. In all these procedures, the surgeon must be sure that the entire inferior oblique muscle is weakened, because the distal portion and the insertion can be anomalously duplicated (Videos 14-6, 14-7).



**VIDEO 14-6** Strabismus surgery: inferior oblique—partial and complete hooking.  
*Courtesy of John D. Ferris, FRCOphth, and Peter E. J. Davies, FRANZCO, MPH.*



**VIDEO 14-7** Inferior oblique weakening procedures.



In cases that show marked asymmetry of the overactions of the inferior oblique muscles and no superior oblique muscle paralysis, unilateral surgery only on the muscle with the more prominent overaction is often followed by a significant degree of overaction in the fellow eye. Therefore, some surgeons recommend bilateral inferior oblique muscle weakening for asymmetric cases. A symmetric result is the rule and overcorrections are rare; however, inferior oblique muscles that are not overacting at all—even when there is overaction in the fellow eye—should not be weakened.

Secondary overaction of the inferior oblique muscle occurs in many patients who have superior oblique muscle paralysis. A weakening of that inferior oblique muscle typically corrects up to  $15\Delta$  of vertical deviation in primary position. The amount of vertical correction is roughly proportional to the degree of preoperative overaction (see Chapter 11). Frequently, a weakening procedure is performed on each inferior oblique muscle for V-pattern strabismus (see Chapter 10).

Moving the insertion of the inferior oblique muscle anteriorly to a point adjacent to the lateral border of the inferior rectus muscle (*inferior oblique anterior transposition, inferior oblique anteriorization*) weakens the normal actions of the inferior oblique. Because the neurofibrovascular bundle along the lateral border of the inferior rectus muscle can then serve as the effective origin for the distal portion of the muscle, anteriorization also allows the inferior oblique muscle to actively oppose elevation of the eye; that is, this muscle becomes an anti-elevator (see Chapter 3). This procedure is effective for treatment of dissociated vertical deviation (DVD) and is especially useful when DVD and inferior oblique overaction coexist.

### ***Weakening the superior oblique muscle***

Procedures to weaken the superior oblique muscle include tenotomy (Video 14-8); tenectomy; split-tendon lengthening; placement of a spacer of silicone, fascia lata, or nonabsorbable suture between the cut edges of the tendon to functionally lengthen it; and recession. The purpose of spacers is to prevent an excessive gap between the cut edges, but they have the disadvantage of possible adhesion formation, which can alter motility. Unilateral weakening of a superior oblique muscle is not commonly performed except as treatment for Brown syndrome (see Chapter 12) or for isolated inferior oblique muscle weakness, which is rare. Unilateral superior oblique muscle weakening can affect not only vertical alignment but also torsion, potentially creating undesired extorsion. Many ophthalmologists favor a tenotomy of only the posterior 75%–80% of the tendon to preserve the torsional action, which is controlled by the most anterior tendon fibers.



**VIDEO 14-8** Superior oblique muscle tenotomy.



Bilateral weakening of the superior oblique muscle can be performed for A-pattern deviations and can be expected to cause an eso-shift in downgaze and almost no change in upgaze. If this procedure is performed on patients with normal binocularity, it may cause vertical or torsional strabismus with subsequent diplopia, which must be considered and discussed with the patient preoperatively.

## **Oblique Muscle Tightening Procedures**

### ***Tightening the inferior oblique muscle***

Inferior oblique muscle tightening is seldom performed. To be effective, advancement of the inferior oblique muscle requires reinsertion more posteriorly and superiorly, which is technically difficult and exposes the macula to possible injury.

### ***Tightening the superior oblique muscle***

Tightening the superior oblique tendon is discussed in Chapter 11. Tucking the superior oblique tendon enhances both its vertical and torsional effects (Video 14-9). The anterior half of the superior oblique tendon alone may be advanced temporally and somewhat anteriorly, in the *Fells modification of the Harada-Ito procedure*, to reduce extorsion in patients with superior oblique muscle paralysis (Video 14-10).



**VIDEO 14-9** Superior oblique tucking.



**VIDEO 14-10** Strabismus surgery: Fells modification of the Harada-Ito procedure.

*Courtesy of John D. Ferris, FRCOphth, and Peter E. J. Davies, FRANZCO, MPH.*



### **Stay Sutures**

A stay (pull-over) suture is a temporary suture that is attached to the sclera at the limbus or under a rectus muscle insertion, brought out through the eyelids, and secured to periocular skin over a bolster to fix the eye in a selected position during postoperative healing. Some surgeons believe that this technique is particularly useful in cases with severely restricted ocular rotations. Its disadvantages are that patients experience some discomfort and that the limbal attachment of the stay suture tends to be lost before the desired interval of 10–14 days after placement.

### **Transposition Procedures**

Transposition procedures involve redirection of the paths of the EOMs. In the treatment of sixth nerve palsy, Duane retraction syndrome, and monocular elevation deficiency, these procedures utilize 1 or both muscles adjacent to the abnormal muscle to provide a tonic force vector (Video 14-11). The effect of the transposition can be augmented by resecting the transposed muscles or by using offset posterior fixation sutures (*Foster modification*). Vertical deviations are a possible complication of vertical rectus muscle transposition surgery. Transposition of only the superior rectus muscle, combined with recession of the medial rectus muscle, can also be effective.



**VIDEO 14-11** Strabismus surgery: lateral rectus and medial rectus inferior full-tendon transfers.

*Courtesy of John D. Ferris, FRCOphth, and Peter E. J. Davies, FRANZCO, MPH.*



### **Posterior Fixation**

Posterior fixation is a procedure in which a rectus muscle is sutured to the sclera far posterior to its insertion. The result is weakening of the muscle in its field of action with little or no effect on the alignment in primary position. This procedure is particularly useful for treatment of incomitant strabismus. A similar effect may be achieved, at least for medial rectus muscles, by fixation to the muscle pulley.

## Complications of Strabismus Surgery

---

### Diplopia

Diplopia can occur after strabismus surgery, occasionally in older children but more often in adults. Surgery can move the fixated image out of a suppression scotoma. In the several months following surgery, various responses are possible:

- Fusion of the 2 images may occur.
- A new suppression scotoma may form, corresponding to the new angle of alignment. If the initial strabismus was acquired before age 10 years, the ability to suppress is generally well developed.
- Diplopia may persist.

Prolonged postoperative diplopia is uncommon. However, if strabismus was first acquired in adulthood, diplopia that was symptomatic before surgery is likely to persist unless comitant alignment and fusion are regained. Prisms that compensate for the deviation may be helpful during the preoperative evaluation to assess the fusion potential and the risk of bothersome postoperative diplopia.

A patient with unequal vision can often ignore the dimmer, more blurred image. Further treatment is indicated for patients whose symptomatic diplopia persists after surgery, especially if it is severe and present in the primary position. If vision in the eyes is equal or nearly so, temporary or permanent prisms should be tried to address any residual diplopia. If this approach fails, additional surgery or botulinum toxin injection may be considered. In some cases, intractable diplopia can be controlled only by occluding or blurring the less-preferred eye with a MIN lens (Fresnel, Bloomington, MN), Bangerter foil (Ryser, St Gallen, Switzerland), or Scotch Magic Tape (3M, St Paul, MN).

### Unsatisfactory Alignment

Unsatisfactory postoperative alignment—overcorrection, undercorrection, or development of an entirely new strabismus problem—is perhaps better characterized as a disappointing outcome of strabismus surgery, rather than as a complication. Alignment in the immediate postoperative period, whether satisfactory or not, may not be permanent. Among the reasons for this unpredictability are poor fusion, poor vision, and contracture of scar tissue. Reoperations are often necessary.

### Iatrogenic Brown Syndrome

Iatrogenic Brown syndrome can result from superior oblique muscle tightening procedures. Taking care to avoid excessive tightening of the tendon when these procedures are performed minimizes the risk of this complication. A tuck can sometimes be reversed if reoperation is undertaken soon after the original surgery. Observation is also an option, as superior oblique tucks tend to loosen with time (see Chapter 12).

### Anti-Elevation Syndrome

Inferior oblique anteriorization can result in restricted elevation of the eye in abduction, known as *anti-elevation syndrome*. Reattaching the lateral corner of the muscle anterior to

the spiral of Tillaux increases the risk of this syndrome; “bunching up” the insertion at the lateral border of the inferior rectus muscle may reduce the risk.

### Lost and Slipped Muscles

A rectus muscle that sustains trauma or that slips out of the sutures or instruments while unattached to the globe during an operation can retract through the Tenon capsule and become inaccessible (“lost”) posteriorly in the orbit. This consequence is most severe when it involves the medial rectus muscle, because that muscle is the most difficult to recover.

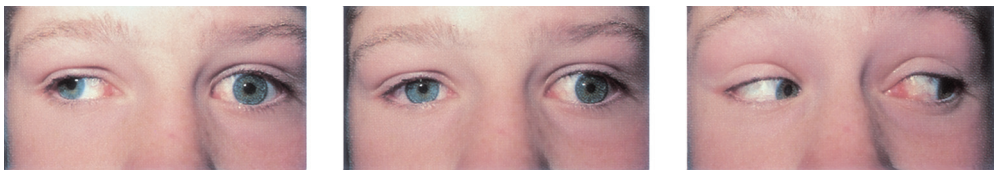The surgeon should immediately attempt to find the lost muscle, if possible with the assistance of a surgeon experienced in this potentially complex surgery. Malleable retractors and a headlight are helpful. Minimal manipulation should be used to bring into view the anatomical site through which the muscle and its sheath normally penetrate the Tenon capsule where, it is hoped, the distal end of the muscle can be recognized and captured. If inspection does not reliably indicate that the muscle has been identified, sudden bradycardia when traction is exerted can be confirmatory. Recovery of the medial rectus muscle has been achieved by using a transnasal endoscopic approach through the ethmoid sinus or by performing a medial orbitotomy. Transposition surgery may be required if the lost muscle is not found, but anterior segment ischemia may be a risk. Where to reattach the recovered muscle depends on several factors in the particular case and is largely a matter of judgment.

A slipped muscle is the result of inadequate imbrication of the muscle during strabismus surgery, which allows it to recede posteriorly within its capsule postoperatively. Clinically, the patient manifests a weakness of that muscle immediately postoperatively, with limited rotations and possibly decreased saccades in its field of action (Fig 14-1). Surgery should be performed as soon as possible in order to secure the muscle before further retraction and contracture take place.

In reoperations for strabismus with deficient rotations, slippage or a stretched scar should be suspected and the involved muscles explored. The pseudotendon must be excised to restore the function of the muscle.

### Pulled-in-Two Syndrome

Dehiscence of a muscle during surgery has been termed *pulled-in-two syndrome (PITS)*. The dehiscence usually occurs at the tendon–muscle junction, and the inferior rectus may be the most frequently affected muscle. Advanced age, various myopathies, previous surgery, trauma, or infiltrative disease may predispose a muscle to PITS by weakening



**Figure 14-1** Slipped left medial rectus muscle. *Left*, Gaze right shows inability to adduct the left eye. *Center*, Exotropia in primary position. *Right*, Gaze left shows full abduction. Note that the left palpebral fissure is wider than the right, especially with attempted adduction.

its structural integrity. Treatment is recovery, when possible, using techniques similar to those used for lost muscles, and re-anastomosis of the muscle.

### Perforation of the Sclera

During reattachment of an EOM, a needle may penetrate the sclera and pass into the supra-choroidal space or perforate the choroid and retina. Perforation can lead to retinal detachment or endophthalmitis (see BCSC Section 9, *Uveitis and Ocular Inflammation*); in most cases, it results in only a small chorioretinal scar, with no effect on vision. Most perforations are unrecognized unless specifically looked for by ophthalmoscopy. If vitreous escapes through the perforation site, many surgeons apply immediate local cryotherapy or laser therapy. Topical antibiotics are generally given during the immediate postoperative period, even when vitreous has not escaped. Ophthalmoscopy during the postoperative period is an appropriate precaution, with referral to a retina consultant if needed.

### Postoperative Infections

Intraocular infection is uncommon following strabismus surgery. Mild conjunctivitis develops in some patients and may be caused by allergy to suture material or postoperative medications, as well as by infectious agents. Preseptal and orbital cellulitis with proptosis, eyelid swelling, chemosis, and fever are rare (Fig 14-2). These conditions usually develop 2–3 days after surgery and generally respond well to systemic antibiotics. Patients should be warned of the signs and symptoms of orbital cellulitis and endophthalmitis and instructed to seek emergency consultation if necessary.

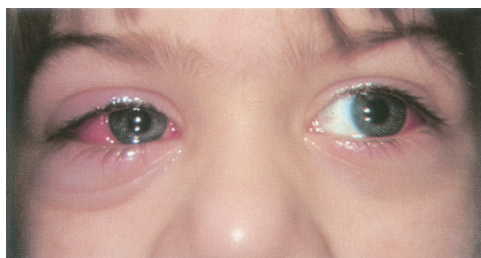### Pyogenic Granuloma and Foreign-Body Granuloma

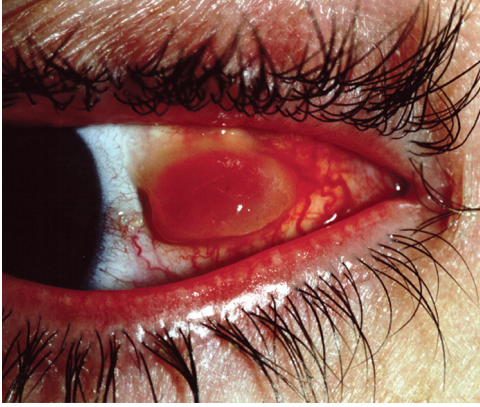Pyogenic granuloma (lobular capillary hemangioma) consists of a lobular proliferation of capillaries with edema that typically develops at the conjunctival incision site (Fig 14-3). It is prone to ulceration or bleeding but usually resolves spontaneously. Persistent lesions may require surgical excision. In rare cases, suture can cause foreign-body granulomas and allergic reactions (Fig 14-4).

### Epithelial Cyst

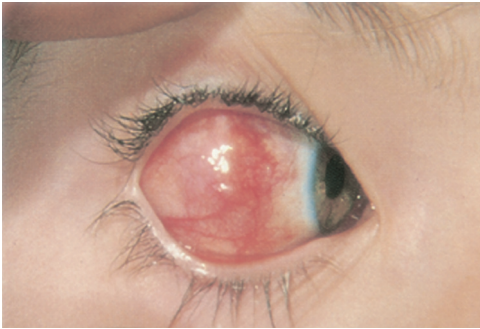
A noninflamed, translucent subconjunctival mass may develop if conjunctival epithelium is buried during muscle reattachment or incision closure (Fig 14-5). Occasionally, the cyst resolves spontaneously. Topical steroids may be helpful; persistent cases may require

**Figure 14-2** Orbital cellulitis, right eye, 2 days after bilateral recession of the lateral rectus muscles.

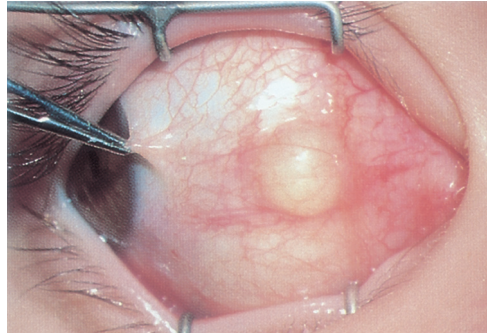




**Figure 14-3** Postoperative pyogenic granuloma over the left lateral rectus muscle. (From Espinoza GM, Lueder GT. Conjunctival pyogenic granulomas after strabismus surgery. *Ophthalmology*. 2005;112(7):1283–1286.)



**Figure 14-4** Allergic reaction to chronic gut suture. Allergic reactions are rare with modern synthetic suture material such as polyglactin.



**Figure 14-5** Postoperative epithelial cyst following right medial rectus muscle recession.

surgical excision. In some cases, the cyst is incorporated into the muscle tendon, so careful exploration is mandatory to identify this complication.

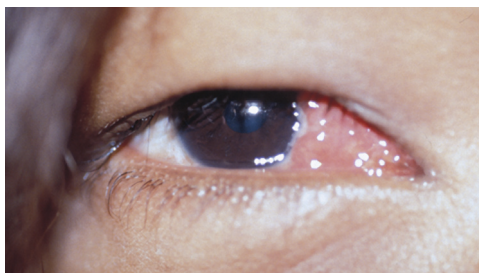
### Conjunctival Scarring

Satisfaction from improved alignment may occasionally be overshadowed by unsightly scarring of the conjunctiva and the Tenon capsule. The tissues remain hyperemic and salmon pink instead of returning to their usual whiteness. This complication may occur as a result of the following:

- *Advancement of thickened Tenon capsule too close to the limbus.* In resection procedures, pulling the muscle forward may advance the Tenon capsule. The undesirable result is exaggerated in reoperations, when the Tenon capsule may be hypertrophied.
- *Advancement of the plica semilunaris.* During surgery on the medial rectus muscle using the limbal approach, the surgeon may mistake the plica semilunaris for a conjunctival edge and incorporate it into the closure. Though not strictly a conjunctival scar, the advanced plica, now pulled forward and hypertrophied, retains its fleshy color (Fig 14-6).



**Figure 14-6** Hypertrophy involving the plica semilunaris. (Courtesy of Scott Olitsky, MD.)



Treatment options include conjunctivoplasty with resection of scarred conjunctiva and transposition of adjacent conjunctiva, resection of subconjunctival fibrous tissue, recession of scarred conjunctiva, and amniotic membrane grafting.

### **Adherence Syndrome**

Tears in the Tenon capsule with prolapse of orbital fat into the sub-Tenon space can cause formation of a fibrofatty scar that may restrict ocular motility. Surgery involving the inferior oblique muscle is particularly prone to this complication because of the proximity of the fat space to the posterior border of the inferior oblique muscle. If recognized at the time of surgery, the prolapsed fat can be excised and the rent closed with absorbable sutures. Meticulous surgical technique usually prevents this serious complication.

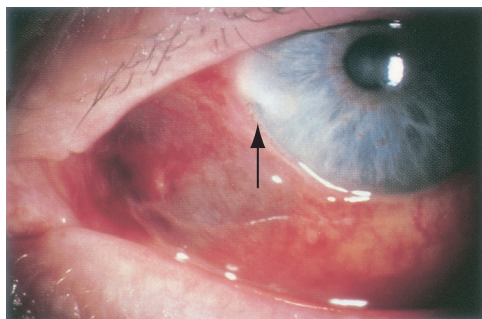
### **Delle**

A *delle* (plural *dellen*) is a shallow area of corneal thinning near the limbus. Dellen occur when raised abnormal bulbar conjunctiva prevents adequate lubrication of the cornea adjacent to the raised conjunctiva (Fig 14-7). Dellen are more likely to occur when the limbal approach to EOM surgery is used. They usually heal with time. Artificial tears or lubricants may be used until the chemosis subsides.

### **Anterior Segment Ischemia**

The blood supply to the anterior segment of the eye is provided, in part, by the anterior ciliary arteries that travel with the 4 rectus muscles. Simultaneous surgery on 3 rectus muscles, or even 2 rectus muscles in patients with poor blood circulation, may therefore

**Figure 14-7** Corneal delle (*arrow*) subsequent to postoperative subconjunctival hemorrhage.



lead to anterior segment ischemia (ASI). The earliest signs of this complication are cells and flare in the anterior chamber. More severe cases are characterized by corneal epithelial edema, folds in the Descemet membrane, and an irregular pupil (Fig 14-8). This complication may lead to anterior segment necrosis and phthisis bulbi. No universally agreed-upon treatment exists for ASI. Because the signs of ASI are similar to those of uveitis, most ophthalmologists treat with topical, subconjunctival, or systemic corticosteroids, although there is no firm evidence supporting this approach.

It is possible to recess, resect, or transpose a rectus muscle while sparing its anterior ciliary vessels. Though difficult and time consuming, this technique may be indicated in high-risk cases. Staging surgery, with an interval of several months between procedures, may also be helpful. Because the anterior segment is partially supplied by the conjunctival circulation through the limbal arcades, using fornix instead of limbal incisions may provide some protection against the development of ASI.

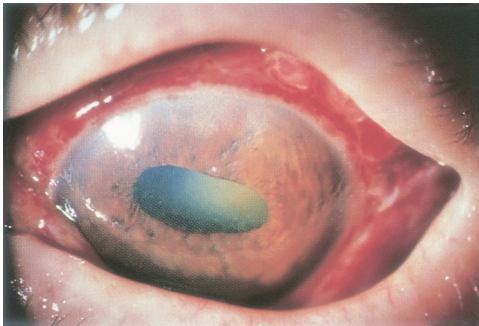
### Change in Eyelid Position

Change in the position of the eyelids is most likely to occur with surgery on the vertical rectus muscles. Pulling the inferior rectus muscle forward, as in a resection, advances the lower eyelid upward; recessing this muscle pulls the lower eyelid down, exposing sclera below the lower limbus (Fig 14-9). Surgery on the superior rectus muscle is less likely to affect upper eyelid position.

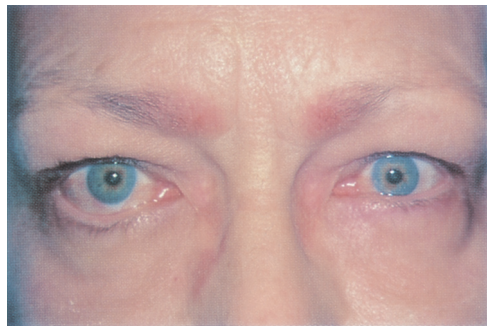
Changes in eyelid position can be obviated somewhat by careful dissection. In general, all intermuscular septum and fascial connections of the vertical rectus muscle must be severed at least 12–15 mm posterior to the muscle insertion. Release of the lower eyelid retractors or advancement of the capsulopalpebral head is helpful to prevent lower eyelid retraction after inferior rectus muscle recession.

### Refractive Changes

Changes in refractive error are most common when strabismus surgery is performed on 2 rectus muscles of an eye. An induced astigmatism of low magnitude usually resolves



**Figure 14-8** Superotemporal segmental anterior segment ischemia after simultaneous superior rectus muscle and lateral rectus muscle surgery following a scleral buckling procedure.



**Figure 14-9** Patient treated for left hypertropia by recession of the right inferior rectus muscle, which pulled the right lower eyelid down, and resection of the left inferior rectus muscle, which pulled the left lower eyelid up.

within a few months. Surgery on the oblique muscles can change the axis of preexisting astigmatism.

Kushner BJ. The effect of oblique muscle surgery on the axis of astigmatism. *J Pediatr Ophthalmol Strabismus*. 1986;23(6):277–280.

## Anesthesia for Extraocular Muscle Surgery

---

### Methods

In cooperative patients, topical anesthetic eyedrops alone (eg, tetracaine 0.5%, proparacaine 0.5%, lidocaine 2%) are effective for most steps in an EOM surgical procedure. Topical anesthesia is not effective for control of the pain produced by pulling on or against a restricted muscle or for cases in which exposure is difficult.

Both peribulbar and retrobulbar anesthesia make most EOM procedures pain-free and should be considered in adults for whom general anesthesia may pose an undue hazard. The administration of a short-acting hypnotic by an anesthesiologist just before retrobulbar injection greatly improves patient comfort. Because injected anesthetics may influence alignment during the first few hours after surgery, suture adjustment is best delayed for at least half a day.

General anesthesia is necessary for children and is often used for adults as well, particularly those requiring bilateral surgery. Neuromuscular blocking agents such as succinylcholine, which are administered to facilitate intubation for general anesthesia, can temporarily affect the results of a traction test. Nondepolarizing agents, which do not have this effect, can be used instead.

### Postoperative Nausea and Vomiting

Eye muscle surgery is a risk factor for postoperative nausea and vomiting. This risk can be reduced by prophylaxis with dexamethasone and serotonin type 3 (5-HT<sub>3</sub>) antagonists (eg, ondansetron), propofol use, adequate hydration, and reduced use of inhalation anesthetics and opioid analgesia.

### Oculocardiac Reflex

The oculocardiac reflex is a slowing of the heart rate caused by traction on the EOMs, particularly the medial rectus muscle. In its most severe form, the reflex can produce asystole. The surgeon should be aware of the possibility of inducing the oculocardiac reflex when manipulating a muscle and should be prepared to release tension if the heart rate drops excessively. Intravenous atropine and other agents can protect against this reflex.

### Malignant Hyperthermia

*Malignant hyperthermia (MH)* is an important disorder for pediatric ophthalmologists because of its association with strabismus, myopathies, ptosis, and musculoskeletal

abnormalities. MH is a defect of calcium binding by the sarcoplasmic reticulum of skeletal muscle that can occur sporadically or be dominantly inherited with incomplete penetrance. When MH is triggered by inhalational anesthetics or the muscle relaxant succinylcholine, unbound intracellular calcium concentration increases. This stimulates muscle contraction, causing massive acidosis. In its fully developed form, MH is characterized by extreme heat production, resulting from the hypermetabolic state.

MH can be fatal if diagnosis and treatment are delayed. The earliest sign is unexplained elevation of end-tidal carbon dioxide concentration. As soon as the diagnosis is made, surgery should be terminated, even if incomplete. Treatment is in the province of the anesthesiologist. See also BCSC Section 1, *Update on General Medicine*.

## Chemodenervation Using Botulinum Toxin

---

### Pharmacology and Mechanism of Action

Botulinum toxin type A paralyzes muscles by blocking the release of acetylcholine at the neuromuscular junction. This agent has a number of uses, but it was originally developed for the treatment of strabismus. Within 24–48 hours of injection, botulinum toxin is bound and internalized within local motor nerve terminals, where it remains active for many weeks. Paralysis of the injected EOM begins within 2–4 days of injection and lasts clinically for at least 5–8 weeks. This produces, in effect, a pharmacologic recession: the EOM lengthens while it is paralyzed by botulinum toxin, and its antagonist contracts. These changes may produce long-term improvement in the alignment of the eyes. The recent introduction of bupivacaine injection into the antagonist muscle to provide a chemical resection effect may extend the durability of the correction and expand the range of deviations in which chemodenervation can be successfully used.

Debert I, Miller JM, Danh KK, Scott AB. Pharmacologic injection treatment of comitant strabismus. *J AAPOS*. 2016;20(2):106–111.

Scott AB. Botulinum toxin injection of eye muscles to correct strabismus. *Trans Am Ophthalmol Soc*. 1981;79:734–770.

### Indications, Techniques, and Results

Clinical trials using botulinum toxin for the treatment of strabismus have shown this agent to be most effective in the following conditions:

- small- to moderate-angle esotropia and exotropia ( $<40\Delta$ )
- postoperative residual strabismus (2–8 weeks following surgery or later)
- acute paralytic strabismus (especially sixth nerve palsy; sometimes fourth nerve palsy), to eliminate diplopia while the palsy resolves
- active thyroid eye disease (Graves disease) or inflamed or pre-phthisical eyes, when surgery is inappropriate
- as a supplement to medial rectus muscle recession for large-angle infantile esotropia or lateral rectus muscle recession for large-angle exotropia

When used to treat patients with strabismus, the toxin is injected directly, with a small-gauge needle, into selected EOMs. Injections into the EOMs may be performed with the use of a portable electromyographic device, although experienced practitioners often dispense with electromyography. In adults, injections are performed with topical anesthetic; in children, general anesthesia is usually necessary (Videos 14-12, 14-13).



**VIDEO 14-12** Strabismus surgery: botulinum medial rectus under general anesthetic.

*Courtesy of John D. Ferris, FRCOphth, and Peter E. J. Davies, FRANZCO, MPH.*



**VIDEO 14-13** Strabismus surgery: botulinum medial rectus.

*Courtesy of John D. Ferris, FRCOphth, and Peter E. J. Davies, FRANZCO, MPH.*



Multiple injections may be required, particularly in adults. As with surgical treatment, results are best when there is fusion to stabilize the alignment. Botulinum toxin injection is usually not effective in patients with large deviations, restrictive or mechanical strabismus (trauma, chronic thyroid eye disease), or secondary strabismus wherein a muscle has been overly recessed. Injection is ineffective in A and V patterns, DVDs, and chronic paralytic strabismus. The long-term recovery rate for patients with acute sixth nerve palsy treated with observation alone is similar to that for patients who receive botulinum toxin.

## Complications

The most common adverse effects of ocular botulinum toxin treatment are ptosis, lagophthalmos, dry eye, and induced vertical strabismus after horizontal muscle injection. These complications are usually temporary, resolving after several weeks. Rare complications include scleral perforation, retrobulbar hemorrhage, pupillary dilation, and permanent diplopia. Systemic botulism has been reported in animals and humans following massive injections of large muscle groups, but this has not been encountered in ophthalmologic use of botulinum toxin.



**PART II**

Pediatric  
Ophthalmology



# Growth and Development of the Eye

## Normal Growth and Development

The human eye undergoes dramatic anatomical and physiologic development throughout infancy and early childhood (Table 15-1). Ophthalmologists caring for pediatric patients should be familiar with the normal growth and development of the child’s eye because departures from the norm may indicate pathology. See also BCSC Section 2, *Fundamentals and Principles of Ophthalmology*.

### Dimensions of the Eye

Most of the growth of the eye takes place in the first year of life. Change in the eye’s axial length occurs in 3 phases. The first phase (birth to age 2 years) is a period of rapid growth: the axial length increases by approximately 4 mm in the first 6 months of life and by an additional 2 mm during the next 6 months. During the second (age 2 to 5 years) and third (age 5 to 13 years) phases, growth slows, with axial length increasing by about 1 mm per phase.

Similarly, with growth of the globe, the corneal diameter increases rapidly during the first year of life. The average horizontal diameter of the cornea is 9.5–10.5 mm in newborns and increases to 12.0 mm in adults. The cornea also flattens in the first year such that keratometry values change markedly, from approximately 52.00 diopters (D) at birth, to 46.00 D by age 6 months, to adult measurements of 42.00–44.00 D by age 12 months. Mild corneal clouding may be seen in healthy newborns and is common in premature infants. It resolves as the cornea gradually becomes thinner, decreasing from an average central thickness of 691  $\mu\text{m}$  at 30–32 weeks’ gestation to 564  $\mu\text{m}$  at birth.

The power of the pediatric lens decreases dramatically over the first several years of life—an important consideration when intraocular lens implantation is planned for

**Table 15-1 Dimensions of Newborn and Adult Eyes**

	Newborn	Adult
Axial length, mm	14.5–15.5	23.0–24.0
Corneal horizontal diameter, mm	9.5–10.5	12.0
K value, diopters	52.00	42.00–44.00

K = keratometry.



infants and young children after cataract extraction. Lens power decreases from approximately 35.00 D at birth to about 23.00 D at age 2 years. Subsequently, the change is more gradual: lens power decreases to approximately 19.00 D by age 11 years, with little or no change thereafter.

Gordon RA, Donzis PB. Refractive development of the human eye. *Arch Ophthalmol*. 1985; 103(6):785–789.

Kirwan C, O’Keefe M, Fitzsimon S. Central corneal thickness and corneal diameter in premature infants. *Acta Ophthalmol Scand*. 2005;83(6):751–753.

## Refractive State

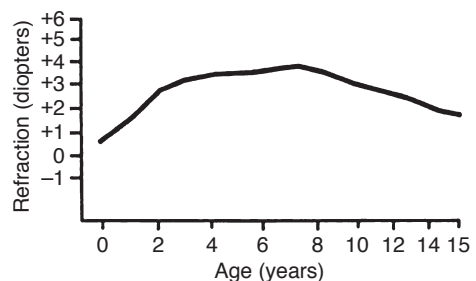
The refractive state of the eye changes as the eye’s axial length increases and the cornea and lens flatten. In general, eyes are hyperopic at birth, become slightly more hyperopic until approximately age 7 years, and then experience a myopic shift until reaching adult dimensions, usually by about age 16 years (Fig 15-1). *Emmetropization* in the developing eye refers to the combination of changes in the refractive power of the anterior segment and in axial length that drive the eye toward emmetropia. The reduction in astigmatism that occurs in many infant eyes and the decreasing hyperopia that occurs after age 6–8 years are examples of emmetropization.

Race, ethnicity, and heredity play a role in the risk of particular types of refractive error. For example, myopia is more common among African American children compared with Hispanic children and non-Hispanic white children. Hyperopia is more common among non-Hispanic white children compared with African American and Hispanic children. Astigmatism is more common among Hispanic children and African American children than non-Hispanic white children.

Myopia is increasingly prevalent worldwide, and it is estimated that by 2050, 50% of the world population will be myopic. If myopia develops before age 10 years, there is a higher risk of eventual progression to myopia of 6.00 D or more. The etiology of increased myopia prevalence is unclear, but urbanization, increased near work, and decreased exposure to ultraviolet light are suggested influences. Low-dose (0.01%) atropine has been shown to significantly decrease myopic progression in Asian children.

Borchert MS, Varma R, Cotter SA, et al; Joint Writing Committee for the Multi-ethnic Pediatric Eye Disease Study and the Baltimore Pediatric Eye Disease Study Groups. Risk factors for hyperopia and myopia in preschool children: the Multi-ethnic Pediatric Eye Disease and Baltimore Pediatric Eye Disease Studies. *Ophthalmology*. 2011;118(10):1966–1973.

**Figure 15-1** Change in mean refractive error as a function of age. (Modified with permission from Eustis HS, Guthrie ME. Postnatal development. In: Wright KW, Strube YNJ, eds. *Pediatric Ophthalmology and Strabismus*. 2nd ed. New York: Springer-Verlag; 2003:49.)



Chia A, Chua WH, Cheung YB, et al. Atropine for the treatment of childhood myopia: safety and efficacy of 0.5%, 0.1%, and 0.01% doses (Atropine for the Treatment of Myopia 2).

*Ophthalmology*. 2012;119(2):347–354.

Holden BA, Fricke TR, Wilson DA, et al. Global prevalence of myopia and high myopia and temporal trends from 2000 through 2050. *Ophthalmology*. 2016;123(5):1036–1042.

McKean-Cowdin R, Varma R, Cotter SA, et al; Multi-ethnic Pediatric Eye Disease Study and the Baltimore Pediatric Eye Disease Study Groups. Risk factors for astigmatism in preschool children: the Multi-ethnic Pediatric Eye Disease and Baltimore Pediatric Eye Disease Studies. *Ophthalmology*. 2011;118(10):1974–1981.

## Orbit and Ocular Adnexa

During infancy and childhood, orbital volume increases, and the orbital opening becomes less circular, resembling a horizontal oval. The lacrimal fossa becomes more superficial and the angle formed by the axes of the 2 orbits less divergent.

The palpebral fissure measures approximately 18 mm horizontally and 8 mm vertically at birth. Growth of the palpebral fissure is greater horizontally than vertically, resulting in the eyelid opening becoming less round and acquiring its elliptical adult shape. Most of the horizontal growth occurs in the first 2 years of life (see Chapter 17, Fig 17-1).

## Cornea, Iris, Pupil, and Anterior Chamber

Central corneal thickness (CCT) decreases during the first 6–12 months of life (see the section Dimensions of the Eye). It then increases from approximately 553  $\mu\text{m}$  at age 1 year to about 573  $\mu\text{m}$  by age 12 years and stabilizes thereafter. CCT is similar in white and Hispanic children, whereas African American children tend to have thinner corneas.

Most changes in iris color occur over the first 6–12 months of life, as pigment accumulates in the iris stroma and melanocytes. Compared with the adult pupil, the infant pupil is relatively small. A pupil diameter less than 1.8 mm or greater than 5.4 mm is suggestive of an abnormality. The pupillary light reflex is normally present after 31 weeks' gestational age. At birth, the iris insertion is near the level of the scleral spur, but during the first year of life, the lens and ciliary body migrate posteriorly, resulting in formation of the angle recess.

Pediatric Eye Disease Investigator Group; Bradfield YS, Melia BM, Repka MX, et al. Central corneal thickness in children. *Arch Ophthalmol*. 2011;129(9):1132–1138.

## Intraocular Pressure

Measurement of intraocular pressure (IOP) in infants can be difficult; results may vary depending on the method used and may not accurately represent the actual IOP. Nevertheless, normal IOP is lower in infants than in adults, and a pressure higher than 21 mm Hg should be considered abnormal. CCT influences the measurement of IOP, but this effect is not well understood in children. See Chapter 22 in this volume and BCSC Section 10, *Glaucoma*, for further discussion.

## Extraocular Muscles

The rectus muscles of infants are smaller than those of adults; muscle insertions, on average, are 2.3–3.0 mm narrower, and the tendons are thinner in infants than in adults. In

newborns, the distance from the rectus muscle insertion to the limbus is roughly 2 mm less than that in adults; by age 6 months, this distance is 1 mm less; and at 20 months, it is similar to that in adults.

Extraocular muscle function continues to develop after birth. Eye movements driven by the vestibular-ocular system are present as early as 34 weeks' gestational age. Conjugate horizontal gaze is present at birth, but vertical gaze may not be fully functional until 6 months of age. Intermittent strabismus occurs in approximately two-thirds of young infants but resolves in most by 2–3 months of age. Accommodation and fusional convergence are usually present by age 3 months.

## Retina

The macula is poorly developed at birth but changes rapidly during the first 4 years of life. Most significant are changes in macular pigmentation, development of the annular ring and foveal light reflex, and differentiation of cone photoreceptors. Improvement in visual acuity with age is due in part to development of the macula, specifically, differentiation of cone photoreceptors, narrowing of the rod-free zone, and an increase in foveal cone density (see Chapter 5). Retinal vascularization begins at the optic disc at 16 weeks' gestational age and proceeds to the peripheral retina, reaching the temporal ora serrata by 40 weeks' gestational age.

Hendrickson A, Possin D, Lejla V, Toth CA. Histologic development of the human fovea from midgestation to maturity. *Am J Ophthalmol.* 2012;154(5):767–778.

## Visual Acuity and Stereoacuity

Visual acuity improvement in infancy and early childhood is attributable to neural development as well as ocular structural changes (see Chapter 16).

Two major methods are used to quantitate visual acuity in preverbal infants and toddlers: *preferential looking (PL)* and *visual evoked potential (VEP)*. See Chapter 1 for a description of these methods. VEP studies show that visual acuity improves from approximately 20/400 in newborns to 20/20 by age 6–7 months. However, PL studies estimate the visual acuity of a newborn to be 20/600, improving to 20/120 by age 3 months and to 20/60 by 6 months. Further, PL testing shows that visual acuity of 20/20 is not reached until age 3–5 years. The discrepancy between measurements obtained by these 2 methods may be related to the higher cortical processing required for PL compared with VEP. Stereoacuity reaches 60 seconds of arc by about age 5–6 months (see Chapter 7).

## Abnormal Growth and Development

Major congenital anomalies occur in 2%–3% of live births. Causes include chromosomal abnormalities, multifactorial disorders, and environmental agents, but many cases are idiopathic. Regardless of etiology, congenital anomalies may be categorized as shown in Table 15-2.

A *malformation* implies a morphologic defect present from the onset of development or from a very early stage. A disturbance to a group of cells in a single developmental field

**Table 15-2 Types of Congenital Anomalies**

Anomaly	Defect	Ocular Example
Agenesis	Developmental failure	Anophthalmia
Hypoplasia	Developmental arrest	Optic nerve hypoplasia
Hyperplasia	Developmental excess	Distichiasis
Dysraphism	Failure to fuse	Choroidal coloboma
	Failure to divide or canalize	Congenital nasolacrimal duct obstruction
	Persistence of vestigial structures	Persistent fetal vasculature

may cause multiple malformations. Multiple etiologies may result in similar field defects and patterns of malformation. A single structural defect or factor can lead to a cascade, or domino effect, of secondary anomalies called a *sequence*. The Pierre Robin group of anomalies (cleft palate, glossoptosis, micrognathia, respiratory problems) may represent a sequence caused by underdevelopment of the mandible and is seen in disorders such as Stickler and fetal alcohol syndromes. A *syndrome* is a recognizable and consistent pattern of multiple malformations known to have a specific cause, which is usually a mutation of a single gene, a chromosome alteration, or an environmental agent. An *association* represents defects known to occur together in a statistically significant number of patients. An association may represent a variety of yet-unidentified causes. Two or more minor anomalies in combination significantly increase the likelihood of an associated major malformation.

Jones KL, Jones MC, del Campo M. *Smith's Recognizable Patterns of Human Malformation*. 7th ed. Philadelphia: Elsevier Saunders; 2013.



# Decreased Vision in Infants and Pediatric Vision Rehabilitation

When an infant has not developed good visual attention or the ability to fixate on and follow objects by 3–4 months of age, the clinician must determine whether the decreased vision is due to an ocular or optic nerve (pregeniculate) condition, cerebral (retrogeniculate) visual impairment, or delayed visual maturation. This chapter discusses the classification of visual impairment in infants and children, as well as the evaluation and rehabilitation of these patients.

## Visual Development in Young Infants

---

Visual development is a highly complex maturational process. Structural changes occur in both the eye and the central nervous system. Laboratory and clinical research has shown that normal vision develops as a result of both genetically programmed neural development and normal early visual experience.

A blink reflex to bright light should be present within a few days of birth. The pupillary light reflex is usually present after 31 weeks' gestation but can be difficult to evaluate in the early neonatal period because the newborn's pupils are miotic.

At approximately 6–8 weeks of age, the healthy full-term infant should be able to make and maintain eye contact with other humans and react with facial expressions. Infants aged 2–3 months should be interested in bright objects. By age 3–4 months, the nasal bias for smooth pursuit should have resolved, the eyes should be orthotropic, and fix-and-follow responses to a small (2–4 inches in diameter) toy should be present. Premature infants can be expected to reach these landmarks later, but there is not an exact week-for-week correlation for the attainment of these milestones.

Dysconjugate eye movements, skew deviation, and *sunsetting* (tonic downward deviation of both eyes) may be noted in healthy newborns but should not persist beyond approximately 3–4 months of age. Signs of poor visual development include searching eye movements, lack of response to familiar faces and objects, and nystagmus. Staring at bright lights and forceful rubbing or poking of the eyes (*oculodigital reflex*) in an otherwise visually disinterested infant are other signs of poor vision and suggest an ocular cause for the deficiency.

## Classification of Visual Impairment in Infants and Children

---

The distinction between pregeniculate and cerebral visual impairment can be helpful in the context of infants who present with poor vision, although it should be recognized that some disorders cause both pregeniculate and retrogeniculate pathology. In addition, in some children, poor visual behavior normalizes over time, a phenomenon known as *delayed visual maturation*.

### Pregenicate Visual Impairment

Pregenicate visual impairment results from pathology anterior to the lateral geniculate nucleus (the pregenicate visual pathways). Causes of pregenicate visual impairment in infants include corneal and lens opacities, glaucoma, retinal disorders, and optic nerve or optic tract abnormalities; these conditions are covered in detail elsewhere in this volume.

### Cerebral Visual Impairment

Cerebral visual impairment (CVI; also termed *retrogeniculate visual impairment*) is the most frequent cause of childhood visual impairment in developed countries. The visual deficit results from pathology posterior to the lateral geniculate nucleus (retrogeniculate visual pathways). CVI is often referred to as *cortical visual impairment*, but the term *cerebral* is preferred because both subcortical (optic radiations) and cortical pathology can result in similar visual impairment. CVI can be transient or permanent and can be an isolated finding or associated with multiple neurologic deficits. Partial improvement in visual behavior may occur over the first few years of life.

CVI can be congenital or acquired. Prenatal and perinatal causes include intrauterine infection, structural central nervous system abnormalities, intracranial hemorrhage, periventricular leukomalacia (a prominent cause of visual impairment in premature children), hypoxia, seizures, and hydrocephalus. Acquired causes include accidental trauma, abusive head trauma, meningitis, and encephalitis.

Infants with CVI show variable degrees of impairment, from mildly decreased visual behavior to roving eye movements with complete absence of response to visual stimulation.

### Delayed Visual Maturation

If normal visual fixation and tracking do not develop within the first 3–4 months of life, visual behavior may still normalize subsequently; this condition is termed *delayed visual maturation (DVM)*, or *cortical inattention*. There are 3 subgroups of infants with DVM: otherwise healthy infants; infants with systemic or neurologic abnormalities; and infants with associated ocular disorders presenting with poor vision out of proportion to the ocular condition.

In an otherwise healthy infant with suspected DVM, the following findings suggest a good visual and neurologic prognosis: some reaction to light, normal pupillary responses, no nystagmus, and normal ocular structures. If the visual behavior does not progress

toward normal by 4–6 months of age, further investigation is warranted to assess for other causes of persistent visual impairment.

Azmeh R, Lueder GT. Delayed visual maturation in otherwise normal infants. *Graefes Arch Clin Exp Ophthalmol*. 2013;251(3):941–944.

## Evaluation of the Infant With Decreased Vision

---

Family history may identify hereditary causes of pregeniculate visual impairment. Details of the pregnancy are important; factors such as in utero exposure to infection, drugs, alcohol, or radiation; trauma; and maternal diabetes mellitus may predispose to pregeniculate impairment and/or CVI. Perinatal problems such as prematurity, intrauterine growth retardation, fetal distress, bradycardia, meconium staining, and oxygen deprivation may be associated with CVI. In addition, the clinician should inquire about systemic abnormalities, delayed developmental milestones, and postnatal causes of brain injury.

Parental observations of the child's visual behavior should be noted. In a child with CVI, visual attentiveness may fluctuate widely; the family may report that the child sometimes seems to see and at other times does not appear to see at all.

Vision in the infant is assessed qualitatively by clinical appraisal and optokinetic nystagmus responses, and quantitatively by preferential looking tests—for example, Teller Acuity Cards II (Stereo Optical, Inc, Chicago, IL) or the Cardiff Acuity Test—and visual evoked potential (VEP); see Chapter 1 for a discussion of these quantitative tests. VEP results may be either normal or subnormal in CVI. Infants with ocular motor apraxia (see Chapter 12) may falsely appear to have poor vision due to impaired horizontal eye movements, but vertical movements are usually spared.

Pupillary responses are sluggish with certain pregeniculate causes of visual impairment such as retinal dystrophies and optic nerve abnormalities. Paradoxical pupils (pupillary constriction in response to darkness) can occur with these conditions. In contrast, pupillary responses are normal in infants with CVI.

In the setting of poor vision, nystagmus in infancy should raise suspicion for sensory nystagmus due to a pregeniculate disorder (see Chapter 13). Conversely, poor visual behavior with normal ocular examination results, normal pupillary responses, and no nystagmus by 3 months of age is more likely to represent CVI or DVM. Congenital motor nystagmus usually does not present with poor vision but is occasionally associated with DVM.

Anterior segment and fundus examinations may reveal a pregeniculate cause of the visual impairment, such as bilateral cataracts, bilateral macular colobomas or scars, bilateral optic nerve hypoplasia, bilateral optic atrophy, or foveal hypoplasia with or without albinism or aniridia. However, some retinal causes of pregeniculate visual impairment may not be associated with any visible abnormalities on fundus examination. Sometimes optic nerve abnormalities may be present even though the primary cause of visual impairment is CVI: descending optic atrophy (from transsynaptic degeneration) may coexist with CVI, and in preterm infants, optic disc cupping resembling that seen in glaucoma can occur as a result of transsynaptic degeneration, most commonly secondary to periventricular leukomalacia.



If the ocular examination is unrevealing yet suspicion is high for a pregeniculate cause of visual impairment (eg, when poor vision is accompanied by nystagmus), then electroretinography (ERG) may be indicated to diagnose a retinal dystrophy. ERG results are normal in CVI.

Neuroimaging studies in CVI may be normal, in which case the visual prognosis tends to be more favorable, or may reveal changes such as cerebral atrophy, porencephaly in the occipital (striate or parastriate) cortex, damage to the optic radiations, or periventricular leukomalacia.

## **Pediatric Low Vision Rehabilitation**

---

Vision rehabilitation should be recommended when a child has a visual impairment that affects his or her ability to access the visual environment (as occurs with best-corrected visual acuity worse than 20/40 in the better-seeing eye, decreased visual field, central field loss, reduced contrast sensitivity, nyctalopia, or impaired visual processing). From diagnosis onward, the ophthalmologist plays an important role in recommending that children with low vision receive comprehensive vision rehabilitation. Early referral is essential for setting the family and child on a course to achieve optimal visual performance, access to instruction, and safe and independent mobility, and for enabling children with acquired visual impairment to adjust successfully to vision loss. Even though preschool-aged children may function well without any low vision aids, early-intervention programs can offer important stimulation and introduce strategies for transition to school.

Pediatric vision rehabilitation involves pediatric ophthalmologists, vision rehabilitation clinicians, teachers of the visually impaired (TVI), occupational therapists, teachers, orientation and mobility specialists, technology experts, state societies, and other professionals and organizations. In the United States, a variety of approaches exist to educate children with visual impairments. Some states have state-funded residential schools for the visually impaired. Elsewhere, districts may cluster students with visual impairment into one school. More commonly, neighborhood schools work with itinerant TVI. An Individualized Education Plan (IEP) outlines the needs of an individual child in the school setting. The child's needs at home and in other nonacademic settings must be considered as well.

Many children can function well with partial sight, with the help of low vision aids, whereas others will benefit from braille literacy, which is most easily acquired in childhood. Because most children have large accommodative amplitudes, enabling them to hold a given object closer than normal to enlarge its retinal image, magnification may not be necessary for very young patients with low vision. However, accommodative amplitudes decrease and visual demands increase with age (as students are faced with smaller print size), so holding objects closer may not be a sustainable strategy for older children. Printed material can be enlarged, and dome-type magnifiers may be helpful for performing near work; video magnification can be used for near- or distance-vision tasks. For distance viewing, handheld monocular telescopes may help. Tablets, smartphones, e-textbooks, and text-to-speech conversion have greatly expanded the opportunities

**Table 16-1 Sources of Information on Low Vision**


---

American Council of the Blind; <a href="http://www.acb.org">www.acb.org</a>
American Foundation for the Blind; <a href="http://www.afb.org">www.afb.org</a>
American Printing House for the Blind, Inc; <a href="http://www.aph.org">www.aph.org</a>
Large-print and braille books, tapes, talking computer software, and low vision aids
Family Support America; <a href="http://www.familysupportamerica.org">www.familysupportamerica.org</a>
For parent support groups in the United States
Learning Ally; <a href="http://www.learningally.org">www.learningally.org</a>
Audiobooks for the blind and dyslexic
Lighthouse Guild; <a href="http://www.lighthouseguild.org">www.lighthouseguild.org</a>
National Federation of the Blind; <a href="http://www.nfb.org">www.nfb.org</a>
National Library Service for the Blind and Physically Handicapped, Library of Congress;
<a href="https://www.loc.gov/nls">https://www.loc.gov/nls</a>
Free library program of braille and audio materials, including books and magazines
National Organization for Albinism and Hypopigmentation; <a href="http://www.albinism.org">www.albinism.org</a>
Prevent Blindness; <a href="http://www.preventblindness.org">www.preventblindness.org</a>

**National Toll-Free Numbers**

American Council of the Blind; (800) 424-8666  
*New York Times Large-Print Weekly*; (800) 631-2580  
*Reader's Digest Large Print*; (877) 732-4438

---

available to visually impaired children and have the benefit of being socially acceptable for older children trying to fit in with their peers. Table 16-1 lists sources of information on low vision.

The American Academy of Ophthalmology's Preferred Practice Pattern guidelines on vision rehabilitation outline the rehabilitation process for preschool-aged children to young adults. The availability of rehabilitation resources varies across communities, but the following online resources, which can be searched by location, may be helpful for clinicians and families in identifying such services in their community: [afb.org/directory.aspx](http://afb.org/directory.aspx) (American Federation for the Blind) and [tsbvi.edu/tagged-resources](http://tsbvi.edu/tagged-resources) (Texas School for the Blind and Visually Impaired resources home page). To learn about the Academy's Initiative in Vision Rehabilitation, visit the Low Vision and Vision Rehabilitation page, which also offers a patient handout, available on the ONE Network at <https://www.aaopt.org/low-vision-and-vision-rehab>.

See also BCSC Section 3, *Clinical Optics*, for a detailed discussion of low vision aids.

American Academy of Ophthalmology Vision Rehabilitation Committee. Preferred Practice Pattern Guidelines. *Vision Rehabilitation*. San Francisco: American Academy of Ophthalmology; 2013. For the latest guidelines, go to <https://www.aaopt.org/guidelines-browse?filter=preferredpracticepatterns>.



# Eyelid Disorders



This chapter includes a related video, which can be accessed by scanning the QR code provided in the text or going to [www.aao.org/bcscvideo\\_section06](http://www.aao.org/bcscvideo_section06).

Eyelid anatomy is described in BCSC Section 2, *Fundamentals and Principles of Ophthalmology*, and Section 7, *Oculofacial Plastic and Orbital Surgery*. Section 7 also discusses many of the eyelid disorders covered in this chapter.

## Congenital Eyelid Disorders

---

Eyelid malformations can be isolated or associated with orbital malformations; they can also represent features of a syndrome. Because of these possibilities, systematic evaluation of the eyelids and ocular adnexa may be an important part of the clinical evaluation of a dysmorphic infant.

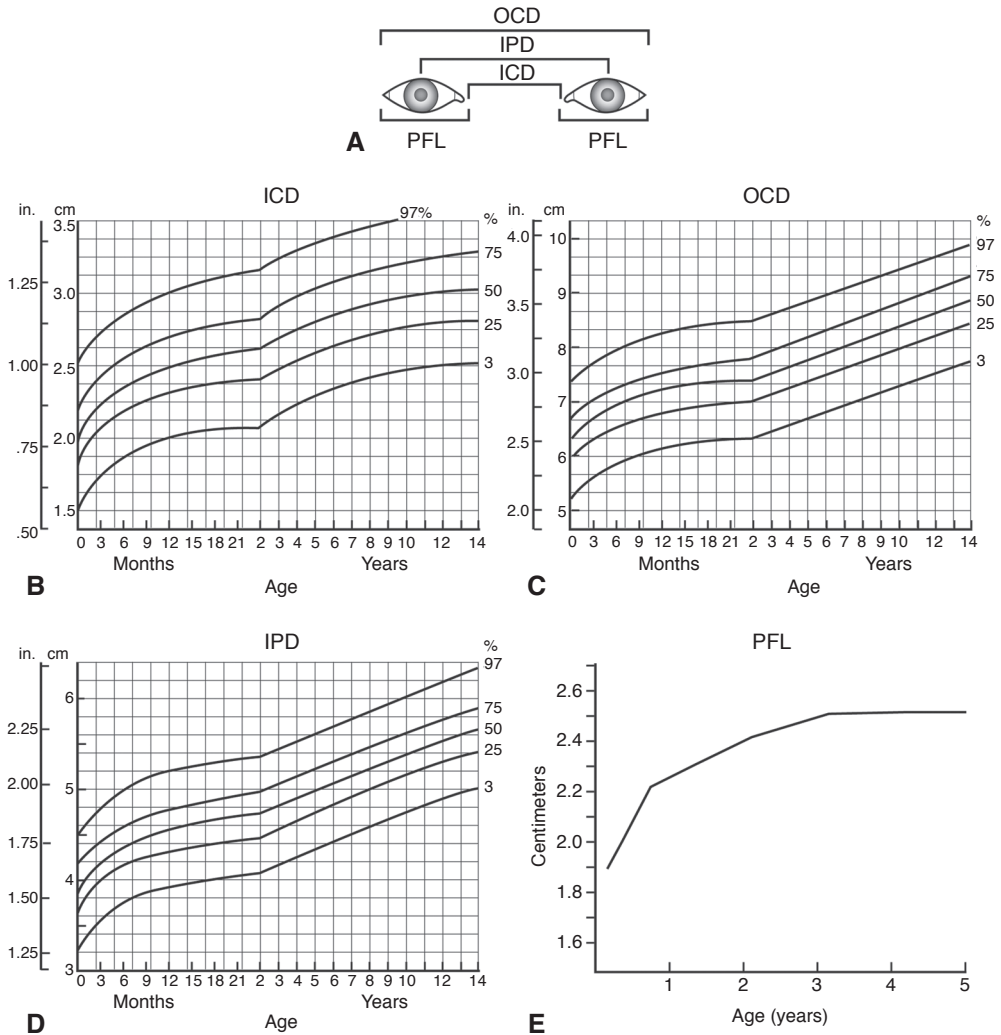
Morphologic measurements of the eyelids and orbit can be compared with normal reference measurements and may have clinical significance (Fig 17-1; see also Chapter 18). The *Farkas canthal index*, defined as the ratio of inner canthal distance to outer canthal distance, can also be used. A canthal index lower than 38 signifies *ocular hypotelorism* (smaller-than-average distance between the eyes), and a canthal index greater than 42 indicates *ocular hypertelorism* (greater-than-average distance between the eyes). Ethnic variations may occur.

### Dystopia Canthorum

Dystopia canthorum is lateral displacement of both the inner canthi and the lacrimal puncta such that an imaginary vertical line connecting the upper and lower puncta crosses the cornea (Fig 17-2). The displacement is a characteristic feature of Waardenburg syndrome type 1.

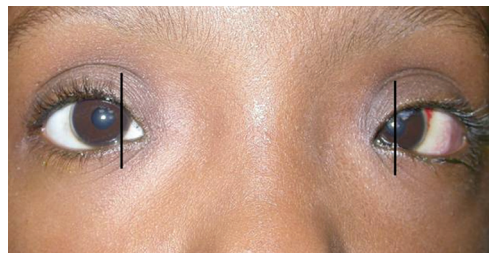
### Cryptophthalmos

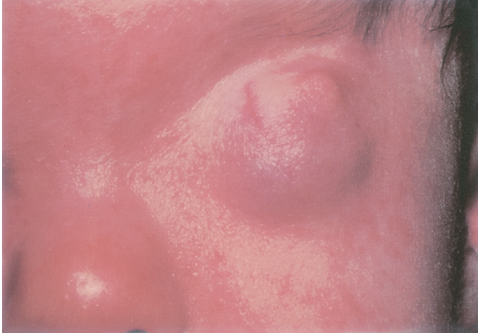Cryptophthalmos is a rare condition resulting from failed differentiation of eyelid structures. There is partial or complete absence of the palpebral fissure, as the skin extends uninterrupted from the forehead to the cheek, covering the eye (Fig 17-3). The adnexa are partially developed and fused to the anterior segment; the cornea is usually malformed.



**Figure 17-1** **A**, Schematic representation of measurements involved in the evaluation of the orbital region. OCD = outer canthal distance; IPD = interpupillary distance; ICD = inner canthal distance; PFL = palpebral fissure length. **B**, ICD measurements according to age. **C**, OCD measurements according to age. **D**, IPD measurements according to age. **E**, PFL measurements according to age. (Modified with permission from Dollfus H, Verloes A. *Dysmorphology and the orbital region: a practical clinical approach*. *Surv Ophthalmol*. 2004;49(6):549.)

**Figure 17-2** Dystopia canthorum in a patient with Waardenburg syndrome. Note that the vertical lines drawn through the puncta intersect the cornea. (Courtesy of Amy Hutchinson, MD.)





**Figure 17-3** Cryptophthalmos, left eye.

*Fraser syndrome*, an autosomal recessive disorder characterized by partial syndactyly and genitourinary anomalies, may include unilateral or bilateral cryptophthalmos and other ocular malformations.

### **Ablepharon**

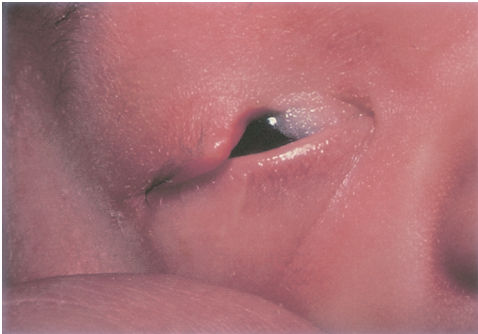
Ablepharon, absence or severe hypoplasia of the eyelids, is very rare. Affected patients are at high risk for exposure keratopathy. Ablepharon is a characteristic feature of ablepharon-macrostomia syndrome.

### **Congenital Coloboma of the Eyelid**

Congenital eyelid coloboma (eyelid cleft or notch) usually involves the upper eyelid and can range from a small notch to a defect encompassing the horizontal length of the eyelid. The eyelid may be fused to the globe (Fig 17-4). Eyelid colobomas are unrelated to other ocular colobomas and are commonly associated with Goldenhar syndrome or amniotic band syndrome. The eye of an infant with a congenital eyelid coloboma should be monitored for exposure keratopathy. Surgical closure of the eyelid defect is required in most cases.

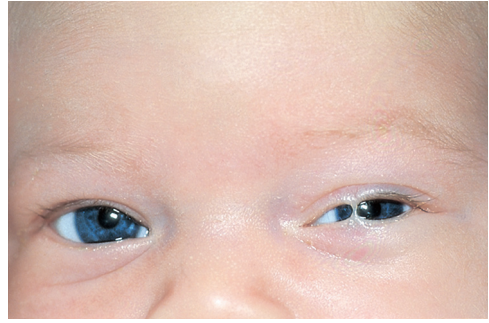### **Ankyloblepharon**

Fusion of part or all of the eyelid margins is termed *ankyloblepharon*. This condition may be dominantly inherited. Treatment is surgical. In *ankyloblepharon filiforme adnatum*, a



**Figure 17-4** Congenital eyelid coloboma (cleft), right eye. The eyelid is fused to the globe.

**Figure 17-5** Ankyloblepharon filiforme adnatum. The eyelid margins are fused by a fine strand of tissue. (Courtesy of Amy Hutchinson, MD.)



variant of ankyloblepharon, the margins of the upper and lower eyelids are joined by fine strands of tissue (Fig 17-5). This variant is seen in Hay-Wells syndrome (also known as *ankyloblepharon-ectodermal dysplasia-clefting syndrome*), a form of ectodermal dysplasia that includes cleft lip or palate. The eyelid adhesions in children with ankyloblepharon filiforme adnatum can often be easily separated in the office with blunt scissors and topical anesthesia.

### **Congenital Ectropion**

Congenital ectropion is a rare abnormality characterized by eversion of the eyelid margin. It usually involves the lower eyelid and is secondary to a vertical deficiency of the skin. Lateral tarsorrhaphy may be effective for mild cases. More severe cases may require a skin flap or graft.

### **Congenital Entropion**

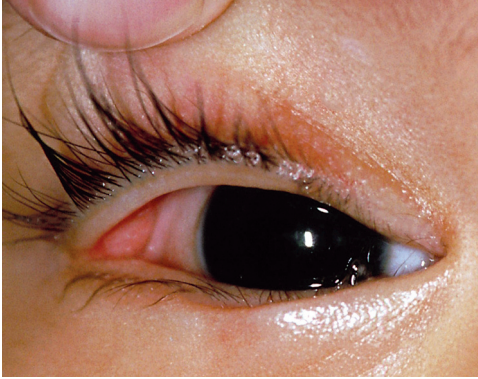Congenital entropion is a rare abnormality characterized by eyelid margin inversion. It does not resolve spontaneously. Surgery should be performed when corneal integrity is threatened.

### **Epiblepharon**

Epiblepharon is a common congenital anomaly characterized by a horizontal fold of skin adjacent to the eyelid margin (most commonly the lower eyelid) that may turn the eyelashes inward, against the cornea (Fig 17-6). Infants' corneas often tolerate this condition surprisingly well. Unlike congenital entropion, epiblepharon often resolves spontaneously. Ocular lubricants may be beneficial. Surgical repair is required when the condition does not resolve or it causes chronic corneal irritation.

### **Congenital Tarsal Kink**

In congenital tarsal kink, the tarsal plate of the upper eyelid is folded at birth, resulting in entropion. The cornea may be exposed and traumatized, leading to ulceration. The clinician can manage minor defects by manually unfolding the tarsus and taping the eyelid shut with a pressure dressing for 1–2 days. More severe cases require surgical incision



**Figure 17-6** Epiblepharon, right eye. The medial lower eyelid eyelashes are turned inward, causing corneal irritation. (Courtesy of Gregg T. Lueder, MD.)

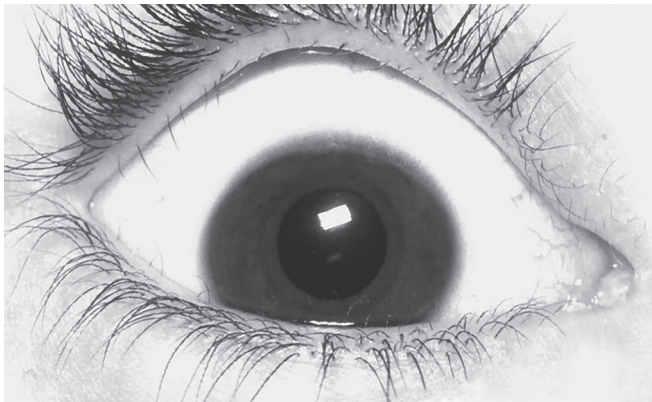
of the tarsal plate or excision of a V-shaped wedge from the inner surface to permit unfolding.

### Distichiasis

In distichiasis, an extra (partial or complete) row of eyelashes arises from or slightly posterior to the meibomian gland orifices (Fig 17-7). The abnormal eyelashes tend to be thinner, shorter, softer, and less pigmented than normal cilia and are therefore often well tolerated. Removal of the abnormal eyelashes with electrolysis or cryotherapy, or eyelid surgery, may be indicated if chronic corneal irritation is present.

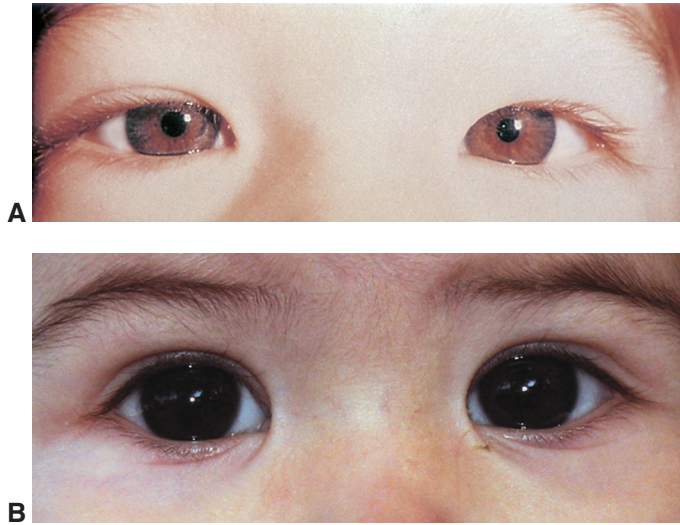
### Euryblepharon

In euryblepharon, the lateral aspect of the palpebral aperture is enlarged, with downward displacement of the temporal half of the lower eyelid. This condition gives the appearance of a very wide palpebral fissure or a droopy lower eyelid. Euryblepharon may occur in Kabuki syndrome. Most patients do not require treatment.



**Figure 17-7** Distichiasis. An accessory row of eyelashes exits from the meibomian gland orifices. (Reproduced with permission from Patil BB, Bell R, Brice G, Jeffery S, Desai SP. Distichiasis without lymphoedema? Eye (Lond). 2004;18(12):1270–1272.)





**Figure 17-8** Epicanthus, bilateral. **A**, Epicanthus tarsalis. **B**, Epicanthus palpebralis. (Part A reproduced with permission from Crouch E. *The Child's Eye: Strabismus and Amblyopia*. Slide script. San Francisco: American Academy of Ophthalmology; 1982. Part B courtesy of Robert W. Hered, MD.)

## Epicanthus

*Epicanthus* refers to a crescent-shaped fold of skin running vertically between the eyelids and overlying the inner canthus (Fig 17-8). There are 4 types:

- *epicanthus tarsalis*: The fold is most prominent in the upper eyelid.
- *epicanthus inversus*: The fold is most prominent in the lower eyelid.
- *epicanthus palpebralis*: The fold is equally distributed between the upper and lower eyelids.
- *epicanthus supraciliaris*: The fold arises from the eyebrow and terminates over the lacrimal sac.

*Epicanthus inversus* may be isolated or associated with blepharophimosis–ptosis–epicanthus inversus syndrome or ptosis. Surgical correction is only occasionally required.

## Palpebral Fissure Slants

In the normal eye, the eyelids are generally positioned so that the lateral canthus is approximately 1 mm higher than the medial canthus. Slight upward or downward slanting of palpebral fissures normally occurs on a familial basis or in certain racial and ethnic groups (eg, Asians). An upward or downward slant is a characteristic feature of some craniofacial syndromes (eg, downward slant in Treacher Collins syndrome; see Chapter 18, Fig 18-9). Slanting of the palpebral fissures may be associated with A- or V-pattern strabismus (see Chapter 10).

## Congenital Ptosis

Ptosis (ie, blepharoptosis) can be congenital or acquired. It is important to differentiate congenital ptosis from acquired cases with systemic associations (Table 17-1; see also

**Table 17-1 Classification of Ptosis**


---

Pseudoptosis
Congenital ptosis
Acquired ptosis
Myogenic ptosis
Myasthenia gravis
Chronic progressive external ophthalmoplegia
Neurogenic ptosis
Horner syndrome
Third nerve palsy
Mechanical ptosis

---

BCSC Section 7, *Oculofacial Plastic and Orbital Surgery*). Congenital ptosis is usually caused by decreased levator muscle function. It may be familial. Anisometropic amblyopia and strabismus are common associations.

Evaluation of ptosis requires assessment of the upper eyelid crease, the palpebral fissure height, and levator muscle function. In severe congenital ptosis, the eyelid crease is usually absent. The clinician can determine the amount of ptosis by measuring the distance between the upper and lower eyelids and the margin–reflex distance (MRD). MRD<sub>1</sub> is the distance from the margin of the upper eyelid to the corneal light reflex when the eye is in primary position. Levator muscle function is assessed by measuring the distance that the upper eyelid moves when the patient shifts from downgaze to upgaze; during measurement, the examiner uses digital pressure on the brow to block recruitment of the frontalis muscle.

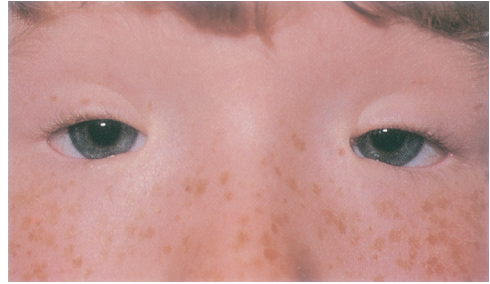Tear function, corneal sensitivity, and the Bell phenomenon should also be evaluated because corneal exposure may occur after surgical repair, should it be necessary. Tear function can be assessed by evaluating the tear lake and tear breakup time, as well as checking for the presence of punctate keratitis. Corneal sensitivity can be assessed by the presence of a blink reflex when the cornea is touched with the tip of a cotton swab. In addition, the clinician should determine whether the globe is microphthalmic or whether a hypotropia is present, as either of these may produce pseudoptosis.

Marked congenital ptosis that obstructs vision must be corrected early in infancy to prevent deprivation amblyopia. Correction of severe ptosis usually requires frontalis suspension because of the lack of levator muscle function. Autologous or allogeneic fascia lata and synthetic material such as silicone rods are some of the materials used for suspension. Autologous fascia, however, cannot be obtained until the patient is 3 or 4 years old. Use of synthetic material or allogeneic fascia lata may lead to higher recurrence rates. Repair of mild or moderate ptosis can usually be performed when the patient is older, although the presence of a compensatory chin-up head position may justify earlier surgery. External levator muscle resection is typically performed for mild or moderate congenital ptosis.

### ***Blepharophimosis–ptosis–epicanthus inversus syndrome***

Blepharophimosis–ptosis–epicanthus inversus syndrome (BPES; also referred to as *congenital eyelid syndrome* or *blepharophimosis syndrome*) may occur as a sporadic or autosomal dominant disorder with features of blepharophimosis, epicanthus inversus, telecanthus, and ptosis. There are 2 types of BPES, both of which include abnormalities of the eyelid; type I also includes premature ovarian failure. Mutations in the *FOXL2* gene

**Figure 17-9** Blepharophimosis–ptosis–epicanthus inversus syndrome. Note telecanthus as well.



have been found in both types. The palpebral fissures are shortened horizontally and vertically (blepharophimosis), levator muscle function is poor, and no upper eyelid fold is present (Fig 17-9). The length of the horizontal palpebral fissure, normally 25–30 mm, is only 18–22 mm in these patients. Repair of the ptosis, usually with frontalis suspension procedures, may be necessary early in life. Because the epicanthus and telecanthus may improve with age, repair of these defects is often delayed.

### **Marcus Gunn jaw-winking syndrome**

Marcus Gunn jaw-winking syndrome (also known as *co-contractive retraction with jaw-eyelid synkinesis syndrome [CCRS], type 5*) is a synkinetic syndrome in which the eyelid elevates with movement of the jaw; it may present with ptosis. In Video 17-1, note elevation of the left eyelid with movement of the jaw. The synkinesis is thought to be caused by aberrant connections between the motor division of cranial nerve V and the levator muscle. The clinician may test an infant for this condition by having the child suck on a bottle or pacifier. Many patients do not require treatment. If the ptosis is amblyogenic or a chin-up head position develops, ptosis surgery may be indicated.



**VIDEO 17-1** Marcus Gunn jaw-winking ptosis.

*Courtesy of Mary A. O'Hara, MD.*

Access all Section 6 videos at [www.aao.org/bcscvideo\\_section06](http://www.aao.org/bcscvideo_section06).

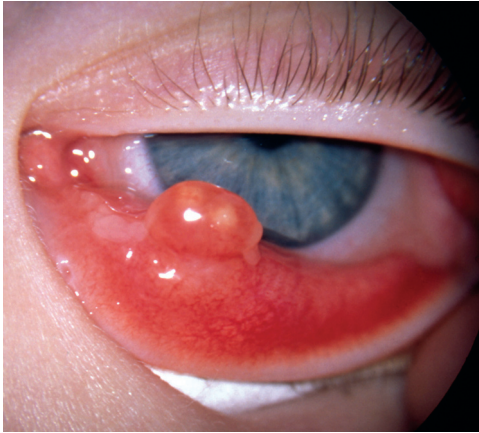

## **Other Causes of Ptosis in Children**

Ptosis may occur in children as a result of several other disorders, including third nerve palsy, monocular elevation deficiency, myasthenia gravis, congenital fibrosis of the extraocular muscles, chronic progressive external ophthalmoplegia, and Horner syndrome. It may also be associated with several systemic disorders, including Turner, Cornelia de Lange, and fetal alcohol syndromes. These entities are discussed elsewhere in this book and in other BCSC volumes.

## **Infectious and Inflammatory Eyelid Disorders**

Inflammatory masses of the eyelids are common in children. *Chalazia* are caused by blockage of the meibomian glands, with secondary irritation due to lipid extravasation. *Hordeola* are localized infections of eyelid glands. Treatment of both disorders includes



**Figure 17-10** Pyogenic granuloma on tarsal conjunctiva at the site of a chalazion. (Reproduced with permission from Lueder GT. Pediatric Practice Ophthalmology. New York: McGraw-Hill Professional; 2010:178.)

warm compresses and management of associated blepharitis. Supplements containing omega-3 fatty acids may be beneficial in some patients. Surgical treatment is reserved for large, painful, or chronic lesions.

*Pyogenic granuloma (lobular capillary hemangioma)*—a pedunculated, fleshy pink hemangiomatous growth—can develop on the tarsal conjunctiva, overlying a chalazion or trauma site (Fig 17-10). Patients with *molluscum contagiosum* may present with characteristic lesions of the eyelids and secondary follicular conjunctivitis (see Chapter 20).

## Vascular Eyelid Disorders

---

### Port-Wine Stain

Port-wine stain (PWS; also known as *port-wine nevus* or *nevus flammeus*) is a congenital vascular malformation that manifests as a flat red or pink cutaneous lesion. It may lighten during the first year of life but then tends to become darker, thicker, and more nodular over time. PWS is associated with Sturge-Weber and Klippel-Trénaunay-Weber syndromes (see Chapter 28) and is seen in combination with ocular melanosis in phakomatosis pigmentovascularis. Glaucoma can occur in affected eyes (see Chapter 22). Lasers can be used to lighten the affected areas.

### Eyelid Hemangioma

Hemangiomas are common vascular lesions that may involve the eyelid or orbit. They are discussed in Chapter 18.

## Neoplasms and Other Noninflammatory Eyelid Lesions

---

Malignant tumors arising from eyelid skin or palpebral conjunctiva are extremely rare in children. Pediatric cases are likely to be associated with underlying systemic disorders that predispose to malignancy, such as basal cell nevus syndrome or xeroderma pigmentosum.

Rhabdomyosarcoma infrequently presents as an eyelid or conjunctival mass (see Chapter 18). Eyelid and epibulbar lesions can develop in juvenile xanthogranuloma (see Chapter 21).

### **Pilomatrixoma**

Pilomatrixomas (sometimes spelled *pilomatrixomas* or called *Malherbe calcifying epitheliomas*) are benign tumors that arise from hair matrix. They may present as solid, noninflamed lesions, often with a whitish appearance (Fig 17-11). Surgical excision is curative.

### **Epithelial Lesions**

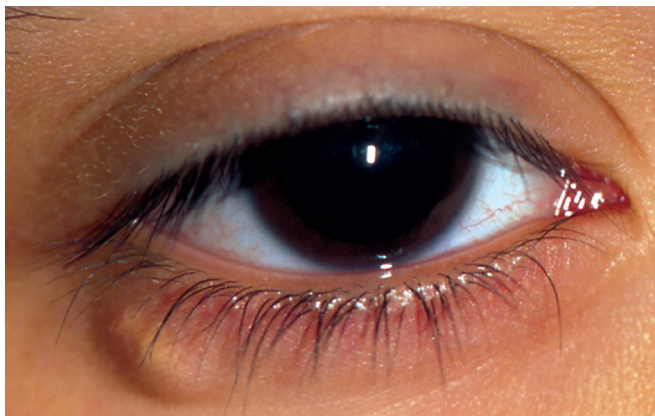Numerous types of benign superficial lesions may arise on the eyelids, including squamous papillomas, epidermal inclusion cysts, verruca vulgaris, and milia. These are discussed in BCSC Section 7, *Oculofacial Plastic and Orbital Surgery*.

### **Eyelid Nevi**

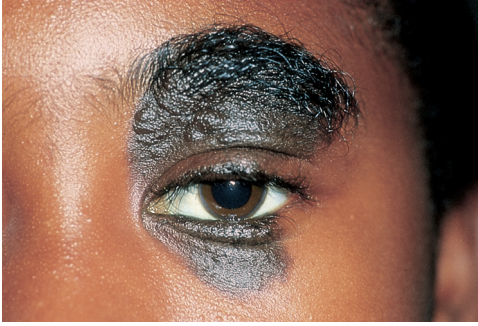Nevi arise from nevus cells, incompletely differentiated melanocytes in the epidermis and dermis and in the junction zone between these 2 layers, and are the third most common benign lesions encountered in the periocular region (after papillomas and epidermal inclusion cysts). The management of simple eyelid nevi in children is similar to that in adults (see BCSC Section 7, *Oculofacial Plastic and Orbital Surgery*).

### ***Congenital nevocellular nevi***

Congenital nevocellular (also called melanocytic) nevi can occur on the eyelids (Fig 17-12) and may cause visual deprivation amblyopia. They may undergo malignant transformation, the risk of which increases with the size of the lesion; large lesions (>20 cm) have a



**Figure 17-11** Pilomatrixoma, right lower eyelid. Note the whitish center. (Reproduced with permission from Lueder GT. *Pediatric Practice Ophthalmology*. New York: McGraw-Hill Professional; 2010:84.)



**Figure 17-12** Congenital nevocellular nevus of the eyelid. (Courtesy of Amy Hutchinson, MD.)

5%–20% risk of malignant transformation. Observation is often recommended for small (<1.5 cm) and medium-sized (1.5–20.0 cm) lesions.

## Other Eyelid Conditions

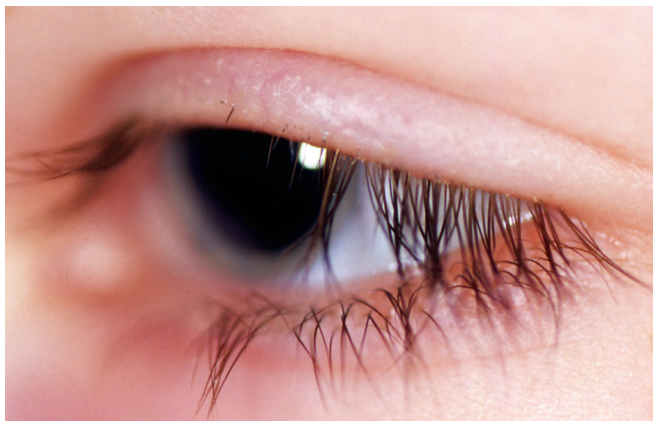---

### Trichotillomania

Trichotillomania is characterized by the pulling out of one's hair, often including the eyebrows and eyelashes. It may be associated with obsessive-compulsive disorder. The characteristic appearance includes madarosis, broken hairs, and regrowth of hairs of varying lengths (Fig 17-13).

### Excessive Blinking

Excessive blinking is common in children. Causes include corneal and eyelid abnormalities, stress reactions, and tics. Ocular tics are usually benign and self-limited. Neurologic



**Figure 17-13** Trichotillomania. Note the segmental loss and irregular lengths of the eyelashes. (Reproduced with permission from Lueder GT. *Pediatric Practice Ophthalmology*. New York: McGraw-Hill Professional; 2010;155.)

consultation may be indicated for patients with multiple tics to evaluate for Tourette syndrome. *Hemifacial spasm* causes unilateral forceful blinking and facial muscle contraction. Imaging is indicated in hemifacial spasm because the disorder may be caused by central nervous system lesions. See BCSC Section 7, *Oculofacial Plastic and Orbital Surgery*, for additional discussion of hemifacial spasm. Squinting may occur in patients with strabismus or uncorrected refractive errors.

# Orbital Disorders

Orbital anatomy is described in BCSC Section 2, *Fundamentals and Principles of Ophthalmology*, and Section 7, *Oculofacial Plastic and Orbital Surgery*. Many pediatric orbital disorders are also discussed in Section 7.

## Abnormal Interocular Distance: Terminology and Associations

---

*Telecanthus* is characterized by a greater-than-normal distance between the inner canthi; it is distinct from, but may accompany, orbital hypertelorism (excessive distance between the medial orbital walls). In primary telecanthus, the abnormality is confined to the soft tissue, occurring without hypertelorism: the interpupillary distance is normal (see also Chapter 17 and Fig 17-1). When telecanthus is secondary to hypertelorism, the interpupillary distance is greater than normal. Telecanthus is common in many syndromes.

*Orbital hypotelorism* is smaller-than-normal distance between the medial orbital walls, with reduced inner and outer canthal distances. The finding is associated with more than 60 syndromes. Hypotelorism can be the result of skull malformation or a failure in brain development.

*Exorbitism* is variously defined as prominent eyes due to shallow orbits or as an increased angle of divergence of the orbital walls.

## Congenital and Developmental Disorders: Craniofacial Malformations

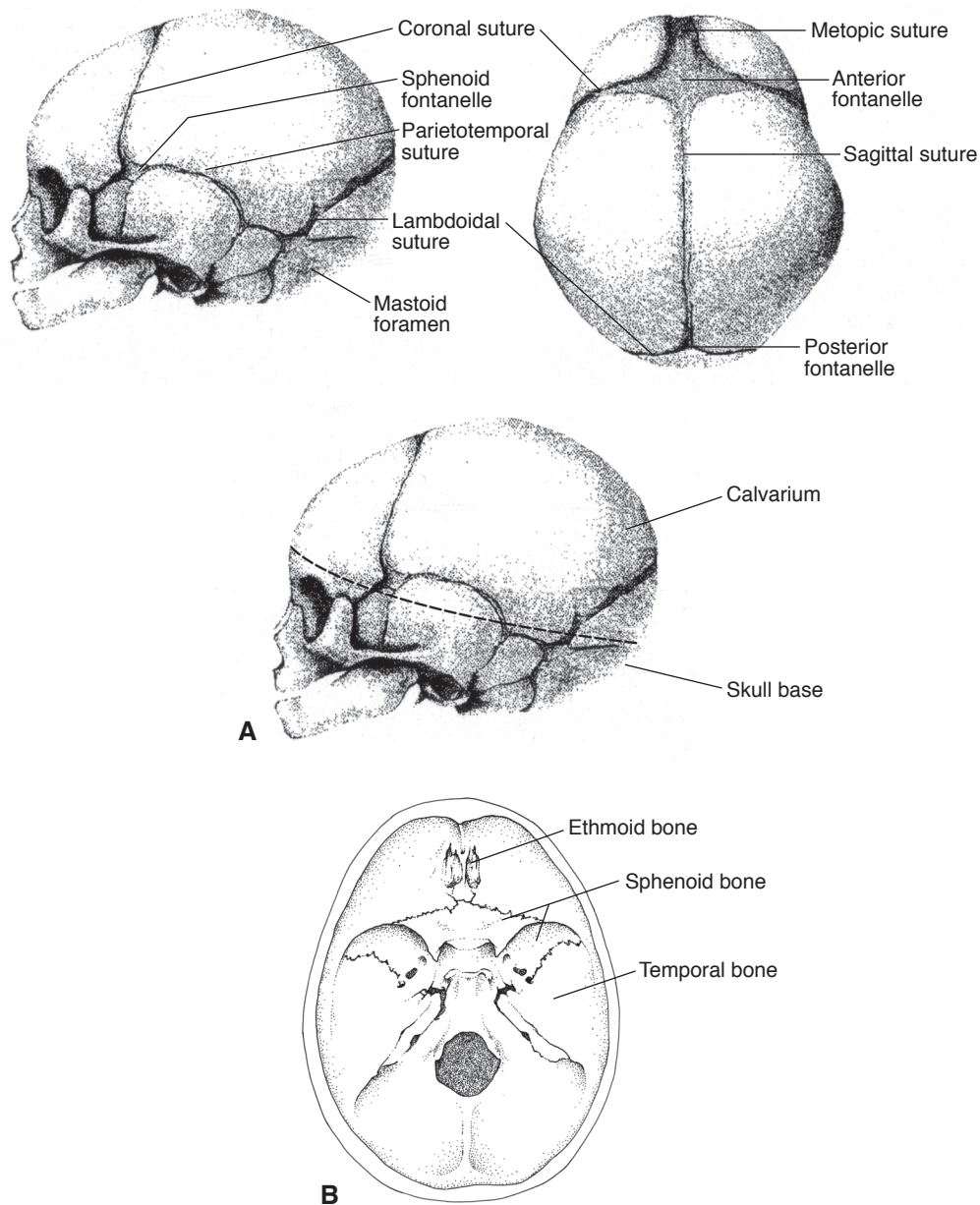
---

### Craniosynostosis

Cranial sutures are present throughout the skull, which is divided into 2 parts, the *calvarium* and the *skull base*, via an imaginary line drawn from the supraorbital rims to the base of the occiput (Fig 18-1). Cranial sutures normally fuse during the first 2 years of life. *Craniosynostosis* is the premature closure of one or more cranial sutures during the embryonic period or early childhood.

Bony growth of the skull occurs in osteoblastic centers located at the suture sites. Bone is laid down parallel and perpendicular to the direction of the suture (Fig 18-2). Premature suture closure prevents perpendicular growth but allows parallel growth. This growth pattern, called *Virchow's law*, results in clinically recognizable cranial bone deformations.

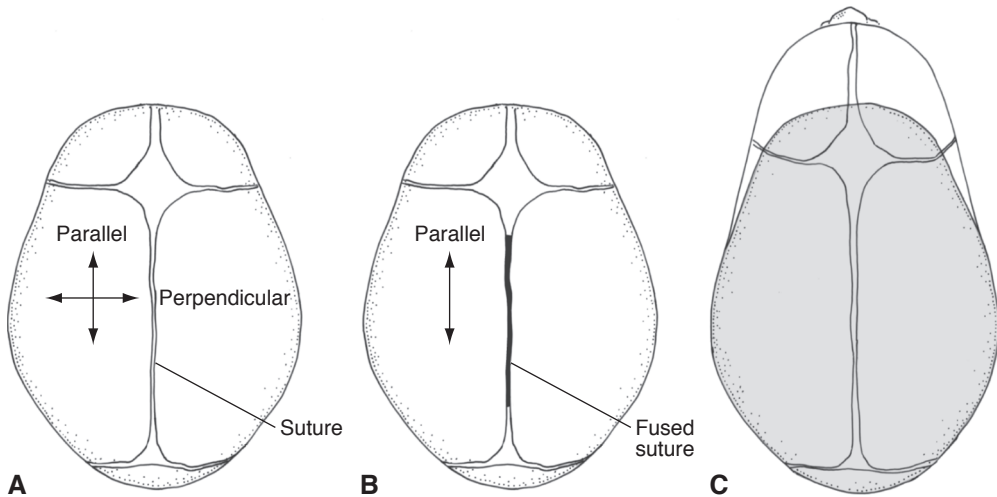




**Figure 18-1** **A**, Normal sutures and fontanelles of the fetal skull. **B**, Adult cranial base, complete with sutures. (Illustration by C. H. Wooley.)

The following are types of abnormal head shapes in infants, listed in order of decreasing frequency:

**Plagiocephaly** Most often plagiocephaly (Greek, *plagio*, “oblique”; *kephale*, “head”) is deformational, the consequence of external compressive forces, occurring prenatally or during infancy. Deformational plagiocephaly due to intrauterine constraint (eg, oligohydramnios)



**Figure 18-2** **A**, Normal sutures. Bone growth occurs at the suture, with bone laid down parallel and perpendicular to the direction of the suture. **B**, Virchow's law. Prematurely fused sutures allow bone growth only in the parallel direction; perpendicular growth is inhibited. **C**, An example of Virchow's law. Premature closure of the sagittal suture produces scaphocephaly (boatlike skull); the shaded area shows the normal skull shape. (Illustration by C. H. Wooley.)

is characterized by ipsilateral occipital flattening with contralateral forehead flattening. This condition may also be caused by unilateral coronal suture synostosis. On the synostotic side, the forehead and supraorbital rim are retruded (depressed), the interpallebral fissure is wider, and the orbit is often higher than on the nonsynostotic side. The nonsynostotic side displays a protruding or bulging forehead, a lower supraorbital rim, a narrower interpallebral fissure, and frequently a lower orbital position.

**Brachycephaly** Brachycephaly (literally, “short head”) is frequently the result of bilateral closure of the coronal sutures. Limited growth along the anterior-posterior axis results in a comparatively short head. Most often, the forehead is wide and flat.

**Scaphocephaly** Scaphocephaly (literally, “boat head”) is usually a result of premature closure of the sagittal suture. There is anteroposterior elongation of the skull, along with bitemporal narrowing.

**Dolichocephaly** In patients with dolichocephaly (literally, “long head”), the skull shape is similar to that in scaphocephaly.

**Kleeblattschädel** The skull shape is trilobar. Kleeblattschädel (“cloverleaf skull”) is typically the result of synostosis of the coronal, lambdoidal, and sagittal sutures.

### ***Etiology of craniosynostosis***

Early suture fusion can be sporadic and occur as an isolated abnormality (eg, sagittal suture synostosis and most cases of unilateral coronal suture synostosis), or it can be part of a genetic syndrome, associated with other abnormalities. Craniosynostosis syndromes are usually autosomal dominant conditions, often with associated limb abnormalities. Many

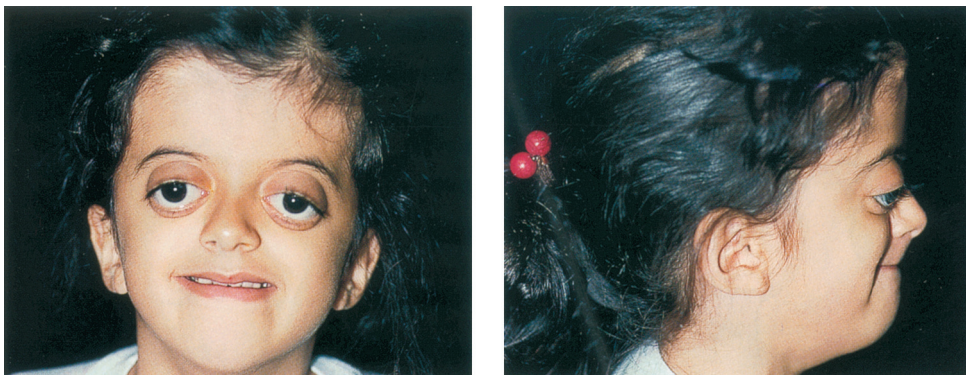of these syndromes have overlapping features, making accurate diagnosis based on clinical findings difficult. Identification of specific mutations may be diagnostic. Mutations in the fibroblast growth factor receptor genes (*FGFRs*) or in the *TWIST* gene are found in most patients with syndromic craniosynostosis.

### **Craniosynostosis syndromes**

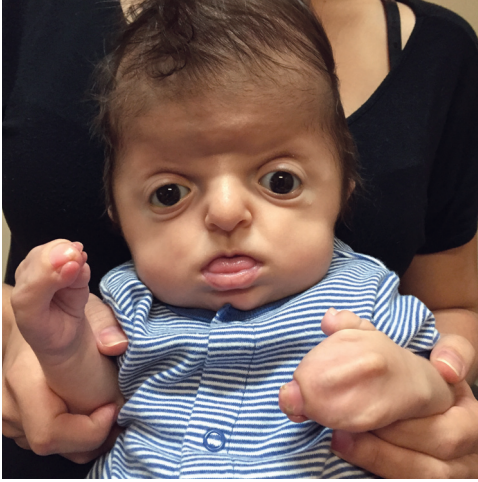Common systemic features of the craniosynostosis syndromes include fusion of multiple calvarial sutures and skull base sutures. Syndactyly (partial fusion of the digits) and brachydactyly (short digits), ranging in severity, are hallmarks of these syndromes, the exception being Crouzon syndrome. The following sections discuss the most common types of craniosynostosis syndromes. All are autosomal dominant.

**Crouzon syndrome** Crouzon syndrome is the most common craniosynostosis syndrome. Calvarial bone synostosis often includes both coronal sutures, resulting in a broad, retracted forehead; brachycephaly; and a tower-shaped skull. The skull base sutures are also involved, leading to varying degrees of midfacial retrusion. There is marked variability of the skull and facial features, with milder cases escaping diagnosis through multiple generations. Hypertelorism and proptosis, with inferior scleral show, are the most frequent features of Crouzon syndrome (Fig 18-3). Hydrocephalus is common, but intelligence is usually normal. Typically, findings are limited to the head. Unlike in the other syndromes, patients with Crouzon syndrome do not have anomalies of the hands and feet; thus, the presence or absence of these anomalies in a patient can aid diagnosis.

**Apert syndrome** Fusion of multiple calvarial sutures, most often both coronal sutures, and skull base suture fusion are usually found in patients with Apert syndrome. The skull shape and facial features of these patients resemble those of Crouzon patients. Apert syndrome, however, is associated with an often extreme amount of syndactyly (Fig 18-4), in which most or all digits of the hands and feet are completely fused (*mitten deformity*). Apert syndrome is likely to be associated with internal organ (cardiovascular and genitourinary)



**Figure 18-3** Crouzon syndrome. This patient exhibits brachycephaly and a “tower” skull with forehead retrusion; proptosis; inferior scleral show; and a small, beaklike nose. Also visible is the emerging midfacial hypoplasia. (Reproduced with permission from Katowitz JA, ed. Pediatric Oculoplastic Surgery. New York: Springer; 2002:fig 31-23.)



**Figure 18-4** Broad forehead, midfacial retrusion, and marked syndactyly in a patient with Apert syndrome. (Courtesy of Robert W. Hered, MD.)

malformations and mental deficiency. Hydrocephalus is less common in this syndrome than in Crouzon syndrome.

**Pfeiffer syndrome** Patients with Pfeiffer syndrome have craniofacial abnormalities resembling those of Apert patients but often have more severe craniosynostosis, resulting in a cloverleaf skull. There is a high risk of hydrocephalus. The syndactyly is much less severe, and patients have characteristic short, broad thumbs and toes.

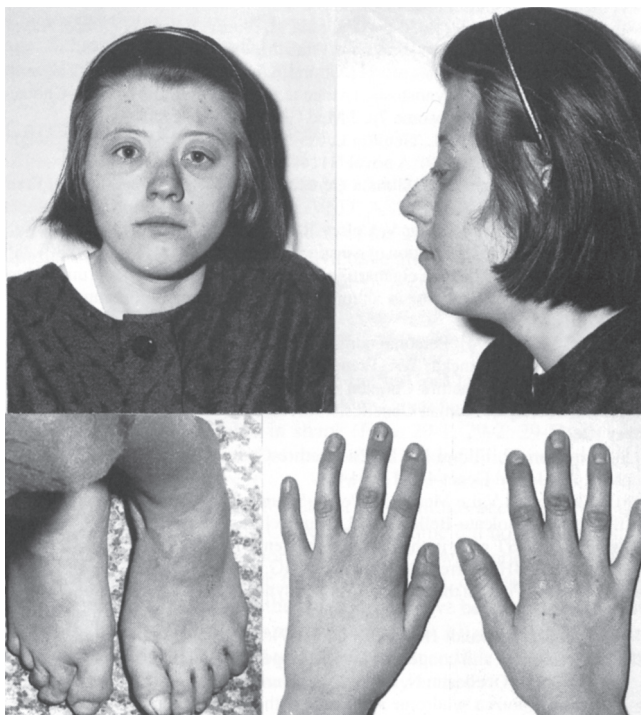**Saethre-Chotzen syndrome** The features of Saethre-Chotzen syndrome are much milder than those of other craniosynostosis syndromes; this syndrome is therefore underdiagnosed. Early suture fusion is not a constant feature but, when present, typically involves 1 coronal suture (plagiocephaly), resulting in facial asymmetry. Other common features are ptosis, low hairline, and ear abnormalities. Abnormalities of the hands and feet include brachydactyly and mild syndactyly (Fig 18-5). Intelligence is usually normal.

### ***Ocular complications of craniosynostosis***

**Proptosis** Proptosis (or exorbitism) results from the reduced volume of the bony orbit. The severity of the proptosis in patients with craniosynostosis is not uniform and frequently increases with age because of the impaired growth of the bony orbit.

**Corneal exposure** Because the eyelids may not close completely over the proptotic globes, corneal exposure may occur, with possible development of exposure keratitis. Aggressive lubrication may be necessary to prevent corneal drying. Tarsorrhaphy can reduce the exposure. Surgically expanding the orbital volume, thereby eliminating the proptosis, may be indicated in extreme cases.

**Globe luxation** In patients with extremely shallow orbits, globe luxation may occur when the eyelids are manipulated or when there is increased pressure in the orbits, such as occurs with a Valsalva maneuver. The globe is luxated forward, the eyelids closing behind the equator of the globe. The condition is very painful and can cause corneal exposure. It

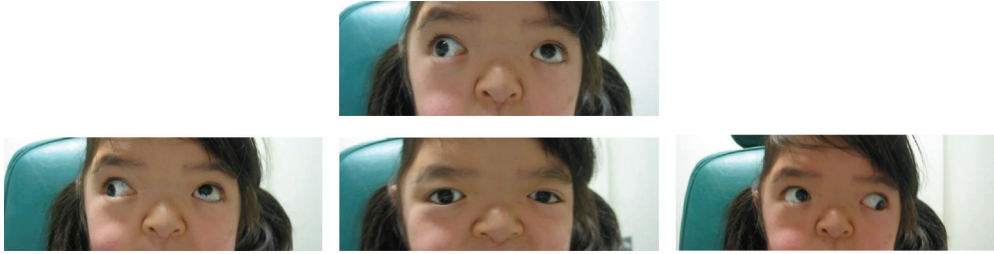


**Figure 18-5** Patient with Saethre-Chotzen syndrome. Note the facial asymmetry, flat forehead, low hairline, mild left ptosis, lateral deviation of the great toes, shortened toes, and partial syndactyly of fingers 2 and 3. (Courtesy of the March of Dimes.)

may also compromise the blood supply to the globe, which is a medical emergency. Physicians and patients (or their caregivers) should quickly reposition the globe behind the eyelids. The best technique for doing this is to place a finger and thumb over the conjunctiva within the interpalpebral fissure and exert gentle but firm pressure; this technique does not damage the cornea. For recurrent luxation, the short-term solution is tarsorrhaphy; the long-term solution is orbital volume expansion.

**Strabismus** Patients with craniosynostosis show a variety of horizontal deviations in primary position; exotropia is the most frequent. The most consistent finding, however, is a marked V pattern (see Chapter 10). This V pattern is often accompanied by a marked over-elevation in adduction, especially when 1 or both coronal sutures are fused, as occurs in unilateral coronal suture synostosis and Apert (Fig 18-6) and Crouzon syndromes. The apparent overaction (often pseudo-overaction) of the inferior oblique muscle on the side of the coronal suture fusion may be due to one of the following: orbital and globe extorsion, which converts the medial rectus muscle into an elevator when the eye is in adduction; superior oblique trochlear retrusion (because of superior orbital rim retrusion), which induces superior oblique underaction and secondary true inferior oblique overaction; anomalous extraocular muscle insertions or agenesis; or orbital pulley abnormalities (see Chapter 3).

**Optic nerve abnormalities** Optic nerve damage may occur for several reasons in patients with craniosynostosis. Optic nerve function may deteriorate in patients with chronically



**Figure 18-6** Strabismus in a patient with Apert syndrome. Note the good alignment in primary position with marked overelevation in adduction and exotropia in upgaze (V pattern). (Courtesy of John Simon, MD.)

elevated intracranial pressure (ICP), which may result from hydrocephalus or be caused by crowding of the intracranial contents due to synostosis. In patients with midfacial retrusion, sleep apnea may develop and can cause idiopathic intracranial hypertension. In rare cases, optic nerve damage can occur secondary to compression stemming from synostosis of the optic foramina. Optic atrophy may occur with or without antecedent papilledema. Because children with elevated ICP may not report headache, a common symptom of this condition, young patients with multiple fused sutures should be monitored for this complication.

**Ocular adnexal abnormalities** Common ocular adnexal abnormalities include orbital hypertelorism, telecanthus, abnormal slant of the palpebral fissures secondary to superior displacement of the medial canthi, ptosis, and nasolacrimal abnormalities. Epiphora is common and may be secondary to nasolacrimal duct obstruction, poor blink secondary to proptosis, obliquity of the palpebral fissures, or ocular irritation from corneal exposure.

### ***Surgical management of craniosynostosis***

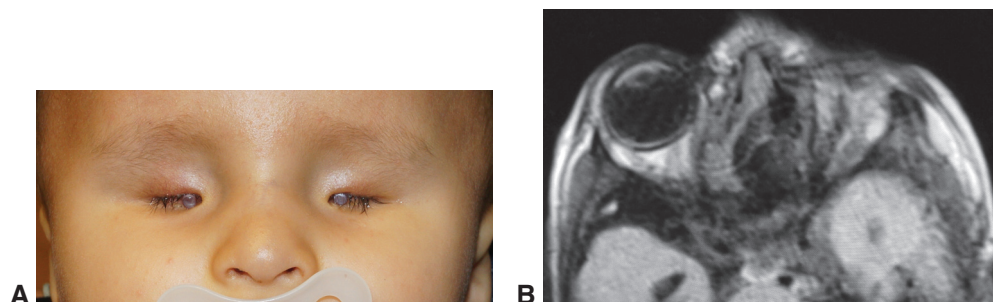
Reconstructive surgery for severe craniofacial malformation is frequently extensive and involves en bloc movement of the facial structures. The status of the visual system should be documented preoperatively and monitored postoperatively, with appropriate treatment as indicated. Procedures that involve moving the orbits may significantly change the degree or type of strabismus. Because of this, deferring treatment of strabismus until craniofacial surgery is completed may be appropriate.

## **Nonsynostotic Craniofacial Conditions**

Many craniofacial syndromes do not involve synostosis. Nonsynostotic syndromes and conditions of particular importance to the ophthalmologist are discussed in the following sections.

### ***Anophthalmia***

*Anophthalmia* (*anophthalmos*), the absence of tissues of the eye (Fig 18-7), is the most severe and rare phenotypic expression of a spectrum of abnormalities that includes typical coloboma and microphthalmia (see also Chapter 21). These conditions may be isolated, but they are frequently associated with other congenital anomalies. Anophthalmia and severe microphthalmia are associated with hypoplastic orbits and eyelids. Various techniques have been utilized for orbital expansion. The best results are achieved with early treatment.



**Figure 18-7** **A**, Anophthalmia, both eyes. **B**, Magnetic resonance image from a patient with unilateral anophthalmia shows absence of ocular structures. (Part A courtesy of Steven Couch, MD; part B courtesy of Alice Bashinsky, MD.)

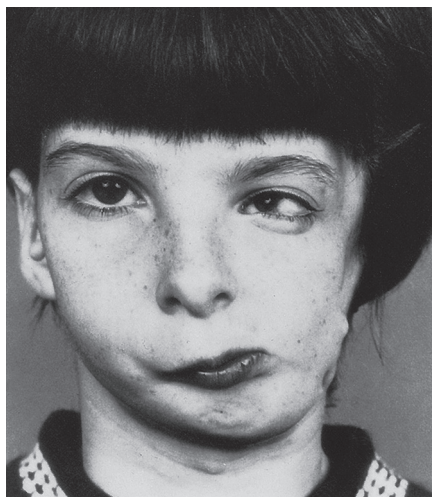### **Branchial arch syndromes**

Branchial arch syndromes are caused by disruptions in the embryonic development of the first 2 branchial arches, which are responsible for formation of the maxillary and mandibular bones, the ear, and facial musculature. The *oculoauriculovertebral spectrum* (OAVS), which includes hemifacial microsomia and Goldenhar syndrome, and Treacher Collins syndrome are the best-known branchial arch syndromes. Hemifacial microsomia is a milder form of OAVS. Patients with OAVS may have vertebral abnormalities such as hemivertebrae and vertebral hypoplasia. They may also have neurologic, cardiovascular, and genitourinary abnormalities. Most cases are sporadic.

**Goldenhar syndrome** Patients with Goldenhar syndrome have hemifacial microsomia (unilateral or bilateral) and characteristic ophthalmic abnormalities (Fig 18-8). Most cases are sporadic.

Epibulbar (limbal) dermoids and dermolipomas are characteristic ocular signs. Dermolipomas (also termed *lipodermoids*) usually occur in the temporal quadrant, covered by conjunctiva and often hidden by the lateral upper and lower eyelids. Epibulbar limbal dermoids occur more frequently than dermolipomas and can be bilateral

**Figure 18-8** Goldenhar syndrome with hemifacial microsomia. The patient has facial asymmetry, a hypoplastic left ear (microtia), an ear tag near the right ear, epibulbar dermolipoma in the left eye, and esotropia. The patient also has Duane retraction syndrome, left eye.



(approximately 25% of cases). They occasionally impinge on the visual axis but more commonly interfere with vision by causing astigmatism and anisometropic amblyopia. Eyelid colobomas may occur. Other ocular conditions include microphthalmia, cataract, and iris abnormalities. Duane retraction syndrome is more common in patients with Goldenhar syndrome.

**Treacher Collins syndrome** Treacher Collins syndrome (mandibulofacial dysostosis) is caused by abnormal growth of the first and second branchial arches, with underdevelopment and even agenesis of the zygoma and malar eminences. The lateral orbital rims are depressed and the palpebral fissures slant downward because of lateral canthal dystopia (Fig 18-9). Pseudocolobomas (uncommonly, true colobomas) occur in the outer third of the lower eyelids. Meibomian glands may be absent. The cilia of the lower eyelid medial to the pseudocoloboma may also be absent. The ears are malformed and hearing loss is common. The mandible is typically hypoplastic, leading to micrognathia. Intelligence is normal. The syndrome is inherited in an autosomal dominant fashion. Most affected patients have a mutation in the *TCOF1* gene.

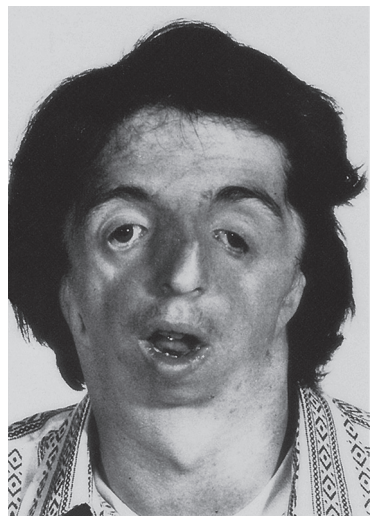
### **Pierre Robin sequence**

The Pierre Robin sequence (also *anomaly, deformity*) is characterized by micrognathia, glossoptosis, and cleft palate. The sequence is a frequent finding in Stickler syndrome. Associated ocular anomalies include retinal detachment, microphthalmia, congenital glaucoma, cataracts, and high myopia.

### **Fetal alcohol syndrome**

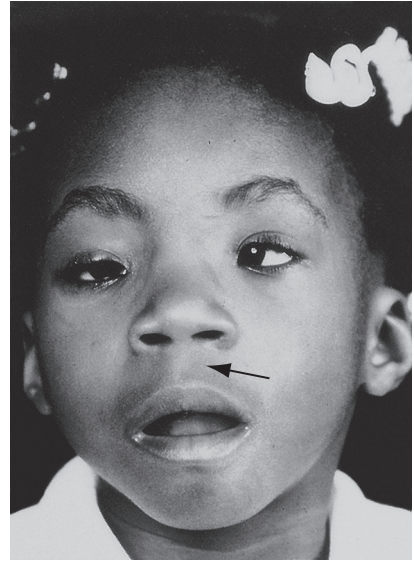
Fetal alcohol syndrome is caused by in utero exposure to ethanol. It is characterized by prenatal and postnatal growth retardation, central nervous system and craniofacial abnormalities, and intellectual disability.

The classic ocular features of fetal alcohol syndrome are short palpebral fissures, telecanthus, epicanthus, ptosis, microphthalmia, and esotropia (Fig 18-10). Anterior segment dysgenesis, optic nerve hypoplasia, and high refractive errors have been reported.



**Figure 18-9** Treacher Collins syndrome (mandibulofacial dysostosis). Note the downward slant of the palpebral fissure, low-set abnormal ears, notch or curving of the inferotemporal eyelid margin, and maxillary and mandibular hypoplasia. (Reproduced with permission from Peyman GA, Sanders DR, Goldberg MF. Principles and Practice of Ophthalmology. Philadelphia: Saunders; 1980:2411.)





**Figure 18-10** Fetal alcohol syndrome. Asymmetric ptosis; telecanthus; strabismus; long, flat philtrum (*arrow*); anteverted nostrils. This child also had Peters anomaly, left eye, and myopia, right eye. (*Reproduced with permission from Miller MT, Israel J, Cuttone J. Fetal alcohol syndrome. J Pediatr Ophthalmol Strabismus. 1981;18(4):6–15.*)

Fifty percent of children with this underdiagnosed syndrome have some form of visual impairment.

### ***Nonsynostotic disorders of bone growth***

**Infantile malignant osteopetrosis** In this rare and severe autosomal recessive form of osteopetrosis, proliferation of bone results in narrowing of the foramina of the skull. Stenosis of the optic canal increases the risk of compressive optic neuropathy. Bone marrow transplant has been reported to reverse the stenosis.

**Cranio metaphyseal dysplasia** Cranio metaphyseal dysplasia is a rare disorder of osteoclast resorption that causes hyperostosis of the cranial bones. The typical facial appearance includes frontal and paranasal bossing. Progressive stenosis of cranial nerve foramina can result in compressive optic neuropathy.

## **Infectious and Inflammatory Conditions**

---

Preseptal and orbital cellulitis usually progress more rapidly and are more severe in children than in adults. See also BCSC Section 7, *Oculofacial Plastic and Orbital Surgery*.

### **Preseptal Cellulitis**

Preseptal cellulitis, a common infection in children, is an inflammatory process involving the tissues anterior to the orbital septum. Eyelid edema may extend into the forehead. The periorbital skin becomes taut and inflamed, and edema of the contralateral eyelids may appear. Proptosis is not a feature of preseptal cellulitis, and the globe remains uninvolved. Full ocular motility and absence of pain on eye movement help distinguish preseptal from orbital cellulitis.

Preseptal cellulitis typically develops in 1 of 3 ways:

- following puncture, insect bite, or laceration of the eyelid skin (posttraumatic cellulitis): In these cases, organisms found on the skin, such as *Staphylococcus* or *Streptococcus* species, are most commonly responsible for the infection.
- in conjunction with severe conjunctivitis such as epidemic keratoconjunctivitis or methicillin-resistant *Staphylococcus aureus* (MRSA) conjunctivitis, or with skin infection such as impetigo or herpes zoster.
- secondary to upper respiratory tract or sinus infection: *Streptococcus pneumoniae* and other streptococcal species, and *S aureus* are the most common causative organisms.

Children with nonsevere preseptal infections can be treated with oral antibiotics as outpatients. Broad-spectrum drugs effective against the most common pathogens, such as cephalosporins or ampicillin–clavulanic acid combination, are usually effective. Particularly with eyelid abscesses, clindamycin may be an appropriate choice because of the increasing prevalence of MRSA, which should also be considered in patients who do not improve with treatment. Eyelid abscesses may require urgent incision and drainage.

For young infants or patients with signs of systemic illness such as sepsis or meningeal involvement, hospital admission may be indicated for appropriate cultures, imaging of the sinuses and orbits, and intravenous (IV) antibiotics. In newborns, dacryocystocele should be considered in the differential diagnosis (see Chapter 19).

## Orbital Cellulitis

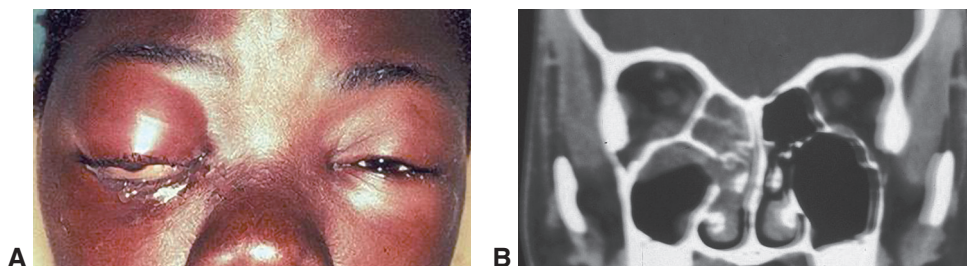
Orbital cellulitis involves the tissues posterior to the orbital septum. It is most commonly associated with ethmoid or frontal sinusitis but can also occur following penetrating injuries of the orbit.

Most young children with orbital cellulitis have infections caused by a single aerobic pathogen. In the neonate, *S aureus* and gram-negative bacilli are most common. In older children and adults, *S aureus*, *Streptococcus pyogenes*, and *S pneumoniae* are common etiologic agents. Concurrent infections with multiple pathogens, including gram-negative and anaerobic organisms, can occur in older or immunosuppressed patients.

Early signs and symptoms of orbital cellulitis include lethargy, fever, eyelid edema, rhinorrhea, headache, orbital pain, and tenderness on palpation. The nasal mucosa becomes hyperemic, with a purulent nasal discharge. Increased venous congestion may cause elevated intraocular pressure. Proptosis, chemosis, and limited ocular movement suggest orbital involvement.

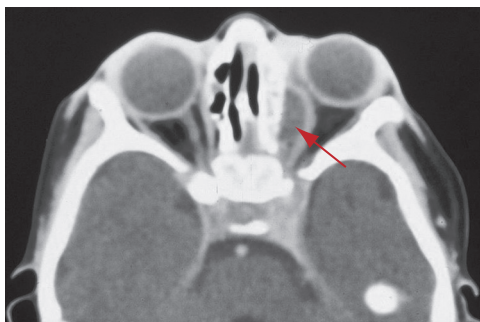
The differential diagnosis of orbital cellulitis includes nonspecific orbital inflammation, benign orbital tumors such as lymphatic malformation and hemangioma, and malignant tumors such as rhabdomyosarcoma, leukemia, and metastases.

Paranasal sinusitis is the most common cause of bacterial orbital cellulitis (Fig 18-11). In children younger than 10 years, the ethmoid sinuses are most frequently involved. If orbital cellulitis is suspected, orbital imaging is indicated to confirm orbital involvement, to document the presence and extent of sinusitis and a subperiosteal abscess (Fig 18-12), and to rule out a foreign body in a patient with a history of trauma.



**Figure 18-11** Bacterial orbital cellulitis with proptosis (A) secondary to sinusitis (B). (Courtesy of Jane Edmond, MD.)

**Figure 18-12** Axial computed tomography (CT) image showing a medial subperiosteal abscess (arrow) of the left orbit associated with ethmoid sinusitis. (Courtesy of Jane Edmond, MD.)



It is crucial to distinguish orbital cellulitis from preseptal cellulitis because the former requires hospital admission and treatment with IV broad-spectrum antibiotics. Choice of IV antibiotic is based on the most likely pathogens until results from cultures are known. If associated sinusitis or subperiosteal abscess is present, pediatric otolaryngologists should be consulted. The patient should be observed closely for signs of visual compromise. Many subperiosteal abscesses in children younger than 9 years resolve with medical management. Emergency drainage of a subperiosteal abscess is indicated for a patient of any age with *either* of the following:

- evidence of optic nerve compromise (decreasing vision, relative afferent pupillary defect) and an enlarging subperiosteal abscess
- an abscess that does not resolve within 48–72 hours of administration of antibiotics

Intraconal orbital abscesses are much less common than subperiosteal abscesses in children and require urgent surgical drainage.

Complications of orbital cellulitis include cavernous sinus thrombosis and intracranial extension (subdural or brain abscesses, meningitis, periosteal abscess), which may result in death. Cavernous sinus thrombosis can be difficult to distinguish from simple orbital cellulitis. Paralysis of eye movement in cavernous sinus thrombosis is often out of proportion to the degree of proptosis. Pain on motion and tenderness on palpation are absent. Decreased sensation along the maxillary division of cranial nerve V (trigeminal) supports the diagnosis. Bilateral involvement is virtually diagnostic of cavernous sinus thrombosis.

Other complications of orbital cellulitis include corneal exposure with secondary ulcerative keratitis, neurotrophic keratitis, secondary glaucoma, septic uveitis or retinitis, exudative retinal detachment, optic nerve edema, inflammatory neuritis, infectious neuritis, central retinal artery occlusion, and panophthalmitis.

Liao JC, Harris GJ. Subperiosteal abscess of the orbit: evolving pathogens and the therapeutic protocol. *Ophthalmology*. 2015;122(3):639–647.

### **Related conditions**

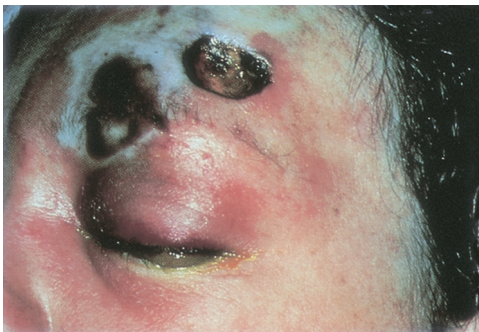*Fungal orbital cellulitis (mucormycosis)* occurs most frequently in patients with ketoacidosis or severe immunosuppression. The infection causes thrombosing vasculitis with ischemic necrosis of involved tissue (Fig 18-13). Cranial nerves often are involved, and extension into the central nervous system is common. Smears and biopsy of the involved tissues reveal the fungal organisms. Treatment includes debridement and systemic administration of antifungal medication. *Allergic fungal sinusitis* is a less fulminant condition that frequently presents with orbital signs, including proptosis from remodeling of the bony orbit. See BCSC Section 7, *Oculofacial Plastic and Orbital Surgery*, for further discussion.

### **Childhood Orbital Inflammation**

Several noninfectious, nontraumatic disorders cause orbital inflammation in children that may simulate infection or an orbital mass lesion. Thyroid eye disease, the most common cause of proptosis in adults, rarely occurs in prepubescent children but occasionally affects adolescents. Bilateral orbital inflammation may occur with sarcoidosis.

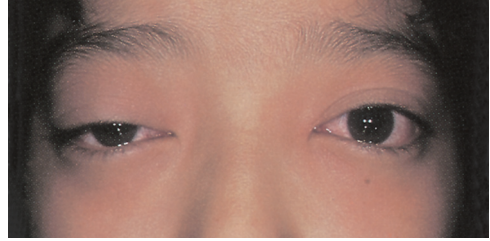
### **Nonspecific orbital inflammation**

Nonspecific orbital inflammation (NSOI) (also known as *orbital pseudotumor*, *idiopathic orbital inflammatory syndrome*) is an inflammatory cause of proptosis in childhood that differs significantly from the adult form. The typical pediatric presentation is acute and painful, more closely resembling orbital cellulitis than tumor or thyroid eye disease (Fig 18-14). NSOI is often bilateral and may be associated with systemic manifestations such as headache, nausea, vomiting, and lethargy. Uveitis is frequently present and occasionally constitutes the dominant manifestation. Imaging studies may show increased density of orbital fat, thickening of posterior sclera and the Tenon layer, or enlargement of



**Figure 18-13** Mucormycosis, left orbit.

**Figure 18-14** Bilateral nonspecific orbital inflammation (orbital pseudotumor) in an 11-year-old boy with a 1-week history of eye pain. Ocular rotation was markedly limited in all directions. CT confirmed proptosis and showed enlargement of all extraocular muscles. Laboratory workup was negative for thyroid disease and rheumatologic disorders. Complete resolution occurred after 1 month of corticosteroid treatment.



extraocular muscles. The lacrimal gland is often involved. Sinusitis is typically not present. Systemic treatment with a corticosteroid usually provides prompt and dramatic relief. Recurrent disease is common. A slow tapering of corticosteroid dosage is usually required to prevent recurrence.

**Orbital myositis** Orbital myositis describes NSOI that is confined to one or more extraocular muscles. The clinical presentation depends on the amount of inflammation. Diplopia, conjunctival chemosis, and orbital pain are common. Symptoms can be subacute or progress rapidly. Vision is rarely impaired unless massive muscle enlargement is present. Imaging studies show diffusely enlarged muscles with the enlargement extending all the way to the insertion (unlike in thyroid myopathy, which mainly involves the muscle belly). Corticosteroid treatment usually produces rapid relief of symptoms. Prolonged treatment is often necessary, and recurrence is common.

## Neoplasms

Several pediatric malignancies may occur in the orbit. Benign adnexal masses, which may threaten vision, are common in the pediatric population.

### Differential Diagnosis

Diagnosis of space-occupying lesions in the orbit is particularly challenging because the clinical manifestations are both nonspecific and relatively limited:

- proptosis or other displacement of the globe
- swelling or discoloration of the eyelids
- palpable subcutaneous mass
- ptosis
- strabismus

Many orbital processes may cause rapid onset of symptoms. These include trauma, which may occur without a reliable history. Mild or moderate proptosis can be difficult to detect in an uncooperative child with associated eyelid swelling. Nevertheless, typical presentations of the more common benign orbital and periorbital masses in infants and children (eg, hemangioma and dermoid cyst, discussed later) are sufficiently distinctive to permit confident clinical diagnosis in most cases. A malignant process should be suspected when proptosis and eyelid swelling suggestive of cellulitis are not accompanied by signs of inflammation or when periorbital ecchymosis or hematoma develops in the absence of a

history of trauma. Pseudoproptosis can result when the volume of the globe exceeds the capacity of the orbit (eg, patients with primary congenital glaucoma or high myopia).

High-quality imaging allows orbital masses to be differentiated noninvasively in many cases. Magnetic resonance imaging (MRI) is the preferred modality for most patients. Computed tomography (CT) is superior at detecting bone abnormalities but exposes the child to radiation and thus should be avoided unless necessary. Ultrasonography may be useful.

Definitive diagnosis often requires biopsy. A pediatric oncologist should be consulted when appropriate. A metastatic workup should be considered prior to orbital surgery, because other, more easily accessible sites can sometimes be biopsied.

### Primary Malignant Neoplasms

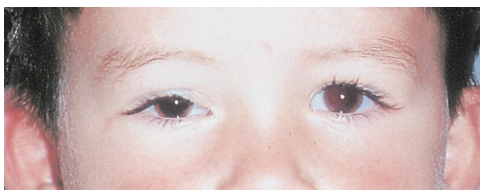Malignant diseases of the orbit include primary and metastatic tumors. Most primary malignant tumors of the orbit in childhood are sarcomas. Tumors of epithelial origin are extremely rare.

#### ***Rhabdomyosarcoma***

The most common primary orbital malignant tumor in children is rhabdomyosarcoma, which is thought to originate from undifferentiated mesenchymal cells. The incidence of this disease (which is found in approximately 5% of pediatric orbital biopsies) exceeds that of all other sarcomas combined. The orbit is the origin of 10% of rhabdomyosarcomas; 25% of these tumors arise elsewhere in the head and neck, occasionally involving the orbit secondarily. The average age at onset is 5–7 years, but rhabdomyosarcoma can occur at any age. Rhabdomyosarcoma in infancy is more aggressive and carries a poorer prognosis.

Although ocular rhabdomyosarcoma usually originates in the orbit, it occasionally arises in the conjunctiva, eyelid, or anterior uveal tract. Presenting signs and symptoms include proptosis (80%–100% of cases), globe displacement (80%), blepharoptosis (30%–50%) (Fig 18-15), conjunctival and eyelid swelling (60%), palpable mass (25%), and pain (10%). Onset of symptoms and signs is usually rapid. Acute, rapidly progressive proptosis with an absence of pain are suggestive of orbital rhabdomyosarcoma. Imaging shows an irregular but well-circumscribed mass of uniform density.

A biopsy is required for confirmation of the diagnosis whenever rhabdomyosarcoma is suspected. The most common histologic type is embryonal, which shows few cells containing characteristic cross-striations. Second in frequency is the prognostically unfavorable alveolar pattern, showing poorly differentiated tumor cells compartmentalized by orderly connective tissue septa. Botryoid (grapelike) or well-differentiated pleomorphic tumors are rarely found in the orbit but may originate in the conjunctiva.



**Figure 18-15** Rhabdomyosarcoma in a 4-year-old boy presenting with right upper eyelid ptosis of 3 weeks' duration and a palpable subcutaneous mass.

Small encapsulated or otherwise well-localized rhabdomyosarcomas should be totally excised when possible. Usually, chemotherapy and radiation are used in conjunction with surgery. Exenteration of the orbit is seldom indicated. Primary orbital rhabdomyosarcoma has a relatively good prognosis. The 5-year survival rates are 74% and 94% for patients with alveolar cell type and those with embryonal cell type, respectively.

### ***Other sarcomas***

Osteosarcoma, chondrosarcoma, and fibrosarcoma can develop in the orbit during childhood. The risk of sarcoma is increased in children with a history of heritable retinoblastoma, particularly when external-beam radiation treatment has been given.

### **Metastatic Tumors**

The orbit is the most common site of ocular metastasis in children, in contrast to adults, in whom the uvea is the most frequent site.

### ***Neuroblastoma***

Neuroblastoma is the most frequent source of orbital metastasis in childhood. This disorder is discussed in Chapter 28.

### ***Ewing sarcoma***

Ewing sarcoma is composed of small round cells and usually originates in the long bones of the extremities or in the axial skeleton. Among solid tumors, Ewing sarcoma is the second most frequent source of orbital metastasis. Treatment regimens involving surgery, radiation, and chemotherapy allow long-term survival in many patients with disseminated disease.

## **Hematopoietic, Lymphoproliferative, and Histiocytic Neoplasms**

### ***Leukemia***

Leukemic infiltration of the orbit is relatively uncommon and more characteristic of acute myelogenous leukemia. Orbital involvement may be difficult to distinguish from bacterial or fungal orbital cellulitis. Orbital infiltration can cause proptosis, eyelid swelling, and ecchymosis. It may be best managed by radiation therapy. *Granulocytic sarcoma*, or *chloroma* (in reference to the greenish color of involved tissue), is a localized accumulation of myeloid leukemic cells; the tumor may occur anywhere in the body, including in the orbit. This lesion may develop several months before leukemia becomes evident hematologically. Leukemia is discussed in Chapter 28.

### ***Lymphoma***

In contrast with lymphoma in adults, lymphoma in children very rarely involves the orbit. Burkitt lymphoma, endemic to East Africa and uncommon in North America, is the most likely form to involve the orbit.

### ***Langerhans cell histiocytosis***

*Langerhans cell histiocytosis* (LCH; formerly called *histiocytosis X*) is the collective term for a group of disorders, usually arising in childhood, that involve abnormal proliferation of

histiocytes, often within bone. The disorders are classified as unifocal eosinophilic granuloma of the bone, multifocal eosinophilic granuloma of the bone, and diffuse soft-tissue histiocytosis.

*Unifocal eosinophilic granuloma*, the most localized and benign form of LCH, produces a bone lesion that involves the orbit, skull, ribs, or long bones in childhood or adolescence. Signs and symptoms may include proptosis, ptosis, and periorbital swelling; localized pain and tenderness are relatively common. CT characteristically shows sharply demarcated osteolytic lesions without surrounding sclerosis (Fig 18-16). Treatment consists of observation of isolated asymptomatic lesions, excision or curettage, systemic or intralesional corticosteroid administration, or low-dose radiation therapy. All modalities have a high rate of success.

*Multifocal eosinophilic granuloma of the bone* is a disseminated and aggressive form of LCH. It usually presents between 2 and 5 years of age and may produce proptosis from involvement of the bony orbit. Diabetes insipidus is common. Chemotherapy is often required, but the prognosis is generally good.

*Diffuse soft-tissue histiocytosis*, the most severe form, usually affects infants younger than 2 years. It is characterized by soft-tissue lesions of multiple viscera (liver, spleen) but rarely involves the eye.

## Benign Tumors

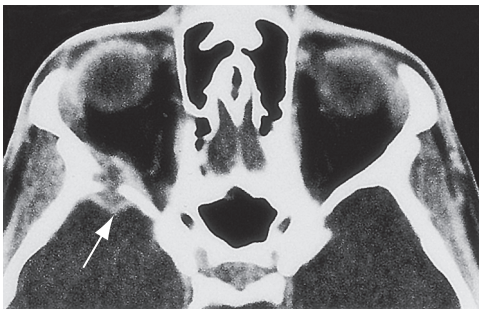### **Vascular lesions: hemangiomas**

The current classification of vascular lesions establishes clinical, histologic, and prognostic differences between hemangiomas and vascular malformations. The older terms *capillary* and *strawberry hemangioma* have been replaced by the single term *hemangioma*. Cavernous hemangiomas, port-wine stains, and lymphangiomas are classified as “malformations.” This nomenclature has not been used consistently in the ophthalmologic literature.

Hemangiomas are hamartomatous growths composed of proliferating capillary endothelial cells. Periocular hemangiomas can be classified as follows:

- preseptal, involving the skin and preseptal orbit
- intraorbital, involving the postseptal orbit
- compound/mixed, involving the preseptal and postseptal orbit

Hemangiomas occur in 1%–3% of term newborns and are more common in premature infants, in females, and after chorionic villus sampling. Most hemangiomas are



**Figure 18-16** Axial CT image showing unifocal eosinophilic granuloma with partial destruction of the right posterior lateral orbital wall (*arrow*) in a 15-year-old boy, who presented with retrobulbar pain and mild edema and erythema of the right upper eyelid.



clinically insignificant at birth. They can be inapparent or can appear as an erythematous macule or a telangiectasia. The natural history is one of rapid proliferation and growth over the first several months of life, rarely lasting beyond 1 year. Periocular lesions may cause amblyopia by inducing astigmatism or obstructing the visual axis. After the first year of life, the lesions usually begin to regress, although the rate and degree of involution vary.

**Systemic disease associated with hemangiomas** *PHACE* is an acronym for *p*osterior fossa malformations, *h*emangiomas, *a*rterial lesions, and *c*ardiac and *e*ye anomalies. The eye abnormalities include increased retinal vascularity, microphthalmia, optic nerve hypoplasia, proptosis, choroidal hemangiomas, strabismus, colobomas, cataracts, and glaucoma. The PHACE syndrome should be considered in any infant presenting with a large, segmental, plaque-like facial hemangioma involving one or more dermatomes (Fig 18-17).

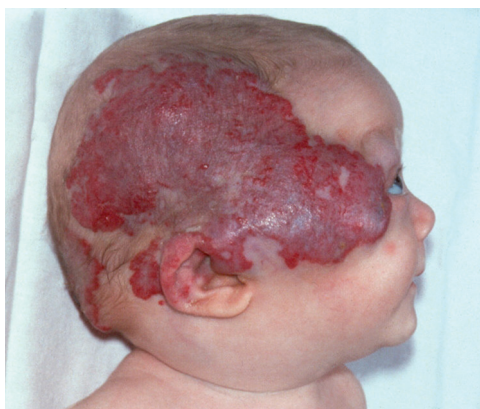*Kasabach-Merritt syndrome* is a thrombocytopenic coagulopathy with a high mortality rate. It is caused by sequestration of platelets within a vascular lesion.

*Diffuse neonatal hemangiomatosis* is a potentially lethal condition that occurs in infants, with multiple small cutaneous hemangiomas associated with visceral lesions affecting the liver, gastrointestinal tract, and brain. These hemangiomas are initially asymptomatic but can lead to cardiac failure and death within weeks. Infants with more than 3 cutaneous lesions should be evaluated for visceral lesions.

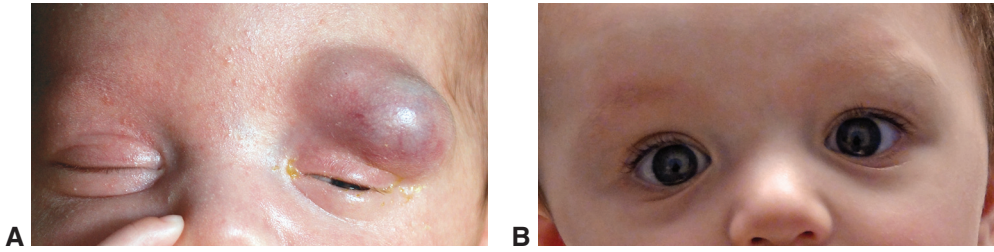
**Treatment of hemangiomas** The diagnosis of hemangiomas is usually obvious from the clinical presentation. MRI or ultrasonography is sometimes helpful in establishing the diagnosis and delineating the posterior extent of the lesion.

Observation is indicated when hemangiomas are small and there is no risk of amblyopia.

Propranolol, a nonselective  $\beta$ -adrenergic blocking agent, induces involution of most hemangiomas (Fig 18-18). The risks of systemic treatment with  $\beta$ -blockers in infants include bradycardia, hypotension, hypoglycemia, and bronchospasm, but the medication is usually well tolerated. Particular caution should be taken when propranolol is used in children with PHACE syndrome, because this drug may increase their risk of stroke. Timolol maleate solution applied topically may be effective in treating superficial



**Figure 18-17** Plaque hemangioma in a child with PHACE (posterior fossa malformations, hemangiomas, arterial lesions, and cardiac and eye anomalies) syndrome. (Courtesy of Ken K. Nischal, MD.)



**Figure 18-18** **A**, Two-month-old infant with a large hemangioma above the left eye. **B**, Resolution of the lesion following treatment with propranolol. (Courtesy of Gregg T. Lueder, MD.)

hemangiomas. Pulsed dye laser can treat superficial hemangiomas with few complications, but it has little effect on deeper components of the tumor.

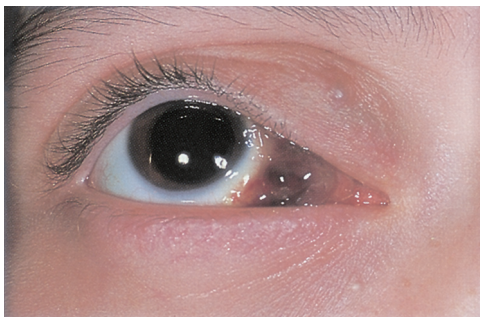
Surgical excision of periocular hemangiomas is feasible for some well-localized lesions or for lesions that do not respond to propranolol.

Drolet BA, Frommelt PC, Chamlin SL, et al. Initiation and use of propranolol for infantile hemangioma: report of a consensus conference. *Pediatrics*. 2013;131(1):128–140.

### **Vascular lesions: malformations**

Vascular malformations are developmental anomalies derived from capillary venous, arterial, or lymphatic vessels. In contrast to hemangiomas, vascular malformations remain relatively static. The age at onset and mode of clinical presentation vary. Cutaneous vascular malformations such as port-wine stains are evident from birth, but many vascular malformations do not manifest until later in life.

**Orbital lymphatic malformation** Orbital lymphatic malformation, previously known as *lymphangioma*, may produce proptosis in infancy, but usually does not until the second decade of life or later. Unilateral smaller cornea, anomalous anterior segment vessels, and abnormal retinal vessel branching in association with orbital lymphatic malformation represent a unique malformation syndrome. Lymphatic malformation of the orbit is best managed conservatively. Exacerbations tend to occur during upper respiratory tract infections and may be managed with a short course of systemic corticosteroids. Rapid expansion may be seen in cases of intralesional hemorrhage (Fig 18-19). Partial resection and drainage may be required if vision is threatened. Because of the infiltrative character



**Figure 18-19** Lymphatic malformation with hemorrhage involving the right orbit, upper eyelid, and conjunctiva in a 15-year-old girl.

of this malformation, complete removal is usually impossible. Newer treatments include oral sildenafil and intralesional injection of sclerosing agents.

Khan AO, Ghadhfan FE. Small cornea with anomalous anterior segment and retinal vasculature associated with lymphangioma. *J AAPOS*. 2009;13(1):82–84.

**Orbital venous malformations** Orbital venous malformations, or varices, can be divided into 2 types: primary and secondary. The primary type is confined to the orbit and is not associated with arteriovenous malformations (AVMs). Secondary orbital varices occur as a result of intracranial AVM shunts that cause dilation of the orbital veins. Orbital venous malformations usually become symptomatic after years of progressive congestion and rarely manifest before the second decade of life. Treatment is reserved for highly symptomatic lesions.

**Orbital arteriovenous malformations** AVMs isolated within the orbit are extremely rare. Patients with congenital AVMs of the retina and midbrain (*Wyburn-Mason syndrome*; see Chapter 28) may have orbital involvement. AVMs of the bony orbit rarely manifest in childhood but when present are characterized by pulsatile proptosis, chemosis, congested conjunctival vessels, and elevated intraocular pressure. AVMs may be treated by embolization, surgical resection, or both.

### ***Tumors of bony origin***

During the early years of life, a variety of uncommon benign orbital tumors of bony origin can present with gradually increasing proptosis. *Fibrous dysplasia* and *juvenile ossifying fibroma* are similar disorders in which normal bone is replaced by fibro-osseous tissue. In both conditions, orbital CT shows varying degrees of lucency and sclerosis.

Fibrous dysplasia has a slow progression that ceases when skeletal maturation is complete. The most serious complication is vision loss caused by optic nerve compression, which may occur acutely. Periodic assessment of vision, pupil function, and optic disc appearance is indicated. Surgical treatment is indicated for functional deterioration or disfigurement.

Juvenile ossifying fibroma is distinguished histologically by the presence of osteoblasts. It tends to be more locally invasive than fibrous dysplasia; some authorities recommend early excision.

*Brown tumor of bone* is an osteoclastic giant cell reaction resulting from hyperparathyroidism. *Aneurysmal bone cyst* is a degenerative process in which normal bone is replaced by cystic cavities containing fibrous tissue, inflammatory cells, and blood, producing a characteristic radiographic appearance.

### ***Tumors of connective tissue origin***

Benign orbital tumors originating from connective tissue are rare in childhood. *Juvenile fibromatosis* may present as a mass in the inferoanterior part of the orbit. These tumors, sometimes called *myofibromas* or *desmoid tumors*, are composed of relatively mature fibroblasts. They tend to recur locally after excision and can be difficult to control, but they do not metastasize.

### **Tumors of neural origin**

*Optic pathway glioma* is the most important orbital tumor of neural origin in childhood. Optic pathway gliomas are usually low-grade pilocytic astrocytomas, but the rate of growth with or without therapeutic intervention is unpredictable. Management of these tumors is controversial and depends largely on their location. Approximately 30% of optic pathway gliomas are associated with neurofibromatosis type 1. *Plexiform neurofibroma* nearly always occurs in the context of neurofibromatosis and frequently involves the eyelid and orbit. See Chapter 28 for further discussion of plexiform neurofibroma and optic pathway glioma. Orbital *meningioma* and *schwannoma* (neurilemoma, neurinoma) are rare in childhood.

## **Ectopic Tissue Masses**

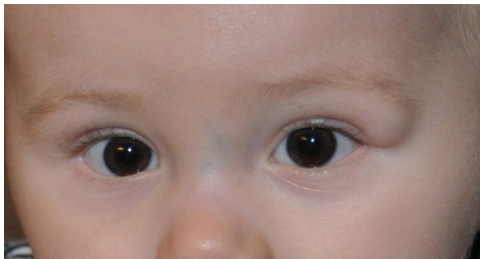The term *choristoma* is applied to growths consisting of tissue that is histologically normal but present in an abnormal location. The growths may result from abnormal sequestration of germ layer tissue during embryonic development or from faulty differentiation of pluripotential cells. Masses composed of such ectopic tissue that are growing in the orbit can also be a consequence of herniation of tissue from adjacent structures.

### **Cystic Lesions**

#### ***Dermoid and epidermoid cysts***

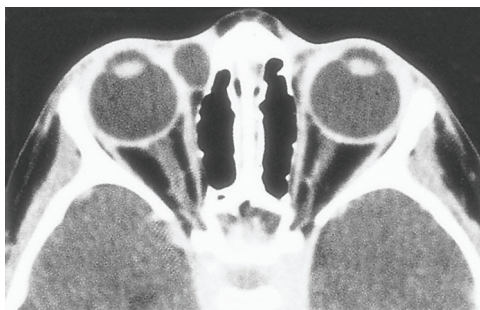*Dermoid cysts* are the most common space-occupying orbital lesions of childhood. They are benign developmental choristomas that arise from primitive dermal and epidermal elements sequestered in fetal skull suture lines. The tissue forms a cyst lined with keratinized epithelium and dermal appendages, including hair follicles, sweat glands, and sebaceous glands. Cysts containing squamous epithelium without dermal appendages are called *epidermoid cysts*.

Orbital dermoid cysts in childhood most commonly arise in the superotemporal and superonasal quadrants (Fig 18-20) but sometimes extend into the bony suture line. Clinically, they present as painless, smooth masses that are mobile and unattached to overlying skin. Inflammation may occur with ruptures of the cyst and extrusion of cyst contents. Most patients have no visual symptoms. Clinical examination is often sufficient for diagnosis. In some cases, imaging is indicated to identify and delineate the extent of the cyst.



**Figure 18-20** Eight-month-old boy with a periorbital dermoid cyst, left eye, with typical superotemporal location. (Courtesy of Robert W. Hered, MD.)

**Figure 18-21** Axial CT image showing a dermoid cyst of the superonasal anterior orbit, right eye, in a 6-year-old boy.



Imaging reveals a well-circumscribed lesion with a low-density lumen and often bony remodeling (Fig 18-21).

Management of dermoid cysts is surgical. Early excision can reduce the risk of traumatic rupture and subsequent inflammation. An infraorbital or eyelid crease incision is used, and the cyst is carefully dissected. If possible, rupture of the cyst at the time of surgery is avoided to limit lipogranulomatous inflammation and scarring. If the cyst is entered, the intraluminal material should be thoroughly removed. Sutural cysts sometimes cannot be removed intact because of their extension into or through bone. To limit the possibility of recurrence, the surgeon must attempt removal of all remaining cyst lining.

### ***Microphthalmia with cyst***

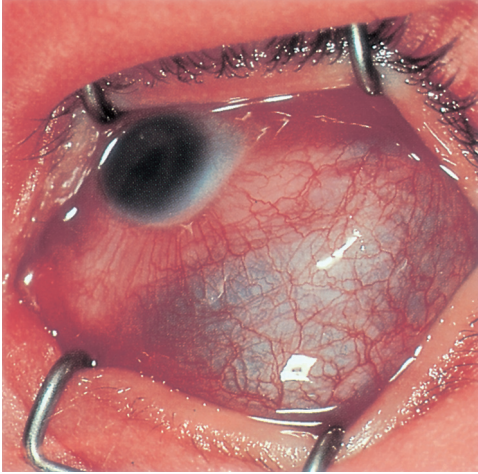
Microphthalmia with cyst (also known as *colobomatous cyst*) is characterized by a small, malformed globe with posterior segment coloboma and a cyst composed of tissues originating from the eye wall of the globe. Most fundus colobomas show some degree of scleral ectasia. In extreme cases, a bulging globular appendage grows to become as large as or larger than the globe itself, which is invariably microphthalmic, sometimes to a marked degree.

Microphthalmia with cyst may occur either as an isolated congenital defect or in association with a variety of intracranial or systemic anomalies. Frequently, the fellow eye shows evidence of coloboma as well. The usual location of the cyst is inferior or posterior to the globe, with which the cyst is always in contact.

Whether posteriorly located cysts cause proptosis depends on the size of the globe and the cyst. Inferiorly located cysts present as a bulging of the lower eyelid or a bluish subconjunctival mass (Fig 18-22). If fundus examination does not make the diagnosis obvious, orbital imaging may reveal a cystic lesion that is attached to the globe and has the uniform internal density of vitreous. The goal of treatment is to promote normal growth of the orbit; methods include aspiration or surgical excision of the cyst, and use of orbital expanders and conformers.

### ***Mucocele***

Mucoceles are cystic lesions that originate from obstructed paranasal sinus drainage. They may expand over time, potentially causing destruction of bone and eroding into the orbit or intracranial space. These lesions most commonly arise from the frontal or anterior ethmoid sinuses, resulting in inferior or medial displacement of the globe. The differential diagnosis includes encephalocele with skull base deformity. Treatment involves reestablishing normal sinus drainage and removing the cyst wall.



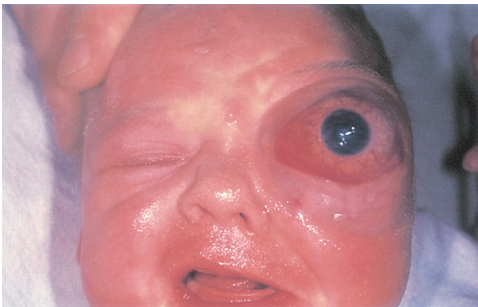**Figure 18-22** Microphthalmia with cyst (colobomatous cyst), left eye.

### ***Encephalocele and meningocele***

Encephaloceles and meningoceles in the orbital region may result from a congenital bony defect that allows herniation of intracranial tissue, or they may develop after trauma that disrupts the bone and dura mater of the anterior cranial fossa. An intraorbital location leads to proptosis or downward displacement of the globe. Anterior presentation takes the form of a subcutaneous mass that can be misdiagnosed as a dacryocystocele. However, encephaloceles and meningoceles are typically located above the medial canthal tendon; dacryocystoceles are typically located below it (see Chapter 19). Pulsation of the globe or the mass from the transmission of intracranial pulse pressure is characteristic. Neuroimaging confirms the diagnosis. Surgical repair is usually performed by neurosurgeons.

### **Teratoma**

Choristomatous tumors that contain multiple tissues derived from all 3 germinal layers (ectoderm, mesoderm, and endoderm) are referred to as *teratomas*. Most teratomas are partially cystic, with varying fluid content. Orbital teratomas account for a very small fraction of both orbital tumors and teratomas in general. The clinical presentation of orbital teratomas may be particularly dramatic, with massive proptosis evident at birth (Fig 18-23). In contrast with teratomas in other locations, which tend to show malignant growth, most



**Figure 18-23** Congenital cystic teratoma originating in the left orbit of a 1-day-old girl.

orbital lesions are benign. Surgical excision, facilitated by prior aspiration of fluid, can often be accomplished without sacrificing the globe. Permanent optic nerve damage from stretching and compression may cause poor vision in the involved eye.

### **Ectopic Lacrimal Gland**

These are rare choristomatous lesions that may present with proptosis in childhood. Cystic enlargement and chronic inflammation sometimes aggravate the condition.

# Lacrimal Drainage System Abnormalities

Nasolacrimal duct obstruction (NLDO) can be congenital or acquired. Congenital NLDO (CNLDO) is the most common lacrimal system disorder encountered in pediatric ophthalmology. This chapter discusses CNLDO, including nonsurgical and surgical management, as well as other congenital and developmental anomalies of the lacrimal system that may be treated by the ophthalmologist. Acquired NLDO is discussed in BCSC Section 7, *Oculofacial Plastic and Orbital Surgery*.

Anatomical features of the lacrimal drainage system and their development are discussed in BCSC Section 2, *Fundamentals and Principles of Ophthalmology*, and Section 7, *Oculofacial Plastic and Orbital Surgery*.

## Congenital and Developmental Anomalies

---

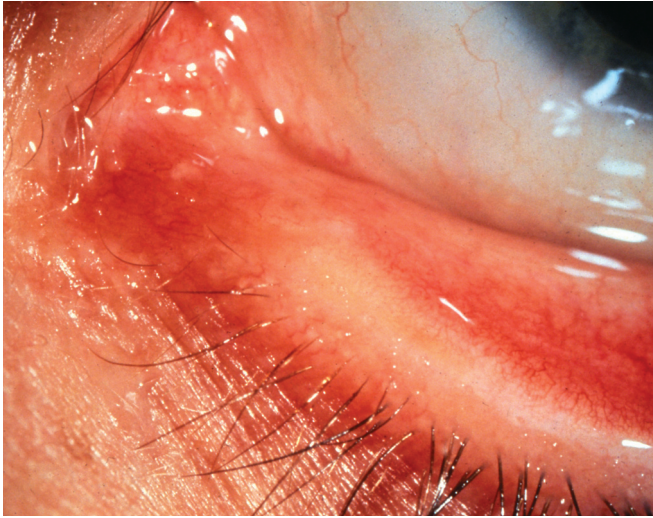
### Atresia of the Lacrimal Puncta or Canaliculi

*Atresia of the lacrimal puncta or canaliculi* refers to failure of canalization during development of the upper lacrimal system structures. Patients with atresia usually present with overflow of clear tears; there is no infection because bacteria cannot reach the lacrimal sac to produce one. The presence of mucopurulent discharge in a patient with atresia of either the upper or lower canaliculus usually indicates concomitant obstruction of the distal NLD, with reflux of discharge through the normal canaliculus.

There are 2 main causes of upper lacrimal system obstruction. One is a thin membrane that obstructs the lacrimal puncta, which are otherwise normal. Simple puncture of the membrane with a punctal dilator eliminates this obstruction. For concomitant obstruction of the distal NLD, probing of the distal system is necessary.

The second cause of upper lacrimal system obstruction is atresia of the puncta and canaliculi. In affected patients, no puncta can be seen (Fig 19-1). If only 1 of the canaliculi is atretic and there is mucopurulent discharge, probing of the distal duct through the patent canaliculus may be curative. If both the upper and the lower canaliculi are absent, an incision through the eyelid margin at the expected location of the canaliculi may reveal structures that can be cannulated. However, many patients ultimately require conjunctivodacryocystorhinostomy (CDCR), a procedure that creates a complete bypass of the lacrimal





**Figure 19-1** Atresia of the lacrimal puncta. No indentation is visible at the site of the normal punctal opening. (Reproduced with permission from Lueder GT. Neonatal lacrimal system anomalies. *Semin Ophthalmol.* 1997;12(2):109.)

drainage system. CDCR is usually deferred until these patients are older. See BCSC Section 7, *Oculofacial Plastic and Orbital Surgery*, for a discussion of this procedure.

### **Congenital Lacrimal Fistula**

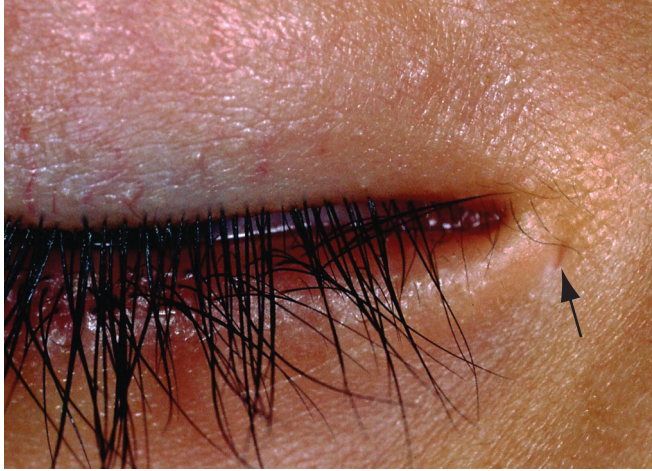Congenital lacrimal fistula (lacrimal–cutaneous fistula) is an epithelium-lined tract extending from the common canaliculus or lacrimal sac to the overlying skin surface. It usually presents as a small dimple medial to the eyelids and may be difficult to detect in the absence of symptoms (Fig 19-2). It is not always patent. If the patient is asymptomatic, no treatment is necessary. Discharge from the fistula is often associated with distal NLDO and may cease after probing of the distal obstruction. If discharge persists despite a patent lacrimal duct, surgical excision of the fistula between the skin and normal lacrimal structures is required.

### **Dacryocystocele**

Congenital dacryocystocele (dacryoceles, mucocele, amniotocele) is present in approximately 3% of infants with NLDO. It develops when a distal blockage causes distention of the lacrimal sac. The valve of Rosenmüller can act as a one-way valve, thereby preventing decompression of the lacrimal sac. Most patients with dacryocystoceles have associated cysts of the distal NLD, which may be seen beneath the inferior turbinate. Involvement is bilateral in 20%–30% of cases.

#### ***Clinical features and diagnosis***

Dacryocystocele presents at birth or within the first few days of life as a bluish swelling just below and nasal to the medial canthus. The differential diagnosis includes hemangioma,

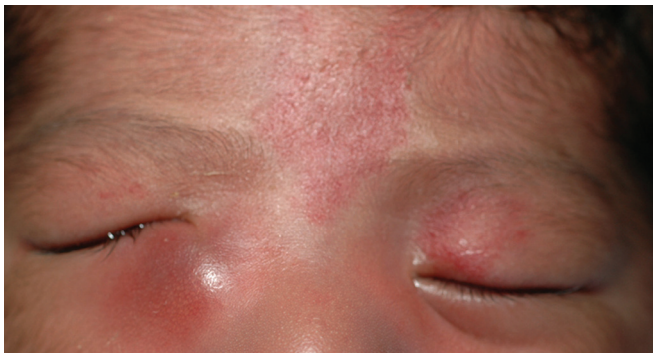

**Figure 19-2** Lacrimal fistula. (Reproduced with permission from Lueder GT. Neonatal lacrimal system anomalies. *Semin Ophthalmol.* 1997;12(2):109.)

dermoid cyst, and encephalocele. Hemangiomas are not typically present at birth. They have a vascular appearance and are generally less firm than dacryocystoceles. Dermoid cysts and encephaloceles present most often above the medial canthal tendon. The diagnosis is clinically apparent when a newborn has a nasal mass beneath the medial canthus that is associated with symptoms of NLDO (discussed later in the chapter); imaging is usually not required in this case.

Dacryocystoceles are prone to infection, and acute dacryocystitis usually develops. The skin over the distended lacrimal sac becomes erythematous (Fig 19-3), and pressure applied on the sac may produce reflux of purulent material.

Infants who have large intranasal cysts may present with respiratory symptoms because infants are obligate nasal breathers. Symptoms range from difficulty during feeding (due to obstruction of the mouth) to respiratory distress.



**Figure 19-3** Infected congenital dacryocystocele, right eye, in a newborn. Note the typical location and erythema overlying the distended lacrimal sac. (Courtesy of Edward L. Raab, MD.)

### **Management**

Early treatment of dacryocystoceles is advised to prevent complications related to infection. Infants are relatively immunocompromised and are therefore at risk for local or systemic spread of infection. Digital massage may be attempted to decompress the dacryocystocele, as the condition occasionally resolves without surgery.

Dacryocystoceles associated with acute respiratory distress require immediate surgical intervention. If the lesions do not resolve within the first 1–2 weeks of life or if there is acute infection of the dacryocystocele, surgery is necessary. NLD probing alone may be curative, but in approximately 25% of patients, the condition persists after probing. NLD probing in conjunction with nasal endoscopy and intranasal cyst removal is effective in more than 95% of infants. Because approximately 20%–30% of patients have bilateral nasal cysts, sometimes without visible dacryocystoceles, bilateral endoscopy is appropriate. Systemic antibiotics should be used perioperatively if acute dacryocystitis is present. Surgical treatment of an infected dacryocystocele via a skin incision should be avoided because of the risk of creating a persistent fistulous tract.

Lueder GT. The association of neonatal dacryocystoceles and infantile dacryocystitis with nasolacrimal duct cysts (an American Ophthalmological Society thesis). *Trans Am Ophthalmol Soc.* 2012;110:74–93.

## **Congenital Nasolacrimal Duct Obstruction**

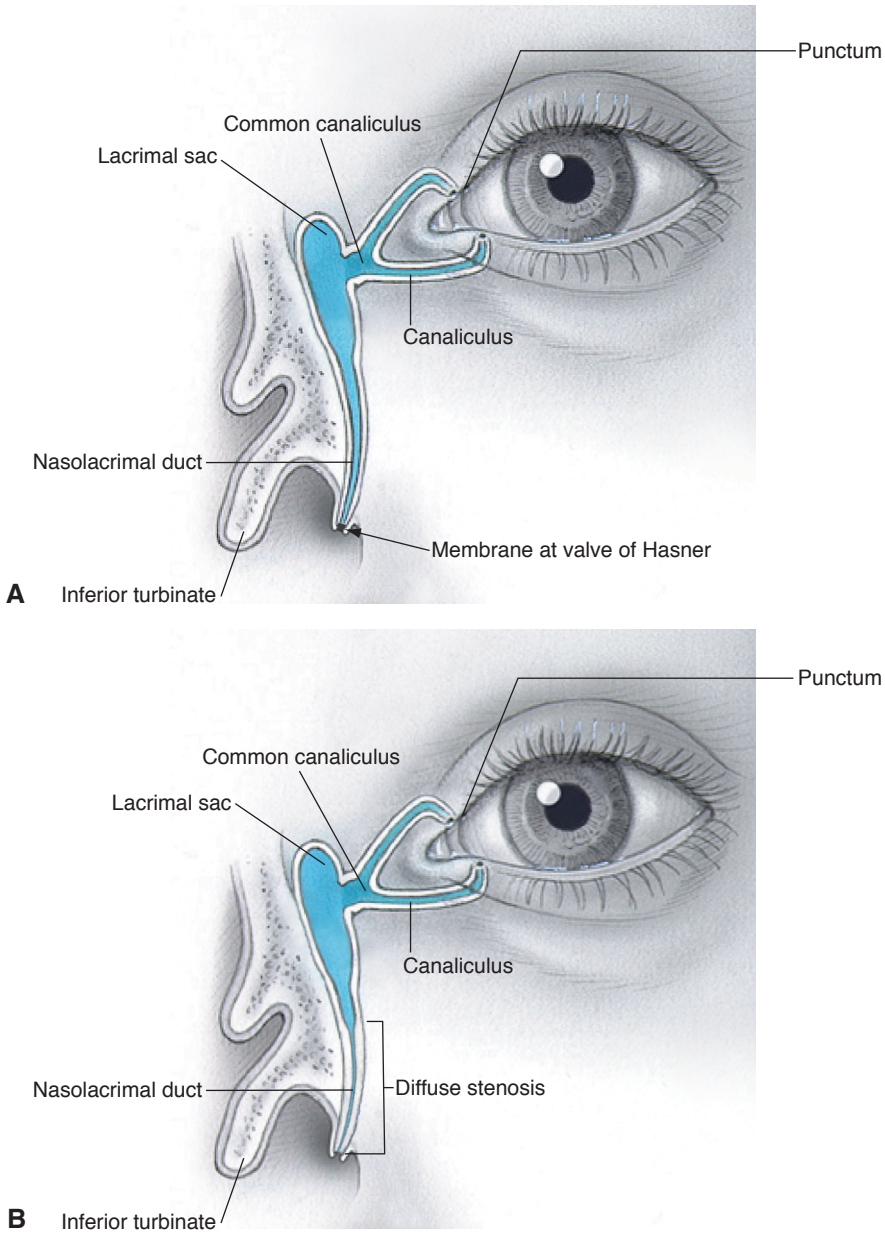
Congenital nasolacrimal duct obstruction (CNLDO) (dacryostenosis) is the most common lacrimal system disorder encountered in pediatric ophthalmology, occurring in approximately 5% of infants, and is more common in patients with Down syndrome (22%) and in those with midfacial abnormalities.

CNLDO can be classified as simple or complex. Simple CNLDO is caused by a thin mucosal membrane at the distal end of the NLD, at the valve of Hasner (Fig 19-4). Complex CNLDO is due to diffuse obstruction or bony obstruction, as is frequently found in patients with midfacial abnormalities.

### **Clinical Features and Examination**

Infants with CNLDO usually present within the first month of life with epiphora, recurrent periocular crusting, or both (Fig 19-5). They do not have photophobia or blepharospasm. Symptoms are usually chronic and worse with nasal congestion; bilateral involvement is common. Applying digital pressure to the lacrimal sac usually results in retrograde discharge of mucoid or mucopurulent material.

Excessive tearing due to CNLDO must be differentiated from epiphora due to infantile glaucoma, which has additional features, including photophobia, blepharospasm, ocular hypertension, corneal clouding with or without enlargement, and breaks in Descemet membrane (see Chapter 22). Besides infantile glaucoma, the differential diagnosis of CNLDO includes conjunctivitis, and epiblepharon with irritation due to trichiasis. A thorough examination is necessary to rule out other ocular abnormalities. A cycloplegic refraction should be performed as results of some studies suggest that there is an increased rate of anisometropia and amblyopia in patients with CNLDO.

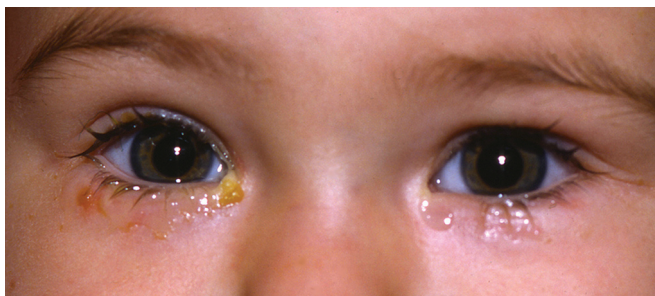

**Figure 19-4** **A**, Typical location of the membrane causing simple nasolacrimal duct obstruction (NLDO) (*arrow*). **B**, Diffuse stenosis of the distal NLD. (*Adapted from an illustration by Christine Galapp.*)

### Nonsurgical Management

There is a high rate of spontaneous resolution of CNLDO, with approximately 90% of patients improving within the first 9–12 months of life. For this reason, conservative treatment is recommended initially for these patients.

Conservative treatment includes lacrimal sac massage and use of topical antibiotics. Massage serves 2 purposes: it empties the sac, thereby reducing the opportunity for bacterial



**Figure 19-5** Bilateral NLDO. Note epiphora and periocular crusting without evidence of inflammation. (Reproduced with permission from Lueder GT. *Pediatric Practice Ophthalmology*. New York: McGraw-Hill Professional; 2011:55.)

growth, and it applies hydrostatic pressure to the obstruction, which may open the duct and resolve the condition. Massage is performed by applying pressure to the lacrimal sac, at the medial canthus, a few times per day. This is the only location where application of external pressure on the lacrimal sac can be effective. Passing the finger along the nares, which is often recommended by primary care providers, is not effective because the NLD is covered by bone at this site.

Topical antibiotics are often recommended if patients have significant periocular discharge. There are 3 important points with regard to topical antibiotic use in this disorder. First, the antibiotics do not cure the obstruction but may reduce the amount of mucopurulent discharge. Second, the infection in CNLDO is due to stasis of fluid within the lacrimal sac; therefore, almost any bacteria, including normal flora, may cause infection. Most broad-spectrum antibiotics are effective in reducing the associated symptoms, so culturing the mucoid or mucopurulent material is usually not necessary. Third, antibiotic use for a few days often produces improvement, and prolonged use may not be necessary. Parents may be instructed to administer the antibiotics as needed when the amount of discharge increases.

### **Surgical Management**

Nasolacrimal probing is one of the most common procedures performed by pediatric ophthalmologists and is very effective in treating CNLDO. It is used to treat infants with CNLDO whose symptoms do not resolve over time with conservative treatment. There are 2 common approaches to the surgical management of this disorder. Some ophthalmologists recommend in-office probing of young infants, whereas others prefer to delay treatment and perform surgery in the operating room on older infants. The advantages of early in-office probing are that it avoids general anesthesia, resolves symptoms earlier, and is likely more cost effective. The disadvantages are that a painful procedure is performed on an awake infant and that surgery is performed on many infants who would have spontaneously improved without surgery. The advantages of later surgery in the operating room are that fewer infants require treatment and the procedure is performed in a more controlled environment in which additional procedures can be performed concurrently. Either of these approaches is acceptable.

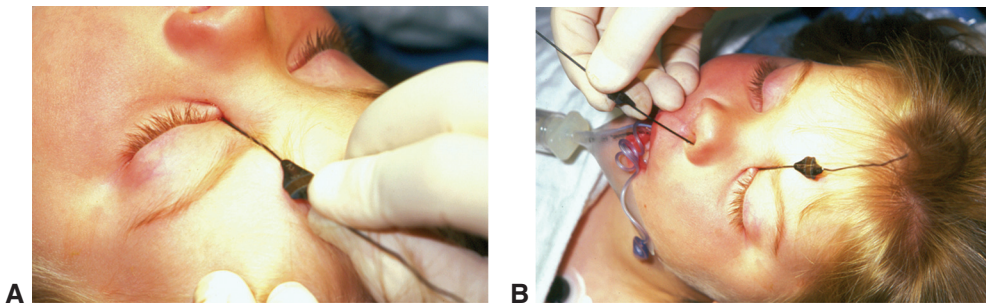
Surgical procedures for CNLDO are also discussed in BCSC Section 7, *Oculofacial Plastic and Orbital Surgery*.

Pediatric Eye Disease Investigator Group. A randomized trial comparing the cost-effectiveness of 2 approaches for treating unilateral nasolacrimal duct obstruction. *Arch Ophthalmol.* 2012;130(12):1525–1533.

### Probing

When nasolacrimal probing is to be performed in the operating room, placement of an oxymetazoline-soaked pledget beneath the inferior turbinate before surgery may decrease intraoperative bleeding. The initial step in nasolacrimal probing is dilation of the puncta and proximal canaliculi. Punctal membranes and atretic canaliculi are sometimes not recognized until surgery. Their management is discussed earlier in this chapter. Because the lacrimal system cannot be visualized beyond the puncta, knowledge of the anatomy and normal course of the lacrimal excretory system is essential for passing lacrimal probes properly. The probes are initially inserted in the puncta, perpendicular to the eyelid. Within 1–2 mm of the eyelid margin, the canaliculi turn approximately 90°; the probes are therefore turned almost immediately and passed along the course of the canaliculi until the nasal bone is encountered on the medial side of the lacrimal sac. The probes are held flat on the patient's face and rotated and passed gently into the distal duct (Fig 19-6A). With simple CNLDO, most surgeons feel a slight popping sensation as the probe passes through the membrane causing the obstruction. With complex CNLDO (see the following section), the surgeon's probe may encounter a firmer obstruction or a tight passage throughout the length of the NLD.

A wide variety of techniques are used for probing in NLDO. Most surgeons begin with a size 0 or 1 Bowman probe, and some pass successively larger probes to enlarge the distal duct. Introducing a second metal probe into the nares and making direct contact with the previously placed lacrimal probe verifies the position of the latter (Fig 19-6B). Alternatively, direct inspection with a nasal speculum and headlamp or with a nasal endoscope can precisely determine the position of the probe. Irrigation may be performed following probing in order to verify that the system is patent. Infracture of the inferior turbinate may be used to widen the area where the fluid drains beneath the inferior turbinate. The surgeon



**Figure 19-6** Probing for NLDO. **A**, The probe is advanced through the lacrimal sac and NLD, in this instance via the lower canaliculus. **B**, A second probe introduced into the nares is used to verify the position of the probe tip. (Courtesy of Edward L. Raab, MD.)

accomplishes this by placing a small periosteal elevator beneath the turbinate or by grasping it with a hemostat and then rotating the instrument.

Postoperatively, minor bleeding from the nose or into the tears commonly occurs and usually requires no treatment. Optional postoperative medications include antibiotic drops, corticosteroid drops, or both instilled 1–4 times daily for 1–2 weeks. Phenylephrine or oxymetazoline nasal spray may be used to control nasal bleeding or congestion. Because transient bacteremia can occur after probing, systemic antibiotic prophylaxis should be considered for patients with cardiac disease.

Resolution of signs after probing may not occur until 1 week or more postoperatively. Recurrence after unsuccessful probing is usually evident within 1–2 months. The success rate of properly performed initial probing for CNLDO exceeds 80% in infants younger than 15 months.

Significant complications of probing are rare. In some patients, mild epiphora occurs occasionally, particularly outdoors in cold weather or in conjunction with an upper respiratory tract infection. This epiphora is probably attributable to a patent but narrow lacrimal drainage channel. Usually no additional treatment is required.

### ***Patients with complex CNLDO or persistent symptoms after initial probing***

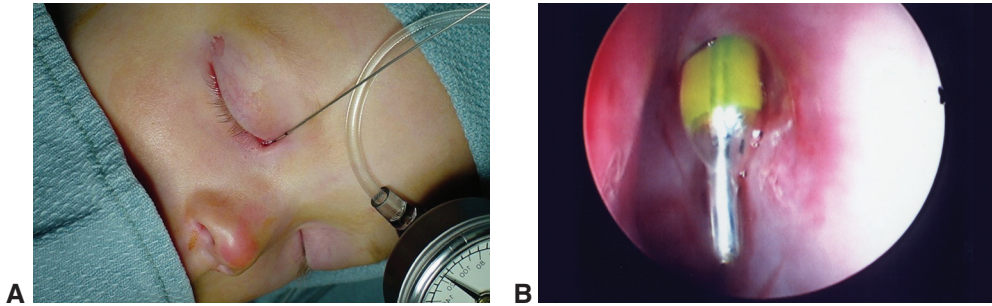
A variety of treatment options are available for patients with complex CNLDO (usually discovered at the time of initial surgery) or those with symptoms that persist following initial probing. Some surgeons may choose to perform balloon dacryoplasty or NLD stenting as the initial procedure in patients they believe are at risk for recurrence of CNLDO. Recurrent NLDO is more likely in persons with chronic rhinitis, those older than 36 months, or patients with complex CNLDO. Balloon dacryoplasty or intubation is more successful than probing alone for persistent NLDO after initial probing. The selection of intubation or balloon dacryoplasty is based on surgeon preference. Infrafracture of the inferior turbinate has not been shown to improve surgical outcomes. Perioperative systemic antibiotics and steroids may be beneficial in children at risk for recurrence.

Pediatric Eye Disease Investigator Group. Balloon catheter dilation and nasolacrimal duct intubation for treatment of nasolacrimal duct obstruction after failed probing. *Arch Ophthalmol.* 2009;127(5):633–639.

Silbert DI, Matta N. Congenital nasolacrimal duct obstruction. *Focal Points: Clinical Practice Perspectives.* San Francisco: American Academy of Ophthalmology; 2016, module 6.

**Balloon dacryoplasty** Balloon dacryoplasty (balloon catheter dilation) is performed by passing a catheter into the distal NLD and inflating its balloon at the site of obstruction (Fig 19-7). This procedure is particularly useful for patients with diffuse, rather than localized, obstruction of the distal duct.

**Intubation** Intubation of the lacrimal system is usually recommended when probing or balloon dacryoplasty has failed. Several methods of intubation are available. Bicanalicular intubation is performed by passing stents through the upper and lower canaliculi and recovering them in the nares. Most surgeons secure the stents in the nares by using a bolster or by suturing the stents to the nasal mucosa. Monocanalicular stents are placed by passing



**Figure 19-7** Balloon dacryoplasty. **A**, Passing the balloon into the NLD. **B**, Inflated balloon, endoscopic view. (Part B courtesy of Eric Paul Purdy, MD.)

them through either the upper or lower canaliculus or sometimes by passing separate stents through both canaliculi.

Complications associated with stents include elongation of the lacrimal puncta, dislodging and protrusion of the stents, and corneal abrasions. In some cases, the stent can be repositioned, but early removal may be necessary.

Stents are usually left in place for 2–6 months, but shorter periods can be successful. The technique used for stent removal depends on the age of the patient, the measure employed to secure the stent, and the position of the stent (in place or partially dislodged).

**Nasal endoscopy** Anatomical abnormalities of the distal NLD account for some of the failures of initial probing. These abnormalities include cysts similar to those seen in infants with dacryocystoceles and flaccid mucosal membranes obstructing the distal duct. In addition, there may be false passages, which may be recognized endoscopically; in these cases, probing may be repeated. Removal of abnormal structures is performed under endoscopic guidance. Endoscopy may be performed by the ophthalmologist alone or in conjunction with an otolaryngologist.

### **Older children with NLDO**

There is some controversy in the literature regarding success rates for NLD surgery in older children. The Pediatric Eye Disease Investigator Group (PEDIG) found a high success rate for simple probing in children up to 36 months of age. Many older children have simple NLDO; they have the same membranous obstruction of the distal duct found in younger children with NLDO (see Fig 19-4A). As previously mentioned, this obstruction is identified by a distinct popping sensation as the probe is passed into the distal duct. Probing in older patients with this finding has a success rate similar to that in younger children. Because probing is less likely to be successful in complex NLDO, particularly in older children, balloon dacryoplasty or stent placement should be considered as the initial surgical procedure.

Pediatric Eye Disease Investigator Group; Repka MX, Chandler DL, Beck RW, et al. Primary treatment of nasolacrimal duct obstruction with probing in children younger than 4 years. *Ophthalmology*. 2008;115(3):577–584.



***Dacryocystorhinostomy***

Dacryocystorhinostomy involves creation of a new opening between the lacrimal sac and the nasal cavity. It is an option when the procedures described in the preceding sections are unsuccessful and NLDO persists or recurs. The decision of when to perform this procedure is affected by the severity of the signs and symptoms of obstruction. See BCSC Section 7, *Oculofacial Plastic and Orbital Surgery*, for further discussion of this procedure.

# External Diseases of the Eye

This chapter focuses on external diseases of the eye that are seen in the pediatric population. Many of the topics covered in this chapter are also discussed in BCSC Section 8, *External Disease and Cornea*.

## Infectious Conjunctivitis

---

Bacterial and viral infections are the most common causes of infectious conjunctivitis in children in developed countries. Presenting symptoms of infectious conjunctivitis commonly include burning, stinging, and foreign-body sensation; signs include conjunctival hyperemia, ocular discharge, and matting of the eyelids. Symptoms and signs may be present unilaterally or bilaterally. The character of the discharge is diagnostically helpful and may be serous, mucopurulent, or purulent. Purulent discharge suggests a polymorphonuclear response to a bacterial infection, mucopurulent discharge suggests a viral or chlamydial infection, and a serous or watery discharge suggests a viral or allergic reaction. Membrane or pseudomembrane formation may occur in severe viral or bacterial conjunctivitis, Stevens-Johnson syndrome, ligneous conjunctivitis, and chemical burns. Table 20-1 lists common causes of conjunctival hyperemia, or *red eye*, in infants and children.

## Ophthalmia Neonatorum

*Ophthalmia neonatorum* refers to conjunctivitis occurring in the first month of life. This condition can be caused by bacterial, viral, or chemical agents. Widespread effective prophylaxis has diminished its occurrence to very low levels in industrialized countries, but ophthalmia neonatorum remains a significant cause of ocular infection, blindness, and even death in medically underserved areas around the world.

## Epidemiology and etiology

Worldwide, the incidence of ophthalmia neonatorum is greater in areas with high rates of sexually transmitted disease and poor health care. The prevalence ranges from 0.1% in highly developed countries with effective prenatal and perinatal care to 10% in areas such as East Africa. Because a mother may have multiple sexually transmitted diseases, infants with one type of ophthalmia neonatorum should be screened for other such diseases. Public health authorities should be contacted to initiate evaluation and treatment of other maternal contacts in cases of sexually transmitted diseases.

**Table 20-1 Common Causes of Conjunctival Hyperemia in Infants and Children**

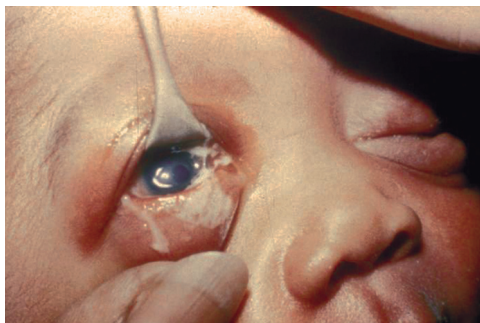
Infectious conjunctivitis
Bacterial infection
Chlamydial infection
Viral infection
Blepharitis
Allergic conjunctivitis
Trauma
Foreign body
Drug, toxic, or chemical reaction
Iritis
Episcleritis or scleritis
Epiblepharon

The causative organism usually infects the infant through direct contact during passage through the birth canal. Infection can ascend to the uterus, especially if there is prolonged rupture of membranes, so even with cesarean delivery, infants can be infected.

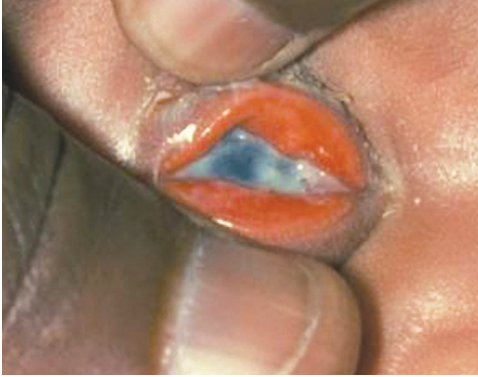***Neisseria gonorrhoeae*** Ophthalmia neonatorum caused by *Neisseria gonorrhoeae* typically presents in the first 3–4 days of life. Patients may present with mild conjunctival hyperemia and ocular discharge. In severe cases, there is marked chemosis, copious discharge, and potentially rapid corneal ulceration and perforation (Fig 20-1). Systemic infection can cause sepsis, meningitis, and arthritis.

Gram stain of the conjunctival exudate showing gram-negative intracellular diplococci allows a presumptive diagnosis of *N gonorrhoeae* infection; treatment should be started immediately. Ophthalmia neonatorum from *Neisseria meningitidis* has also been reported. Definitive diagnosis is based on culture of the conjunctival discharge. Treatment of gonococcal ophthalmia neonatorum includes systemic ceftriaxone and topical irrigation with saline. Topical antibiotics may also be indicated if there is corneal involvement.

***Chlamydia trachomatis*** *Chlamydia trachomatis* is an obligate intracellular bacterium that can cause neonatal inclusion conjunctivitis. Onset of conjunctivitis usually occurs around



**Figure 20-1** *Neisseria gonorrhoeae* conjunctivitis. (Courtesy of Jane C. Edmond, MD.)



**Figure 20-2** Chlamydial ophthalmia neonatorum. (Courtesy of Jane C. Edmond, MD.)

1 week of age, although it may be earlier, especially in cases with premature rupture of membranes. Eye infection is characterized by minimal to moderate filmy discharge, mild swelling of the eyelids, and hyperemia with a papillary reaction of the conjunctiva (Fig 20-2). Severe cases may be accompanied by more copious discharge and pseudomembrane formation. Chlamydial infection in infants differs from that in adults in several ways: in infants, membrane formation may occur, the amount of mucopurulent discharge is greater, and there is no follicular response.

Chlamydial infections can be diagnosed by culture of conjunctival scrapings, polymerase chain reaction, direct fluorescent antibody tests, and enzyme immunoassays. Systemic treatment of neonatal chlamydial disease is indicated because of the risk of pneumonitis and otitis media. The treatment of choice is oral erythromycin, 50 mg/kg per day in 4 divided doses for 14 days. Topical erythromycin ointment may be used in addition to but not as a replacement for oral therapy.

**Herpes simplex virus** Infection with herpes simplex virus (HSV) is usually secondary to HSV type 2 and typically presents later than infection with *N gonorrhoeae* or *C trachomatis*, frequently in the second week of life. See the discussion of congenital HSV infection in Chapter 28.

### **Chemical conjunctivitis**

Chemical conjunctivitis refers to a mild, self-limited irritation and redness of the conjunctiva occurring in the first 24 hours after instillation of silver nitrate, a preparation used for ophthalmia neonatorum prophylaxis. This condition improves spontaneously by the second day of life.

### **Ophthalmia neonatorum prophylaxis**

Originally, 2% silver nitrate was used as prophylactic treatment of gonorrheal ophthalmia neonatorum. However, it is not effective against *C trachomatis* and has largely been supplanted by agents that are effective against both *N gonorrhoeae* and *C trachomatis*, such as erythromycin and tetracycline ointments and 2.5% povidone-iodine solution. Silver nitrate is still used in some parts of the world.

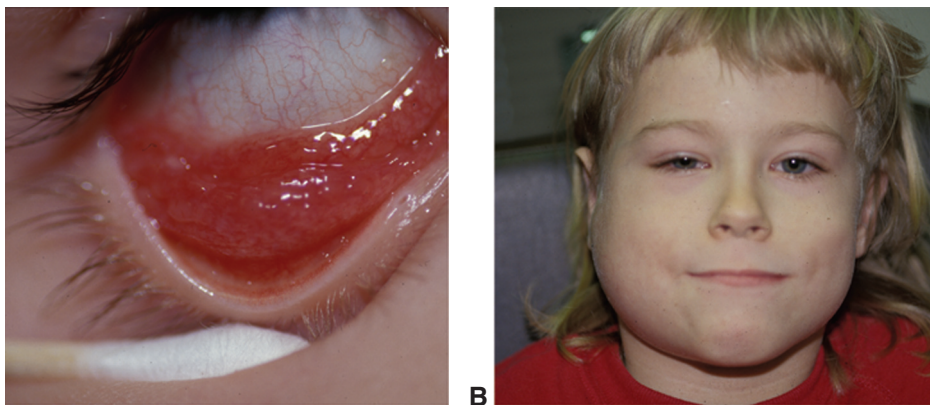
### Bacterial Conjunctivitis in Children and Adolescents

The most common causes of bacterial conjunctivitis in school-aged children are *Streptococcus pneumoniae*, *Haemophilus* species, *Staphylococcus aureus*, and *Moraxella*. The incidence of infection from *Haemophilus* has decreased because of widespread immunization, whereas the incidence of methicillin-resistant *S aureus* (MRSA) conjunctivitis has increased. More severe forms of bacterial conjunctivitis accompanied by copious discharge suggest infection with more virulent organisms, including *N gonorrhoeae* and *N meningitidis*.

Diagnosis is by clinical presentation. Culture to identify the offending agent is usually not necessary in mild cases but should be performed in severe cases. If the infection is untreated, symptoms are self-limited but may last up to 2 weeks. A broad-spectrum topical ophthalmic drop or ointment should shorten the course to a few days. Topical medications that are usually effective include polymyxin combinations, aminoglycosides, erythromycin, bacitracin, fluoroquinolones, and azithromycin. Fluoroquinolones may be considerably more expensive than other medications and may increase the risk of promoting drug-resistant organisms. Patients with *N meningitidis* conjunctivitis, and others exposed to these patients, require systemic treatment because of the high risk of meningitis.

### Parinaud oculoglandular syndrome

Parinaud oculoglandular syndrome (POS) manifests as unilateral granulomatous conjunctivitis associated with preauricular and submandibular lymphadenopathy that can be very marked (Fig 20-3). MRSA conjunctivitis can have a similar presentation. *Bartonella henselae*, a pleomorphic gram-negative bacillus that is endemic in cats and causes cat-scratch disease, is the most common cause of POS. Other causative organisms include *Mycobacterium tuberculosis*, *Mycobacterium leprae*, *Francisella tularensis*, *Yersinia pseudotuberculosis*, *Treponema pallidum*, and *C trachomatis*. Cat-scratch disease is usually associated with a scratch from a kitten, but a cat bite or even touching the eye with a hand that has been licked by an infected kitten can cause the disease.



**Figure 20-3** Parinaud oculoglandular syndrome. **A**, Marked follicular reaction in the lower fornix. **B**, Massive enlargement of submandibular lymph node on the affected right side. (Courtesy of David A. Plager, MD.)

Serologic testing is an effective means of diagnosing POS. Presence of antibodies to *B henselae*, detected by indirect fluorescent antibody testing or enzyme immunoassay, can confirm a diagnosis of cat-scratch disease. Treatment can be supportive in mild cases of cat-scratch disease because the disease is self-limited. In more severe cases systemic treatment, usually with azithromycin, may be indicated. Appropriate systemic antibiotics are used to treat the other organisms that cause POS.

### **Chlamydial infections**

Two different diseases can be caused by *C trachomatis* in children and adolescents: trachoma (serotypes A–C) and adult inclusion conjunctivitis (serotypes D–K).

**Trachoma** Trachoma is the most common cause of preventable blindness in the world. This disease is uncommon in Europe and the United States, except in areas of the southern United States and on Native American reservations. It is caused by poor hygiene and inadequate sanitation and is spread from eye to eye or by flies or fomites. Clinical manifestations include acute purulent conjunctivitis, a follicular reaction, papillary hypertrophy, vascularization of the cornea, and progressive cicatricial changes of the cornea and conjunctiva. Diagnosis is made by Giemsa stain, cell culture, or polymerase chain reaction. Treatment includes both topical and systemic erythromycin. Tetracycline can be used in children 8 years of age and older.

**Adult inclusion conjunctivitis** Adult inclusion conjunctivitis is a sexually transmitted disease that can be found in sexually active adolescents in association with chlamydial urethritis or cervicitis. However, there are nonsexual modes of transmission, including shared eye cosmetics and contaminated swimming pools. Patients present with follicular conjunctivitis, scant mucopurulent discharge, and preauricular lymphadenopathy. There is no membrane formation. This condition can be diagnosed by culture of conjunctival scrapings, polymerase chain reaction, direct fluorescent antibody tests, and enzyme immunoassays. If untreated, inclusion conjunctivitis resolves spontaneously in 6–18 months. The recommended treatment is oral tetracycline, doxycycline, azithromycin, or erythromycin. The clinician should consider whether the patient has been sexually abused, especially if adult inclusion conjunctivitis is found in a young child.

## **Viral Conjunctivitis in Infants and Children**

### **Adenovirus**

Viral conjunctivitis is most often caused by an adenovirus, a DNA virus that can cause a range of human diseases, including upper respiratory tract infection and gastroenteritis. The following adenoviral diseases are listed with their associated serotypes: epidemic keratoconjunctivitis (serotypes 8, 19, and 37, subgroup D), pharyngoconjunctival fever (serotypes 3 and 7), acute hemorrhagic conjunctivitis (serotypes 11 and 21), and acute follicular conjunctivitis (serotypes 1, 2, 3, 4, 7, and 10). Contact precautions are especially important during the examination of infants. Outbreaks of adenoviral conjunctivitis have been associated with retinopathy of prematurity examinations in neonatal intensive care units. In neonates, adenoviral pneumonia can be fatal or lead to serious morbidity.

Haas J, Larson E, Ross B, See B, Saiman L. Epidemiology and diagnosis of hospital-acquired conjunctivitis among neonatal intensive care unit patients. *Pediatr Infect Dis J*. 2005;24(7):586–589.

**Epidemic keratoconjunctivitis** Epidemic keratoconjunctivitis (EKC) is a highly contagious conjunctivitis that tends to occur in epidemic outbreaks. This infection is an acute bilateral follicular conjunctivitis that is usually unilateral at onset and associated with preauricular lymphadenopathy. Initial symptoms are foreign-body sensation and periorbital pain. A diffuse superficial keratitis is followed by focal epithelial lesions that stain. After 11–15 days, subepithelial opacities begin to form beneath the focal epithelial infiltrates. The epithelial component fades by day 30, but the subepithelial opacities may remain for up to 2 years. In severe infections, particularly in infants, a conjunctival membrane forms and marked swelling of the eyelids occurs; these signs must be differentiated from those of orbital or preseptal cellulitis. In severe cases, complications include persistent subepithelial opacities and conjunctival scar formation.

Because EKC is easily transmitted, contact precautions must be maintained for up to 2 weeks. Isolation areas should be designated for examination of patients known or suspected to have adenoviral infections.

Diagnosis is usually based on clinical presentation but can be confirmed in the office by a rapid immunodetection assay. The organism can be recovered from the eyes and throat for 2 weeks after onset, demonstrating that patients are infectious during this period. Treatment is supportive in most cases. Artificial tears and cold compresses can provide symptomatic relief. Topical corticosteroids may be used judiciously to decrease symptoms in severe cases and in cases of decreased vision secondary to subepithelial opacities; such agents may prolong the time to full recovery. Corticosteroid use in adenoviral infection is seldom indicated in children.

**Pharyngoconjunctival fever** Pharyngoconjunctival fever presents with conjunctival hyperemia, subconjunctival hemorrhage, conjunctival edema, epiphora, and eyelid swelling, accompanied by sore throat and fever. Within a few days, a follicular conjunctival reaction and preauricular lymphadenopathy develop. Symptoms may last for 2 weeks or more. Treatment is supportive because no topical or systemic treatment alters the course of the disease.

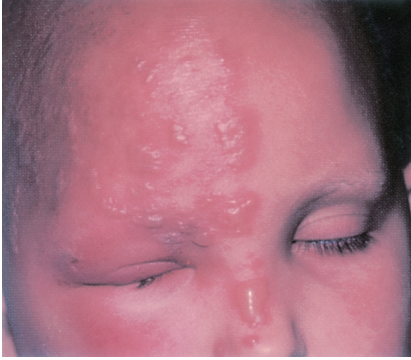### ***Herpes simplex virus***

Conjunctivitis caused by HSV type 1 is covered in BCSC Section 8, *External Disease and Cornea*.

### ***Varicella-zoster virus***

Varicella-zoster virus (VZV) is a herpesvirus that can cause varicella and herpes zoster.

**Varicella** Varicella (chickenpox) is a contagious viral exanthem of childhood caused by primary infection with VZV. Varicella vaccine is very effective in preventing severe disease, but immunized children exposed to VZV may have mild symptoms. Clinical manifestations of primary VZV infection include fever and characteristic vesicular lesions of the



**Figure 20-4** Herpes zoster.

skin and mucous membranes. Except for eyelid vesicles and follicular conjunctivitis, ocular involvement is uncommon. Treatment of conjunctival disease is usually not necessary. Intravenous or oral acyclovir is recommended by the American Academy of Pediatrics in the treatment of immunocompromised children with varicella.

**Herpes zoster** Reactivation of latent VZV in dorsal root and cranial nerve ganglia results in herpes zoster. Vesicular lesions may erupt on the periorbital skin and are localized to a single dermatome, with subsequent ocular involvement (Fig 20-4). Keratitis and anterior uveitis are most likely to occur if the nasociliary branch of cranial nerve V is affected.

Oral acyclovir is indicated in healthy children to shorten the course of the illness and decrease the risk of bacterial superinfection. Intravenous antiviral agents (famciclovir, valacyclovir, acyclovir) are indicated in immunocompromised patients or individuals with severe disseminated disease. Antiviral medications should be started within 72 hours of onset of symptoms.

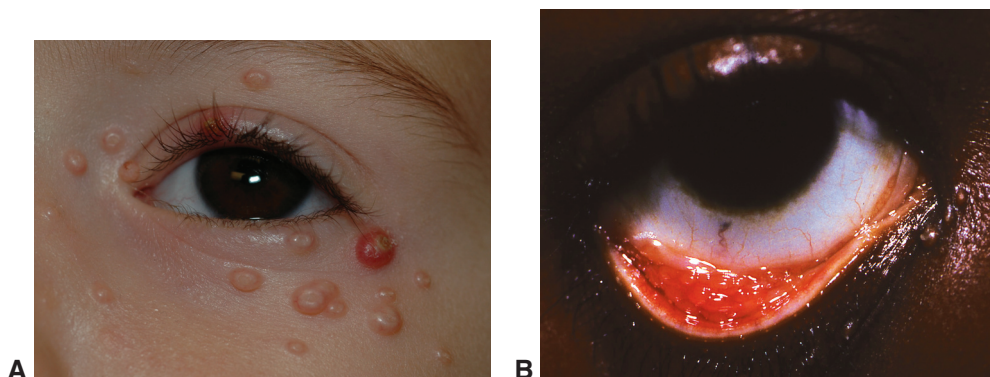
### ***Epstein-Barr virus***

Epstein-Barr virus is a herpesvirus that can cause infectious mononucleosis, a benign and self-limited disease that occurs most commonly between ages 15 and 30 years. Findings include fever, widespread lymphadenopathy, pharyngitis, hepatic involvement, and the presence of atypical lymphocytes in the circulating blood. Conjunctivitis is the most common ocular finding. Nummular keratitis may also occur. The diagnosis is confirmed with detection of immunoglobulin M antibodies to viral capsid antigens or with a positive result on the heterophile antibody test. Ocular treatment is cool compresses to the eyes.

### ***Molluscum contagiosum***

Molluscum contagiosum is caused by a DNA poxvirus and usually presents as numerous umbilicated skin lesions (Fig 20-5A). Lesions on or near the eyelid margin can release viral particles onto the conjunctival surface, resulting in a follicular conjunctivitis (Fig 20-5B). Most lesions do not require treatment because they tend to resolve spontaneously; however, resolution can take months or years. Lesions causing conjunctivitis can be treated by incising each lesion and debriding the central core; in young children, such treatment usually requires general anesthesia.





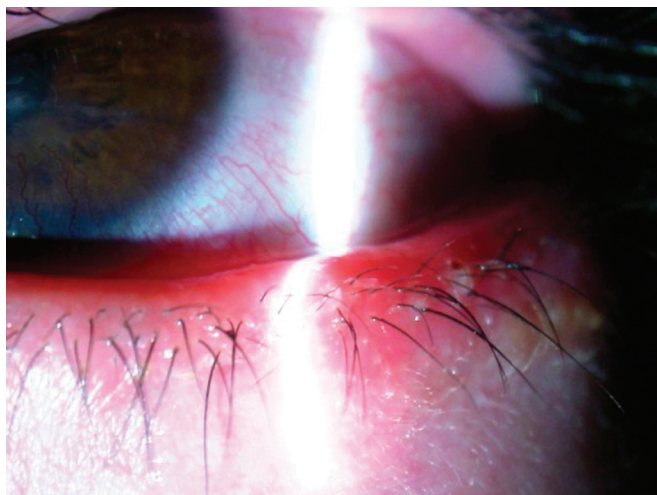
**Figure 20-5** Molluscum contagiosum. **A**, Eyelid lesions. **B**, Secondary follicular conjunctivitis. (Part A courtesy of Edward L. Raab, MD; part B courtesy of Gregg T. Lueder, MD.)

## Inflammatory Disease

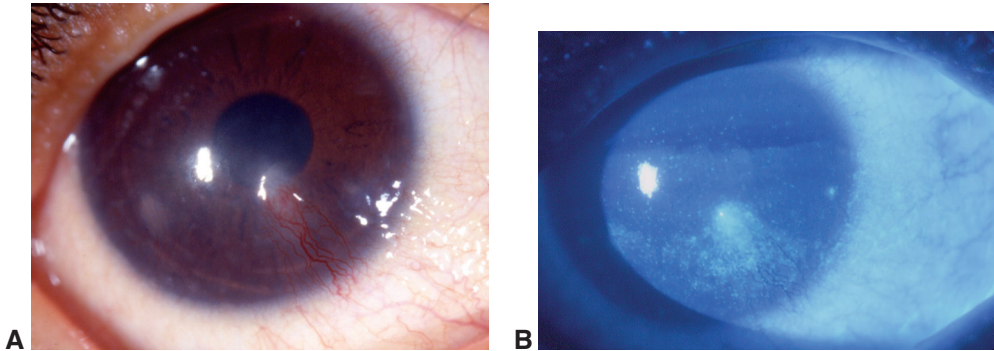
### Blepharitis

Blepharitis is a common cause of chronic conjunctivitis in children. The signs and symptoms of blepharitis in children are similar to those in adults and include ocular irritation, conjunctival hyperemia, morning eyelid crusting, eyelid margin erythema, and meibomian gland obstruction (Fig 20-6). Intermittent blurred vision may occur because of tear film instability. Inferior keratitis may develop in more severe cases, leading to epithelial disruption and fluorescein staining, corneal scarring, and permanent vision loss (Figs 20-7, 20-8).

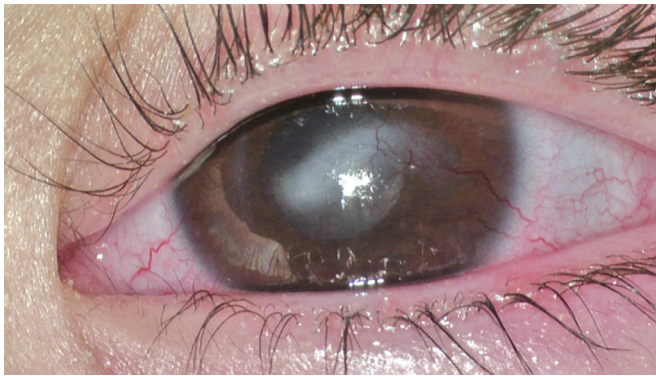
Recurrent chalazia in children may indicate underlying blepharitis. Acne rosacea in children may be manifested by chronic blepharitis and facial telangiectasias, papules, and



**Figure 20-6** Blepharitis with meibomian gland dysfunction, scurf, and telangiectasias. (Courtesy of Steven Safran, MD.)



**Figure 20-7** **A**, Inferior keratitis secondary to severe blepharitis. **B**, Fluorescein staining of keratitis (same patient as in part A). (Courtesy of Robert W. Hered, MD.)



**Figure 20-8** Severe corneal scarring secondary to keratitis caused by blepharitis. (Courtesy of Erin Stahl, MD.)

pustules. *Demodex* (human mites that inhabit the hair follicles) may play a role in the pathogenesis of blepharitis and should be considered when blepharitis does not respond to treatment. Patients with demodicosis typically present with a waxy, sleeve-like buildup at the base of eyelashes. Demodicosis may respond to dilute tea tree oil applied to lash bases.

Initial treatment of blepharitis includes warm compresses, eyelid scrubs with baby shampoo, and erythromycin or bacitracin ophthalmic ointment or azithromycin ophthalmic solution, 1%. Severe cases may benefit from oral antibiotic use. Tetracyclines (tetracycline, doxycycline, minocycline) and macrolides (erythromycin, azithromycin) may be helpful. Macrolides are most commonly used in children younger than 8 years to avoid the potential dental staining associated with use of tetracyclines. Judicious use of topical corticosteroids may be indicated in patients with corneal disease. Dietary supplementation with omega-3 fatty acids may benefit some patients.

Hammersmith KM. Blepharoconjunctivitis in children. *Curr Opin Ophthalmol*. 2015; 26(4):301–305.

## Ocular Allergy

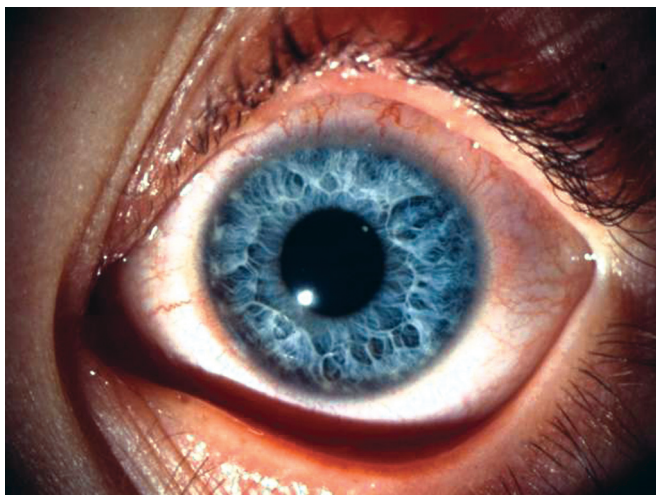Allergies are thought to affect approximately 20% of the US and European populations; more than 50% of patients who seek treatment for allergies present with ocular symptoms. Allergic ocular disease is a common problem in children and is often associated with asthma, allergic rhinitis, and atopic dermatitis. Marked itching and bilateral conjunctival inflammation of a chronic, recurrent, and possibly seasonal nature are hallmarks of external ocular disease of allergic origin. Other signs and symptoms may be nonspecific and include tearing, stinging, burning, and photophobia.

Four specific types of ocular allergy are discussed in this section: seasonal and perennial allergic conjunctivitis, vernal keratoconjunctivitis (VKC), and atopic keratoconjunctivitis (AKC). All have some element of a type I hypersensitivity reaction caused by the interaction between an allergen and specific immunoglobulin E antibodies on the surface of mast cells in the conjunctiva. This interaction initiates a cascade of biochemical events involved in mediation of the allergic response. Among the mediators released is histamine, which causes much of the itching, vasodilation, and edema that are characteristic of the ocular allergic response.

### ***Seasonal and perennial allergic conjunctivitis***

Seasonal allergic conjunctivitis is a common clinical entity that affects approximately 40 million people in the United States, including many children. It occurs in the spring and fall and is triggered by environmental contact with specific airborne allergens such as pollens from grasses, flowers, weeds, and trees. Patients typically present with red and watery eyes, boggy-appearing conjunctiva, and ocular itching (Fig 20-9). Blue-gray to purple discoloration of the lower eyelids, termed *allergic shiners*, can occur secondary to venous stasis from nasal congestion.

The signs, symptoms, and presentation of perennial allergic conjunctivitis are similar to those of seasonal allergic conjunctivitis. Perennial allergic conjunctivitis is a type I



**Figure 20-9** Seasonal allergic conjunctivitis. (Courtesy of Albert W. Biglan, MD.)

hypersensitivity reaction that occurs after contact with ubiquitous household allergens, such as dust mites and dander from domestic pets. This condition is diagnosed based on the history and clinical presentation.

Treatment of all ocular allergy disorders is fundamentally similar to that of other allergy-related disorders. The most effective treatment is to avoid offending allergens or remove them from the patient's environment. Unfortunately, avoidance may not be possible and complete removal may not be adequate to alleviate the patient's symptoms. Medical treatment can be systemic or topical. Although oral antihistamines may be less effective at relieving specific ocular symptoms, they are often better tolerated in children, who may not accept eyedrops.

Topical medications include mast-cell stabilizers, H<sub>1</sub>-receptor antagonists, antihistamines, vasoconstrictors, corticosteroids, or combinations of these drugs (Table 20-2).

---

**Table 20-2 Topical Drops for Treatment of Allergic Ocular Disorders**

---

**Over-the-counter antihistamines/vasoconstrictors**

Naphazoline/antazoline (Vasocon-A)  
Naphazoline/pheniramine (Naphcon-A, Opcon-A, Visine-A)

**Mast-cell stabilizers**

Cromolyn sodium 2% (Opticrom)  
Cromolyn sodium 4% (Crolom)  
Lodoxamide tromethamine 0.1% (Alomide)  
Nedocromil sodium 2% (Alocril)  
Pemirolast potassium 0.1% (Alamast)

**H<sub>1</sub>-receptor antagonist**

Cetirizine 0.24% (Zerviate)  
Emedastine difumarate 0.05% (Emadine)

**Drops with both mast-cell stabilizer and H<sub>1</sub>-antagonist**

Alcaftadine 0.25% (Lastacaft)  
Azelastine hydrochloride 0.05% (Optivar)  
Bepotastine besilate 1.5% (Bepreve)  
Epinastine hydrochloride 0.05% (Elestat) [also H<sub>2</sub> blocker]  
Ketotifen fumarate 0.025% (Alaway, Zaditor)  
Olopatadine hydrochloride 0.1% (Patanol)  
Olopatadine hydrochloride 0.2% (Pataday)  
Olopatadine hydrochloride 0.7% (Pazeo)

**Corticosteroids**

Fluorometholone 0.1% (FML, Fluor-Op)  
Fluorometholone 0.25% (FML Forte)  
Loteprednol etabonate 0.2% (Alrex)  
Loteprednol etabonate 0.5% (Lotemax)  
Medrysone 1% (HMS)  
Prednisolone acetate 0.12% (Pred Mild)  
Prednisolone acetate 1% (Pred Forte, Econopred Plus)  
Rimexolone 1% (Vexol)

**Nonsteroidal anti-inflammatory drug**

Ketorolac tromethamine 0.5% (Acular)

**Anti-inflammatory drug**

Cyclosporine 0.05% (Restasis)

---

H<sub>1</sub>-receptor antagonists can be used on an as-needed basis, but mast-cell stabilizers must be used for a few days before an effect is seen. In addition, mast-cell stabilizers should be used continuously through the allergy season to maximize their effectiveness. Nonsteroidal anti-inflammatory drops should be used with caution; cases of corneal perforation, though rare, have been reported. Topical corticosteroid drops used in pulsed doses can effectively reduce severe allergic ocular symptoms, but patients must be closely monitored for adverse effects, including glaucoma and cataracts.

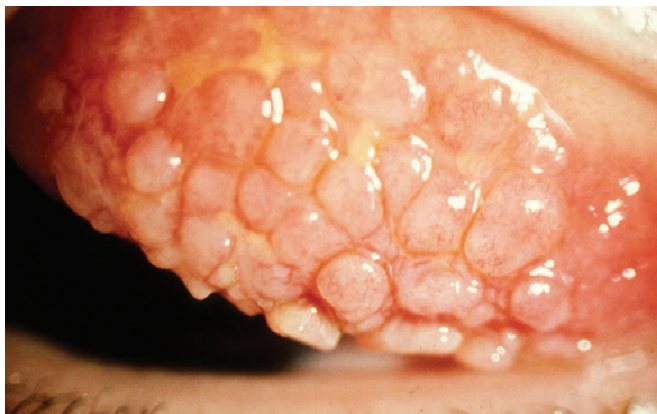
### **Vernal keratoconjunctivitis**

Vernal keratoconjunctivitis (VKC) is caused by type I and type IV hypersensitivity reactions. This condition most commonly affects males in the first 2 decades of life and, like seasonal allergic conjunctivitis, usually occurs in the spring and fall. There are 2 forms of VKC: palpebral and limbal (or bulbar). Both types manifest with severe itching. The limbal form is more common in patients of African or Asian descent and is more prevalent in warm, subtropical climates.

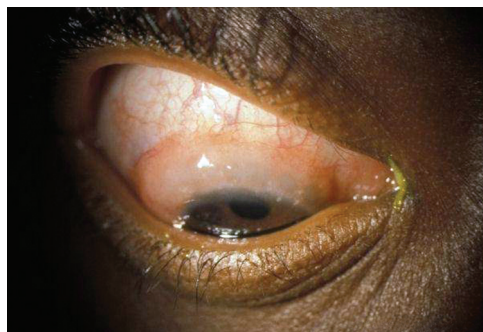Clinically, the palpebral form of VKC preferentially affects the tarsal conjunctiva of the upper eyelid. In the early stages, the eye may be diffusely injected, with little discharge. There may be no progression beyond this stage. However, papillae may multiply, covering the tarsal area with a mosaic of flat papules (Fig 20-10). A thick, ropy, whitish discharge may be present.

The limbal form of VKC manifests early with thickening and opacification of the conjunctiva at the limbus, usually most marked at the upper margin of the cornea. The discrete limbal nodules that appear are gray, jelly-like, elevated lumps with vascular cores. A whitish center filled with eosinophils and epithelioid cells may appear in the raised lesion. This complex is called a *Horner-Trantas dot*. Limbal nodules may increase in number and become confluent (Fig 20-11). They persist as long as the seasonal exacerbation of the disease lasts.

The cornea may become involved, with punctate epithelial erosions, especially superiorly. Corneal involvement may progress to a large, confluent epithelial defect, typically in the upper half of the cornea, called a *shield ulcer*. The ulcer is sterile and clinically resembles an ovoid corneal abrasion (Fig 20-12).



**Figure 20-10** Palpebral vernal keratoconjunctivitis (VKC), upper eyelid. (Courtesy of Ken K. Nischal, MD.)



**Figure 20-11** Limbal VKC with Horner-Trantas dots. (Courtesy of Stephen P. Christiansen, MD.)

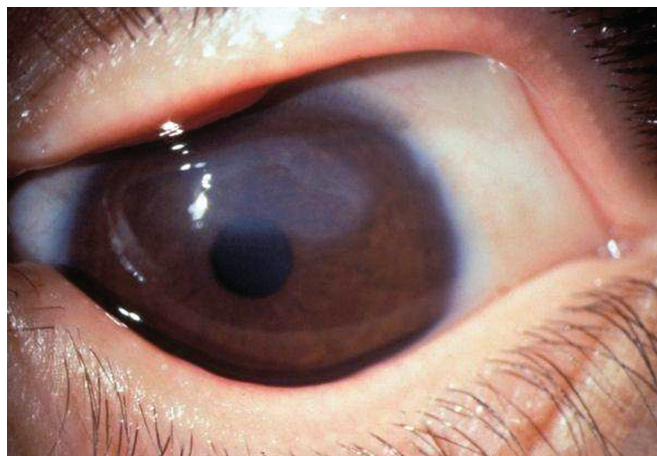
Treatment of VKC is usually less effective than that of seasonal allergic conjunctivitis. Eyedrops combining a mast-cell stabilizer and an H<sub>1</sub>-receptor antagonist may be used initially. In addition, treatment of VKC often requires topical steroids or topical cyclosporine. Supratarsal injection of corticosteroids may be used in patients with refractory palpebral VKC.

### ***Atopic keratoconjunctivitis***

Atopic keratoconjunctivitis is a nonseasonal disorder that occurs in patients with atopic disease. It is relatively rare in children. See BCSC Section 8, *External Disease and Cornea*, for further discussion.

### **Ligneous Conjunctivitis**

Ligneous conjunctivitis is a rare bilateral chronic disorder characterized by firm (“woody”), yellowish, fibrinous pseudomembranes on the palpebral conjunctiva. It is thought to be secondary to severe deficiency in type I plasminogen and can affect persons of all ages. No single treatment is consistently effective. Surgical removal, amniotic membrane transplantation, fresh frozen plasma, and heparin have been used.



**Figure 20-12** VKC with shield ulcer. (Courtesy of Stephen P. Christiansen, MD.)

## Other Conjunctival and Subconjunctival Disorders

---

### Papillomas

Papillomas are benign epithelial proliferations that usually appear as sessile masses at the limbus or as pedunculated lesions of the caruncle, fornix, or palpebral conjunctiva. They may be transparent, pale yellow, or salmon colored and are sometimes speckled with red dots. Papillomas in children usually result from viral infection. They often resolve spontaneously. Oral cimetidine can induce papilloma regression. Carbon dioxide laser or surgical incision is indicated when symptoms are severe or if new lesions continue to appear. Seeding may follow excision, leading to recurrence.

### Conjunctival Epithelial Inclusion Cysts

Conjunctival inclusion cysts are clear, fluid-filled cysts on the conjunctiva. These cysts are often noted in patients who had ocular surgery or trauma. Excision is indicated if the cyst causes irritation.

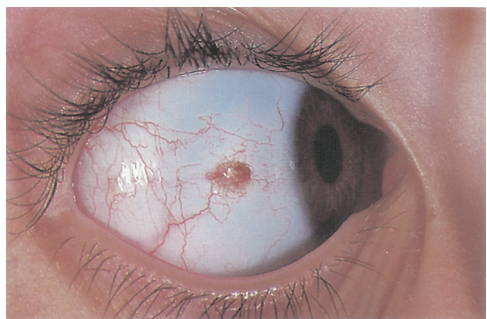### Conjunctival Nevi

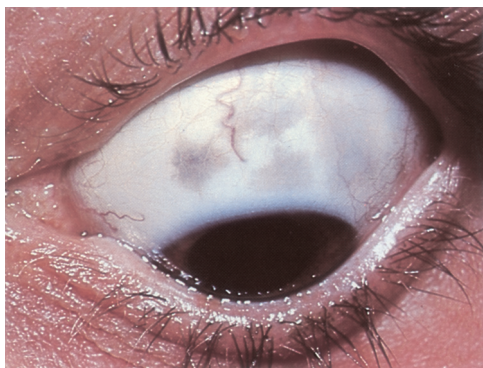
Conjunctival nevi are relatively common in childhood. Nevocellular nevi of the conjunctiva consist of nests or more diffuse infiltrations of benign melanocytes. Histologically, most of these nevi are compound (nevus cells found in both epithelium and substantia propria); others are junctional (nevus cells confined to the interface between epithelium and substantia propria). The lesions are occasionally noted at birth. More commonly, they develop during later childhood or adolescence. The lesions may be flat or elevated. Nevi are typically brown, but approximately one-third are nonpigmented and have a pinkish appearance (Fig 20-13). Removal may be indicated if significant growth occurs, although transformation to malignant melanoma is extremely rare in childhood.

### Ocular Melanocytosis

Ocular melanocytosis (*melanosis oculi*) is a congenital focal proliferation of subepithelial melanocytes characterized by unilateral patchy but extensive slate-gray or bluish discoloration of the episclera (Fig 20-14). Intraocular pigmentation is also increased, which is

**Figure 20-13** Pigmented nevus of the bulbar conjunctiva, right eye.





**Figure 20-14** Ocular melanocytosis.

associated with a higher incidence of glaucoma and risk of malignant melanoma. Some patients, particularly persons of Asian ancestry, may have associated involvement of eyelid and adjacent skin with dermal hyperpigmentation that produces brown, bluish, or black discoloration without thickening (*oculodermal melanocytosis, nevus of Ota*). Small patches of slate-gray scleral pigmentation, typically bilateral and without clinical significance, are common in black and Asian children. Melanosis of skin and sclera is occasionally associated with Sturge-Weber syndrome and Klippel-Trénaunay-Weber syndrome.

### Stevens-Johnson Syndrome and Toxic Epidermal Necrolysis

Stevens-Johnson syndrome (SJS) and toxic epidermal necrolysis (TEN) are rare hypersensitivity reactions that affect skin and mucous membranes. The most common etiologies of SJS and TEN in children are medications (usually anticonvulsants and sulfonamides) and infections (usually *Mycoplasma* species or herpes simplex virus). The pathogenesis of SJS and TEN is discussed in BCSC Section 8, *External Disease and Cornea*.

Systemic manifestations range from mild to severe. A prodrome of fever, malaise, and upper respiratory tract infection is followed by bullous mucosal and skin lesions. These lesions rupture, ulcerate, and become covered by gray-white membranes and a hemorrhagic crust.

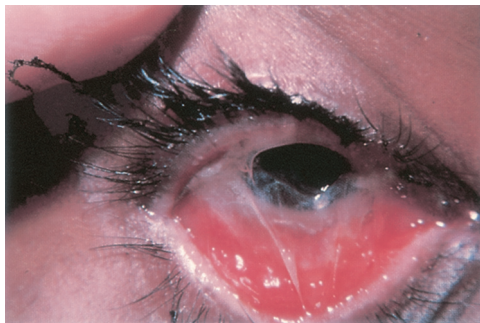
Ocular involvement, which occurs in as many as 50% of patients, varies from mild mucopurulent conjunctivitis to severe perforating corneal ulcers. Ocular involvement in SJS and TEN begins with edema, erythema, and crusting of the eyelids. The palpebral conjunctiva becomes hyperemic, and distinct vesicles or bullae may occur. In many instances, epithelial defects or ulcers involving the tarsus and fornices develop. In severe cases, membranous or pseudomembranous conjunctivitis may occur (Fig 20-15) and lead to symblepharon formation. Superinfection, most commonly with *Staphylococcus* species, may develop.

Late ocular complications, possibly accompanied by a decrease in vision, occur in approximately 27% of pediatric patients. These complications include anomalies of eyelid position (ectropion and entropion), dry eye disease, trichiasis, chronic conjunctivitis, corneal defects, corneal vascularization, and symblepharon formation.

SJS and TEN are considered a disease continuum, distinguished by severity. The current nomenclature is based on the amount of skin involvement, with SJS being of lesser



**Figure 20-15** Stevens-Johnson syndrome. Early, severe involvement of the conjunctiva, right eye.



severity; TEN, greater severity; and SJS-TEN in between these. They are diagnosed based on clinical presentation and skin biopsy results. Initial management includes treatment of any underlying infection and discontinuation of any inciting drug. Systemic therapy with corticosteroids or intravenous immunoglobulin is controversial. The mortality rate for these conditions is much lower in children than in adults: 0% in SJS, 4% in SJS-TEN, and 16% in TEN. A full discussion of systemic treatment is beyond the scope of this book. A dermatologist and a specialist in pediatric infectious diseases should be consulted.

Early intervention is important for preventing the late ocular complications of SJS, SJS-TEN, and TEN. Ocular lubrication with artificial tears and ointments (preferably preservative-free) should be applied frequently. Associated microbial infections should be treated. The fornices may be swept to lyse adhesions, although some ophthalmologists believe that doing so may stimulate inflammation and cause further scarring. In severe cases, a symblepharon ring may be useful in cooperative patients. In patients with significant ocular disease, a corneal bandage device using amniotic membrane or amniotic membrane grafting should be considered early to decrease the risk of late ocular complications.

Hsu DY, Brieva J, Silverberg NB, Paller AS, Silverberg JI. Pediatric Stevens-Johnson syndrome and toxic epidermal necrolysis in the United States. *J Am Acad Dermatol.* 2017;76(5): 811–817.

Jain R, Sharma N, Basu S, et al. Stevens-Johnson syndrome: the role of an ophthalmologist. *Surv Ophthalmol.* 2016;61(4):369–399.

## CHAPTER 21

# Disorders of the Anterior Segment

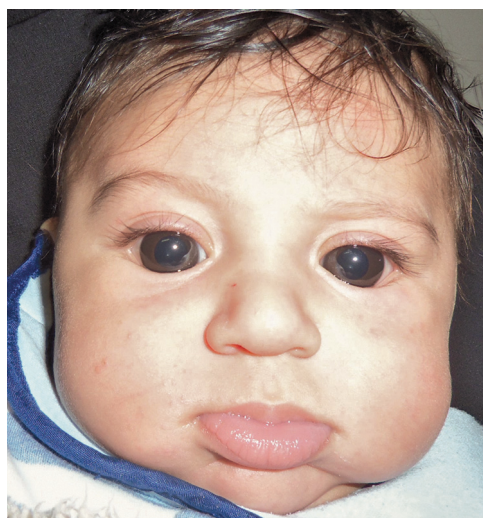Disorders of the anterior segment include a wide spectrum of conditions involving the cornea, iris, anterior chamber angle, and lens. Pediatric glaucoma and lens disorders are discussed in Chapters 22 and 23, respectively. Anatomy of the anterior segment and its development are discussed in BCSC Section 2, *Fundamentals and Principles of Ophthalmology*. See also Section 8, *External Disease and Cornea*, for detailed discussion of some of the disorders covered in this chapter.

### Abnormalities of Corneal Size or Shape

---

#### Megalocornea

*Primary megalocornea* is characterized by bilateral congenitally enlarged corneas, with an increased horizontal corneal diameter and a deep anterior chamber (Fig 21-1); it is often



**Figure 21-1** Megalocornea. The depth of the anterior chamber in this male infant was more than 19% of total axial length, a feature that is useful for distinguishing the anomaly from buphthalmos. (Courtesy of Arif O. Khan, MD.)

associated with iris transillumination. On biometry, the ratio of anterior chamber depth to total axial length is typically 0.19 or greater, a feature that is useful for distinguishing this anomaly from buphthalmos. Late changes include corneal mosaic degeneration (shagreen), arcus juvenilis, presenile cataracts, and glaucoma. The phenotype is often caused by X-linked recessive mutation in *CHRD1*. *Secondary megalocornea* is typically a result of increased intraocular pressure.

Davidson AE, Cheong SS, Hysi PG, et al. Association of *CHRD1* mutations and variants with X-linked megalocornea, Neuhäuser syndrome and central corneal thickness. *PLoS One*. 2014; 9(8):e104163.

### Microcornea

*Microcornea* is characterized by a horizontal corneal diameter of 9 mm or less at birth and less than 10 mm after 2 years of age (Fig 21-2). It is often a component of ocular malformations such as microphthalmia and persistent fetal vasculature and of syndromes such as oculodentodigital, Nance-Horan, and Lenz syndromes.

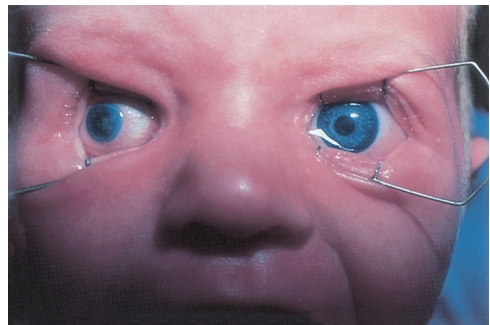### Keratoglobus

*Keratoglobus* is characterized by a steep corneal curvature, peripheral corneal thinning, and a very deep anterior chamber. The phenotype can be due to brittle cornea syndrome, which is the result of biallelic mutations in *ZNF469* or *PRDM5*. Spontaneous breaks in Descemet membrane may produce acute corneal edema. Because the cornea can be ruptured by minor blunt trauma, wearing protective spectacles full time is appropriate.

### Keratoconus

*Keratoconus* is characterized by central or paracentral corneal bulging and progressive thinning. It may present and progress during adolescence and is often familial. Keratoconus is more common in Down syndrome, atopic diseases, Leber congenital amaurosis, and chronic eye rubbing. Iron lines (Fleischer rings), stress lines (Vogt striae), and apical scarring are often noted. Tears in Descemet membrane can occur and cause acute corneal edema (hydrops).

**Figure 21-2** Microcornea, right eye.



## Abnormalities of Peripheral Corneal Transparency

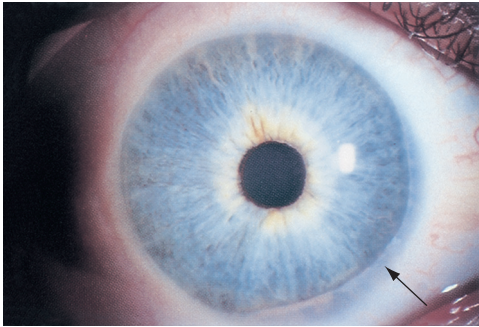
### Posterior Embryotoxon

*Posterior embryotoxon* (*prominent Schwalbe line*) represents a thickening and anterior displacement of the Schwalbe line, causing the anomaly to be seen as an irregular white line just concentric with and anterior to the limbus (Fig 21-3). It is a common isolated finding (occurring in 15% of healthy patients) but is often seen in Axenfeld-Rieger syndrome, arteriohepatic dysplasia (Alagille syndrome), and velocardiofacial syndrome (22q11 deletion syndrome).

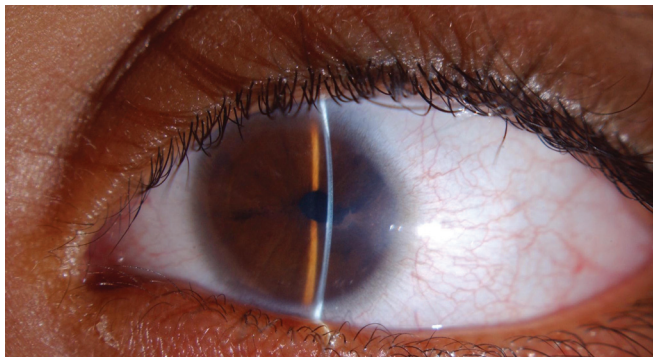
### Cornea Plana

*Cornea plana* is a pathognomonic phenotype of flat cornea, indistinct limbus, shallow anterior chamber, hyperopia, and associated accommodative esotropia (Fig 21-4); it is specific for biallelic *KERA* mutations. Refractive correction and monitoring for glaucoma, which may develop later in life, are the mainstays of treatment.

Khan AO, Aldahmesh M, Meyer B. Recessive cornea plana in the Kingdom of Saudi Arabia. *Ophthalmology*. 2006;113(10):1773–1778.



**Figure 21-3** Posterior embryotoxon (*arrow*) in Axenfeld-Rieger syndrome.



**Figure 21-4** An extremely flat cornea is apparent in this child with cornea plana. Also note the indistinct limbus and irregular pupil. (Reproduced with permission from Khan AO. *Ocular genetic disease in the Middle East*. *Curr Opin Ophthalmol*. 2013;24(5):369–378.)

### Epibulbar Dermoid

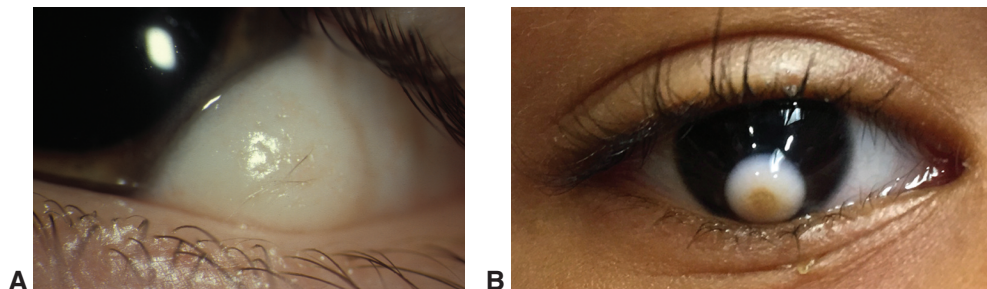An *epibulbar (limbal) dermoid* is a choristoma composed of fibrofatty tissue covered by keratinized epithelium; it may contain hair follicles, sebaceous glands, or sweat glands. The dermoid often straddles the limbus (typically inferotemporally) or, less frequently, resides more centrally in the cornea. It is typically less than 10 mm in diameter, with minimal postnatal growth. The dermoid may extend into the corneal stroma and adjacent sclera but seldom encompasses the full thickness (Fig 21-5). Often, a lipid infiltration of the corneal stroma is noted at the leading edge. Sometimes the lesion is continuous with epibulbar dermolipomas that involve the lateral quadrant of the eye.

Epibulbar dermoids may be seen in Goldenhar syndrome (see also Chapter 18). Patients with Goldenhar syndrome may have one or more of a variety of anomalies, including ear deformities or periauricular tags, maxillary or mandibular hypoplasia, vertebral deformities, eyelid colobomas, or Duane retraction syndrome.

Epibulbar dermoids can produce astigmatism with secondary anisometropic amblyopia. Large epibulbar dermoids can block the visual axis. Surgical excision may be indicated if they cause ocular irritation or amblyopia, but the procedure may result in scarring and astigmatism, which can also lead to amblyopia. Although excision will not eliminate the preexisting astigmatism, surgery may be useful for treating very elevated lesions. Tumor removal involves excising the episcleral portion flush with the plane of surrounding tissue. In general, the surgeon need not remove underlying clear corneal tissue, mobilize surrounding tissue, or apply a patch graft over the resulting surface defect; however, because some lesions extend into the anterior chamber, tissue should be available in the event that a patch graft is required. The cornea and conjunctiva heal within a few days to several weeks, generally with some scarring and imperfect corneal transparency; nevertheless, the appearance can be improved considerably.

### Dermolipoma

A *dermolipoma* is an epibulbar choristoma composed of adipose and dense connective tissue. Often, dermal tissue, including hairs, has replaced a portion of the overlying conjunctiva. Dermolipomas can be extensive, involving orbital tissue, the lacrimal gland, extraocular muscle, or a combination of these. Like limbal dermoids, dermolipomas can be associated with Goldenhar syndrome (see Chapter 18).



**Figure 21-5** **A**, Epibulbar limbal dermoid with hair growing in the center. **B**, Corneal dermoid. (Part A courtesy of Ken K. Nischal, MD; part B courtesy of Robert W. Hered, MD.)

Dermolipomas rarely require excision. If surgery is undertaken, the surgeon should attempt to remove only the portion of the lesion that is visible within the palpebral fissure, disturbing the conjunctiva and the Tenon layer as little as possible to minimize scarring and the risks of strabismus and dry eye. Cicatrization may occur even with a conservative operative approach.

## Abnormalities of Central and Diffuse Corneal Transparency

The mnemonic *STUMPED* refers to sclerocornea, tears in Descemet membrane (usually owing to forceps trauma or congenital glaucoma), ulcers (infection; see Chapter 28), metabolic disorders (eg, mucopolysaccharidosis), Peters anomaly, edema (eg, congenital hereditary endothelial dystrophy [CHED], posterior polymorphous corneal dystrophy [PPCD], congenital hereditary stromal dystrophy [CHSD], glaucoma), and dermoid (Table 21-1).

**Table 21-1 Differential Diagnosis of Infantile Corneal Opacities**

Entity	Location and Description of Opacity	Other Signs	Method of Diagnosis
Sclerocornea (total corneal opacification)	Peripheral opacity, clearest centrally; unilateral or bilateral; often vascularized	Flat cornea	Inspection; anterior segment imaging
Forceps injury	Central opacity; unilateral	Breaks in Descemet membrane	History
Posterior corneal defect	Central opacity; unilateral or bilateral	Iris adherence to cornea; posterior keratoconus	Inspection
Infection	Central or diffuse opacity; unilateral or bilateral	Dendrites, infiltrate, ulceration	Culture, polymerase chain reaction, serologic tests
Mucopolysaccharidosis	Diffuse opacity; bilateral	Smooth epithelium	Biochemical testing
Congenital hereditary stromal dystrophy (CHSD)	Diffuse opacity; bilateral	Stromal opacities; normal thickness; normal epithelium	Examination of family members for autosomal dominance
Congenital hereditary endothelial dystrophy (CHED)	Diffuse opacity; bilateral	Thickened cornea	Inspection
Infantile glaucoma	Diffuse opacity; unilateral or bilateral	Enlarged cornea; breaks in Descemet membrane	Tonometry for elevated intraocular pressure
Dermoid	Inferotemporal opacity; unilateral; elevated; surface hair; keratinized; usually limbal	Associated with Goldenhar syndrome	Inspection

**Table 21-2 Primary and Secondary Corneal Opacities: An Alternative Classification****Primary**

Corneal dystrophies (eg, CHED, PPCD, CHSD)  
Corneal dermoid

**Secondary**

Posterior corneal depression  
Kerato-irido-lenticular dysgenesis (KILD)  
  Iridocorneal adhesions only (Peters anomaly type 1)  
  Failure of lens to separate from cornea (Peters anomaly type 2)  
  Lens separation but failure to form thereafter (sclerocornea)  
  Failure of lens to form (sclerocornea)  
Congenital or infantile glaucoma  
Traumatic breaks in Descemet membrane  
Infection  
Metabolic causes

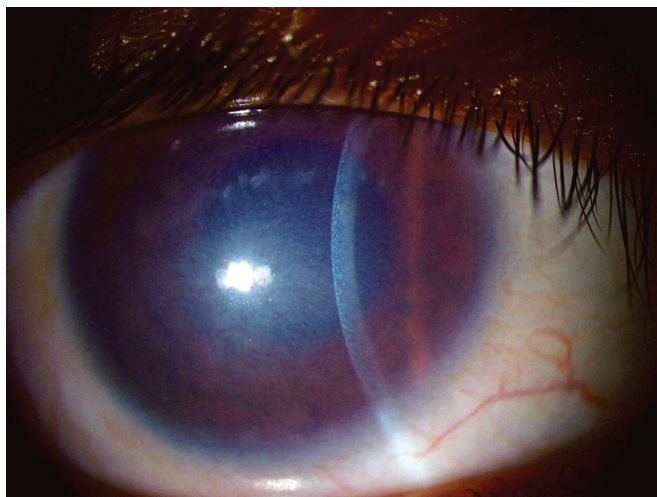CHED= congenital hereditary endothelial dystrophy; CHSD= congenital hereditary stromal dystrophy; PPCD= posterior polymorphous corneal dystrophy.

Adapted with permission from Nischal KK. A new approach to the classification of neonatal corneal opacities. *Curr Opin Ophthalmol.* 2012;23(5):344–354.

Although this mnemonic has been used when the differential diagnosis of corneal opacity in young patients is considered, an alternative and more useful classification of corneal opacities is based on whether they are primary or secondary (Table 21-2).

**Primary Causes*****Congenital hereditary endothelial dystrophy***

In CHED, the cornea is diffusely and uniformly edematous (thick), often with a mosaic haze (Fig 21-6). The phenotype is specific for biallelic *SLC4A11* mutations. On measurement,



**Figure 21-6** Congenital hereditary endothelial dystrophy. Note the diffuse mosaic haze, bluish discoloration, and thickness of the cornea. (Courtesy of Arif O. Khan, MD.)

intraocular pressure is sometimes falsely elevated, which can lead to the misdiagnosis of glaucoma. Deafness presents later in some cases (Harboyan syndrome).

### ***Congenital hereditary stromal dystrophy***

An autosomal dominant condition, CHSD is extremely rare. It is characterized by a smooth, normal epithelium with flaky or feathery clouding of the stroma, which is of normal thickness.

Weiss JS, Møller HU, Aldave AJ, et al. IC3D classification of corneal dystrophies—edition 2. *Cornea*. 2015;34(2):117–159. [Erratum appears in *Cornea*. 2015;34(10):e32.]

## **Secondary Causes**

### ***Posterior corneal depression***

*Posterior corneal depression (central posterior keratoconus; von Hippel internal ulcer)* is a discrete posterior corneal indentation with a normal anterior curvature; it can be considered a variant of Peters anomaly (see the following section). Pigment deposits sometimes are seen on the border of the defect. An abnormal red reflex is noted during examination with a retinoscope or direct ophthalmoscope. If refractive correction is not successful, Descemet stripping endothelial keratoplasty (DSEK) can be considered.

### ***Peters anomaly***

*Peters anomaly (kerato-irido-lenticular dysgenesis)* is characterized by a posterior corneal defect with an overlying stromal opacity, often accompanied by adherent iris strands (Peters anomaly type 1; Fig 21-7A). A more severe phenotype includes adherence of the lens to the cornea at the site of the central defect (Peters anomaly type 2; Fig 21-7B). The corneal opacity ranges from a dense to mild central leukoma (Fig 21-7C). In severe cases, the central leukoma may be vascularized and protrude above the level of the cornea. In rare cases, a membrane may form posterior to the posterior corneal defect, causing the appearance of a central cyst in an opacified cornea (Fig 21-7D). The stromal opacity may decrease with time in some cases. Lysis of adherent iris strands has been reported to improve corneal clarity in some cases.

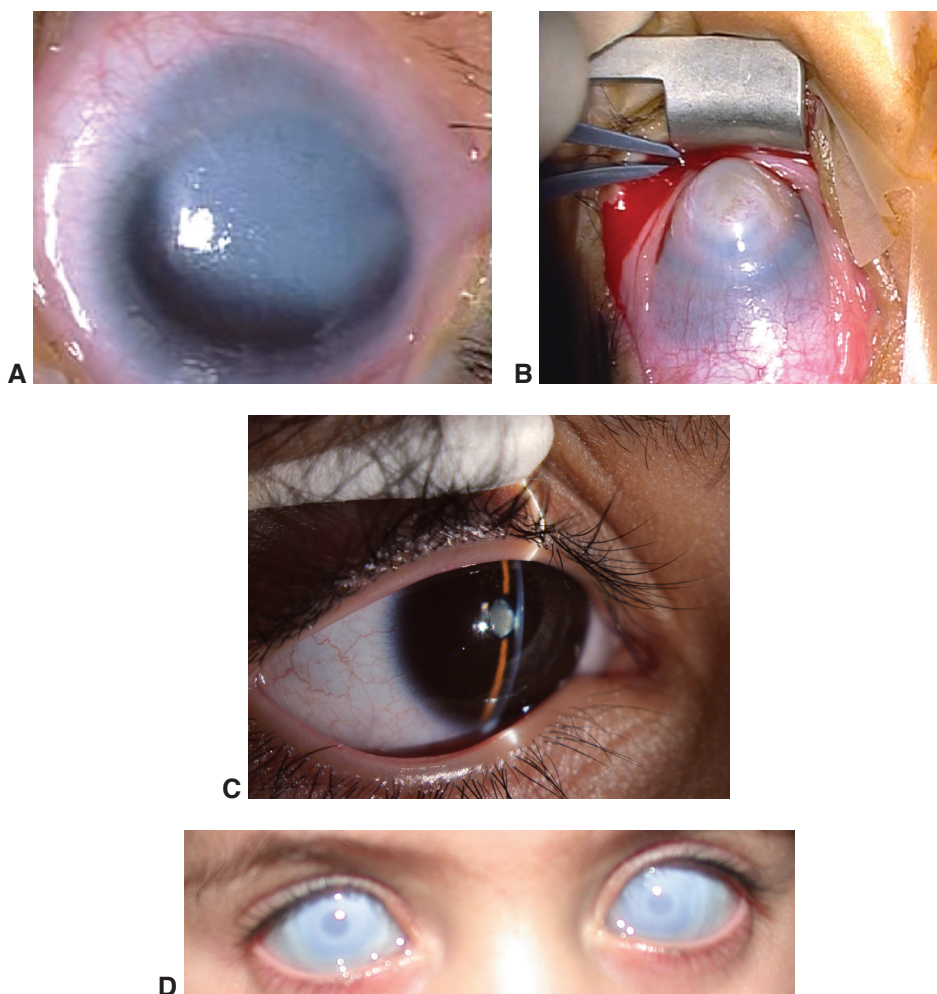
Peters anomaly can arise from a variety of gene mutations (eg, heterozygous *PAX6* mutation, biallelic *CYP1B1* mutations) or from in utero insult (eg, congenital rubella). Unilateral cases are usually isolated. Bilateral cases warrant a complete genetic evaluation. One Peters anomaly syndrome is *Peters-plus syndrome*, which is caused by biallelic *B3GLCT* mutations. Peters-plus syndrome is associated with short stature, a distinct craniofacial appearance, shortened fingers and toes, and intellectual disability. In this syndrome, the stromal opacity may diminish with time.

Bhandari R, Ferri S, Whittaker B, Liu M, Lazzaro DR. Peters anomaly: review of the literature. *Cornea*. 2011;30(8):939–944.

Khan AO, Al-Katan H, Al-Gehedan S, Al-Rashed W. Bilateral congenital stromal cyst of the cornea. *J AAPOS*. 2007;11(4):400–401.

Nischal KK. Genetics of congenital corneal opacification—impact on diagnosis and treatment. *Cornea*. 2015;34(Suppl 10):S24–S34.





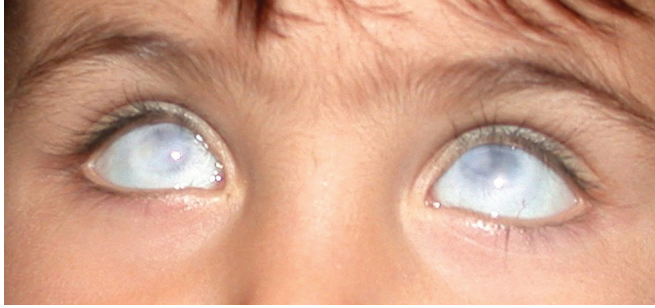**Figure 21-7** **A**, Corneal opacity secondary to iridocorneal adhesion (Peters anomaly type 1). **B**, Corneal opacity secondary to keratolenticular adhesion (Peters anomaly type 2). **C**, A Peters phenotype of central lens opacity with keratolenticular adhesion. **D**, Bilateral posterior corneal defect with a thin posterior membrane, causing the appearance of a central cyst in an opacified cornea. (Parts A and B courtesy of Ken K. Nischal, MD; parts C and D courtesy of Arif O. Khan, MD.)

### **Sclerocornea**

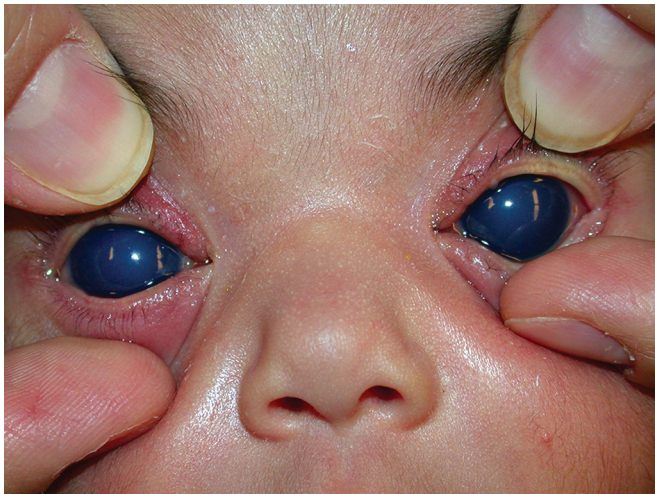*Sclerocornea* (total corneal opacification) is a descriptive term for a congenitally opaque cornea resembling sclera (Fig 21-8). As it is a vague term that does not suggest causation, its use should be avoided.

### **Congenital or infantile glaucoma**

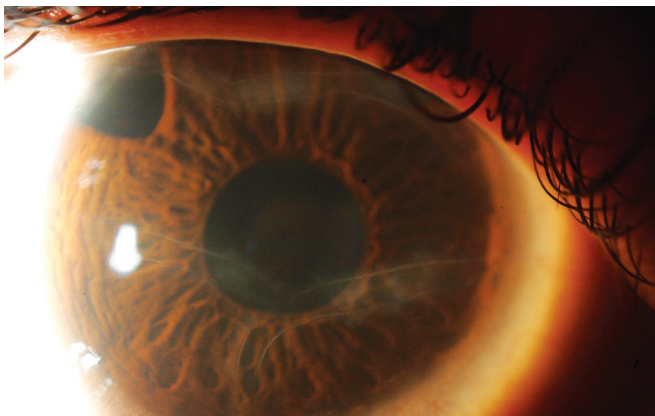Glaucoma in young children can cause the cornea to become edematous, cloudy, and enlarged. Breaks in Descemet membrane from glaucomatous enlargement are termed *Haab striae* (Figs 21-9, 21-10). See Chapter 22 for further discussion.



**Figure 21-8** Bilateral sclerocornea. (Courtesy of Arif O. Khan, MD.)



**Figure 21-9** Primary congenital glaucoma. (Reproduced with permission from Khan AO. *Genetics of primary glaucoma*. *Curr Opin Ophthalmol*. 2011;22(5):347–355.)



**Figure 21-10** Haab striae in an eye that underwent peripheral iridectomy related to prior glaucoma surgery. (Courtesy of Arif O. Khan, MD.)

**Traumatic breaks in Descemet membrane**

Traumatic breaks in Descemet membrane can be caused by forceps trauma during delivery. Other signs of trauma are frequently apparent on the child's head. Traumatic breaks are usually vertical and linear, unlike the curvilinear and often horizontal Haab striae of congenital glaucoma. Acute rupture leads to stromal and sometimes epithelial edema. Acute stromal and epithelial edema regresses, but the edges of the broken Descemet membrane persist and can be seen as ridges protruding slightly from the posterior corneal surface. Amblyopia may result from prolonged corneal opacity or, more commonly, from induced anisometric astigmatism. In patients with brittle cornea syndrome, a disorder of corneal fragility caused by biallelic mutations in *ZNF469* or *PRDM5*, minor trauma can cause traumatic breaks in Descemet membrane (Fig 21-11).


Khan AO. Conditions that can be mistaken as early childhood glaucoma. *Ophthalmic Genet.* 2011;32(3):129-137.

**Corneal ulcers**

Congenital corneal ulcers are rare and may be caused by herpes simplex keratitis or other infection (see Chapter 28).

**Treatment of Corneal Opacities**

If bilateral dense opacities are present, early keratoplasty can be considered for 1 eye so that deprivation amblyopia can be minimized. Coexistent anterior segment disease must be considered before keratoplasty is undertaken. If the opacity is unilateral, the decision is more difficult. Keratoplasty should be undertaken only if the family and the ophthalmologists involved in the child's care are prepared for the significant commitment of time and effort needed to deal with corneal graft rejection, which occurs often in children, as well as with amblyopia. The team should include ophthalmologists skilled in pediatric corneal surgery, pediatric glaucoma, and amblyopia. Contact lens expertise is important for the



**Figure 21-11** Descemet tears from minor trauma in a child with brittle cornea syndrome. (Courtesy of Arif O. Khan, MD.)

care of infants with small eyes and large refractive errors. Repeated examinations under anesthesia are often required.

In addition to traditional penetrating keratoplasty, treatment options include optical iridectomy, deep anterior lamellar keratoplasty (DALK; used for stromal disease with healthy endothelium), DSEK (used to replace diseased endothelium or Descemet membrane), and keratoprostheses.

Ashar JN, Ramappa M, Vaddavalli PK. Paired-eye comparison of Descemet's stripping endothelial keratoplasty and penetrating keratoplasty in children with congenital hereditary endothelial dystrophy. *Br J Ophthalmol*. 2013;97(10):1247–1249.

Harding SA, Nischal KK, Upponi-Patil A, Fowler DJ. Indications and outcomes of deep anterior lamellar keratoplasty in children. *Ophthalmology*. 2010;117(11):2191–2195.

## Congenital and Developmental Anomalies of the Globe

---

### **Microphthalmia, Anophthalmia, and Coloboma**

Microphthalmia, anophthalmia, and coloboma (MAC) is a spectrum that may be isolated or syndromic. It has been associated with mutations in numerous genes, including *CHX10*, *MAF*, *PAX6*, *PAX2*, *RAX*, *SHH*, *SIX3*, and *SOX2*.

#### **Microphthalmia**

*Microphthalmia* is a small, disorganized globe that can be associated with cystic outpouching of the posteroinferior sclera.

#### **Anophthalmia**

*Anophthalmia* is absence of any ocular globe tissue (see Chapter 18). It is very rare; usually, when anophthalmia is clinically suspected, the child actually has severe microphthalmia.

#### **Coloboma**

*Coloboma* is the most common and least severe manifestation of the MAC spectrum. It is typically an inferonasal gap in the iris or retina. Coloboma results from failure of the embryonic fissure to close in the fifth week of gestation.

### **Nanophthalmos**

*Nanophthalmos* is a small eye, typically with an axial length of 18 mm or less and with associated high hyperopia. The cornea is abnormally steep in the recessive form, distinguishing it from ordinary hyperopia. The lens-to-eye ratio is high, with a shallow anterior chamber and risk for angle-closure glaucoma. Another distinguishing feature is a characteristic papillomacular fold. The phenotype can result from biallelic mutations in *PRSS56* or *MFRP* or from heterozygous mutations in *TMEM98*. When the anterior segment is of grossly normal depth, the phenotype is termed *posterior microphthalmos*.

Nowilaty SR, Khan AO, Aldahmesh MA, Tabbara KF, Al-Amri A, Alkuraya FS. Biometric and molecular characterization of clinically diagnosed posterior microphthalmos. *Am J Ophthalmol*. 2013;155(2):361–372.e7.

## Congenital and Developmental Anomalies of the Iris or Pupil

### Abnormalities of the Iris

#### **Persistent pupillary membrane**

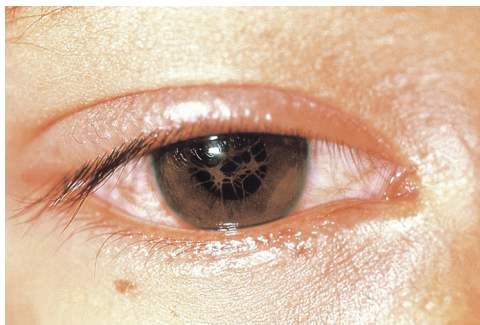
*Persistent pupillary membrane* (Fig 21-12) is the most common developmental abnormality of the iris; it can be seen in approximately 95% of newborns. Remnants are common in older children and adults. Persistent pupillary membranes are rarely visually significant. If especially prominent, they can adhere to the anterior lens capsule, causing a small anterior polar cataract. They may be associated with other anterior segment abnormalities.

#### **Iris hypoplasia**

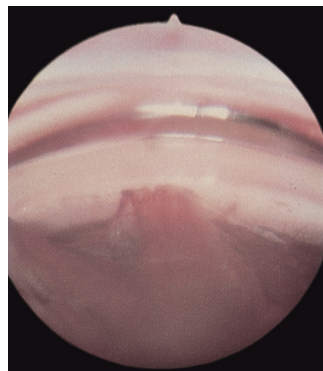
*Iris hypoplasia* refers to an underdeveloped iris stroma. It may be focal (iris coloboma) or diffuse (aniridia). If only the posterior pigment epithelium is underdeveloped, iris transillumination occurs.

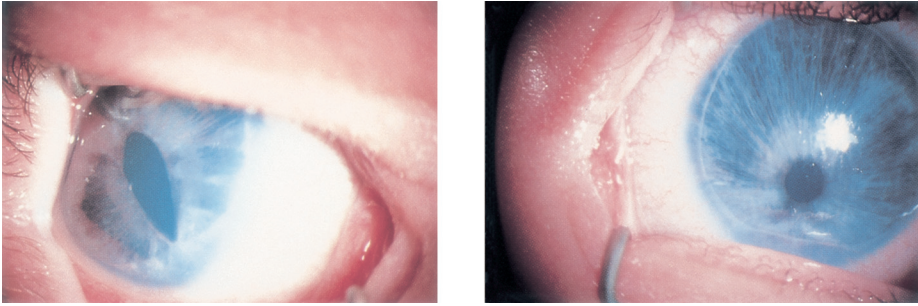
**Axenfeld-Rieger syndrome** *Axenfeld-Rieger syndrome (ARS)* is the commonest cause of iris (stromal) hypoplasia. Characteristic findings include posterior embryotoxon with attached iris strands and iris hypoplasia. These patients have a 50% lifetime risk of glaucoma (Figs 21-13, 21-14, 21-15). ARS is a spectrum that shows phenotypic and genetic

**Figure 21-12** Persistent pupillary membrane. Uncorrected visual acuity was 20/40.

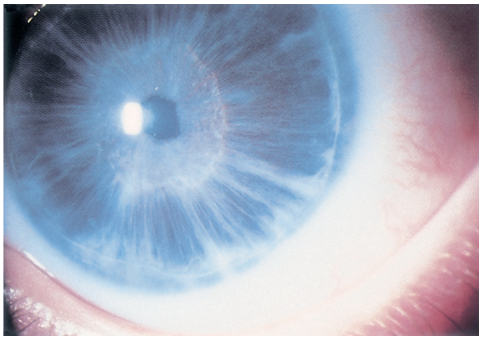


**Figure 21-13** Gonioscopic view in Axenfeld-Rieger syndrome.





**Figure 21-14** Axenfeld-Rieger syndrome, bilateral.



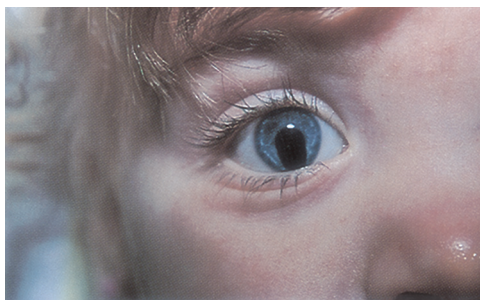**Figure 21-15** Axenfeld-Rieger syndrome. Note variation compared with Figures 21-13 and 21-14. (Courtesy of Jane D. Kivlin, MD.)

heterogeneity. Conditions previously considered distinct—such as Axenfeld anomaly, Rieger anomaly or syndrome, iridogoniodysgenesis anomaly or syndrome, iris hypoplasia, and familial glaucoma iridogoniodysplasia—are now recognized as part of the spectrum of ARS.

The features of ARS range from a smooth, cryptless iris surface to a phenotype that mimics aniridia. Examples include mild stromal thinning, marked atrophy with hole formation, corectopia, and ectropion uveae. Posterior embryotoxon, megalocornea (secondary to glaucoma), or microcornea may occur. Associated nonocular abnormalities include abnormal teeth, distinct facies, redundant periumbilical skin, hypospadias, cardiac valve abnormalities, and pituitary abnormalities. Heterozygous mutations in *PITX2* or *FOXC1*, homeobox genes that regulate other ocular developmental genes, are the most common identifiable cause.

**Iris transillumination** *Iris transillumination* results from the absence of pigment in the posterior epithelial layers (albinism) or from iris hypoplasia (as part of anterior segment dysgenesis, as in ARS). Iris transillumination has also been reported in Marfan syndrome, Prader-Willi syndrome, ectopia lentis et pupillae, X-linked megalocornea, and microcoria. Patchy areas of transillumination can also be seen after trauma, surgery, or uveitis. Scattered iris transillumination defects may be a normal variant in individuals with very lightly pigmented irides.

**Figure 21-16** Typical iris coloboma, right eye.

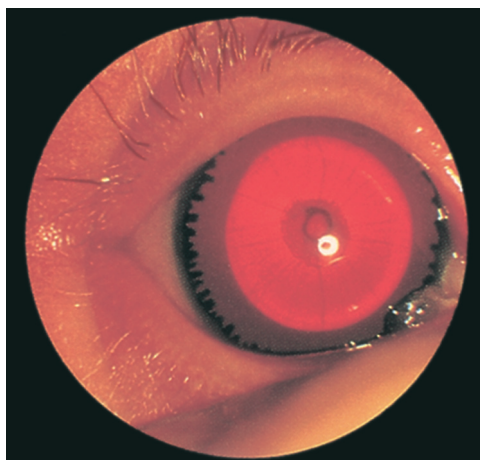


**Coloboma of the iris** With a typical inferonasal iris coloboma, the pupil is shaped like a lightbulb, keyhole, or inverted teardrop (Fig 21-16). Typical colobomas may also involve the lens, ciliary body, choroid, retina, or optic nerve and are part of the MAC spectrum (discussed previously in this chapter). Parents of an affected child may have small, previously undetected chorioretinal or iris defects in an inferonasal location; thus, careful examination of family members is indicated.

Atypical iris colobomas occur in areas other than the inferonasal quadrant and are not usually associated with posterior uveal colobomas. These colobomas probably result from fibrovascular remnants of the anterior hyaloid system and pupillary membrane.

**Aniridia** Classic *aniridia* is a panocular bilateral disorder. The term is a misnomer, however, because at least a rudimentary iris is always present. The degree of iris formation ranges from almost total absence to only mild hypoplasia, overlapping with ARS. The typical presentation is an infant with nystagmus who appears to have absent irides or dilated, unresponsive pupils. Examination findings commonly include small anterior polar lens opacities, at times with attached strands of persistent pupillary membranes (Fig 21-17). Foveal hypoplasia is usually present, with visual acuity often less than 20/100.

**Figure 21-17** Aniridia in an infant. Both the ciliary processes and the edge of the lens are visible. Also present are persistent pupillary membrane fibers and a small central anterior polar cataract.



Glaucoma, typically juvenile, and optic nerve hypoplasia are common. Corneal opacification often develops later in childhood and may lead to progressive deterioration of visual acuity. The corneal abnormality is due to a stem cell deficiency; therefore, keratolimbal allograft stem cell transplantation may be a more effective treatment than corneal transplantation.

Heterozygous *PAX6* gene mutations (11p13) cause classic aniridia, particularly non-sense mutations (haploinsufficiency). Missense mutations are more likely associated with variable expressivity and partial phenotypes. Most (approximately two-thirds) aniridic children have the familial form. The *PAX6* gene is a homeotic eye morphogenesis control gene involved in complex interactions between the optic cup, surface ectoderm, and neural crest during formation of the iris and other ocular structures.

Approximately one-third of aniridia cases result from new deletions that, if large enough, can also affect the contiguous *WT1* gene (a contiguous gene syndrome); such patients are therefore at risk for Wilms tumor (nephroblastoma) before 5 years of age. This phenotype is part of the WAGR syndrome (Wilms tumor, aniridia, genitourinary malformations, and mental retardation). All children with sporadic aniridia should undergo chromosomal deletion analysis of 11p13 to exclude increased Wilms tumor risk. Familial aniridia does not carry a significant risk, although there have been rare reports of Wilms tumor associated with familial aniridia.

### ***Congenital iris ectropion***

Ectropion of the posterior pigment epithelium onto the anterior surface of the iris is sometimes termed *ectropion uveae*, but this is a misnomer because posterior iris epithelium is derived from neural ectoderm and is not considered part of the uvea. Congenital iris ectropion can occur as an acquired tractional abnormality, often associated with rubeosis iridis, or as a congenital nonprogressive abnormality, which can be associated with later glaucoma. It may occur in patients with neurofibromatosis, facial hemihypertrophy, or Prader-Willi syndrome. *Congenital iris ectropion syndrome* is a constellation of unilateral congenital iris ectropion, a glassy-smooth cryptless iris surface, a high iris insertion, dysgenesis of the drainage angle, and glaucoma risk, often with ptosis.

## **Abnormalities in the Size, Shape, or Location of the Pupil**

### ***Dyscoria***

*Dyscoria* is an abnormal pupil shape, typically resulting from congenital malformation such as ARS (see Fig 21-14).

### ***Congenital miosis***

*Congenital miosis (microcoria)* may represent an absence or malformation of the dilator pupillae muscle. It can also occur secondary to contracture of fibrous material on the pupil margin owing to remnants of the tunica vasculosa lentis or neural crest cell anomalies. The pupil rarely exceeds 2 mm in diameter, is often eccentric, and reacts poorly to mydriatic drops. Severe cases require surgical pupilloplasty. *Ectopia lentis et pupillae* refers to



eccentric microcoria with lens subluxation, often from biallelic *ADAMTSL4* mutations (also see the section “Corectopia”).

### ***Congenital mydriasis***

Many cases of *congenital mydriasis (iridoplegia)* fall within the aniridia spectrum, especially if the central iris structures from the collarette to the pupillary sphincter are absent. Congenital cardiovascular defects may be associated with congenital mydriasis in patients with heterozygous *ACTA2* mutation, which sometimes causes an alternate phenotype of prominent iris flocculi rather than iridoplegia. Other causes include iris sphincter trauma, pharmacologic mydriasis, and acquired neurologic disease that affects parasympathetic innervation.

Milewicz DM, Østergaard JR, Ala-Kokko LM, et al. De novo *ACTA2* mutation causes a novel syndrome of multisystemic smooth muscle dysfunction. *Am J Med Genet A*. 2010;152A(10):2437–2443.

### ***Corectopia***

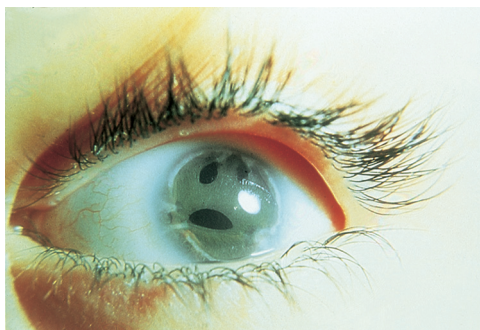
Normally, the pupil is located approximately 0.5 mm inferonasally from the center of the iris. Minor deviations of up to 1.0 mm are usually cosmetically insignificant and are not considered abnormal; displacement greater than this is considered *corectopia*. Sector iris hypoplasia or other colobomatous lesions can lead to corectopia. Vision can be good.

Isolated noncolobomatous, autosomal dominant corectopia has been reported. Progressive corectopia can be associated with ARS or, in adults, with iridocorneal endothelial (ICE) syndrome.

*Ectopia lentis et pupillae* is corectopia associated with lens subluxation. It is often due to biallelic *ADAMTSL4* mutations. The pupils and lenses are displaced in opposite directions. The pupils may be very small and misshapen; they often dilate poorly (see Chapter 23).

### ***Polycoria and pseudopolycoria***

True *polycoria* (in which each pupil has a sphincter mechanism) is very rare. Most accessory iris openings are *pseudopolycoria*. These iris holes may be congenital or may develop in response to progressive corectopia and iris hypoplasia in ARS (Fig 21-18) or, in adults, in ICE syndrome. Pseudopolycoria can also result from trauma, surgery, or persistent pupillary membranes.



**Figure 21-18** Pseudopolycoria secondary to Axenfeld-Rieger syndrome. (Courtesy of John W. Simon, MD.)

## Acquired Corneal Conditions

---

### Keratitis

Keratitis may be epithelial, stromal, peripheral, or, in rare cases, endothelial.

#### **Infectious causes**

**Congenital syphilis** Interstitial keratitis may occur in the first decade of life secondary to congenital syphilis (discussed in Chapter 28). The keratitis presents as a rapidly progressive corneal edema followed by abnormal vascularization in the deep stroma adjacent to Descemet membrane. Intense vascularization may give the cornea a salmon-pink color—hence the term *salmon patch*. Blood flow through these vessels gradually ceases over several weeks to several months, leaving empty “ghost” vessels in the corneal stroma. Immune-mediated uveitis, arthritis, and hearing loss may also develop and may recur even after treatment of syphilis. Immunosuppression may be necessary to diminish sequelae.

**Herpes simplex infection** Eye involvement in congenital herpes simplex virus (HSV) infection can include conjunctivitis, keratitis, retinochoroiditis, and cataracts. Congenital HSV infection is discussed in Chapter 28.

**Adenovirus infection** Punctate epithelial keratitis is most often seen after adenoviral infection; it is due to subepithelial immune complex deposition. See BCSC Section 8, *External Disease and Cornea*, for further discussion.

#### **Noninfectious causes**

Punctate epithelial erosions are most commonly seen in patients with lagophthalmos or dry eye disease. Peripheral (marginal) keratitis is usually associated with blepharokeratoconjunctivitis secondary to meibomian gland disease.

**Thygeson superficial punctate keratitis** The etiology of *Thygeson superficial punctate keratitis* is unclear, but it is thought to be immune-mediated. It can occur in children and presents with tearing, photophobia, and reduced vision. The condition is bilateral but often asymmetric. Characteristic features include slightly elevated gray corneal epithelial lesions with negative staining. It is treated with mild corticosteroids (eg, fluorometholone 0.1%) or topical cyclosporine 0.05%.

**Cogan syndrome** This syndrome is a rare vasculitis that presents with ocular, audiovestibular, and systemic features. Interstitial keratitis, uveitis, conjunctivitis, episcleritis, or a combination of these features may be seen.

## Systemic Diseases Affecting the Cornea or Iris

---

### Metabolic Disorders Affecting the Cornea or Iris

See also Chapter 28, Ocular Manifestations of Systemic Disease, and Table 28-2.

**Mucopolysaccharidosis**

The mucopolysaccharidoses (MPSs) are a group of lysosomal storage diseases. Ocular manifestations can include corneal haze from incompletely degraded glycosaminoglycan. Corneal haze may be present in early life in MPS IH (Hurler syndrome), MPS IS (Scheie syndrome), and MPS IV (Morquio syndrome). Treatment options for significant opacities include penetrating keratoplasty and DALK. Enzyme replacement therapy is available for certain forms of these lysosomal storage diseases. See BCSC Section 8, *External Disease and Cornea*, for further discussion.

**Cystinosis**

*Cystinosis* is caused by biallelic *CTNS* mutations. The infantile form includes failure to thrive, rickets, and progressive renal failure, resulting in Fanconi syndrome.

Iridescent, elongated corneal crystals appear at approximately age 1 year, first in the peripheral cornea and the anterior stroma. Crystals also present in the uvea and on the surface of the iris. Corneal crystals result in severe photophobia. There are reports of angle-closure glaucoma secondary to crystal deposition in the ciliary body.

Oral cysteamine alleviates systemic problems but not the corneal crystal deposition. Topical cysteamine can reduce corneal crystal deposition but requires frequent application, may be difficult to obtain, and has an unpleasant odor.

**Tyrosinemia type II**

*Tyrosinemia type II (Richner-Hanhart syndrome)* results from biallelic *TAT* mutations and is associated with photophobia, pseudodendritic ulcers on the cornea, and ulceration on the palms and soles. Systemic problems include liver and kidney dysfunction. Dietary restriction of phenylalanine and tyrosine is the mainstay of treatment.

**Wilson disease**

In *Wilson disease (hepatolenticular degeneration)*, there is excess copper deposition in the liver, kidneys, and basal ganglia of the brain, leading to cirrhosis, renal tubular damage, and a Parkinson-like disorder of motor function. The phenotype results from biallelic *ATP7B* mutations. The characteristic Kayser-Fleischer ring—a golden-brown, ruby-red, or green pigment ring consisting of copper deposits—is limited to Descemet membrane, can be several millimeters in width, and may resolve with treatment. Laboratory tests for serum copper and ceruloplasmin are better than an eye examination for early diagnosis because the ring can develop late.

**Fabry disease**

*Fabry disease* is an X-linked lysosomal storage disease with variable systemic manifestations. It is due to  $\alpha$ -galactosidase deficiency (hemizygous *GLA* mutations). Vortex keratopathy (verticillata) can be seen in affected males and in female carriers.

**Schnyder corneal dystrophy**

*Schnyder corneal dystrophy* is a predominantly local disorder of corneal lipid metabolism arising from biallelic *UBIAD1* mutations. Although crystalline keratopathy is characteristic, stromal haze without crystals is a common presentation.

## Other Systemic Diseases Affecting the Cornea or Iris

### **Familial dysautonomia**

*Familial dysautonomia (Riley-Day syndrome)* is a disorder of autonomic dysfunction characterized by relative insensitivity to pain, temperature instability, and absence of the fungiform papillae of the tongue. The phenotype occurs largely in children of Eastern European Jewish (Ashkenazic) descent and results from biallelic *IKBKAP* mutations. Failure to respond with a wheal and flare to intradermal injection of 1:1000 histamine solution is characteristic. Exposure keratitis and corneal ulcers with secondary opacification are frequent. Treatment includes artificial tears and tarsorrhaphy.

### **Waardenburg syndrome**

*Waardenburg syndrome* is a rare neurocristopathy characterized by Hirschsprung disease; deafness; and depigmentation of hair (a white forelock), skin, and iris. Ophthalmic findings include telecanthus and dystopia canthorum (see Chapter 17).

## Tumors of the Anterior Segment

---

### **Cornea**

Tumors of the cornea are extremely rare in children, but squamous cell carcinomas have been reported in cases of xeroderma pigmentosum.

### **Iris**

#### **Nodules**

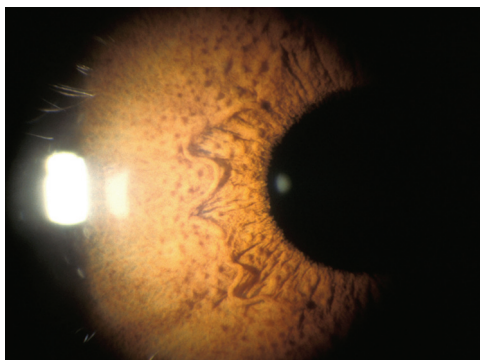
**Lisch nodules** *Lisch nodules* occur in patients with neurofibromatosis and are discussed in Chapter 28.

**Juvenile xanthogranuloma** *Juvenile xanthogranuloma* is a nonneoplastic histiocytic proliferation that develops in infants younger than 2 years. It is characterized by the presence of Touton giant cells. Skin involvement—consisting of one or more small, round, orange or tan papules—is typically but not always present. Iris lesions are relatively rare and virtually always unilateral. The fleshy, yellow-brown masses may be small and localized or may diffusely infiltrate the entire iris, resulting in heterochromia. Spontaneous bleeding with hyphema is a characteristic clinical presentation. Secondary glaucoma may cause acute pain, photophobia, and vision loss. Those at greatest risk for ocular involvement are children with multiple skin lesions.

Juvenile xanthogranuloma is a self-limited condition that usually regresses spontaneously by age 5 years, but to avoid complications, treatment is indicated for ocular involvement. Topical corticosteroids and pharmacologic agents to lower intraocular pressure, given as necessary, are generally sufficient to control the problem. Surgical excision or radiation should be considered if intractable glaucoma is present.

**Iris mammillations** *Iris mammillations* may be unilateral or bilateral. They appear as numerous tiny, diffuse, pigmented nodules on the surface of the iris (Fig 21-19). They are

**Figure 21-19** Iris mammillations. The nodules are diffuse and are the same color as the iris (Lisch nodules, by contrast, are lighter or darker than the surrounding iris). (Courtesy of Arlene Drack, MD.)



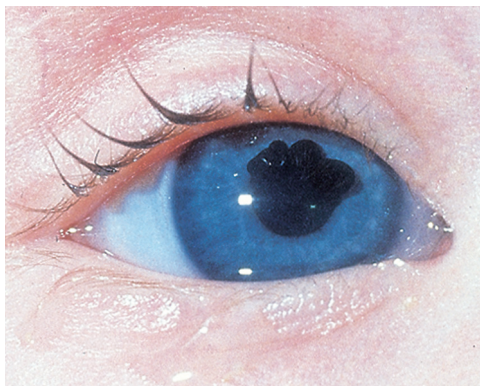
more common in darkly pigmented eyes and are usually the same color as the iris. These nodules may be bilateral, autosomal dominant, and isolated, or they may be associated with oculodermal melanocytosis or phakomatosis pigmentovascularis type IIB (nevus flammeus with persistent, aberrant mongolian spots). Iris mammillations have also been reported in cases of ciliary body tumor and choroidal melanoma. They must be differentiated from Lisch nodules; mammillations are usually dark brown, smooth, uniformly distributed, and equal in size or slightly larger near the pupil. The incidence of iris mammillations is higher among patients with neurofibromatosis type 1.

**Brushfield spots** Focal areas of iris stromal hyperplasia surrounded by relative hypoplasia occur in up to 90% of patients with Down syndrome; in such patients, these areas are known as *Brushfield spots*. They are hypopigmented. Similar lesions, known as *Wolfflin nodules*, occur in up to 24% of healthy individuals. Neither condition is visually significant.

### **Cysts**

**Primary iris cysts** These cysts may originate from the iris pigment epithelium or the iris stroma.

**CYSTS OF IRIS PIGMENT EPITHELIUM** Spontaneous cysts of the iris pigment epithelium result from a separation of the 2 layers of epithelium anywhere between the pupil and ciliary body (Fig 21-20). These cysts tend to be stable and rarely cause ocular complications. They are usually not diagnosed until the teenaged years.



**Figure 21-20** Cysts of the iris pigment epithelium at the pupillary border (flocculi).

**CENTRAL CYSTS** Pigment epithelial cysts at the pupillary border, also termed *iris flocculi*, are sometimes hereditary. In rare cases, they may be from an *ACTA2* mutation (see the section “Congenital mydriasis”). They are usually diagnosed in infancy. The cysts may enlarge slowly but generally remain asymptomatic and rarely require treatment. Cholinesterase-inhibiting eyedrops such as echothiophate may produce similar pupillary cysts, especially in young phakic eyes. Discontinuation of the drug or concomitant administration of phenylephrine generally results in improvement.

**CYSTS OF IRIS STROMA** Primary iris stromal cysts are often diagnosed in infancy. They are most likely caused by sequestration of epithelium during embryologic development. The epithelium-lined stromal cysts usually contain goblet cells, and they may enlarge, causing obstruction of the visual axis, glaucoma, corneal decompensation, or iritis from cyst leakage.

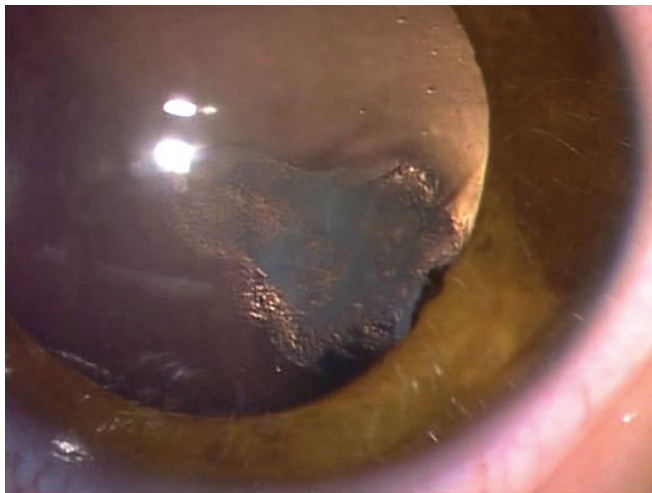
Numerous treatments have been described, including cyst aspiration and photocoagulation or photodisruption, but the sudden release of cystic contents may result in transient iritis and glaucoma. Because of these potential complications and frequent cyst recurrence, surgical excision may be the preferred treatment method. Iris stromal cysts account for approximately 16% of childhood iris cysts. The visual prognosis is guarded.

**Secondary iris cysts** Secondary iris cysts have been reported in childhood after trauma; they are also associated with tumors and iris nevi.

## Ciliary Body

### ***Medulloepithelioma***

A *medulloepithelioma* (*diktyoma*) originates from the nonpigmented epithelium of the ciliary body and most often presents as an iris mass during the first decade of life. Secondary glaucoma, hyphema, and ectopia lentis et pupillae or sectoral cataract (Fig 21-21) are less frequent initial manifestations. This rare lesion shows a spectrum of clinical and



**Figure 21-21** Sectoral cataract adjacent to medulloepithelioma. (Courtesy of Ken K. Nischal, MD.)

pathologic characteristics, ranging from benign to malignant. Although distant metastasis is rare, local invasion can lead to death. Teratoid elements are often present. Enucleation is usually required and is curative in most cases.

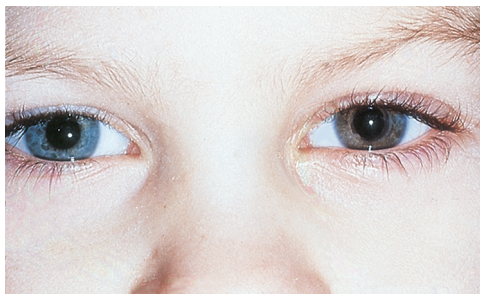## Miscellaneous Clinical Signs

---

### Pediatric Iris Heterochromia

The differential diagnosis of pediatric iris heterochromia is extensive. Causes can be classified based on whether the condition is congenital or acquired and whether the affected eye is hypopigmented or hyperpigmented (Fig 21-22, Table 21-3). Trauma, chronic iridocyclitis, intraocular surgery, and use of topical prostaglandin analogues are important causes of acquired hyperpigmented heterochromia. Whether congenital or acquired, hypopigmented heterochromia that is associated with a more miotic pupil and ptosis on the ipsilateral side should prompt a workup for Horner syndrome.

**Figure 21-22** Iris heterochromia. The left iris has become darker since development of a traumatic cataract. (Courtesy of John W. Simon, MD.)




---

**Table 21-3 Causes of Pediatric Iris Heterochromia**

---

#### Hypochromic heterochromia

- Horner syndrome (congenital or early in life)
- Incontinentia pigmenti (Bloch-Sulzberger syndrome; rare)
- Fuchs heterochromia
- Waardenburg syndrome
- Nonpigmented tumors
- Hypomelanosis of Ito

#### Hyperchromic heterochromia

- Oculodermal melanocytosis (associated with glaucoma in nonwhite adults)
  - Pigmented tumors
  - Siderosis
  - Iris ectropion syndrome
  - Extensive rubeosis
  - Port-wine stain
  - Trauma
  - Chronic iridocyclitis
  - Intraocular surgery
  - Topical prostaglandin analogues
-

## **Anisocoria**

Inequality in the diameters of the 2 pupils is called *anisocoria*. For a detailed discussion of anisocoria and the following conditions, see BCSC Section 5, *Neuro-Ophthalmology*.

### ***Physiologic anisocoria***

Physiologic anisocoria is a common cause of a difference in size between the 2 pupils. This difference is usually less than 1 mm and can vary from day to day in an individual. The inequality does not change significantly when the patient is in dim light or bright light.

### ***Tonic pupil***

Features of a tonic pupil include anisocoria that is greater in bright light and a pupil that is sluggishly and segmentally responsive to light and more responsive to near effort. Greater-than-normal constriction in response to dilute pilocarpine is diagnostic. Possible etiologic causes in children include varicella-zoster virus infection and Adie syndrome with absence of deep tendon reflexes.

### ***Horner syndrome***

A lesion at any location along the oculosympathetic pathway may lead to *Horner syndrome*. Affected patients have anisocoria that is greater in dim light and ptosis secondary to paralysis of the Müller muscle. Congenital cases may be associated with iris heterochromia in which the affected iris is lighter in color. However, the heterochromia may not be present in infants because the normal iris needs time to acquire pigment.


The diagnosis of Horner syndrome can be confirmed with the use of topical cocaine or apraclonidine drops. Apraclonidine reverses the anisocoria, causing dilation of the affected (smaller) pupil and having no effect on the normal pupil. This agent should be used with caution in young children, as it may cause excessive sedation owing to its central nervous system effects. Additional pharmacologic testing may not be necessary in the presence of typical clinical findings.

Horner syndrome in children may be idiopathic or may be caused by trauma, surgery, or the presence of neuroblastoma affecting the sympathetic chain in the chest. For children with acquired Horner syndrome but no history of trauma or surgery that could explain the anisocoria, evaluation should include imaging studies of the brain, neck, and chest. The value of measuring catecholamine excretion has been questioned because some patients with normal catecholamine measurements have been found to have neuroblastomas.





# Pediatric Glaucomas

 This chapter includes related videos, which can be accessed by scanning the QR codes provided in the text or going to [www.aao.org/bcscvideo\\_section06](http://www.aao.org/bcscvideo_section06).

Pediatric glaucomas are a heterogeneous group of diseases that may result from an isolated congenital abnormality of the aqueous outflow pathways (primary glaucoma) or from abnormalities affecting other regions of the eye (secondary glaucoma). A variety of systemic conditions are associated with pediatric glaucoma. See BCSC Section 10, *Glaucoma*, for additional discussion of topics covered in this chapter.

## Classification

---

In 2013, an international classification system for childhood glaucoma was established by the Childhood Glaucoma Research Network and the World Glaucoma Association. In the classification system, *childhood glaucoma* is defined as intraocular pressure (IOP)-related damage to the eye as opposed to IOP-related damage to the optic nerve, which defines adult glaucoma. This classification is summarized in Table 22-1, and an algorithm for classifying a patient with childhood glaucoma using these criteria is presented in Figure 22-1.

Beck AD, Chang TCP, Freedman SF. Definition, classification, differential diagnosis. In: Weinreb RN, Grajewski AL, Papadopoulos M, Grigg J, Freedman S, eds. *Childhood Glaucoma*. Amsterdam: Kugler Publications; 2013:3–10. *World Glaucoma Association Consensus Series—9*.

## Genetics

---

Although primary congenital glaucoma (PCG) usually occurs sporadically, it may be inherited as an autosomal recessive trait. When no other family history of PCG exists, the chance of an affected parent having a child with PCG is approximately 2%. Four chromosomal loci for PCG have been identified: GLC3A on band 2p21, GLC3B on 1p36, GLC3C on 14q24.3, and GLC3D on 14q24.3. Mutations in *CYP1B1* (at the GLC3A locus) have been shown to cause PCG. Populations in which consanguinity is common, especially those in which the carrier rate of the *CYP1B1* gene is high, have higher incidences of PCG. Individuals who carry the *CYP1B1* gene but who are nonpenetrant for PCG remain at higher risk for adult-onset glaucoma. *LTBP2* mutations (at the GLC3D locus) cause a primary megalocornea with zonular weakness, forward displacement of the lens, and a

**Table 22-1 Classification of Childhood Glaucoma****Primary childhood glaucoma**

- Primary congenital glaucoma (PCG)
  - Neonatal or newborn onset (age 0–1 month)
  - Infantile onset (age 1–24 months)
  - Late-onset or late-recognized (age  $\geq$ 24 months)
- Juvenile open-angle glaucoma (JOAG)

**Secondary childhood glaucoma**

- Glaucoma associated with nonacquired ocular anomalies
- Glaucoma associated with nonacquired systemic disease or syndrome
- Glaucoma associated with acquired condition
- Glaucoma following cataract surgery

Information from Beck AD, Chang TCP, Freedman SF. Definition, classification, differential diagnosis. In: Weinreb RN, Grajewski AL, Papadopoulos M, Grigg J, Freedman S, eds. *Childhood Glaucoma*. Amsterdam: Kugler Publications; 2013:3–10. *World Glaucoma Association Consensus Series—9*.

secondary glaucoma that responds poorly to standard angle surgery. In this condition, the preferred treatment is lens removal.

Juvenile open-angle glaucoma is inherited as an autosomal dominant trait and has been linked to the GLC1A myocilin gene (*MYOC*), which is also responsible for some forms of adult open-angle glaucoma.

The genetic causes of many conditions associated with secondary childhood glaucoma have been identified; they are discussed in the chapters associated with their primary conditions.

Khan AO, Aldahmesh MA, Alkuraya FS. Congenital megalocornea with zonular weakness and childhood lens-related secondary glaucoma—a distinct phenotype caused by recessive *LTBP2* mutations. *Mol Vis*. 2011;17:2570–2579.

## Primary Childhood Glaucoma

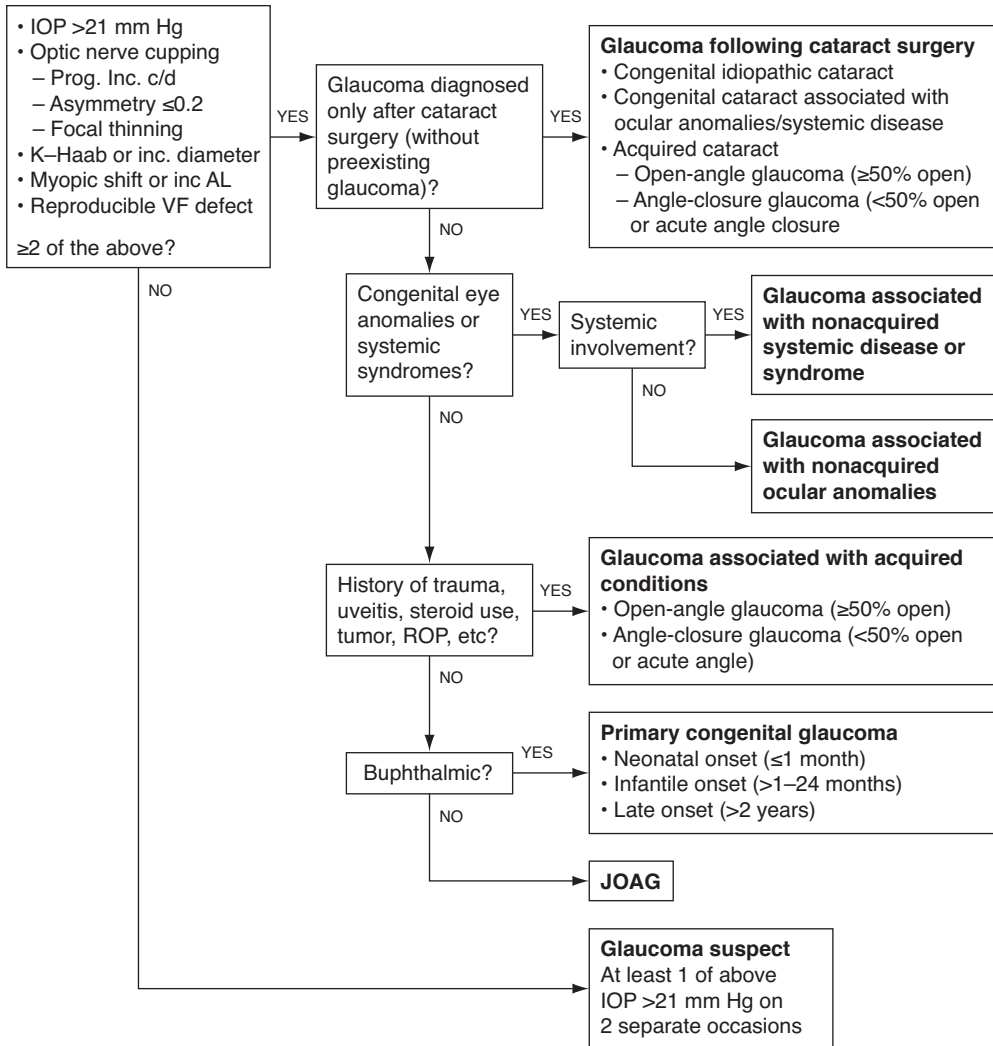
### Primary Congenital Glaucoma

Primary congenital glaucoma (PCG; also called *congenital* or *infantile glaucoma*) is the most common form of childhood glaucoma. The incidence of PCG varies in different populations, ranging from 1 in 1250 live births to 1 in 68,000. PCG occurs more frequently in males (65% of cases), and it is bilateral in about two-thirds of patients. PCG results in blindness in 2%–15% of cases, and visual acuity remains worse than 20/50 in at least 50% of cases.

Although the diagnosis is made at birth in only 25% of affected infants, disease onset occurs within the first year of life in more than 80% of cases. Neonatal-onset and late-recognized PCG are associated with guarded prognoses.

### Pathophysiology

The basic pathologic defect is increased resistance to aqueous outflow through the trabecular meshwork due to abnormal development of neural crest–derived tissue of the anterior chamber angle. The anomaly occurs late in embryologic development.



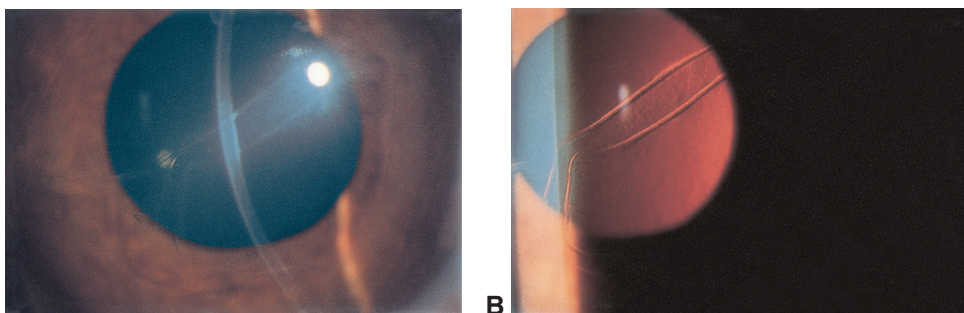
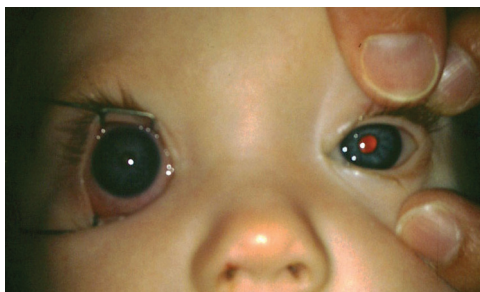**Figure 22-1** Childhood Glaucoma Research Network/World Glaucoma Association algorithm for the classification of childhood glaucoma. AL = axial length; C/D = cup–disc; JOAG = juvenile open-angle glaucoma; ROP = retinopathy of prematurity; VF = visual field. (Courtesy of Allen Beck, MD, and Ta Chen Peter Chang, MD; [www.gl-foundation.org/](http://www.gl-foundation.org/).)

### Clinical manifestations

Primary congenital glaucoma usually presents in the neonatal period or within the first 2 years of life (*infantile PCG*), but it can present or be recognized after 2 years of age (*late-onset* or *late-diagnosed PCG*). Epiphora, photophobia, and blepharospasm constitute the classic clinical triad of PCG. A red eye may be present. Other signs include clouding and enlargement of the cornea (Fig 22-2).

Corneal edema results from elevated IOP and may be gradual or sudden in onset. Corneal edema is often the presenting sign in infants younger than 3 months and is responsible for the clinical triad. Microcystic edema initially involves the corneal epithelium

**Figure 22-2** Primary congenital glaucoma, right eye. The cornea is enlarged. (Courtesy of Gregg T. Lueder, MD.)



**Figure 22-3** **A**, Breaks in Descemet membrane (Haab striae), right eye. **B**, Retroillumination, same eye.

but later extends into the stroma, often accompanied by one or more curvilinear breaks in Descemet membrane (*Haab striae*) (Fig 22-3). Although the edema may resolve with IOP reduction, the split in Descemet membrane persists. Significant corneal scarring and persistent opacification may require penetrating keratoplasty. Corneal enlargement occurs with gradual stretching of the cornea as a result of elevated IOP.

The signs and symptoms of PCG can occur in infants with other forms of glaucoma as well. Nonglaucomatous conditions may also cause some of the signs and symptoms seen in PCG (Table 22-2).

### **Diagnostic examination**

A full ophthalmologic examination of every child suspected of having glaucoma is imperative, despite the challenges. Both office examination and examination under general anesthesia are usually required. Although visual field testing is helpful in following disease progression in older children, results of these tests are rarely reliable in children younger than 6–8 years. Vision is usually poorer in the affected eye in unilateral cases and may be poor in both eyes when glaucoma is bilateral. Fixation and following behavior and the presence of nystagmus should be noted. Refraction, when possible, often reveals myopia and astigmatism from eye enlargement and corneal irregularity.

**Cornea** The cornea should be examined for size, clarity, and Haab striae. In newborns, the normal horizontal diameter of the cornea is 9.5–10.5 mm; a diameter greater than

**Table 22-2 Differential Diagnosis of Signs in Primary Congenital Glaucoma****Conditions sharing signs of epiphora and red eye**

- Conjunctivitis
- Congenital nasolacrimal duct obstruction
- Corneal epithelial defect/abrasion
- Keratitis
- Ocular inflammation (eg, due to uveitis, trauma, foreign body)
- Epiblepharon with eyelash touch

**Conditions sharing sign of corneal edema or opacification**

- Corneal dystrophies: congenital hereditary endothelial dystrophy, posterior polymorphous dystrophy
- Obstetric birth trauma with Descemet tears
- Storage diseases: mucopolysaccharidoses, cystinosis, sphingolipidosis
- Congenital anomalies: sclerocornea, Peters anomaly, choristomas
- Keratitis (eg, secondary to maternal rubella, herpes, phlyctenules)
- Keratomalacia (from vitamin A deficiency)
- Skin disorders affecting the cornea: congenital ichthyosis, congenital dyskeratosis
- Idiopathic (diagnosis of exclusion only)

**Conditions sharing sign of corneal enlargement**

- Axial myopia
- Megalocornea

**Conditions sharing sign of optic nerve cupping (real or apparent)**

- Physiologic optic nerve cupping
- Cupping associated with prematurity, periventricular leukomalacia
- Optic nerve coloboma or pit
- Optic atrophy
- Optic nerve hypoplasia
- Optic nerve malformation

Adapted with permission from Buckley EG. Primary congenital open-angle glaucoma. In: Kahook M, Schuman J, eds. *Chandler and Grant's Glaucoma*. 5th ed. Thorofare, NJ: Slack Incorporated; 2013.

11.5 mm suggests glaucoma. By age 1 year, the normal corneal diameter is 10.0–11.5 mm; a diameter greater than 12.5 mm suggests abnormality. Glaucoma should be suspected in any child with a corneal diameter greater than 13.0 mm. A difference as small as 0.5 mm between the 2 eyes may be significant. Haab striae are best seen against the red reflex after pupil dilation (see Fig 22-3B).

**Central corneal thickness** Portable ultrasonic pachymeters may be used to measure central corneal thickness (CCT), which is typically higher in infants with glaucoma. CCT affects the IOP measurement, but current evidence is inadequate to quantify these effects. See also Chapter 15.

**Tonometry** If the child is struggling during measurement of IOP, pressure readings may be falsely elevated. Examination under sedation or anesthesia may be necessary in children for accurate assessment, but IOP can also be unpredictably altered (usually lowered) with anesthetics and sedation. A useful technique to avoid these issues is to have the parent bottle-feed the infant during pressure measurement. In infants and young children, the most commonly used tonometers are Icare (Icare Finland Oy, Helsinki, Finland), TonoPen (Reichert Technologies, Depew, NY), and Perkins (Haag-Streit USA, Mason, OH). Goldmann applanation readings are preferred when a child is old enough to cooperate.

The normal mean IOP in infants and young children is lower than that in adults: between 10 and 12 mm Hg in newborns and approximately 14 mm Hg by age 7–8 years. In PCG, IOP commonly ranges between 30 and 40 mm Hg, and it is usually greater than 20 mm Hg even with the patient under anesthesia. Asymmetric IOP readings in a quiet or anesthetized child should raise suspicion of glaucoma.

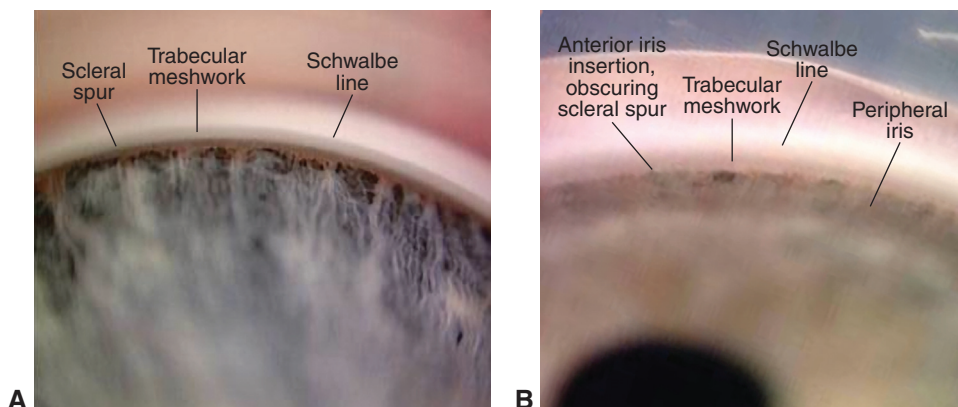
**Anterior segment** A portable slit lamp enables detailed examination of the anterior segment. An abnormally deep anterior chamber and hypoplasia of the peripheral iris stroma are common findings in PCG.

Gonioscopy provides important information about the mechanism of glaucoma. A direct (Koeppel-type) goniolens is preferred for examining children. The anterior chamber angle of a normal infant eye (Fig 22-4A) differs from that of an adult's eye in the following ways:

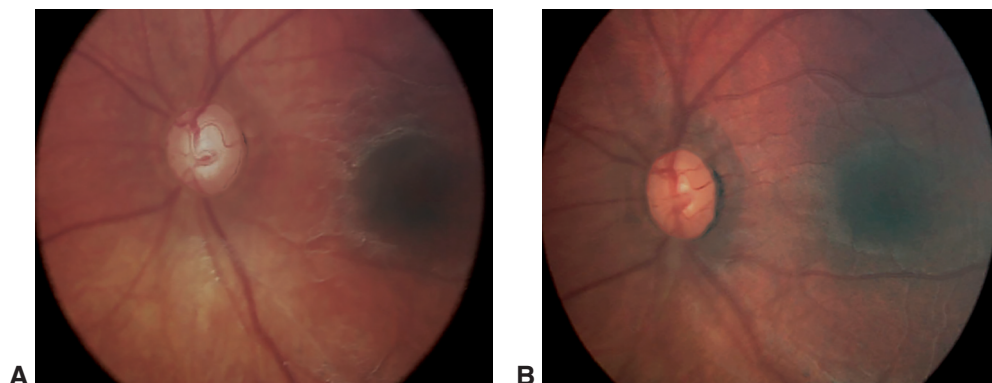
- The trabecular meshwork is more lightly pigmented.
- The Schwalbe line is often less distinct.
- The uveal meshwork is translucent, so the junction between the scleral spur and the ciliary body band is often not well seen.

In an eye with PCG, the iris often shows a more anterior insertion compared with the insertion in a normal infant eye, and the translucence of the uveal meshwork is altered, making the ciliary body band, trabecular meshwork, and scleral spur indistinct (Fig 22-4B). The scalloped border of the iris pigment epithelium is often unusually prominent, especially when peripheral iris stromal hypoplasia is present.

**Optic nerve** In PCG, the optic nerve, when visible, usually shows increased cupping. Generalized enlargement of the optic cup in very young patients with glaucoma has been



**Figure 22-4** **A**, The anterior chamber angle of a normal infant eye, as seen by direct gonioscopy with a Koeppel lens. **B**, Typical appearance of the anterior chamber angle of an infant with primary congenital glaucoma. Note the scalloped appearance of the peripheral iris. The anterior iris insertion obscures the scleral spur. (Courtesy of Ken K. Nischal, MD.)



**Figure 22-5** Optic nerve changes after treatment of congenital glaucoma. **A**, Preoperative enlarged optic disc cup. **B**, Reduction in disc cupping after intraocular pressure is reduced by goniotomy. (Reproduced from Mochizuki H, Lesley AG, Brandt JD. Shrinkage of the scleral canal during cupping reversal in children. *Ophthalmology*. 2011;118(10):2009.)

attributed to stretching of the optic canal and backward bowing of the lamina cribrosa. In most eyes with PCG, the cup–disc ratio exceeds 0.3, whereas in most normal newborn eyes, the cup–disc ratio is less than 0.3. Cup–disc asymmetry greater than 0.2 between the 2 eyes is also suggestive of glaucoma. In young children, optic nerve cupping may be reversible if IOP is lowered (Fig 22-5). Whenever possible, photographs should be taken of the optic disc for comparison during later examinations.

**Axial length** Serial measurement of axial length is useful for monitoring disease progression in infant eyes. Excessive axial length in an eye, especially compared with the fellow eye, may indicate inadequate IOP control.

**Optical coherence tomography** Newer methods of optic nerve and retinal nerve fiber analysis, such as optical coherence tomography (OCT), are being used as objective tools for follow-up of children with elevated IOP and glaucoma. Macular thickness, retinal nerve fiber layer thickness, and optic nerve topography have been shown to vary with race, axial length, and age in children, but normative data are becoming available, which should further increase the usefulness of OCT in the assessment of pediatric glaucoma.

El-Dairi MA, Asrani SG, Enyedi LB, Freedman SF. Optical coherence tomography in the eyes of normal children. *Arch Ophthalmol*. 2009;127(1):50–58.

Prakalapakorn SG, Freedman SF, Lokhnygina Y, et al. Longitudinal reproducibility of optical coherence tomography measurements in children. *J AAPOS*. 2012;16(6):523–528.

### **Natural history**

Untreated PCG almost always progresses to blindness. The cornea irreversibly opacifies and may vascularize. It may continue to enlarge through the first 2–3 years of life, reaching a diameter of up to 17 mm. As the entire eye enlarges, pseudoproptosis and an “ox eye” appearance (buphthalmos) may result. Scleral thinning and myopic fundus



changes may occur, and spontaneous lens dislocation can result. Optic nerve damage progresses, leading to complete blindness. However, rare cases of spontaneous resolution have been reported.

### Juvenile Open-Angle Glaucoma

Juvenile open-angle glaucoma (JOAG) is an autosomal dominant condition that presents after 4 years of age. Unlike in late-recognized PCG, the cornea is not enlarged, Haab striae are not present, and the anterior chamber angle usually appears normal. Management of JOAG is similar to that of adult primary open-angle glaucoma, but the condition frequently requires surgery. See BCSC Section 10, *Glaucoma*, for management of adult glaucoma.

## Secondary Childhood Glaucoma

Glaucoma caused by other ocular anomalies (congenital or acquired) or associated with systemic disease or syndromes is considered secondary. Table 22-3 lists nonacquired ocular anomalies and systemic diseases and syndromes associated with secondary glaucoma.

### Secondary Glaucoma Associated With an Acquired Condition

In children, as in adults, glaucoma may develop secondary to corticosteroid use, uveitis, infection, or ocular trauma. The anticonvulsant and antidepressant medication topiramate can cause acute, usually bilateral, angle-closure glaucoma secondary to ciliary effusion. The ciliochoroidal effusion causes relaxation of zonules, resulting in extreme anterior displacement of the lens-iris complex, which leads to secondary angle-closure glaucoma and high myopia. Peripheral iridectomy is not effective as treatment, but timely cessation of the medication is.

**Table 22-3 Nonacquired Conditions Associated With Secondary Glaucoma**

Ocular Anomalies	Systemic Disease or Syndrome
Anterior segment abnormalities	Sturge-Weber syndrome
Aniridia	Neurofibromatosis type 1
Axenfeld-Rieger syndrome	Lowe (oculocerebrorenal) syndrome
Congenital iris ectropion	Lens-associated disorders
Microcornea	Homocystinuria
Microspherophakia	Marfan syndrome
Peters anomaly	Weill-Marchesani syndrome
Sclerocornea	
Tumors of the iris	
Posterior segment abnormalities	
Familial exudative vitreoretinopathy	
Persistent fetal vasculature	
Retinopathy of prematurity	
Tumors of the retina or ciliary body	

## Glaucoma Following Cataract Surgery

Aphakic glaucoma is a common form of secondary glaucoma in childhood. The reported incidence of open-angle aphakic glaucoma after congenital cataract surgery varies from 15% to 50% or higher. Aphakic glaucoma often develops years after cataract surgery, but it can occur within weeks to months of surgery and remains a lifelong risk. Consequently, patients who have undergone cataract surgery in childhood require regular ophthalmic examination. The children at highest risk for glaucoma development following cataract surgery are those who have surgery during infancy, and the risk appears to be even higher in patients with microcornea or persistent fetal vasculature.

The mechanism of aphakic glaucoma is unclear. The anterior chamber angle usually appears open on gonioscopy; the outflow channels are compromised by some combination of abnormal development of the anterior chamber angle and perhaps susceptibility of the infant eye to surgically induced inflammation, loss of lens support, retained lens epithelial cells, or vitreous factors.

Acute or subacute angle closure with iris bombé is a rare form of aphakic glaucoma. Although it usually occurs soon after surgery, onset can be delayed by a year or more. The diagnosis should be apparent with a slit lamp, but examination at the slit lamp may be difficult in young children. Treatment consists of anterior vitrectomy to relieve the pupillary block, often with surgical iridectomy and goniosynechialysis.

Freedman SF, Lynn MJ, Beck AD, Bothun ED, Öрге FH, Lambert SR; Infant Aphakia Treatment Study Group. Glaucoma-related adverse events in the first 5 years after unilateral cataract removal in the Infant Aphakia Treatment Study. *JAMA Ophthalmol.* 2015;133(8):907–914.

## Treatment

The primary treatment for most types of childhood glaucoma is surgery. PCG is usually effectively treated with angle surgery (goniotomy or trabeculotomy). Although angle surgery may be used to treat some forms of secondary pediatric glaucoma—most notably, those associated with Axenfeld-Rieger syndrome, Sturge-Weber Syndrome, and aniridia—the outcome is often less successful. The treatment of most forms of secondary childhood glaucoma (see Table 22-3) is similar to that of open-angle or secondary glaucoma in adults. Medical treatment often has value prior to surgery and may have long-term benefit, particularly in JOAG and some secondary childhood glaucomas.

## Surgical Therapy

Surgical intervention is the treatment of choice for PCG. Goniotomy or trabeculotomy is the preferred initial procedure. In a *goniotomy*, an incision is made, under direct gonioscopic visualization, across the trabecular meshwork (Fig 22-6, Video 22-1).




**VIDEO 22-1** Goniotomy.  
Courtesy of Ken K. Nischal, MD.



Access all Section 6 videos at [www.aao.org/bcscvideo\\_section06](http://www.aao.org/bcscvideo_section06).

**Figure 22-6** Goniotomy needle with its tip in the trabecular meshwork. The trabecular meshwork to the left of the needle has been incised. (Courtesy of Ken K. Nischal, MD.)



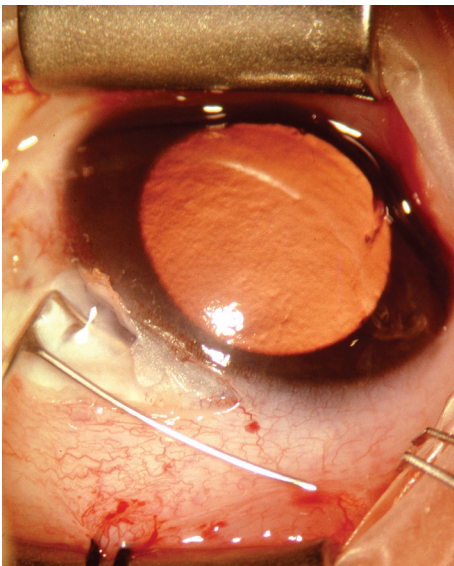
In *trabeculotomy*, an external approach is used to identify and cannulate the Schlemm canal, and then connect it with the anterior chamber through incision of the trabecular meshwork (Fig 22-7, Video 22-2).



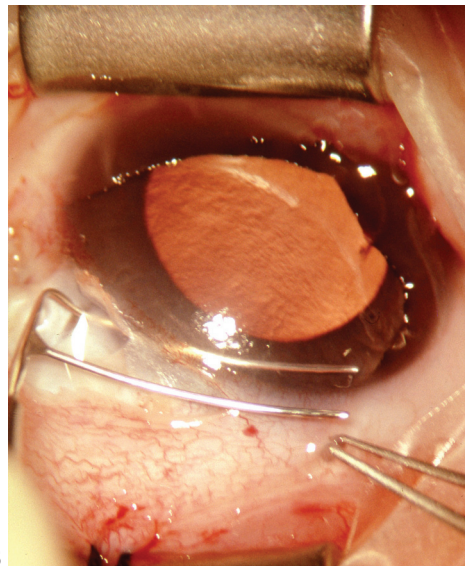
**VIDEO 22-2** Trabeculotomy.  
Courtesy of Young H. Kwon, MD, PhD.



A modification of this technique uses a 6-0 polypropylene monofilament suture or illuminated microcatheter to cannulate and open the Schlemm canal for its entire 360° circumference in one surgery (Video 22-3).



**A**



**B**

**Figure 22-7** Trabeculotomy. **A**, The trabeculotome has entered the Schlemm canal. **B**, The trabeculotome has been rotated into the anterior chamber. (Courtesy of Steven M. Archer, MD.)


**VIDEO 22-3** Illuminated microcatheter–assisted 360-degree trabeculotomy.

*Courtesy of Brenda L. Bohnsack, MD, PhD.*


If the cornea is clear, either a goniotomy or a trabeculotomy can be performed at the surgeon's discretion. Preoperative glaucoma medications or stripping of edematous epithelium from the cornea can temporarily clear the cornea. If the view through the cornea is compromised, trabeculotomy or combined trabeculotomy-trabeculectomy can be performed.

In approximately 80% of infants with PCG presenting from 3 months to 1 year of age, IOP is controlled with 1 or 2 angle surgeries. If the first procedure is not sufficient, at least 1 additional angle surgery is usually performed before a different procedure is used.

When angle surgery is not successful in a child or is not indicated (as is the case in many forms of secondary glaucoma) and medical therapy is inadequate, additional surgical options include trabeculectomy with or without antifibrotic therapy (eg, mitomycin C [MMC]), tube shunt implantation, and cyclodestructive procedures.

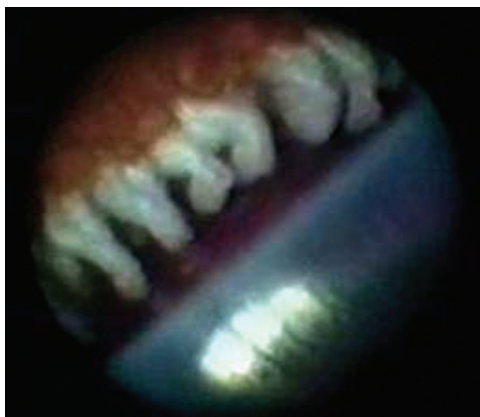Reported success rates for trabeculectomy vary considerably by surgical technique and type of glaucoma and decrease as the length of follow-up increases. Patients younger than 1 year and those who are aphakic are more prone to treatment failure. Although the success rate of trabeculectomy improves with the use of antifibrotics such as MMC, the long-term risk of bleb leaks and endophthalmitis also increases. Long-term risk is reduced by using a fornix-based rather than a limbus-based conjunctival flap. Ab interno trabeculectomy using a mechanical device such as Trabectome (NeoMedix, Tustin, CA) has been described in the treatment of pediatric glaucoma, but its use is still evolving.

The reported success rate of tube shunt implantation surgery with Molteno (Molteno Ophthalmic Limited, Dunedin, New Zealand), Baerveldt (Johnson & Johnson Vision, Santa Ana, CA), and Ahmed (New World Medical, Rancho Cucamonga, CA) devices varies between 54% and 85%. Although most children with implanted tube shunts must remain on adjunct topical medical therapy to control IOP after surgery, their blebs are thicker and are less prone to leaking and infection than those of patients who have undergone MMC-augmented trabeculectomy. Potential complications include shunt failure, tube erosion or migration, tube–cornea touch, cataract, restrictive strabismus, and endophthalmitis.

Laser cyclodestruction and cyclocryotherapy are generally reserved for resistant cases or those not amenable to other surgical procedures. These techniques decrease ciliary body production of aqueous humor, which results in lower IOP. *Cyclocryotherapy* (freezing the ciliary processes through the sclera) may be successful, but the complication rate is high. Repeated applications are often necessary, and the risk of phthisis and blindness is significant (approximately 10%). *Transscleral cyclophotocoagulation* with the Nd:YAG or diode laser has a lower risk of complications. The short-term success rate is approximately 50%. Patients usually require more than one treatment.

*Endoscopic cyclophotocoagulation (ECP)* has been used in children with glaucomas that are difficult to treat. In ECP, a microendoscope applies laser energy to the ciliary processes under direct visualization (Fig 22-8). Success rates of up to 50% have been reported. Although this is an intraocular procedure, the complication rate may be lower than that of external cyclodestructive procedures. Use of the microendoscope is advantageous in eyes

**Figure 22-8** Endoscopic view of the ciliary processes during endoscopic cyclophotocoagulation. The white structure at the bottom right of the photo is the lens. (Courtesy of Endo Optiks, Little Silver, NJ.)



with abnormal anterior segment anatomy. Some studies have shown encouraging results for patients with aphakic glaucoma.

Chen TC, Chen PP, Francis BA, et al. Pediatric glaucoma surgery: a report by the American Academy of Ophthalmology. *Ophthalmology*. 2014;121(11):2107–2115.

Jayaram H, Scawn R, Pooley F, et al. Long-term outcomes of trabeculectomy augmented with mitomycin C undertaken within the first 2 years of life. *Ophthalmology*. 2015;122(11):2216–2222.

## Medical Therapy

Generally, medical therapy for childhood glaucoma has lower success rates and greater risks than medical therapy for adult glaucomas. However, it serves several important purposes in preoperative, postoperative, and long-term management, particularly in childhood glaucoma other than PCG. For example, medications can be used to lower IOP before surgery in order to reduce corneal edema and improve visualization during surgery. They may also be used after surgical procedures in order to provide additional IOP lowering.

Medical therapy for pediatric glaucoma also carries unique risks (Table 22-4) because of the greater dose per body weight and the limited number of controlled clinical trials in children. Although punctal occlusion may be used to reduce systemic absorption of topical medications, it may be impractical in many young children. Limiting the frequency of eyedrop administration in young children may enhance adherence.

### Topical medications

Therapy with topical  $\beta$ -adrenergic antagonists, or  $\beta$ -blockers, may reduce IOP by 20%–30%. The major risks of this therapy are respiratory distress (caused by apnea or bronchospasm) and bradycardia, both of which occur mostly in small infants and in children with a history of bronchospasm. Betaxolol, a cardioselective  $\beta_1$ -adrenergic antagonist, may be safer than a nonselective  $\beta$ -blocker for use in patients with asthma, but its pressure-lowering effect is less than that of nonselective agents.

**Table 22-4 Systemic and Ocular Adverse Effects of Glaucoma Medications in Children**

Drug	Adverse Effects	Precautions
<b>β-Adrenergic antagonists</b>		
Betaxolol, carteolol, levobunolol, metipranolol, timolol hemihydrate, timolol maleate	Hypotension, bradycardia, bronchospasm, apnea Hallucinations Masking of hypoglycemia in diabetic children	Avoid in premature or small infants Use with caution in infants, children with asthma or cardiac disease Select lower concentrations Use punctal occlusion Consider cardioselective β-blocker to reduce risk of bronchospasm
<b>Prostaglandin analogues</b>		
Bimatoprost, latanoprost, latanoprostene bunod, tafluprost, travoprost	May exacerbate uveitis Risk of retinal detachment in Sturge-Weber syndrome Low systemic risk, possible sleep disturbance or exacerbation of asthma	Avoid in patients with uveitis Use with caution following intraocular surgery
<b>α<sub>2</sub>-Adrenergic agonists</b>		
Apraclonidine, brimonidine	Apraclonidine: tachyphylaxis, allergy Apraclonidine and brimonidine: hypotension, bradycardia, hypothermia, CNS depression, coma Risks are greater with brimonidine	Brimonidine relatively contraindicated in children <2 years of age Caution in children <6 years of age or <20 kg Use low dosage Avoid in patients with cardiovascular disease, hepatic or renal impairment
<b>Topical CAIs</b>		
Brinzolamide, dorzolamide	Metabolic acidosis (rare) Stevens-Johnson syndrome Corneal edema	Contraindicated in infants with renal insufficiency Contraindicated in sulfonamide hypersensitivity Monitor infant feeding, weight gain Caution in corneal disease
<b>Oral CAIs</b>		
Acetazolamide, methazolamide	Metabolic acidosis Stevens-Johnson syndrome Headache, nausea, dizziness, paresthesia Growth suppression, failure to thrive, weight loss Bed-wetting	Contraindicated in renal insufficiency, hypokalemia, hyponatremia Contraindicated in sulfonamide hypersensitivity Monitor for metabolic acidosis Monitor infant feeding, weight gain
<b>Parasympathomimetic agents (miotics)</b>		
Echothiophate, pilocarpine	Risk of pupillary block Paradoxical rise in IOP Echothiophate: diarrhea, urinary incontinence, cardiac arrhythmia, weakness, headache, fatigue, iris cysts Pilocarpine: bronchospasm, hypertension, vomiting, diarrhea, dizziness, weakness, headache	Avoid in patients with uveitis Use with caution in cardiac disease, asthma, urinary tract obstruction Limit dosage and use lower concentrations Echothiophate: avoid succinylcholine Consider stopping before general anesthesia

CAIs = carbonic anhydrase inhibitors.

Topical carbonic anhydrase inhibitors (CAIs) are effective in children, but they produce a smaller reduction in IOP (<15%) than do  $\beta$ -blockers. Corneal edema is a risk of topical CAIs; thus, they should be used with caution in children with coexisting corneal disease.

Prostaglandin analogues are effective in many pediatric patients. Their low systemic risk and once-daily dosing are advantageous.

Miotics are rarely used in children; perioperative pilocarpine, however, may facilitate angle surgery. Pilocarpine and echothiophate may be effective in patients with aphakic glaucoma.

The  $\alpha_2$ -adrenergic agonist apraclonidine may be useful for short-term IOP reduction, but there is a high incidence of tachyphylaxis and allergy with use of this drug in young children. Brimonidine, another  $\alpha_2$ -adrenergic agonist, effectively reduces IOP in some cases of pediatric glaucoma. Both medications can produce somnolence and respiratory depression in infants and young children. Infants and young children are particularly susceptible to brimonidine's adverse effects. Therefore, brimonidine should be used with caution in children younger than 6 years, and it is relatively contraindicated in children younger than 2 years because of the risk of respiratory depression. There are similar limitations for the use of fixed-dose combination drugs such as brimonidine/timolol and brinzolamide/brimonidine in the pediatric population.

### **Oral medications**

Oral CAIs may be used effectively in children, particularly to delay the need for surgery or to clear the cornea before goniotomy. Their usefulness may be limited because of their systemic adverse effects (see Table 22-4).

## **Prognosis and Follow-Up**

---

The prognosis for control of IOP and preservation of vision is poor for patients with PCG who present at birth; at least half of these patients become legally blind. If the horizontal diameter of the cornea is greater than 14 mm at diagnosis, the visual prognosis is similarly poor. Up to 90% of cases in the "favorable prognostic group" (onset at 3–12 months of age) can be controlled with angle surgery and medications. The remaining 10%, and many of the remaining cases of primary and secondary glaucomas, often present a lifelong challenge.

Vision loss in childhood glaucoma is multifactorial. It may result from corneal scarring and opacification, optic nerve damage, myopic astigmatism, and associated anisometropic and strabismic amblyopia. Myopia results from axial enlargement of the eye in the setting of high IOP; astigmatism may result from unequal expansion of the anterior segment or from corneal scarring. Careful treatment of refractive errors and amblyopia is necessary to optimize outcomes.

All cases of childhood glaucoma, as well as suspected but unconfirmed glaucoma, require diligent follow-up. After any surgical intervention or change in medical therapy, control of IOP should be assessed within a few weeks. Examination under sedation or anesthesia is often necessary in children for accurate assessment. The IOP should be

considered not as an isolated finding but rather in conjunction with other measurements obtained from the examination, including refractive error (measured serially), corneal diameter, axial length, and cup–disc ratio. If the IOP is less than 20 mm Hg under anesthesia but clinical evidence shows persistent corneal edema or enlargement, progressive optic nerve cupping, or myopic progression, further intervention should be pursued despite the IOP reading. In contrast, a young child who has an IOP of about 20 mm Hg but shows evidence of clinical improvement may be observed carefully.

Long-term follow-up of children with glaucoma is important. Relapse can occur years later, with elevated IOP and subsequent vision loss. Parents, and patients themselves as they become older, should be educated about the need for lifelong monitoring and management.





# Childhood Cataracts and Other Pediatric Lens Disorders

Disorders of the pediatric lens include cataract and abnormalities in lens shape, size, and location. Such abnormalities constitute a significant source of visual impairment in children. The incidence of lens abnormalities ranges from 1:4000 to 1:10,000 live births per year worldwide.

See BCSC Section 11, *Lens and Cataract*, for additional discussion of many of the topics covered in this chapter.

## Pediatric Cataracts

---

Cataracts are responsible for nearly 10% of all vision loss in children worldwide. Pediatric cataracts can be

- isolated or associated with a systemic condition or other ocular anomalies
- congenital (infantile) or acquired
- inherited or sporadic
- unilateral or bilateral
- partial or complete
- stable or progressive

### General Features

Cataracts in children can be isolated, or they can be associated with a number of conditions, including chromosomal abnormalities, systemic syndromes and diseases, infection, trauma, and radiation exposure. In almost all cases of cataract associated with systemic disease, the cataracts are bilateral (Table 23-1); many bilateral cataracts, however, are not associated with systemic disease. Significant asymmetry can be present in bilateral cases.

Cataracts can also be associated with other ocular anomalies, including persistent fetal vasculature, anterior segment dysgenesis, aniridia, and retinal disorders (eg, coloboma, detachment).

Pediatric cataracts can be congenital or acquired. Congenital cataracts are present at birth, although they may not be identified until later. Infantile cataracts are present during the first year of life. The terms *congenital* and *infantile cataract* are typically used synonymously. In general, the earlier the onset, the more amblyogenic the cataract will be,

**Table 23-1 Etiology of Pediatric Cataracts****Bilateral cataracts**

- Idiopathic
- Familial (hereditary), usually autosomal dominant; also X-linked; rarely autosomal recessive
- Chromosomal abnormality
  - Trisomy 21 (Down syndrome), 13, 18
  - Other translocations, deletions, and duplications
- Craniofacial syndromes
  - Hallermann-Streiff, Rubinstein-Taybi, Smith-Lemli-Opitz, others
- Musculoskeletal disorders
  - Albright syndrome, Conradi-Hünemann syndrome, myotonic dystrophy
- Renal syndromes
  - Alport syndrome, Lowe syndrome
- Metabolic diseases
  - Cerebrotendinous xanthomatosis, diabetes mellitus, Fabry disease, galactosemia, mannosidosis, Wilson disease
- After intrauterine infection
  - Cytomegalovirus
  - Rubella
  - Syphilis
  - Toxoplasmosis
  - Varicella
- Ocular anomalies
  - Aniridia
  - Anterior segment dysgenesis
- Iatrogenic
  - Corticosteroid use
  - Radiation exposure

**Unilateral cataracts**

- Idiopathic
- Ocular anomalies
  - Persistent fetal vasculature
  - Posterior lenticonus, lentiglobus
  - Posterior segment tumor
  - Retinal detachment (from any cause) or coloboma
- Trauma (including child abuse)
- Radiation exposure

particularly in unilateral cases. Lens opacities that are visually significant before 2–3 months of age are the most likely to be detrimental to vision.

Most hereditary cataracts show an autosomal dominant mode of transmission, and they are almost always bilateral. X-linked and autosomal recessive inheritance may occur; the latter is more common in consanguineous populations. *OMIM* (*Online Mendelian Inheritance in Man*; omim.org) includes the most up-to-date information on genetic disorders with lens involvement.

**Morphology**

Cataracts can involve the entire lens (*total*, or *complete*, cataract) or only part of the lens structure. The location in the lens and morphology of the cataract provide information

**Table 23-2 Morphology and Etiology of Select Pediatric Cataracts**

Cataract Morphology	Etiology	Other Possible Findings
Spokelike	Fabry disease Mannosidosis	Corneal whorls Hepatosplenomegaly
Vacuolar	Diabetes mellitus	Elevated blood glucose level
Multicolored flecks	Hypoparathyroidism Myotonic dystrophy	Low serum calcium level Characteristic facial features, tonic “grip”
Green “sunflower”	Wilson disease	Kayser-Fleischer ring
Thin disciform	Lowe syndrome	Hypotonia, glaucoma

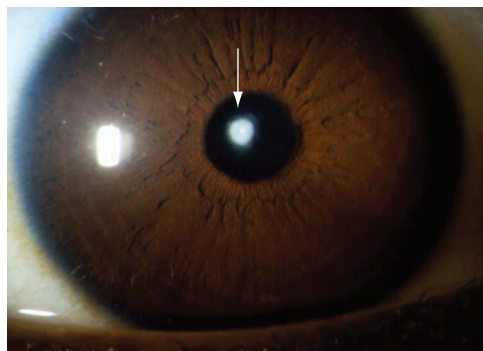
about etiology (Table 23-2), onset, and prognosis. Important types and causes of cataract in children are discussed in the following sections.

### **Anterior polar cataract**

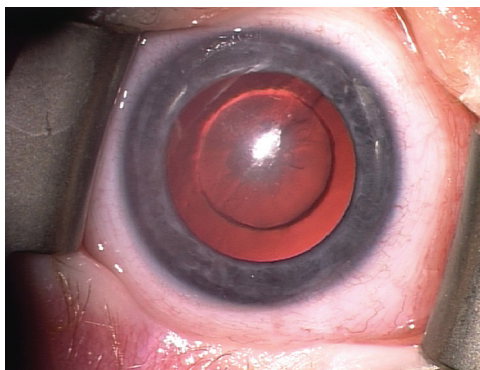
Anterior polar cataracts (APCs) are common and usually less than 3 mm in diameter, appearing as small white dots in the center of the anterior lens capsule (Fig 23-1). They are congenital, usually sporadic opacities. APCs can be unilateral or bilateral. They are usually nonprogressive and visually insignificant, perhaps more appropriately termed *anterior lens opacities*. However, unilateral APCs are associated with anisometropia, which may cause amblyopia; thus, careful refraction and follow-up are indicated. *Anterior pyramidal cataracts*, as the name suggests, have a pyramidal shape and project into the anterior chamber. This cataract is a larger, more severe form of APC. It is often associated with cortical changes that can be progressive and amblyogenic, depending on the size of the opacity.

### **Infantile nuclear cataract**

Nuclear cataracts are opacities that involve the center, or nucleus, of the lens. They are usually approximately 3 mm in diameter, but the irregularity of the lens fibers can extend more peripherally. Density and size can vary. Infantile nuclear cataracts may not be significantly dense at birth (Fig 23-2). They can be inherited or sporadic and are more commonly bilateral. These opacities are usually stable, but they can progress. Eyes with nuclear cataracts may be smaller than normal.



**Figure 23-1** Anterior polar cataract (arrow).  
(Courtesy of Gregg T. Lueder, MD.)



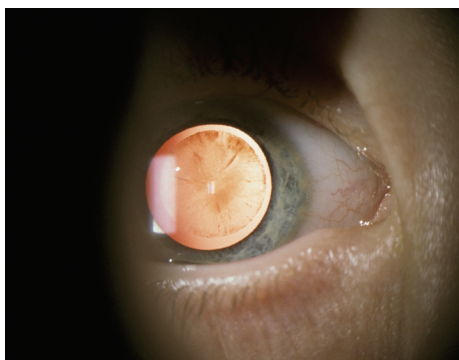**Figure 23-2** Congenital nuclear cataract. (Courtesy of Ken K. Nischal, MD.)

### **Lamellar cataract**

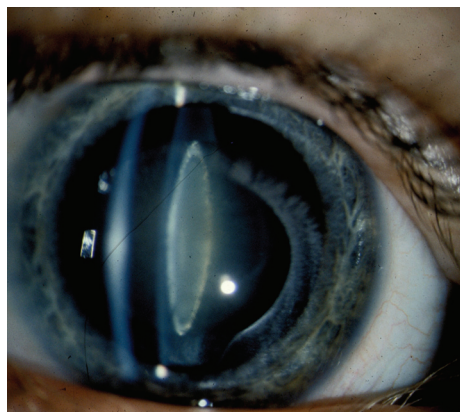
Lamellar (*zonular*) cataracts affect one or more of the layers of the developing lens cortex surrounding the nucleus. Affected lenses have a clear center, a discrete lamellar opacity, and a clear peripheral cortex. Larger than nuclear cataracts, these opacities are typically 5 mm or more in diameter (Fig 23-3). They can be unilateral but are more often bilateral. The size and corneal diameter of affected eyes are normal. Lamellar cataracts are often less dense than other forms of infantile cataracts, and therefore the visual prognosis is usually better.

### **Posterior lenticonus**

Posterior lenticonus is a cone-shaped deformation of the posterior lens surface caused by progressive thinning of the central capsule (Fig 23-4A); when the deformation is spherical, it is referred to as *lentiglobus*. This thinning initially causes the lens to have an “oil droplet” appearance on red reflex examination. As the outpouching of the lens progresses, the surrounding cortical fibers gradually opacify (Fig 23-4B). This process can take many years, but if the capsule develops a small tear, rapid, total opacification of the lens can occur (Fig 23-4C).

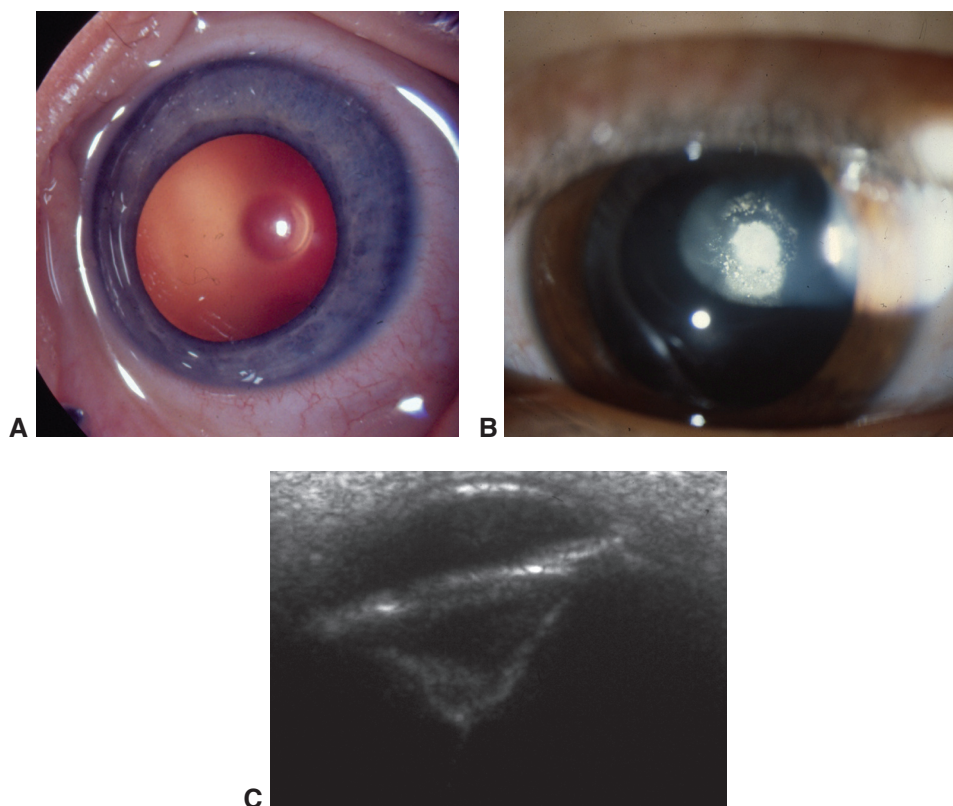


**A**



**B**

**Figure 23-3** Lamellar cataract. **A**, Retroillumination shows the size of the lamellar opacity. **B**, Slit-lamp view shows a lamellar opacity surrounding clear nucleus. (Courtesy of David A. Plager, MD.)



**Figure 23-4** Posterior lenticonus. **A**, Early clear defect in the central posterior capsule. **B**, Opacification of the central defect. **C**, Ultrasound biomicroscopy of advanced posterior lenticonus. (Part A courtesy of Edward L. Raab, MD; part B, David A. Plager, MD; part C, Ken K. Nischal, MD.)

The opacities are almost always unilateral, and the affected eye is normal in size. Although the weakness in the posterior capsule may be congenital, the cataract does not usually form until later and thus behaves like an acquired cataract. The visual prognosis after cataract surgery is usually favorable.

### **Posterior subcapsular cataract**

Posterior subcapsular cataracts (PSCs) are less common in children than in adults. They are usually acquired and are often bilateral. PSCs tend to progress. Causes of PSC include corticosteroid use, uveitis, retinal abnormalities, radiation exposure, and trauma. PSCs can be seen in association with neurofibromatosis type 2 and may be the first observed manifestation of this disorder.

### **Sectoral cataract**

Wedge-shaped cortical cataracts are occasionally seen in children. These opacities may be idiopathic, or they may be associated with occult posterior segment tumor, previous blunt trauma, vitreoretinopathies, or retinal coloboma with fibrous bands attached to the

posterior lens capsule. Careful posterior segment examination is indicated to rule out these associated pathologies.

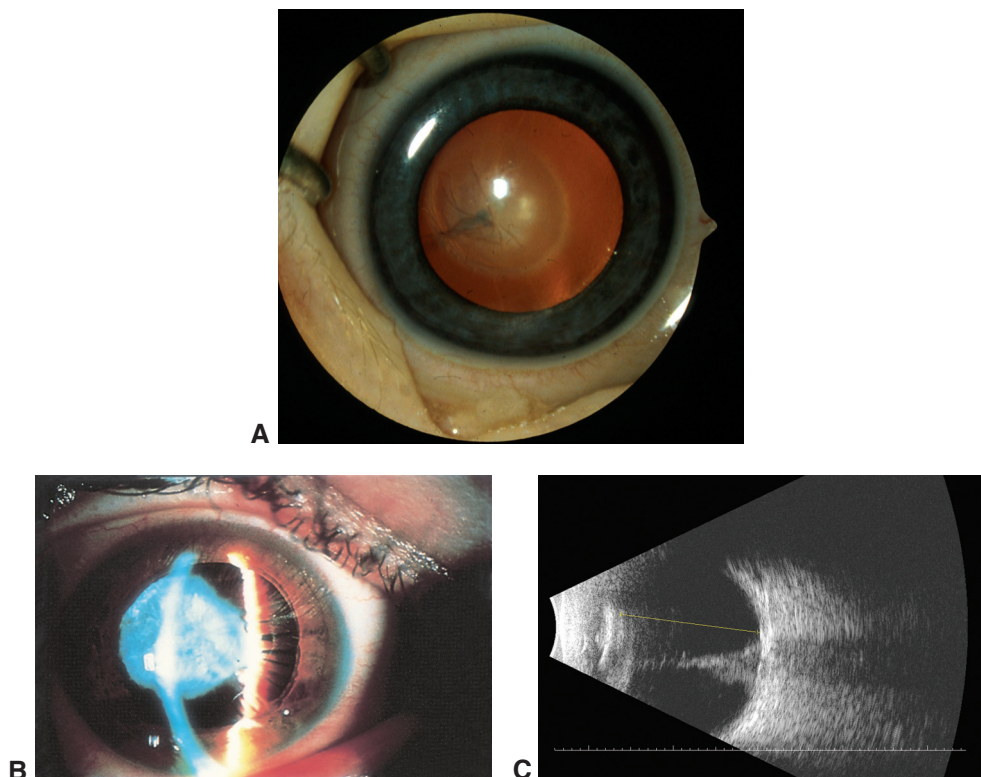
### ***Peripheral vacuolar cataract***

These asymptomatic peripheral lens vacuoles are sometimes seen in premature infants. The cataracts are most often encountered during examination for retinopathy of prematurity. They are rarely visually significant and usually resolve spontaneously.

### ***Persistent fetal vasculature***

Persistent fetal vasculature (PFV; previously called *persistent hyperplastic primary vitreous*) is the most common cause of a unilateral cataract. PFV is typically an isolated, sporadic ocular malformation, but bilateral cases may be associated with systemic or neurologic abnormalities. Usually, affected eyes are smaller than normal.

PFV ranges in severity from mild to severe (Fig 23-5). Features of mild PFV are prominent hyaloid vessel remnants, a large Mittendorf dot, and Bergmeister papilla. At the other end of the spectrum are microphthalmic eyes with dense retrolental plaques; a thick, fibrous persistent hyaloid artery; elongated ciliary processes (classic for PFV), which may



**Figure 23-5** Persistent fetal vasculature (PFV). **A**, Mild variant with central retrolental membrane. **B**, Elongated ciliary processes are adherent to the lens. Note the dense fibrous plaque on the posterior lens capsule. **C**, Ultrasonogram of an eye with PFV. Note the dense stalk arising from the optic nerve and attaching to the posterior lens. (Part A courtesy of David A. Plager, MD; part C courtesy of Edward L. Raab, MD.)

be visible through the dilated pupil; and prominent radial iris vessels. Traction on the optic disc may cause distortion of the posterior retina. Varying degrees of lens opacification occur. The opacity usually consists of a retrolental plaque that is densest centrally and may contain cartilage and fibrovascular tissue.

The natural history of more severely affected eyes is usually one of progressive cataract formation and anterior chamber shallowing, causing secondary glaucoma. The glaucoma can occur acutely because of rapid, total lens opacification and swelling, or it may develop gradually, over years. Congenital retinal nonattachment, ciliary body detachment, vitreous hemorrhage, and optic nerve dysmorphism are other features of severe PFV.

Retinoblastoma may be part of the initial differential diagnosis of PFV because of leukocoria. The presence of microphthalmia and cataract are important factors in the differentiation of these disorders, as retinoblastoma is rarely found in microphthalmic eyes, and cataracts are very unusual in retinoblastoma.

### Evaluation of Pediatric Cataracts

All newborns should have a screening eye examination performed by their primary care provider, including an evaluation of the red reflex. Retinoscopy through an undilated pupil is helpful for assessing the potential visual significance of an axial lens opacity in a preverbal child. Table 23-3 summarizes the evaluation of pediatric cataracts.

---

**Table 23-3 Evaluation of Pediatric Cataracts**

---

Family history (autosomal dominant, X-linked, autosomal recessive, reduced penetrance, variable expressivity; associated anomalies may be indicative of chromosomal translocation, balanced in the parent, unbalanced in the child)
Detailed history of the child's growth, development, and systemic disorders
Pediatric physical examination
Genetics evaluation
Ocular examination, including
Visual function
Corneal diameter
Iris configuration
Anterior chamber depth
Lens position
Cataract morphology
Posterior segment
Rule out posterior mass.
Rule out retinal detachment.
Rule out stalk between optic nerve and lens.
Intraocular pressure
Laboratory studies to consider for bilateral cataracts of unknown etiology
Disorders of galactose metabolism: urine for reducing substances; galactose-1-phosphate uridylyltransferase; galactokinase
Infectious diseases: TORCH and varicella titers, VDRL test
Metabolic diseases: urine amino acids test (Lowe syndrome); serum calcium (low in hypoparathyroidism), phosphorus (high in hypoparathyroidism), glucose (high in diabetes mellitus), and ferritin (high in hyperferritinemia)

---

TORCH = toxoplasmosis, rubella, cytomegalovirus, herpes simplex virus.



### ***History***

The clinician should obtain a history of the child's growth, development, and systemic disorders, in addition to a family history, as this information can help guide the evaluation. For example, a patient with acquired cataract and intractable diarrhea should be evaluated for the treatable metabolic disorder cerebrotendinous xanthomatosis. A slit-lamp examination of immediate family members can reveal previously undiagnosed lens opacities that are visually insignificant but that may indicate an inherited cause for the child's cataracts. Congenital posterior sutural cataracts, for example, develop in female carriers of X-linked Nance-Horan syndrome, and mild lenticular opacities develop in female carriers of Lowe (oculocerebrorenal) syndrome by puberty.

### **Examination**

#### ***Visual function***

The mere presence of a cataract does not suggest that surgical removal is necessary. That determination requires assessment of the visual significance of the lens opacity.

In healthy infants aged 2 months or younger, the fixation reflex may not be fully developed; thus, its absence in this group of patients is not necessarily abnormal. In general, anterior capsule opacities are not visually significant unless they occlude the entire pupil. Central or posterior lens opacities of sufficient density that are greater than 3 mm in diameter are usually visually significant. Opacities that have a large area of surrounding normal red reflex or that have clear areas within them may allow good visual development. Strabismus associated with a unilateral cataract and nystagmus associated with bilateral cataracts indicate that the opacities are visually significant. Although these signs may also indicate that the optimal time for treatment has passed, cataract surgery may still improve visual function.

In preverbal children older than 2 months, standard clinical assessment of fixation behavior, fixation preference, and objection to occlusion provide additional evidence of the visual significance of the cataract(s). For bilateral cataracts, assessment of the child's visual behavior and the family's observations of the child at home help determine the level of visual function. Preferential looking tests and visual evoked potentials can provide quantitative information (see Chapter 1). In older children, particularly those with lamellar or posterior subcapsular cataracts, glare testing may be useful for assessing decreased vision.

#### ***Ocular examination***

Slit-lamp examination can help classify the morphology of the cataract and reveal associated abnormalities of the anterior segment. If the cataract allows some view of the posterior segment, the optic nerve and fovea should be examined. If no such view is possible, B-scan ultrasonography should be performed to assess for anatomical abnormalities of the posterior segment. The presence of retinal or optic nerve abnormalities cannot be definitively ruled out, however, until the posterior pole can be visualized directly. See Table 23-3 for additional information.

**Workup**

Unilateral cataracts are not usually associated with systemic disease; laboratory tests are therefore not warranted in these cases. In contrast, bilateral cataracts are associated with many metabolic or other systemic diseases. If the child has a positive family history of isolated congenital or childhood cataract or if examination of the parents shows lens opacities (and there are no associated systemic diseases to explain their cataracts), systemic evaluation and laboratory tests are not necessary. A basic laboratory evaluation for bilateral cataracts of unknown etiology is outlined in Table 23-3.

Further workup should be directed by the presence of other systemic abnormalities. Evaluation by a geneticist may be helpful for determining whether there are associated disorders and for counseling the patient's family regarding recurrence risks. Next-generation gene sequencing, which analyzes large portions of the genome, is of increasing utility, even in cases without evidence of systemic disease.

## Cataract Surgery in Pediatric Patients

---

**Timing of the Procedure**

In general, the younger the child, the greater the urgency to remove the cataract, because of the risk of deprivation amblyopia. For optimal visual development, a visually significant unilateral cataract should be removed before age 6 weeks; visually significant bilateral cataracts, before age 10 weeks.

For older children with bilateral cataracts, surgery is indicated when the level of visual function interferes with the child's visual needs. Although children with best-corrected visual acuity of roughly 20/70 may function relatively well in early grade school, their participation in activities such as unrestricted driving may be restricted. Surgery should be considered when visual acuity decreases to 20/40 or worse.

For older children with unilateral cataract, cataract surgery is indicated when visual acuity cannot be improved beyond 20/40.

**Intraocular Lens Use in Children**

The choice of optical device for correction of aphakia depends primarily on the age of the patient and the laterality of the cataract. Intraocular lens (IOL) implantation in children aged 1–2 years and older is widely accepted. The use of IOLs in younger infants, however, is associated with a higher rate of complications and larger shifts in refractive error with age. Early surgical intervention followed by consistent contact lens wear and patching of the uninvolved eye usually allows development of some useful vision. In most infants who are left aphakic, secondary IOL implantation can be performed after 1–2 years of age.

Infants with mild PFV have a higher incidence of adverse events after lensectomy compared with children with other forms of unilateral cataract, but visual outcomes are similar in both groups.

## Management of the Anterior Capsule

To enable access to the lens nucleus and cortex during cataract surgery, a *capsulorrhexis* is performed. Because the tearing characteristics of the pediatric capsule are quite different from those of the adult capsule, lens removal techniques are modified for pediatric patients so that the risk of inadvertent extension of the tear is minimized. The elasticity of the capsule is greatest in younger patients, especially infants, making continuous curvilinear capsulorrhexis more difficult. The pulling force should be directed nearly perpendicular to the direction of intended tear, and the capsule should be regrasped frequently to maintain optimal control over the direction of tear. An alternative to capsulorrhexis in infants is *vitrectorhexis*, the creation of an anterior capsule opening using a vitrectomy instrument. In children with dense cataracts that obscure the red reflex, visibility of the anterior capsule can be enhanced with application of trypan blue ophthalmic solution 0.06% to the capsule.

## Lensectomy Without Intraocular Lens Implantation

In children who will be left aphakic, lensectomy is done through a small peripheral corneal, limbal, or pars plana incision with a vitreous-cutting instrument (vitrector). Irrigation can be provided by an integrated infusion sleeve or by a separate anterior chamber cannula. Ultrasonic phacoemulsification is not required, as the lens cortex and nucleus are generally soft in children of all ages. Removing all cortical material is important because of the propensity for reproliferation of pediatric lens epithelial cells. Tough, fibrotic plaques (eg, in severe PFV) may require manual excision with intraocular scissors and forceps.

Because posterior capsule opacification occurs rapidly in young children, a controlled posterior capsulectomy and anterior vitrectomy should be performed at the time of cataract surgery. This technique allows rapid, permanent establishment of a clear visual axis for retinoscopy and prompt fitting and monitoring of the aphakic optical correction. If possible, sufficient peripheral lens capsule should be left to facilitate secondary posterior chamber IOL implantation later.

## Lensectomy With Intraocular Lens Implantation

Single-piece foldable acrylic IOLs, which can be placed through a 3-mm clear corneal or scleral tunnel incision, have become popular in pediatric cataract surgery, although larger single-piece polymethyl methacrylate (PMMA) lenses are also still used. Silicone lenses have not been well studied in children.

If an IOL is to be placed at the time of cataract extraction, 2 basic techniques can be used for the lensectomy, depending on whether the posterior capsule will be left intact. Many pediatric cataract surgeons leave the posterior capsule intact if the child is approaching the age when an Nd:YAG laser capsulotomy in an awake patient could be performed (usually 5 years of age). Primary capsulectomy is usually preferred for younger children. Studies have shown that in early childhood, the lens capsule opacifies, on average, within 18–24 months of surgery, but this can vary considerably.

***Technique with posterior capsule intact***

After the cortex is aspirated, the clear corneal or scleral tunnel incision is enlarged to allow placement of the IOL. Placement in the capsular bag is desirable, but ciliary sulcus fixation is acceptable. Viscoelastic material should be removed to prevent a postoperative spike in intraocular pressure. Closure of 3-mm clear corneal incisions with absorbable suture is safe and does not induce astigmatism in children.

***Techniques for primary posterior capsulectomy***

**Posterior capsulectomy/vitrectomy before IOL placement** After lensectomy, the vitrector settings should be set to the low-suction, high-cutting rate appropriate for vitreous surgery. A posterior capsulectomy with anterior vitrectomy is then performed. The anterior capsule is enlarged, if necessary, to an appropriate size for the IOL, and the lens is implanted in the capsular bag or the ciliary sulcus. The surgeon must take care to ensure that the capsulotomy does not extend, the IOL haptics do not go through the posterior opening, and vitreous does not become entangled with the IOL or enter the anterior chamber.

**Posterior capsulectomy/vitrectomy after IOL placement** Some surgeons prefer to place the IOL in the capsular bag, close the anterior incision, and approach the posterior capsule through the pars plana. Irrigation can be maintained through the same anterior chamber infusion cannula used during lensectomy. A small conjunctival opening is made over the pars plana, and a sclerotomy is made with a microvitrectomy blade 2.5–3.0 mm posterior to the limbus. This provides good access to the posterior capsule, and a wide anterior vitrectomy can be performed.

***Intraocular lens implantation issues***

Because the eye continues to elongate throughout the first decade of life and beyond, selecting an appropriate IOL power is complicated. Power calculations in infants and young children may be unpredictable for several reasons, including widely variable growth of the eye, difficulty obtaining accurate keratometry and axial length measurements, and use of power formulas that were developed for adults rather than children. Studies have shown that in aphakic pediatric eyes, a variable myopic shift in refractive error of approximately 7.00–8.00 D occurs from 1 year to 10 years of age, with a wide standard deviation. This suggests that if a child is made emmetropic with an IOL at 1 year of age, refractive error at 10 years of age can be –8.00 D or greater. Refractive change in children younger than 1 year is even more unpredictable. This assumes that the presence of an IOL does not alter the normal growth curve of the aphakic eye, an assumption that may not be valid based on results of both animal and early human studies.

Lens implantation in children requires consideration of the age of the child, the target refractive error at the time of surgery, and the refractive error of the contralateral eye. Some surgeons implant IOLs with powers that are expected to be required in adulthood, allowing the child to grow into the selected lens power. Thus, the child initially requires hyperopic correction. Other surgeons aim for emmetropia at the time of lens implantation, especially in unilateral cases, believing that this approach improves the treatment of

amblyopia and facilitates development of binocular function by decreasing anisometropia in the early childhood years. These children usually become progressively more myopic and may eventually require a second procedure to address the increasing anisometropia.

## **Postoperative Care**

### ***Medical therapy***

If all cortical material is adequately removed, postoperative inflammation is usually mild in a child without a lens implant. Topical antibiotics, corticosteroids, and cycloplegics are commonly applied for a few weeks after surgery. Topical corticosteroids should be used more aggressively in children who have undergone IOL implantation. Some surgeons administer intracameral corticosteroids at the time of surgery, and others use oral corticosteroids postoperatively, especially in very young children and in children with heavily pigmented irides. Some surgeons administer intracameral antibiotics in addition to topical antibiotics.

### ***Amblyopia management***

Amblyopia therapy should begin as soon as possible after surgery. For aphakic patients, contact lenses or glasses should be dispensed within a few weeks of surgery.

For infants with bilateral aphakia, glasses are the safest and simplest method of correction. They can be easily changed according to the refractive shifts that occur with growth of the eye. Until the child can use a bifocal lens properly, the power selected should make the eye myopic, because most of an infant's visual activity occurs at near. Contact lenses may also be used in bilaterally aphakic patients, but they require more effort on the part of both the caregiver and the physician than do glasses.

For infants with unilateral aphakia, contact lenses are the most common method of correction. Advantages of contact lenses include relatively easy power changes and the potential for extended wear with certain lenses. Disadvantages include easy displacement by eye rubbing, the expense of replacement, and the risk of microbial keratitis. Aphakic glasses are occasionally used in infants with unilateral aphakia who are unable to tolerate contact lenses, but these glasses are suboptimal owing to the amblyogenic effect of aniseikonia and the difficulty of wearing glasses that are much heavier on one side.

After optical correction of aphakia, patching of the better eye is necessary in patients with unilateral cataract and in some patients with bilateral cataracts if the visual acuity is asymmetric. The amount of patching is based on the degree of amblyopia and the age of the child. Avoidance of full-time occlusion in the neonatal period may allow stimulation of binocular vision and may help prevent strabismus.

## **Complications Following Pediatric Cataract Surgery**

Strabismus is very common in children following surgery for either unilateral or bilateral cataracts. The risk of glaucoma is increased in children who have cataract surgery in infancy and in those with small eyes (see Chapter 22), but glaucoma often does not develop until several years after surgery. Corneal decompensation is very rare in children. Retinal detachments are also rare and are most likely to occur when other ocular abnormalities are present. The incidence of macular edema is unknown, as it is

difficult to detect ophthalmoscopically in young children and optical coherence tomography is usually not possible. Postoperative endophthalmitis rarely occurs in children after cataract surgery.

### Visual Outcome After Cataract Extraction

Visual outcome after cataract surgery depends on many factors, including age at onset and type of cataract, timing of surgery, choice of optical correction, and treatment of amblyopia. Early surgery by itself does not ensure a good outcome. Optimal vision requires careful, long-term postoperative management, particularly regarding amblyopia. Even when congenital cataracts are detected late (after age 4 months), cataract removal combined with a strong postoperative vision rehabilitation program can achieve good vision in some eyes.

## Structural or Positional Lens Abnormalities

### Congenital Aphakia

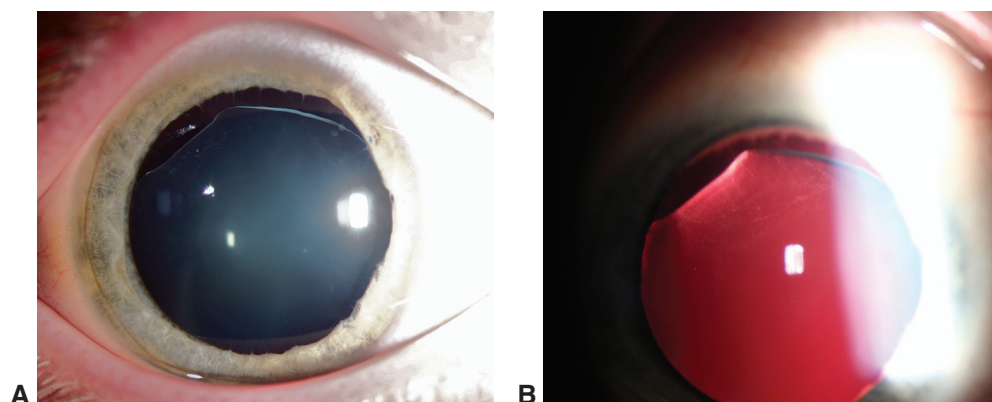
Congenital aphakia, the absence of the lens at birth, is rare. This condition is usually associated with a markedly abnormal eye.

### Spherophakia

A lens that is spherical and smaller than normal is termed *spherophakic*. This condition is usually bilateral. The lens may dislocate and prolapse into the anterior chamber, causing secondary glaucoma.

### Coloboma

A lens coloboma involves flattening or notching of the lens periphery (Fig 23-6). It may be associated with a coloboma of the iris, optic nerve, or retina, all of which are caused by abnormal closure of the embryonic fissure. The term *lens coloboma* is a misnomer because



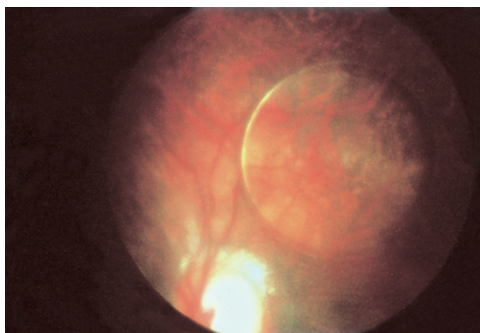
**Figure 23-6** Lens coloboma, viewed with slit-beam illumination (A) and retroillumination (B). The lens is subluxated inferonasally, and there is a notch in the superotemporal portion of the lens where zonules are lacking. (Courtesy of Gregg T. Lueder, MD.)

the lens defect is caused by absence or stretching of the zonular fibers in the affected area (usually inferonasally) and is not directly due to abnormal embryonic fissure closure. In more significant colobomatous defects, lens dislocations may occur superiorly and temporally. Most colobomatous lenses do not progressively worsen.

## Dislocated Lenses in Children

When the lens is not in its normal position, it is said to be *dislocated*. *Subluxated* (or *subluxed*) lenses are partly dislocated. *Luxated* (or *luxed*), or *ectopic*, lenses are completely detached from the ciliary body; they are free in the posterior chamber (Fig 23-7), or they have prolapsed into the anterior chamber. The amount of dislocation can vary, from slight displacement with minimal *iridodonesis* (tremulousness of the iris) to severe displacement in which the lens periphery is not visible through the pupillary opening. Lens dislocation can be familial or sporadic. It can be associated with gene mutations that specifically affect the eye, with multisystem disease, and with inborn errors of metabolism (Table 23-4). Lens dislocation can occur with trauma, usually involving significant injury to the eye, but this is not common. Spontaneous lens dislocation has been reported in aniridia, buphthalmos associated with congenital glaucoma, and congenital megalocornea with zonular weakness (due to mutations in latent transforming growth factor beta-binding protein 2 [*LTBP2*]).

Khan AO, Aldahmesh MA, Alkuraya FS. Congenital megalocornea with zonular weakness and childhood lens-related secondary glaucoma—a distinct phenotype caused by recessive *LTBP2* mutations. *Mol Vis*. 2011;17:2570–2579.



**Figure 23-7** Lens dislocation into vitreous.

**Table 23-4 Conditions Associated With Dislocated Lenses**

Systemic conditions	Ocular conditions
Marfan syndrome	Aniridia
Homocystinuria	Iris coloboma
Weill-Marchesani syndrome	Trauma
Sulfite oxidase deficiency	Hereditary ectopia lentis
	Congenital megalocornea with zonular weakness

### Isolated Ectopia Lentis

In simple ectopia lentis, the lens is displaced superiorly and temporally. The condition is usually bilateral and symmetric. Most commonly, it is inherited as an autosomal dominant trait. Onset can be at birth or later in life. Glaucoma is common in the late-onset type.

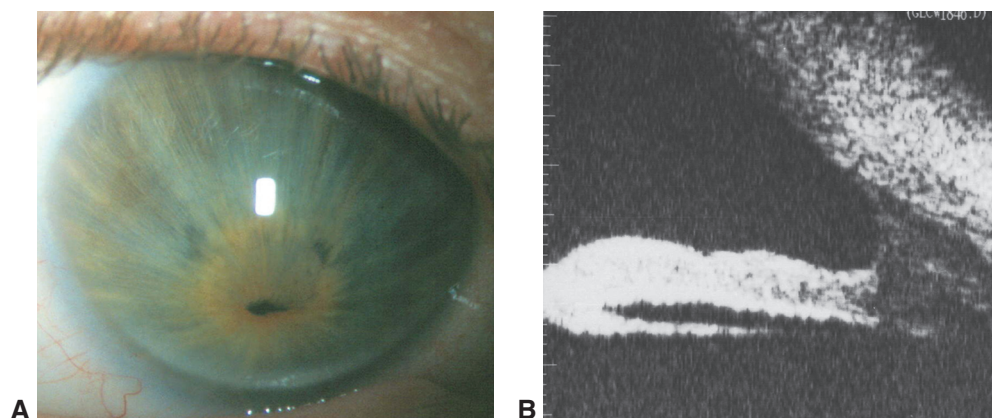
Some patients with heterozygous mutations in *FBNI*, which cause Marfan syndrome (discussed later), do not have the systemic findings associated with this syndrome and have only ectopia lentis.

### Ectopia Lentis et Pupillae

Ectopia lentis et pupillae is a rare autosomal recessive condition in which there is bilateral displacement of the pupil, usually inferotemporally, and dislocation of the lens in the opposite direction (Fig 23-8A) (see Chapter 21). The condition is characterized by small, round lenses (microspherophakia); miosis; and poor pupillary dilation with mydriatics. Ectopia lentis et pupillae may be the result of a membrane extending from a posterior origin to attach to the proximal pupil margin (Fig 23-8B).

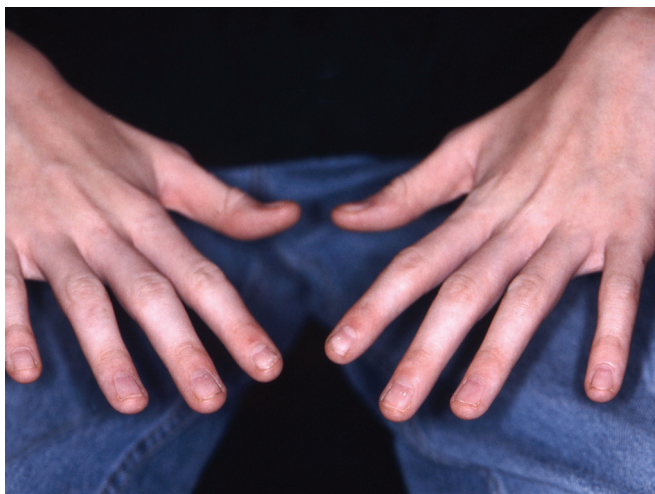### Marfan Syndrome

Marfan syndrome is the systemic disease most commonly associated with subluxated lenses. The syndrome consists of abnormalities of the cardiovascular, musculoskeletal, and ocular systems. It is inherited as an autosomal dominant trait, but family history is negative in 15% of cases. Marfan syndrome is caused by mutations in *FBNI*, which provides instructions for making the protein fibrillin-1, the major constituent of extracellular microfibrils. Affected patients are characteristically tall, with long limbs and fingers (*arachnodactyly*) (Fig 23-9); loose, flexible joints; scoliosis; and chest deformities. Cardiovascular abnormalities are a source of significant mortality and manifest as enlargement of the aortic root, dilation of the descending aorta, dissecting aneurysm, and floppy mitral



**Figure 23-8** **A**, Ectopia lentis et pupillae. **B**, Ultrasonography shows a membrane posterior to the iris attaching at the pupil margin. (Part A reproduced from Byles DB, Nischal KK, Cheng H. Ectopia lentis et pupillae. A hypothesis revisited. *Ophthalmology*. 1998;105(7):1331–1336. Part B courtesy of Ken K. Nischal, MD.)





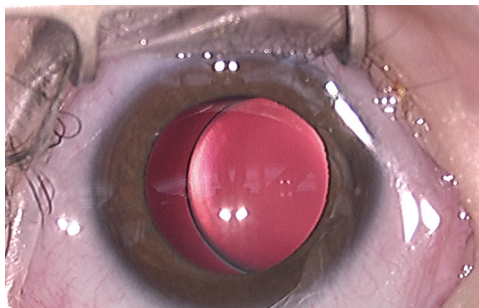
**Figure 23-9** Long, slender digits in a patient with Marfan syndrome. (Reproduced with permission from Lueder GT. Pediatric Practice: Ophthalmology. New York: McGraw-Hill Education; 2010: 222.)

valve. The life expectancy of patients with Marfan syndrome is about half that of the normal population.

Ocular abnormalities occur in more than 80% of affected patients, with lens subluxation being the most common (Fig 23-10). In approximately 75% of cases, the lens is subluxated superiorly. Typically, the zonules that are visible are intact and unbroken. Examination of the iris usually shows iridodonesis and may reveal transillumination defects near the iris base. The pupil is small and dilates poorly. The corneal curvature is often decreased. The axial length is increased, and affected patients are frequently myopic. Retinal detachment can occur spontaneously, usually in the second and third decades of life.

### Homocystinuria

Homocystinuria is a rare autosomal recessive condition, occurring in approximately 1 in 100,000 births. The classic form is usually caused by mutations in the gene encoding cystathionine  $\beta$ -synthase, which causes homocysteine to accumulate in the plasma and to be excreted in the urine.



**Figure 23-10** Lens subluxation in a patient with Marfan syndrome. (Courtesy of Gregg T. Lueder, MD.)

The clinical manifestations of homocystinuria vary; the eye, skeletal system, central nervous system, and vascular system can be affected. Most of the abnormalities develop after birth and become progressively worse with age. The ophthalmologist may see patients with this disorder before the systemic diagnosis is made. The skeletal features are similar to those of Marfan syndrome. Affected patients are usually tall and have osteoporosis, scoliosis, and chest deformities. Central nervous system abnormalities occur in approximately 50% of patients; intellectual disability and seizures are the most common.

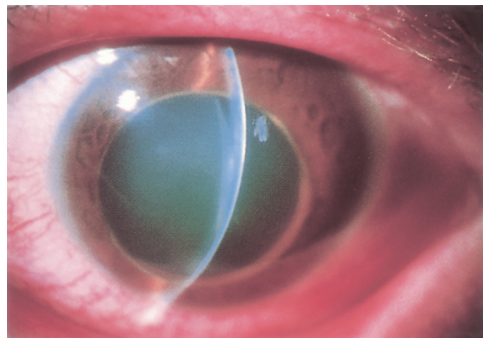
Vascular complications are common and secondary to thrombotic disease, which affects large or medium-sized arteries and veins anywhere in the body. Hypertension and cardiomegaly are also common. Anesthesia carries a higher risk for patients with homocystinuria because of thromboembolic phenomena; thus, this disorder should be identified before patients undergo general anesthesia.

The main ocular finding is lens subluxation, most frequently inferiorly, but the direction of subluxation is not diagnostic. Subluxation typically begins between the ages of 3 and 10 years. The lenses may dislocate into the anterior chamber, a finding suggestive of homocystinuria (Fig 23-11). The zonular fibers are frequently broken, in contrast with those in Marfan syndrome.

The diagnosis is confirmed by the detection of disulfides, including homocystine, in the urine. Medical management of homocystinuria is directed toward normalizing the biochemical abnormality. Dietary management (low-methionine diet and supplemental cysteine) may be attempted. Supplementation with the coenzyme pyridoxine (vitamin B<sub>6</sub>) diminishes systemic problems in approximately 50% of cases.

### Weill-Marchesani Syndrome

Patients with Weill-Marchesani syndrome can be thought of as clinical opposites of patients with Marfan syndrome in that the former are characteristically short, with brachydactyly and short limbs. Inheritance can be autosomal dominant or recessive. Mutations in the *ADAMTS10* gene have been identified in patients with this disorder. The lenses are microspherophakic. With time, the lenses may dislocate into the anterior chamber and cause pupillary block glaucoma. For this reason, prophylactic laser peripheral iridectomy or lensectomy may be indicated.



**Figure 23-11** Homocystinuria. The lens may dislocate into the anterior chamber and cause acute pupillary block glaucoma.

### **Sulfite Oxidase Deficiency**

Sulfite oxidase deficiency (molybdenum cofactor deficiency) is a very rare hereditary disorder of sulfur metabolism manifested by severe neurologic disorders and ectopia lentis. The enzyme deficiency interferes with conversion of sulfite to sulfate, resulting in increased excretion of sulfite in the urine. The diagnosis can be confirmed by the absence of sulfite oxidase activity in skin fibroblasts. Neurologic abnormalities include infantile hemiplegia, choreoathetosis, and seizures. Irreversible brain damage and death usually occur by 5 years of age.

### **Treatment**

#### ***Optical correction***

Optical correction of the refractive error caused by lens dislocation is often difficult. With mild subluxation, the patient may be only myopic, and corrected visual function may be good. More severe dislocation causes optical distortion, because the patient is looking through the far periphery of the lens. Because the resultant myopic astigmatism is difficult to measure accurately by retinoscopy or automated refractometry, using an aphakic correction may provide the patient with better vision, as long as the subluxated lens does not fill the pupillary space. Refraction before and after pupil dilation is often helpful for selecting the best type of optical correction. If satisfactory visual function cannot be achieved with glasses or if visual function worsens, lens removal should be considered.

#### ***Surgery***

Subluxated lenses can be removed either from the anterior segment through a limbal incision or posteriorly through the pars plana. In most circumstances, complete lensectomy is indicated. Lens removal is easier when the lens is not severely subluxated.

In the United States, contact lenses or glasses are usually used for postoperative vision rehabilitation, with good visual results. Anterior chamber or scleral-fixated IOLs are sometimes implanted. The latter should be used with caution if sutures are used for fixation because of the high rate of suture breakage. Iris-claw lenses (Artisan; OPHTEC BV, Groningen, the Netherlands) are widely used in other countries and are currently under investigation in the United States.

# Uveitis in the Pediatric Age Group

*Uveitis* is broadly defined as inflammation of the uvea, including the iris, ciliary body, and choroid. See BCSC Section 9, *Uveitis and Ocular Inflammation*, for a more detailed description of the clinical features and inflammatory mechanisms of the conditions discussed in this chapter.

## Epidemiology

---

The prevalence of pediatric uveitis varies among studies, with pediatric cases accounting for 2%–14% of all uveitis cases. The distribution between the sexes is similar to that of uveitis in adults, showing a slight female preponderance. The mean age at diagnosis is 8–9 years, and 75% of patients have bilateral disease. In the United States, approximately 62% of pediatric patients with uveitis are white. The 2 major etiologies of uveitis in children are idiopathic (25%–54% of cases) and juvenile idiopathic arthritis (15%–47% of cases). Most types of uveitis are not inherited.

## Classification

---

As in adults, uveitis in children can be classified according to several factors, including anatomical location, pathology (granulomatous or nongranulomatous), course (acute, chronic, or recurrent), or etiology (traumatic, immunologic, infectious [exogenous or endogenous], masquerade, or idiopathic). This chapter categorizes and describes uveitic entities using the basic anatomical classification of uveitis into 4 groups: anterior, intermediate, posterior, and panuveitis. Anatomical location of the uveitis can be helpful in determining etiology (Table 24-1). Results of a recent claims-based study of uveitis in the United States showed that anterior uveitis accounted for 75% of pediatric uveitis cases, with posterior uveitis and panuveitis accounting for the remaining 25%.

Thorne JE, Suhler E, Skup M, et al. Prevalence of noninfectious uveitis in the United States: a claims-based analysis. *JAMA Ophthalmol*. 2016;134(11):1237–1245.

**Table 24-1 Differential Diagnosis of Uveitis in Children****Anterior uveitis**

Juvenile idiopathic arthritis  
 Trauma  
 Sarcoidosis  
 Tuberculosis  
 Syphilis  
 Lyme disease  
 Herpes virus  
 Kawasaki disease  
 Tubulointerstitial nephritis and uveitis syndrome  
 Behçet disease  
 Inflammatory bowel disease  
 Granulomatosis with polyangiitis (Wegener granulomatosis)  
 Nonspecific orbital inflammation (orbital pseudotumor)  
 Idiopathic anterior uveitis

**Intermediate uveitis**

Sarcoidosis  
 Tuberculosis  
 Syphilis  
 Lyme disease  
 Multiple sclerosis  
 Idiopathic intermediate uveitis (pars planitis)

**Posterior uveitis and panuveitis**

Toxoplasmosis  
 Toxocariasis  
 Sarcoidosis  
 Tuberculosis  
 Syphilis  
 Lyme disease  
 Herpes virus  
 Rubella or measles  
 Sympathetic ophthalmia  
*Bartonella henselae* infection (cat-scratch disease)  
*Candida albicans* infection  
 Familial juvenile systemic granulomatosis (Blau syndrome)  
 Diffuse unilateral subacute neuroretinitis  
 Vogt-Koyanagi-Harada syndrome  
 Behçet disease  
 Idiopathic posterior uveitis or panuveitis

## Anterior Uveitis

Anterior uveitis primarily involves inflammation of the iris and ciliary body. When the anterior chamber is the primary site where inflammation is observed, the term *iritis* may be used for this inflammation. When inflammation is also observed in the anterior vitreous, the term *iridocyclitis* may be used.

### Juvenile Idiopathic Arthritis

*Juvenile idiopathic arthritis (JIA)* (formerly, *juvenile rheumatoid arthritis*) is the most common identifiable etiology of childhood anterior uveitis. JIA is defined as arthritis of at least

**Table 24-2 Subtypes of Juvenile Idiopathic Arthritis**

- 
- I. Systemic arthritis
  - II. Pauciarticular arthritis
  - III. Polyarticular arthritis
  - IV. Spondyloarthritis
    - A. Enthesitis-related arthritis
    - B. Juvenile psoriatic arthritis
    - C. Juvenile ankylosing spondylitis
    - D. Enteropathic arthritis
    - E. Reactive arthritis
    - F. Undifferentiated spondyloarthritis
  - V. Undifferentiated arthritis
- 

6 weeks' duration without an identifiable cause in children younger than 16 years. There are several subtypes of JIA, which are listed in Table 24-2.

Overall, the prevalence of uveitis in JIA varies from 2% to 34%. The subtypes of JIA that are particularly associated with uveitis are pauciarticular (oligoarthritis), polyarticular, psoriatic arthritis, and enthesitis-related arthritis. Uveitis almost never occurs in children with systemic arthritis and is very rare in those with rheumatoid factor–positive polyarticular subtype. In contrast to most forms of anterior uveitis, the uveitis associated with pauciarticular JIA and polyarticular JIA is initially asymptomatic. It has been described as “white iritis” because of the absence of a red eye. Screening for uveitis among children with JIA is therefore of great importance.

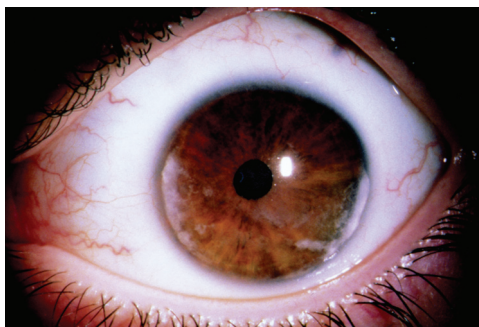
*Pauciarticular* is the most frequent type of JIA in children in North America and Europe. By definition, pauciarticular JIA affects 4 or fewer joints during the first 6 months of the disease. It occurs predominantly in young girls. Anterior uveitis is most likely to occur with this type of arthritis, developing in 10%–30% of patients. Laboratory markers include a high prevalence of antinuclear antibodies (ANA). Rheumatoid factor is almost always absent.

Children with *polyarticular* JIA show involvement of more than 4 inflamed joints during the first 6 months of the disease. This disease is more common in girls, and the mean age at onset is higher compared with pauciarticular JIA. Uveitis occurs in approximately 10% of these children. Affected patients may have a positive ANA test result, which is associated with an increased risk of uveitis. Human leukocyte antigen (HLA) associations have not been consistently documented.

The pathogenesis of the anterior uveitis associated with JIA is unknown, but it is likely to have an immunologic basis. The risk for development of uveitis is highest during the first 4 years after diagnosis of JIA. Among patients with JIA, 90% of uveitis cases develop within 7 years of onset of arthritis. Occasionally, uveitis is diagnosed before or at the onset of joint symptoms; in these cases, unfortunately, the prognosis is often poorer because the initially asymptomatic nature of the ocular inflammation often delays diagnosis and thus treatment. A shorter interval between the onset of arthritis and uveitis is also associated with a more aggressive course.

JIA-associated uveitis is usually bilateral and nongranulomatous with fine to medium-sized keratic precipitates, but a minority of children, especially African Americans, may

**Figure 24-1** Slit-lamp photograph from a patient with uveitis associated with juvenile idiopathic arthritis (JIA). As is typical in pauciarticular or polyarticular JIA, the conjunctiva is “white.” Band keratopathy is present. (Courtesy of Amy Hutchinson, MD.)



have granulomatous precipitates. Chronic inflammation may produce band keratopathy (Fig 24-1), posterior synechiae, ciliary membrane formation, hypotony, cataract, glaucoma, and phthisis. Vitritis and macular edema occur infrequently.

### Screening for uveitis

Recognition of the importance of screening for uveitis in children with JIA has resulted in an improved prognosis for this disorder. However, visual impairment has been reported in up to 40% of children with JIA-associated uveitis, and blindness may occur in as many as 10% of affected eyes. Screening guidelines continue to undergo revision but are based on 4 factors that are associated with an increased risk of uveitis:

- category of arthritis
- age at onset of arthritis
- presence of ANA positivity
- duration of the disease

Table 24-3 outlines the eye examination schedule for pauciarticular and polyarticular JIA, as recommended by the American Academy of Pediatrics. After 4 years, the eye

**Table 24-3 Frequency of Eye Examination in Patients With Pauciarticular or Polyarticular JIA**

Age at Onset of JIA, y	Duration of Disease, y	Eye Examination Frequency (mo) for ANA-Positive, ANA-Negative Patients	
		ANA+	ANA-
≤6	≤4	3	6
≤6	>4 to ≤7	6	12
≤6	>7	12	12
>6	≤4	6	12
>6	>4	12	12

ANA=antinuclear antibody; JIA=juvenile idiopathic arthritis.

Frequencies are for the first 4 years after diagnosis.

Information from Cassidy J, Kivlin J, Lindsley C, Nocton J; Section on Rheumatology; Section on Ophthalmology. Ophthalmologic examinations in children with juvenile rheumatoid arthritis. *Pediatrics*. 2006;117(5):1844.

examinations become less frequent. Although female sex is associated with a higher incidence of uveitis, this factor is not incorporated in the guidelines. Initial ophthalmologic examination should occur within 6 weeks of diagnosis.

### Juvenile Spondyloarthropathies

Juvenile spondyloarthropathies are a group of HLA-B27–associated disorders and are associated with uveitis in 25% of affected individuals. Boys are more commonly affected than girls, and the disease onset is usually in early adolescence. There are differentiated and undifferentiated forms. Differentiated types include enthesitis-related arthritis, juvenile ankylosing spondylitis, juvenile psoriatic arthritis, reactive arthritis, and the arthritis associated with inflammatory bowel disease (enteropathic) (Table 24-4). A unifying feature of the differentiated forms is enthesitis, an inflammation of the sites where the ligaments, tendons, and joint capsules attach to bone. Enthesitis most commonly affects the insertions of the patellar ligament at the inferior patella, plantar fascia at the calcaneus, and the Achilles tendon. Asymmetric lower-extremity oligoarthritis with involvement of the hips and midfoot is highly suggestive of the disease.

The anterior uveitis associated with juvenile spondyloarthropathies usually has an acute onset with photophobia, pain, and a red eye.

Gmuca S, Weiss PF. Juvenile spondyloarthritis. *Curr Opin Rheumatol*. 2015;27(4):364–372.

**Table 24-4 Types of Juvenile Spondyloarthropathies**

Type	Additional Systemic Manifestations	Uveitis Prevalence and Characteristics
Enthesitis-related arthritis	None	Occurs in 20% of affected children Acute, symptomatic Unilateral, but both eyes may be affected at different times
Juvenile psoriatic arthritis	Nail changes (pitting or onycholysis), dactylitis, psoriasis	Occurs in 10% of affected children Insidious and chronic anterior uveitis Usually bilateral
Juvenile ankylosing spondylitis	Involves the spine Sacroiliitis, which may be subclinical Cardiac disease rare in children	Occurs in 20%–30% of those affected Acute, symptomatic Unilateral, but both eyes may be affected at different times
Enteropathic arthritis	Crohn disease, ulcerative colitis	Occurs in 5% of those affected
Reactive arthritis	Follows an infection not involving the joints Urethritis	Occurs in 12% of those affected Acute, symptomatic Unilateral and recurrent anterior uveitis Conjunctivitis may also be present



### Tubulointerstitial Nephritis and Uveitis Syndrome

Tubulointerstitial nephritis and uveitis (TINU) syndrome is kidney disease associated with chronic or recurrent anterior uveitis in adolescents. The median age at onset is 15 years. The renal disease is characterized by low-grade fever, fatigue, pallor, and weight loss. Elevated levels of  $\beta_2$ -microglobulin are usually present in the urine. The uveitis is usually bilateral and may occur before, simultaneously with, or after the renal disease. The prognosis is generally good, but long-term follow-up is required because the inflammation may recur.

### Kawasaki Disease

Kawasaki disease, also known as *mucocutaneous lymph node syndrome*, is a primary vasculitis mediated by immunoglobulin (Ig) A affecting children younger than 5 years. Abnormalities include fever, conjunctival injection, mucous membrane changes, extremity changes involving the skin, rash, and cervical lymphadenopathy. The most significant complication of Kawasaki disease is coronary artery aneurysm, which occurs in 15%–25% of untreated children. Treatment with aspirin and intravenous IgG reduces the incidence of coronary artery aneurysm formation. After conjunctivitis, a generally self-limited anterior uveitis during the acute phase of the illness is the second most common ocular finding, occurring in approximately 10% of cases.

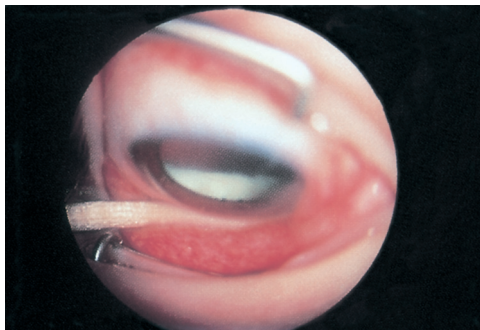
### Other Causes of Anterior Uveitis

Many cases of anterior uveitis are idiopathic or are caused by trauma. Other causes include a variety of infectious and noninfectious diseases (see Table 24-1).

### Intermediate Uveitis

The term *intermediate uveitis* is an anatomically based description of the primary site of the ocular inflammation. The inflammation is localized to the vitreous base overlying the ciliary body, pars plana, and peripheral retina, as well as the anterior vitreous (Fig 24-2). Intermediate uveitis accounts for 12%–28% of uveitis cases in the pediatric age group. In children, it may occur with various conditions, including sarcoidosis, syphilis, Lyme disease, multiple sclerosis, and tuberculosis. Idiopathic disease, known as *pars planitis*, accounts for 85%–90% of cases.

**Figure 24-2** Intermediate uveitis with inferior snowbank formation (inflammatory exudative accumulation on the inferior pars plana ["snow bank"]), right eye.



## Posterior Uveitis

*Posterior uveitis* is defined as intraocular inflammation primarily involving the choroid; often, there is also retinal involvement.

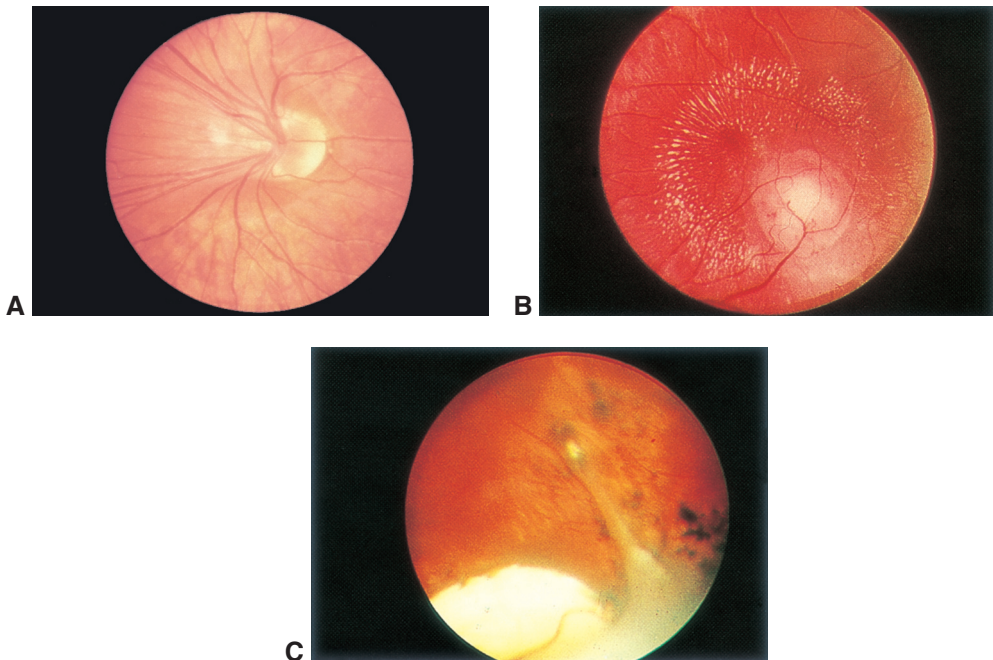
### Toxoplasmosis

Toxoplasmosis is the most common cause of posterior uveitis in children. It is discussed in Chapter 28.

### Toxocariasis

Ocular toxocariasis is caused by the nematode larvae of a common intestinal parasite of dogs (*Toxocara canis*) or cats (*Toxocara cati*). This disease, contracted through ingestion of ascarid ova in soil contaminated by dog or cat feces, primarily affects children. *Visceral larva migrans (VLM)* is an acute systemic infection produced by these organisms; it commonly occurs at approximately age 2 years. If symptomatic, it is associated with fever, cough, rashes, malaise, and anorexia. Laboratory testing reveals eosinophilia. VLM and ocular toxocariasis, for unknown reasons, seldom occur in the same patient.

Ocular toxocariasis is usually unilateral and is not associated with systemic illness or an elevated eosinophil count. The average age at onset is 11.5 years. The 3 major retinal forms of the disease include posterior pole granuloma, peripheral granuloma with macular traction (Fig 24-3), and endophthalmitis. There is often little external evidence of



**Figure 24-3** Toxocariasis. **A**, Distortion of posterior pole vessels, right eye. **B**, Fundus photograph showing macular granuloma. **C**, Fundus photograph of peripheral granuloma.

inflammation. Patients may present with leukocoria, strabismus, or decreased vision. These are also common presenting signs and symptoms of retinoblastoma, which must be differentiated from ocular toxocariasis. Because elevated *Toxocara* titers may be found in a significant percentage of children, a positive result on tests such as the enzyme-linked immunosorbent assay does not rule out other possibilities, including retinoblastoma.

Treatment includes observation of peripheral lesions, periocular or systemic steroids for posterior lesions and endophthalmitis, or surgical intervention to address retinal traction, cataract, glaucoma, or cyclitic membranes. Systemic anthelmintics are not useful in treating ocular toxocariasis because the organism may already be dead or its death can produce significant inflammation.

Woodhall D, Starr MC, Montgomery SP, et al. Ocular toxocariasis: epidemiologic, anatomic, and therapeutic variations based on a survey of ophthalmic subspecialists. *Ophthalmology*. 2012;119(6):1211–1217.

### Other Causes of Posterior Uveitis

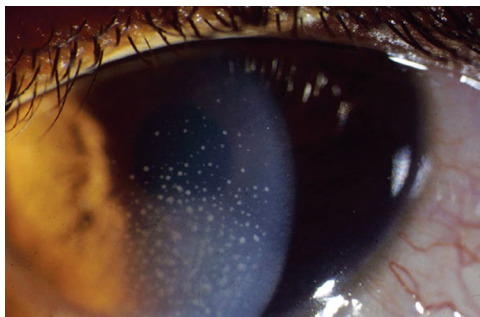
Other causes of posterior uveitis are listed in Table 24-1.

## Panuveitis

In panuveitis, inflammation is diffuse without a predominant site. Inflammation is observed in the anterior chamber, vitreous, and choroid.

### Sarcoidosis

Sarcoidosis may present in 2 distinct forms in children. In young patients (<5 years), lung disease is rare, and sarcoidosis is more often characterized by the triad of uveitis, granulomatous arthritis, and rash. Early-onset sarcoidosis is considered a *pediatric granulomatous arthritis* and is phenotypically and genetically similar to familial juvenile systemic granulomatosis (discussed in the following section). Older children (8–15 years) with sarcoidosis have the pulmonary abnormalities and lymph node findings more commonly associated with the adult form of the disease and are also at risk for uveitis. Although anterior uveitis (Fig 24-4) is the most common manifestation of ocular sarcoidosis in children, this disease can produce a panuveitis.



**Figure 24-4** Keratic precipitates in sarcoidosis.  
(Courtesy of Ken K. Nischal, MD.)

Diagnosis and treatment in children is similar to that in adults (see BCSC Section 9, *Uveitis and Ocular Inflammation*). However, serum angiotensin-converting enzyme levels, which may be abnormally elevated in patients with sarcoidosis, are normally higher in healthy children than in adults and thus can be misleading in diagnosis of this disease.

### **Familial Juvenile Systemic Granulomatosis**

Familial juvenile systemic granulomatosis (*Blau syndrome*) is an autosomal dominant disease that may be identical to early-onset sarcoidosis; both are classified as *pediatric granulomatous arthritides*. In both diseases, there are mutations in the nucleotide binding oligomerization domain containing 2 gene (*NOD2*) on chromosome 16; however, in Blau syndrome, other family members are affected. Both diseases present with granulomatous arthritis, uveitis, and rash during childhood, but pulmonary involvement and lymphadenopathy are absent in Blau syndrome. Chronic panuveitis associated with multifocal chorioiditis is the most common ocular presentation; in some cases, the uveitis may be limited to the anterior segment and the disease misdiagnosed as JIA. Ocular complications, including cataract, glaucoma, band keratopathy, and vision loss, are common.

### **Vogt-Koyanagi-Harada Syndrome**

Vogt-Koyanagi-Harada syndrome is a chronic, progressive bilateral panuveitis that is associated with exudative retinal detachments and may be accompanied by meningeal irritation, auditory disturbances, and skin changes. It is rare in children, but in those affected, the rate of ocular complications such as cataract and glaucoma is higher and the visual prognosis poorer compared with that for adults. For further discussion, see BCSC Section 9, *Uveitis and Ocular Inflammation*.

### **Other Causes of Panuveitis**

Other causes of panuveitis are listed in Table 24-1.

## **Masquerade Syndromes**

---

Various conditions can simulate pediatric uveitis. Table 24-5 lists these masquerade syndromes and their diagnostic features.

## **Evaluation of Pediatric Uveitis**

---

Establishing the correct diagnosis is important in managing a pediatric patient with uveitis, but some ophthalmologists defer the workup of isolated anterior uveitis unless it is recurrent or unresponsive to initial therapy. Accurate diagnosis requires a detailed history, thorough ophthalmic examination, and selected laboratory tests. An examination under anesthesia may be necessary if the child is not cooperative enough for an office evaluation. Laboratory investigations are chosen based on the suspected diagnoses (Table 24-6; see also Table 24-5).

**Table 24-5 Uveitis Masquerade Syndromes in Children**

Disease or Condition	Age, y	Signs of Inflammation	Examination/Diagnostic Studies
<b>Anterior segment</b>			
Retinoblastoma	<15	Flare, cells, pseudohypopyon	Ultrasonography, MRI
Leukemia	<15	Flare, cells, hypopyon, heterochromia, hyphema	Bone marrow biopsy, peripheral blood smear
Intraocular foreign body	Any age	Flare, cells	X-ray, CT, ultrasonography
Malignant melanoma	Any age	Flare, cells	Fluorescein angiography, ultrasonography, OCT
Juvenile xanthogranuloma	<15	Flare, cells, hyphema	Examination of skin, iris biopsy
Peripheral retinal detachment	Any age	Flare, cells	Ophthalmoscopy
<b>Posterior segment</b>			
Retinitis pigmentosa	Any age	Cells in vitreous, waxy disc pallor, bone-spicule pigmentary changes in midperiphery	ERG, visual fields
Systemic lymphoma	≥15	Retinal hemorrhage or exudates, vitreous cells	Node biopsy, bone marrow biopsy, physical examination
Retinoblastoma	<15	Vitreous cells, retinal exudates	Ultrasonography, MRI
Malignant melanoma	≥15	Vitreous cells	Fluorescein angiography, ultrasonography, OCT
Multiple sclerosis	≥15	Periphlebitis, pars planitis	Neurologic examination

CT = computed tomography; ERG = electroretinogram; MRI = magnetic resonance imaging; OCT = optical coherence tomography.

## Treatment of Pediatric Uveitis

The goals of treatment of uveitis in children are to eliminate the inflammation of the eye before ocular complications occur and to monitor for ocular and systemic adverse effects of the treatment. It is important to note that although the presence of cells in the anterior chamber indicates active inflammation, flare (protein) may persist long after the inflammation has been successfully treated.

Infectious diseases and malignancies producing uveitis should be identified and treated appropriately. Treatment of noninfectious uveitis is discussed in the following sections.

### Management of Inflammation

Anterior segment inflammation is initially treated with topical corticosteroid and mydriatic/cycloplegic agents. Because topical corticosteroids do not penetrate well into the vitreous or posterior segment, sub-Tenon injections of a corticosteroid may be useful in the treatment of intermediate or posterior uveitis. Short courses of oral corticosteroids may be used, but

**Table 24-6 Laboratory Tests and Imaging for Various Types of Uveitis****Anterior uveitis**

Antinuclear antibody (JIA)  
 ACE, lysozyme (sarcoidosis)  
 Chest x-ray (sarcoidosis, tuberculosis)  
 Tuberculin skin test, interferon- $\gamma$  release assay (tuberculosis)  
 FTA-ABS (syphilis)  
 Lyme serology (Lyme disease)  
 Complete blood count (leukemia)  
 HLA-B27 and sacroiliac joint films (enthesitis-related arthritis, ankylosing spondylitis)  
 Gastrointestinal series (if ulcerative colitis or regional enteritis [Crohn disease] is suspected)  
 Urinalysis, blood urea nitrogen, serum creatinine, urine  $\beta_2$ -microglobulin (TINU syndrome)  
 Antineutrophil cytoplasmic antibody (granulomatosis with polyangiitis)

**Intermediate uveitis**

ACE, lysozyme (sarcoidosis)  
 Chest x-ray (sarcoidosis, tuberculosis)  
 Tuberculin skin test, interferon- $\gamma$  release assay (tuberculosis)  
 FTA-ABS (syphilis)  
 Lyme serology (Lyme disease)

**Posterior uveitis and panuveitis**

Toxoplasmosis PCR, ELISA  
 Toxocariasis PCR, ELISA  
 ACE, lysozyme (sarcoidosis)  
 Chest x-ray (sarcoidosis, tuberculosis)  
 Tuberculin skin test, interferon- $\gamma$  release assay (tuberculosis)  
 FTA-ABS (syphilis)  
 Lyme serology (Lyme disease)  
 PCR, blood cultures, viral cultures, or antibody levels (if cytomegalovirus, herpes simplex, herpes zoster, rubella, measles, or *Bartonella henselae* infection is suspected)

---

ACE = angiotensin-converting enzyme; ELISA = enzyme-linked immunosorbent assay; FTA-ABS = fluorescent treponemal antibody absorption; HLA = human leukocyte antigen; JIA = juvenile idiopathic arthritis; PCR = polymerase chain reaction; TINU = tubulointerstitial nephritis and uveitis.

long-term use is usually avoided because of the potential for significant ocular and systemic adverse effects. Corticosteroid intravitreal implants containing either fluocinolone acetonide or dexamethasone have been used successfully to treat posterior uveitis in children.

Glaucoma and cataract formation are the most serious ocular complications of any corticosteroid therapy. In general, more potent topical corticosteroids are more likely to increase intraocular pressure. Periocular injections of corticosteroids can elevate intraocular pressure for weeks to months after injection. Cataracts and glaucoma are reported adverse effects of intravitreal steroid implants. Risks of long-term systemic corticosteroid use in children include growth retardation, osteoporosis and bone fractures, cushingoid appearance, diabetes mellitus, peptic ulcers, myopathy, hypertension, altered mental status, idiopathic intracranial hypertension, and increased risk of infection. Patients may also require increased doses of corticosteroids during times of stress to avoid an Addisonian crisis.

Systemic immunosuppressive therapy is beneficial in treating both uveitis and arthritis. It can sometimes reduce or eliminate the need for steroids. The therapy should be

undertaken in cooperation with a pediatric specialist familiar with the use of immunosuppressive and immunomodulatory medications. In patients with JIA, immunosuppressive drugs reduce the risk of vision loss from uveitis.

Methotrexate is the most common antimetabolite used to treat arthritis and uveitis in children. Less commonly used antimetabolites include azathioprine and mycophenolate mofetil. These agents inhibit nucleic acid synthesis by a variety of mechanisms. Gastrointestinal disturbance is the most common adverse effect of oral methotrexate and can be alleviated by switching to subcutaneous injections. Oral folic acid supplementation is often recommended for patients using methotrexate. Hepatic toxicity, interstitial pneumonitis, and cytopenia are rare but serious adverse effects of methotrexate use.

Biologic drugs for the treatment of uveitis are used with increasing frequency to suppress the immune system in children. The 2 classes of biologic medications are tumor necrosis factor  $\alpha$  (TNF- $\alpha$ ) inhibitors and cell-specific antibodies. The TNF- $\alpha$  inhibitors most commonly used to treat uveitis are infliximab and adalimumab, which are monoclonal IgG antibodies against TNF- $\alpha$ . Commonly used cell-specific antibodies include abatacept (antibody to CD80 and CD86) and rituximab (antibody to interleukin-2). Etanercept should be avoided because new-onset inflammatory eye disease (uveitis, scleritis, optic neuritis) has been associated with its use, caused by poor drug efficacy and/or adverse effect of the drug. In general, TNF- $\alpha$  inhibitors are used before cell-specific antibodies. TNF- $\alpha$  inhibitors should not be used during periods of active infection. All these biologic drugs used to treat uveitis require intravenous infusion, except for adalimumab, which can be given subcutaneously. There is concern that children and adolescents treated with TNF- $\alpha$  blockers may be at increased risk for malignancies; however, a recent study showed that children with JIA are at increased risk for malignancies unrelated to the use of biologic drugs.

Beukelman T, Haynes K, Curtis JR, et al; Safety Assessment of Biological Therapeutics Collaboration. Rates of malignancy associated with juvenile idiopathic arthritis and its treatment. *Arthritis Rheum.* 2012;64(4):1263–1271.

Gregory AC II, Kempen JH, Daniel E, et al; Systemic Immunosuppressive Therapy for Eye Diseases Cohort Study Research Group. Risk factors for loss of visual acuity among patients with uveitis associated with juvenile idiopathic arthritis: the Systemic Immunosuppressive Therapy for Eye Diseases Study. *Ophthalmology.* 2013;120(1):186–192.

Klotsche J, Niewerth M, Haas JP. Long-term safety of etanercept and adalimumab compared to methotrexate in patients with juvenile idiopathic arthritis (JIA). *Ann Rheum Dis.* 2016;75(5):855–861.

Reiff A, Kadayifcilar S, Özen S. Rheumatic inflammatory eye diseases of childhood. *Rheum Dis Clin North Am.* 2013;39(4):801–832.

### **Surgical Treatment of Complications of Uveitis**

Complications of uveitis include band keratopathy, cataract, and glaucoma. Band keratopathy can be treated by removal of corneal epithelium, followed by calcium chelation with ethylenediaminetetraacetic acid (EDTA). Treatment may have to be repeated. Phototherapeutic keratectomy has also been used to treat band keratopathy.

Cataract surgery for patients with uveitis can be complicated by hypotony, glaucoma, synechiae formation, cystoid macular edema, and retinal detachment. In patients with JIA, combined lensectomy and vitrectomy seems to produce better results than cataract extraction alone. Uveitis must be aggressively treated so that it is under control both before and after surgery. Intraocular lens implantation is usually not considered in children with uveitis until after a prolonged period of quiescence.

Glaucoma surgery may become necessary in children with uveitis. Many techniques have been used, and long-term success rates vary. Standard trabeculectomy is associated with a high rate of failure due to scarring. Goniotomy or trabeculotomy is effective in many children and can be the initial surgery if the anterior chamber angle is visible. Tube shunts can be used when goniotomy fails or if the angle is closed.

Bohnsack BL, Freedman SF. Surgical outcomes in childhood uveitic glaucoma. *Am J Ophthalmol.* 2013;155(1):134–142.





## CHAPTER 25

# Disorders of the Retina and Vitreous



*This chapter includes related videos, which can be accessed by scanning the QR codes provided in the text or going to [www.aao.org/bcscvideo\\_section06](http://www.aao.org/bcscvideo_section06).*

This chapter focuses on retinal diseases that are most often diagnosed in the first 2 decades of life. These include retinopathy of prematurity, Leber congenital amaurosis, and retinoblastoma. Many of the topics covered in this chapter are also discussed in BCSC Section 12, *Retina and Vitreous*. See BCSC Section 4, *Ophthalmic Pathology and Intraocular Tumors*, for detailed discussion of tumors.

## Congenital and Developmental Abnormalities

---

### Persistent Fetal Vasculature

Persistent fetal vasculature is covered in Chapter 23.

### Retinopathy of Prematurity

Retinopathy of prematurity (ROP) is a vasoproliferative retinal disorder unique to premature infants. First described in the 1950s, ROP is a leading cause of childhood blindness in the United States, second only to cerebral visual impairment.

### Pathophysiology

Retinal vascularization begins during week 16 of gestation. Mesenchymal tissue (the source of retinal vessels) grows centrifugally from the optic disc, reaching the nasal ora serrata by 36 weeks' gestation and the temporal ora serrata by 40 weeks' gestation. ROP results from abnormal growth of these retinal blood vessels in premature infants because of a complex interaction between vascular endothelial growth factor (VEGF) and insulin-like growth factor I (IGF-I). The pathophysiology of ROP is currently thought of as a 2-phase process and is outlined in Table 25-1.

### Classification

The International Classification of Retinopathy of Prematurity (ICROP) describes the disease by location (zone), stage, and extent (Table 25-2; Figs 25-1 through 25-5). Higher stage numbers and lower zone numbers indicate more severe ROP.

**Table 25-1 Interaction Between VEGF and IGF-I in Development of ROP****Phase I**

- Occurs at 22–30 weeks' gestational age
- Retina is hyperoxic (relative to intrauterine oxygen levels)
- VEGF levels are low
- Retinal blood vessels stop growing; this arrested growth is
  - worsened by high oxygen levels
  - worsened by low levels of IGF-I
  - correlated with poor weight gain

**Phase II**

- Occurs at 31–44 weeks' gestational age
- Avascular retina is hypoxic
- VEGF levels rise (due to the hypoxic avascular retina)
- Neovascularization occurs

**Treatment of ROP**

- Laser therapy destroys hypoxic avascular retina, so VEGF levels fall
- Bevacizumab inhibits VEGF

---

IGF-I = insulin-like growth factor I; ROP = retinopathy of prematurity; VEGF = vascular endothelial growth factor.

*Plus disease* refers to marked arteriolar tortuosity and venous engorgement of the posterior pole vasculature and is diagnosed by comparison with a standard photograph. It implies vascular shunting through the new vessels and signifies severe disease (Fig 25-6). *Pre-plus disease* refers to dilatation and tortuosity that are abnormal but less than that seen in the standard photograph (Fig 25-7).

*Aggressive posterior ROP* (AP-ROP; formerly known as *Rush disease*) is a severe form of ROP defined as zone I or posterior zone II disease, associated with plus disease involving all 4 quadrants of the posterior pole retinal vessels, shunt vessels, and flat neovascularization at the junction between vascularized and avascular retina. Without treatment, AP-ROP typically progresses quickly to stage 4 or 5 ROP (Fig 25-8).

The Cryotherapy for Retinopathy of Prematurity (CRYO-ROP) trial defined *threshold disease* as 5 contiguous or 8 total clock-hours of stage 3 ROP in zone I or II in the presence of plus disease. The Early Treatment for Retinopathy of Prematurity (ETROP) trial defined *prethreshold disease* as all zone I and zone II ROP changes that do not meet threshold treatment criteria, except for zone II stage 1 and zone II stage 2 without plus disease. ETROP further divided prethreshold ROP into *type 1* and *type 2* disease to delineate which babies would benefit from treatment before the development of threshold disease (Table 25-3).

International Committee for the Classification of Retinopathy of Prematurity. The International Classification of Retinopathy of Prematurity revisited. *Arch Ophthalmol.* 2005;123(7):991–999.

**Risk factors for development of ROP**

Premature birth ( $\leq 30$  weeks' gestational age) and low birth weight ( $\leq 1500$  g) are the most significant risk factors for development of ROP. Excessive administration of supplemental

**Table 25-2 International Classification of Retinopathy of Prematurity**


---

**Location:** zones II and III based on convention rather than strict anatomy (see Fig 25-1)

*Zone I* (posterior pole): a circle centered on the optic disc with a radius equal to twice the distance from the center of the disc to the macula. Clinically, the temporal edge of zone I is visible with a 25 or 28 D lens, with the other edge of the field of view centered on the nasal disc margin

*Zone II:* a circle centered on the optic disc with a radius equal to the distance from the center of the optic disc to the nasal ora serrata

*Zone III:* residual crescent anterior to zone II

**Extent:** specified as hours of the clock as observer looks at each eye

**Stages**

*Stage 0:* immature vascularization, no ROP

*Stage 1:* presence of a demarcation line between vascularized retina posteriorly and avascular retina anteriorly (see Fig 25-2)

*Stage 2:* presence of a ridge with height and width, with or without small tufts of fibrovascular proliferation (“popcorn”) (see Fig 25-3)

*Stage 3:* ridge with extraretinal fibrovascular proliferation (see Fig 25-4)

- mild fibrovascular proliferation
- moderate fibrovascular proliferation
- severe fibrovascular proliferation

*Stage 4:* subtotal retinal detachment (see Fig 25-5)

- A. extrafoveal retinal detachment
- B. retinal detachment including fovea

*Stage 5:* total retinal detachment; open or closed funnel

**Plus disease:** venous dilatation and arteriolar tortuosity present in posterior pole retinal vessels in at least 2 quadrants of the retina; standard photograph used to define the minimum amount of vascular abnormalities necessary to make the diagnosis; plus symbol (+) added to ROP stage denotes presence of plus disease (eg, stage 3 + ROP)

**Pre-plus disease:** venous dilatation and arteriolar tortuosity in the posterior pole but not as severe as the vascular abnormalities seen in plus disease

**Aggressive posterior ROP:** zone I or posterior zone II ROP associated with plus disease involving all 4 quadrants of the posterior pole retinal vessels, shunt vessels, and flat neovascularization at the junction between vascularized and avascular retina. Without treatment, typically progresses quickly to stage 4 or 5 ROP. Was formerly known as *Rush disease*

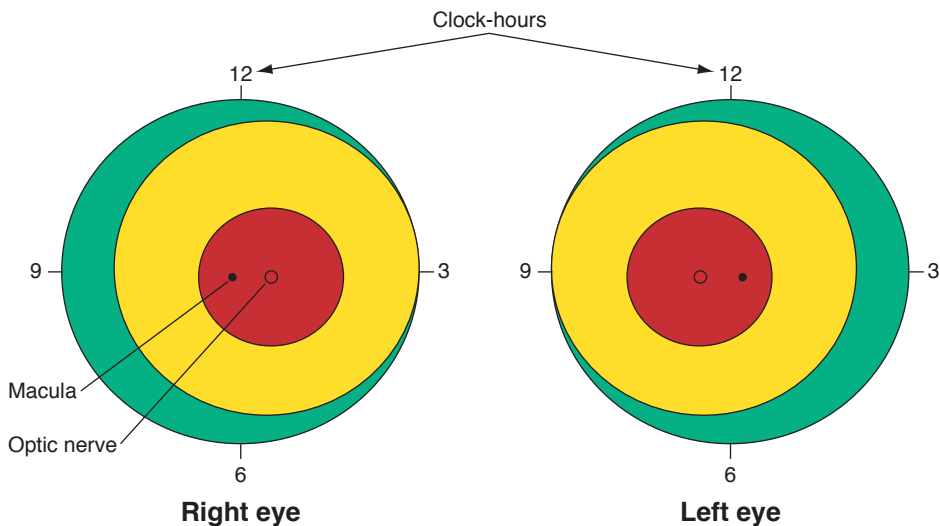
---

D = diopter.

Information from International Committee for the Classification of Retinopathy of Prematurity. The International Classification of Retinopathy of Prematurity revisited. *Arch Ophthalmol.* 2005;123(7):991–999.

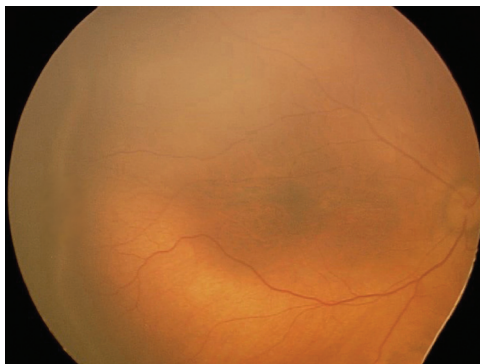
oxygen during the early postnatal period is also a risk factor for ROP development. Despite decades of research, however, the ideal amount of oxygen required by a premature infant remains unknown. Low target ranges of oxygen saturation have been associated with an increased risk of death and disability. Low levels of serum IGF-I are associated with poor postnatal weight gain and more severe ROP. Numerous algorithms using postnatal weight gain to identify infants at risk for type 1 ROP have been developed and are under investigation. African American preterm infants are at lower risk for needing ROP treatment.

BOOST-II Australia and United Kingdom Collaborative Groups; Tarnow-Mordi W, Stenson B, Kirby A, et al. Outcomes of two trials of oxygen-saturation targets in preterm infants. *N Engl J Med.* 2016;374(8):749–760.

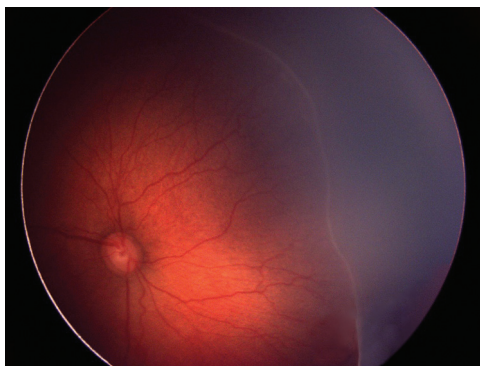


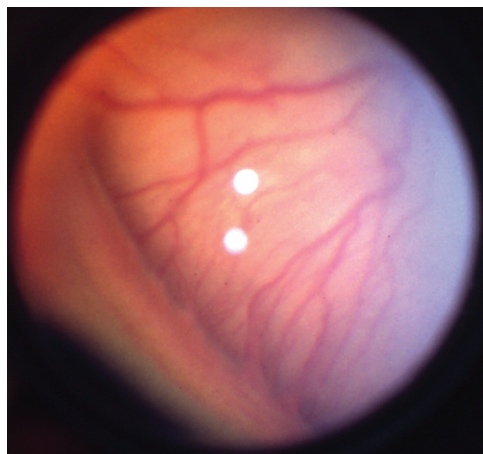
**Figure 25-1** Schematic of the retina of the right and left eyes, showing the area of zones I (red), II (yellow), and III (green), which are used to describe the location of retinopathy of prematurity (ROP). The extent of ROP is specified as hours of the clock.

**Figure 25-2** Stage 1 ROP. The demarcation line has no height. (Courtesy of Daniel Weaver, MD.)

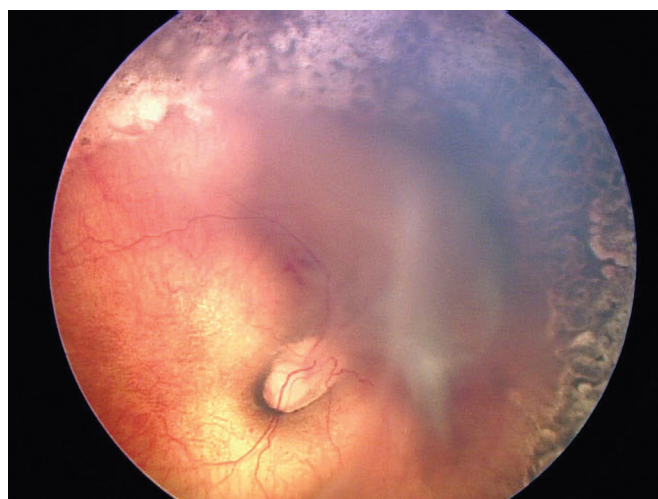


**Figure 25-3** Stage 2 ROP. The demarcation line has height and width, creating a ridge. (Courtesy of Andrea Molinari, MD.)





**Figure 25-4** Stage 3 ROP. Ridge with extra-retinal fibrovascular proliferation. (Reproduced with permission from Lueder GT. *Pediatric Practice Ophthalmology*. New York: McGraw-Hill; 2011:232.)



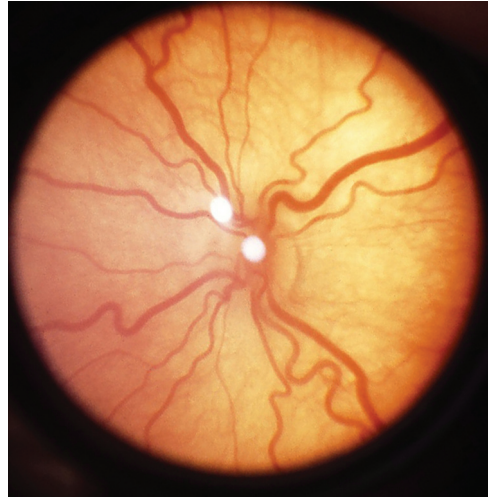**Figure 25-5** Subtotal extrafoveal retinal detachment in the right eye of a patient with stage 4A ROP treated with laser. (Courtesy of Robert W. Hered, MD.)

Saugstad OD, Aune D. Optimal oxygenation of extremely low birth weight infants: a meta-analysis and systematic review of the oxygen saturation target studies. *Neonatology*. 2014;105(1):55–63.

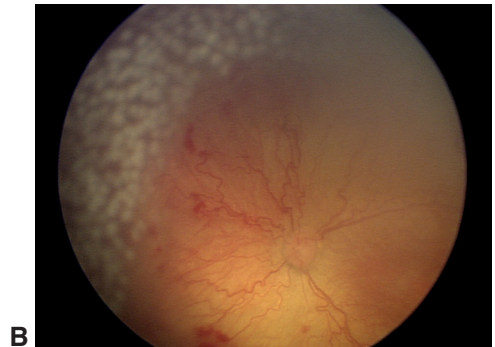
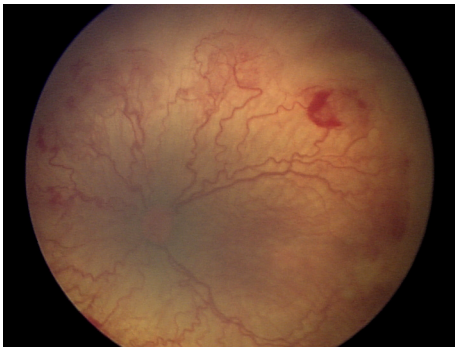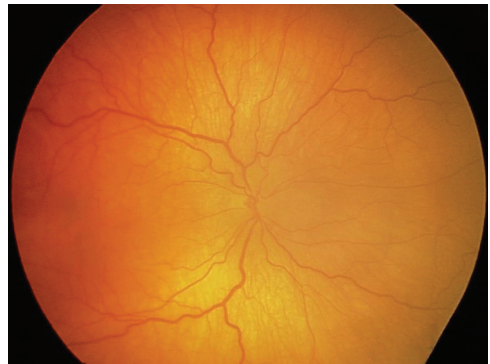### **Screening and diagnosis**

Current guidelines from the American Academy of Pediatrics, American Academy of Ophthalmology, and American Association for Pediatric Ophthalmology and Strabismus recommend that infants with gestational age of 30 weeks or less, birth weight of 1500 g or less, or a complicated clinical course be screened for ROP. The first examination should be performed at 4 weeks' chronologic (postnatal) age or at a corrected gestational age of 31 weeks, whichever is later (but not later than 6 weeks' chronologic age). Current screening

**Figure 25-6** Plus disease. (*Reproduced with permission from Lueder GT. Pediatric Practice Ophthalmology. New York: McGraw-Hill; 2011:231.*)



**Figure 25-7** Pre-plus disease. (*Courtesy of Daniel Weaver, MD.*)



**Figure 25-8** Aggressive posterior ROP, left eye, prior to treatment (A) and shortly after laser treatment (B). (*Courtesy of Robert W. Hered, MD.*)

**Table 25-3 ETROP Classification of ROP****Type 1**

- Zone I, any stage ROP with plus disease
- Zone I, stage 3 ROP without plus disease
- Zone II, stage 2 or 3 ROP with plus disease

**Type 2**

- Zone I, stage 1 or 2 ROP without plus disease
- Zone II, stage 3 ROP without plus disease

ETROP = Early Treatment for Retinopathy of Prematurity.

Modified from Wallace DK. Retinopathy of prematurity. *Focal Points: Clinical Modules for Ophthalmologists*. San Francisco: American Academy of Ophthalmology; 2008, module 12:p 4.

recommendations can be found on the website of the American Academy of Pediatrics (<http://pediatrics.aappublications.org/content/131/1/189>). In developing countries, ROP occurs in infants at an older gestational age and with a higher birth weight compared with infants in the United States. This suggests that screening criteria for ROP do not apply globally and should be modified in other regions of the world.

ROP examinations are performed after pharmacologic dilation of the pupils. Combination eyedrops of relatively low concentration (cyclopentolate 0.2% and phenylephrine 1%) are typically used. Sterile instruments should be used to examine the infant. A nurse should be present for examinations in the neonatal intensive care unit because an infant may experience apnea and bradycardia during examination. If an examination must be postponed, the postponement and medical reason should be documented in the patient's medical record. Suggested intervals for follow-up ophthalmic examinations for ROP without plus disease are given in Table 25-4; discontinuation of screening examinations is summarized in Table 25-5. Most ROP regresses spontaneously via involution.

Diagnosis of ROP via digital retinal photography and telemedicine is under investigation. It is currently being used in developing countries and areas where ophthalmologists are not available to perform ROP examinations.

- Fierson WM; American Academy of Pediatrics Section on Ophthalmology; American Academy of Ophthalmology; American Association for Pediatric Ophthalmology and Strabismus; American Association of Certified Orthoptists. Screening examination of premature infants for retinopathy of prematurity. *Pediatrics*. 2013;131(1):189–195.
- Vinekar A, Jayadev C, Mangalesh S, Shetty B, Vidyasagar D. Role of tele-medicine in retinopathy of prematurity screening in rural outreach centers in India—a report of 20,214 imaging sessions in the KIDROP program. *Semin Fetal Neonatal Med*. 2015;20(5):335–345.

### **Treatment**

Approximately 10% of infants examined for ROP require treatment. Several multicenter ROP trials have been influential in guiding treatment of the disease. The initial ROP treatment study, CRYO-ROP, recommended treatment with cryotherapy when the disease reached a certain level of severity, termed *threshold*. Current treatment guidelines



**Table 25-4 Recommended Intervals of Follow-up Eye Examinations for ROP Without Plus Disease****1 Week or Less**

Immature vascularization: zone I or posterior zone II  
 Stage 1 or 2 ROP: zone I  
 Stage 3 ROP: zone II  
 Presence or suspected presence of aggressive posterior ROP

**1 to 2 Weeks**

Immature vascularization: posterior zone II  
 Stage 2 ROP: zone II  
 Unequivocally regressing ROP: zone I

**2 Weeks**

Stage 1 ROP: zone II  
 Immature vascularization: zone II  
 Unequivocally regressing ROP: zone II

**2 to 3 Weeks**

Stage 1 or 2 ROP: zone III  
 Regressing ROP: zone III

Information from Fierson WM; American Academy of Pediatrics Section on Ophthalmology; American Academy of Ophthalmology; American Association for Pediatric Ophthalmology and Strabismus; American Association of Certified Orthoptists. Screening examination of premature infants for retinopathy of prematurity. *Pediatrics*. 2013;131(1):189–195.

**Table 25-5 Criteria for Discontinuation of ROP Screening Examinations<sup>a</sup>**

Fully vascularized retina  
 Zone III vascularization without previous zone I or II ROP  
 Lack of development of prethreshold or worse ROP by 50 weeks' postmenstrual age  
 Regression of ROP in zone III without abnormal vascular tissue capable of reactivation in zone II or III

<sup>a</sup>May consider discontinuation if any of the criteria are met. Applies to infants who did not require treatment.

Adapted from Shulman JP, Hobbs R, Hartnett ME. Retinopathy of prematurity: evolving concepts in diagnosis and management. *Focal Points: Clinical Modules for Ophthalmologists*. San Francisco: American Academy of Ophthalmology; 2015, module 1.

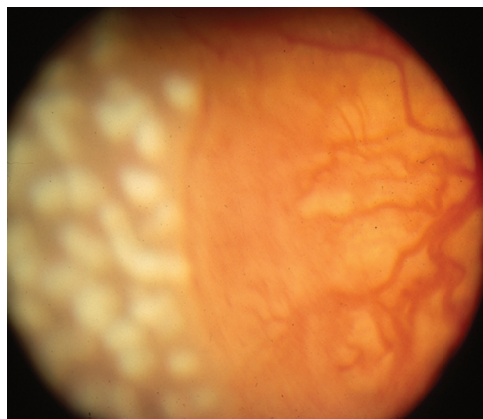
are based on results of the ETROP trial (see Table 25-3 for ETROP classification), which found that earlier treatment in prethreshold eyes classified as type 1 resulted in better structural and visual outcomes than did conventional treatment. Panretinal laser photocoagulation is performed to ablate the peripheral avascular retina (Fig 25-9). Current guidelines strongly recommend treatment for any eye with type 1 ROP. Eyes with type 2 ROP should be closely observed for progression to type 1 disease (Videos 25-1 through 25-4 show ROP progression and response to laser treatment).

**VIDEO 25-1** Stage 3 retinopathy of prematurity.

Courtesy of Leslie D. MacKeen, BSc, and Anna L. Ells, MD, FRCS(C). Dynamic documentation of the evolution of retinopathy of prematurity in video format. *J AAPOS*. 2008;12(4):349–351.

Access all Section 6 videos at [www.aao.org/bcscvideo\\_section06](http://www.aao.org/bcscvideo_section06).





**Figure 25-9** Laser photocoagulation applied anterior to avascular retina. Laser treatment should not be applied directly to the ridge. Note the thick band of neovascularization and plus disease. (Courtesy of Philip J. Ferrone, MD.)

AP-ROP typically occurs in zone I or posterior zone II, progresses rapidly, is often difficult to treat, and has a poor prognosis (see Table 25-2 and Fig 25-8). Another characteristic of AP-ROP is that it does not progress in the typical fashion (ie, through stages 1, 2, and 3), and stage 3 can often appear as flat neovascularization.



**VIDEO 25-2** Aggressive posterior retinopathy of prematurity with laser treatment.

Courtesy of Leslie D. MacKeen, BSc, and Anna L. Ells, MD, FRCS(C).  
*Dynamic documentation of the evolution of retinopathy of prematurity in video format.*  
 J AAPOS. 2008;12(4):349–351.



**VIDEO 25-3** Retinopathy of prematurity—the movie, 2.

Courtesy of Anna L. Ells, MD, FRCS(C), and Leslie D. MacKeen, BSc.  
*Retinopathy of prematurity—the movie.* J AAPOS. 2004;8(4):389.



**VIDEO 25-4** Retinopathy of prematurity—the movie, 7.

Courtesy of Anna L. Ells, MD, FRCS(C), and Leslie D. MacKeen, BSc.  
*Retinopathy of prematurity—the movie.* J AAPOS. 2004;8(4):389.



The most recent treatment option for type 1 ROP is intravitreal injection of anti-VEGF agents bevacizumab and ranibizumab. The initial study of anti-VEGF agents for treatment of ROP, and the most influential, was Bevacizumab Eliminates the Angiogenic Threat of Retinopathy of Prematurity (BEAT-ROP), which found a significant benefit to structural outcome for zone I eyes that received intravitreal bevacizumab monotherapy compared with those that received laser treatment. Subsequent publications have documented that ROP may recur months after treatment with anti-VEGF agents; thus, prolonged surveillance and re-treatment may be necessary after intravitreal anti-VEGF injections. Anti-VEGF treatment should not be administered to infants who are unlikely to return for frequent follow-up examinations after they are discharged from the hospital.

There is concern that antiangiogenic drugs' effects on the developing vasculature in other areas of the body may lead to adverse developmental outcomes. Abnormalities of retinal vasculature have been documented by fluorescein angiography years after anti-VEGF treatment. Further study is necessary to determine the long-term ocular and systemic effects of anti-VEGF agents used to treat ROP.

Early Treatment for Retinopathy of Prematurity Cooperative Group. Revised indications for the treatment of retinopathy of prematurity: results of the Early Treatment for Retinopathy of Prematurity randomized trial. *Arch Ophthalmol.* 2003;121(12):1684–1694.

Early Treatment for Retinopathy of Prematurity Cooperative Group; Good WV, Hardy RJ, Dobson V, et al. Final visual acuity results in the Early Treatment for Retinopathy of Prematurity study. *Arch Ophthalmol.* 2010;128(6):663–671.

Lepore D, Quinn GE, Molle F, et al. Intravitreal bevacizumab versus laser treatment in type 1 retinopathy of prematurity: report on fluorescein angiographic findings. *Ophthalmology.* 2014;121(11):2212–2219.

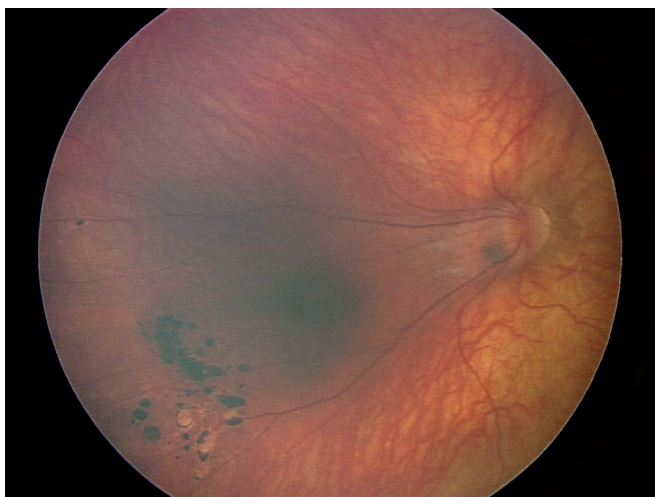Mintz-Hittner HA, Kennedy KA, Chuang AZ; BEAT-ROP Cooperative Group. Efficacy of intravitreal bevacizumab for stage 3+ retinopathy of prematurity. *N Engl J Med.* 2011;364(7):603–615.

Morin J, Luu TM, Superstein R, et al; Canadian Neonatal Network and the Canadian Neonatal Follow-Up Network Investigators. Neurodevelopmental outcomes following bevacizumab injections for retinopathy of prematurity. *Pediatrics.* 2016;137(4). pii: e20153218.

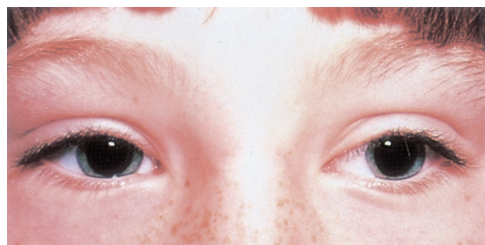### **Sequelae and complications**

One of the most common sequelae of significant ROP, whether treated or spontaneously regressed, is myopia, which may be severe. Also, premature infants with ROP, especially those who required treatment, are at higher risk for strabismus and amblyopia. Another recognized risk is glaucoma from crowding of the anterior chamber angle.

Various sequelae due to ROP involution may be noted in the retina and its vasculature, including latticelike degeneration, failure of peripheral vascularization, and tortuous vessels. Dragging of the macula can occur, giving rise to pseudoexotropia as a result of a large positive angle kappa (Figs 25-10, 25-11) (see Chapter 7 for a discussion of angle kappa). Eyes that have undergone treatment may also experience late retinal detachments at the border between treated and untreated retina. A child who has had ROP thus requires



**Figure 25-10** Posterior pole traction and dragging of the macula (right eye), a sequela of ROP. (Courtesy of Robert W. Hered, MD.)



**Figure 25-11** Pseudoexotropia in a fixating left eye in ROP. The patient has a positive angle kappa as a result of macular dragging.

periodic ophthalmic examinations beyond the newborn period. Late changes associated with stage 5 ROP include cataract, glaucoma, and phthisis bulbi.

When laser treatment, cryotherapy, or intravitreal bevacizumab monotherapy has not prevented the progression of ROP to stage 4 or 5 (retinal detachment), scleral buckling and vitrectomy may be indicated. Anatomical success varies depending on many factors, but visual acuity results have been disappointing, particularly with stage 5 eyes.

Unfortunately, even with the current guidelines for screening and treatment, approximately 400–600 babies become legally blind because of ROP each year in the United States. Poor ROP outcomes may be perceived as medical malpractice and therefore pose a risk for litigation by patients or their families. The Ophthalmic Mutual Insurance Company ([www.omic.com](http://www.omic.com)) offers numerous tools to help ophthalmologists limit their liability risk.

Repka MX, Tung B, Good WV, Capone A Jr, Shapiro MJ. Outcome of eyes developing retinal detachment during the Early Treatment for Retinopathy of Prematurity study. *Arch Ophthalmol.* 2011;129(9):1175–1179.

### Hereditary Retinal Disease

Nystagmus is the most common presenting sign of hereditary retinal disease. The onset of nystagmus typically occurs between 8 and 12 weeks of age and indicates limited visual potential if the cause is retinal disease (see Chapter 13). In infantile nystagmus caused by certain forms of Leber congenital amaurosis, achromatopsia, or X-linked congenital stationary night blindness, the retinal appearance can be normal.

Nystagmus does not develop in all patients with hereditary retinal disease; for example, it may not develop in those with less severe retinal damage. Poor visual function or failed vision screening may be the presenting abnormality in older children with retinal disease. The paradoxical pupillary response (pupils that initially constrict in the dark rather than dilate) is common in hereditary retinal dystrophies (Table 25-6).

Tests utilized to evaluate a patient with a possible hereditary retinal disorder include electroretinography (ERG), electro-oculography (EOG), and optical coherence tomography (OCT), as well as color vision, visual field, and dark adaptation tests. Sedation or general anesthesia may be required in order to perform ERG or OCT in young children. Because significant retinal maturation occurs during the first few years of life, an ERG can appear subnormal in a healthy infant. To obtain more reliable results, ERG is performed after 6–10 months of age. Repeated ERG testing may be necessary to confirm abnormalities of phototransduction.

**Table 25-6 Differential Diagnosis of Paradoxical Pupils**


---

Achromatopsia (complete, incomplete, or blue-cone monochromatism)
Albinism
Best disease
Congenital stationary night blindness
Leber congenital amaurosis
Optic nerve hypoplasia
Retinitis pigmentosa

---

Hereditary retinal diseases with onset late in childhood are much like those in adulthood and are not covered here. See BCSC Section 12, *Retina and Vitreous*.

### ***Leber congenital amaurosis***

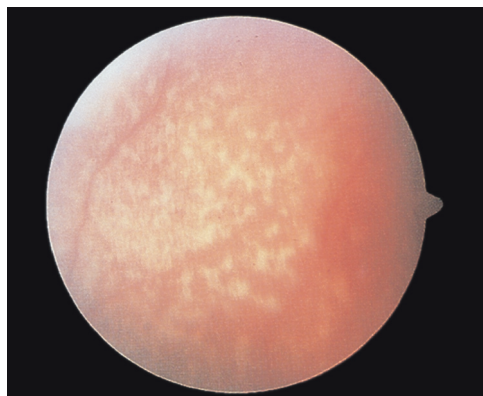Leber congenital amaurosis (LCA) is a group of hereditary (usually autosomal recessive) retinal dystrophies that affect both rod and cone photoreceptors. LCA is characterized by severe vision loss in infancy, nystagmus, poorly reactive pupils, and an extinguished ERG. Visual acuity typically ranges from 20/200 to bare light perception, but in some patients is not very low.

Ophthalmoscopic appearance varies greatly, depending on the genotype. It ranges from a normal appearance, particularly in infancy; to pigment clumping in the retinal pigment epithelium (RPE); to resemblance of classic retinitis pigmentosa, with bone spicules, attenuation of arterioles, and disc pallor. Other reported but less common fundus findings include extensive chorioretinal atrophy, macular coloboma, white dots (similar to those seen in retinitis punctata albescens), and marbled retinal appearance (Fig 25-12). Histologic examination shows diffuse absence of photoreceptors.

Additional ocular manifestations include the oculodigital reflex (rubbing or poking the eye), photoaversion, cataracts, keratoconus, and keratoglobus. High refractive errors, usually high hyperopia, are common.

LCA-like phenotypes can be found in a number of systemic diseases, including peroxisomal disorders (Zellweger [cerebrohepato renal] syndrome, neonatal adrenoleukodystrophy, and infantile Refsum disease) and the ciliopathies (Alström syndrome, Joubert syndrome, Senior-Løken syndrome, and Bardet-Biedl syndrome). The ciliopathies are a group of genetic disorders in which the structure and/or function of the cilia is affected, manifesting in cerebral anomalies and renal and retinal disease. Retinal involvement is common because the junction between inner and outer segments of the photoreceptor cell is modified nonmotile cilium (see Chapter 28). Thus, ophthalmologists should be aware that an LCA-like phenotype may be the first sign of an undiagnosed systemic disease.

**Diagnosis** An ERG is typically used to diagnose LCA. However, in a child with an obvious phenotype (oculodigital reflex, severely decreased vision at birth, and pigmentary retinopathy), ERG is not always necessary. Genetic testing is important and can be used to confirm the diagnosis, distinguish LCA from other retinal diseases, predict prognosis, and help with family planning. Molecular diagnosis of LCA is hindered by the fact that the disease is heterogeneous. At least 20 different genetic mutations are known to cause



**Figure 25-12** Leber congenital amaurosis with marbled fundus.

LCA; the most frequent involve *CEP290* (15%), *GUCY2D* (12%), and *CRB1* (10%), as well as *RPE65* (6%).

**Treatment** Gene therapy is available for biallelic *RPE65* disease. Studies have demonstrated improvement in subjective and objective vision after subretinal injections of the gene promoter attached to an adenovirus viral particle, but it is unclear whether these results will be sustainable. Results seem most promising in young children.

Alkharashi M, Fulton AB. Available evidence on Leber congenital amaurosis and gene therapy. *Semin Ophthalmol.* 2017;32(1):14–21.

Weleber RG, Pennesi ME, Wilson DJ, et al. Results at 2 years after gene therapy for *RPE65*-deficient Leber congenital amaurosis and severe early-childhood-onset retinal dystrophy. *Ophthalmology.* 2016;123(7):1606–1620.

### **Achromatopsia**

Complete achromatopsia, also known as *rod monochromatism*, is an autosomal recessive congenital disorder of the cone photoreceptors in which patients have no color vision, poor central vision, nystagmus, and photophobia. These patients see the world in shades of gray. Hemeralopia, the inability to see clearly in bright light, occurs in these patients.

Findings on retinal examination are usually normal, with the possible exception of a poor or absent foveal reflex. Although achromatopsia was initially thought to be a stationary disorder, results of recent studies have shown deterioration of visual acuity, macular appearance, and cone function on ERG.

**Diagnosis** Results of color vision testing are markedly abnormal. The ERG is subnormal, showing extinguished cone or photopic responses but normal or nearly normal rod responses. Several recessive gene mutations have been identified as the cause of achromatopsia, including mutations in *CNGA3*, *CNGB3* (most common), *GNAT2*, *PDE6C*, and *PDE6H*.

Other cone dystrophies causing early-onset visual impairment and nystagmus include *incomplete achromatopsia*, which is an autosomal recessive condition, and *blue-cone monochromatism*, which is an X-linked disorder. In both disorders, patients usually have better vision than do those with complete achromatopsia. In incomplete achromatopsia,

some residual cone function is observed on ERG testing. In blue-cone monochromatism, the blue (short-wavelength) cones show normal function on specialized ERG testing, but the photopic response is usually extinguished.

**Treatment** Glasses with dark lenses or red lenses that exclude short wavelengths may help. Gene therapy has been used in animal models.

### ***Congenital stationary night blindness***

*Congenital stationary night blindness (CSNB)* refers to a group of nonprogressive retinal disorders characterized predominantly by abnormal function of the rod system. The condition may be X-linked (the most common form), autosomal recessive, or autosomal dominant.

Children with CSNB, especially the autosomal recessive and X-linked forms, usually present in early infancy with nystagmus and a normal fundus appearance. These forms are often also associated with myopia and decreased visual acuity of roughly 20/200. However, the range of vision in these patients is wide, and occasionally, patients have normal vision. The retina usually appears normal, but the optic nerve may show myopic tilt and temporal pallor.

**Diagnosis** An ERG or genetic testing is necessary for diagnosis. The most common ERG pattern seen in CSNB is the “negative” dark-adapted ERG: a large a-wave and a reduced-amplitude (negative) b-wave. Dark adaptation is abnormal in all patients with CSNB. Infants with CSNB may have a flat ERG until approximately 6 months of age, when it converts to the classic negative configuration.

**Treatment** Bright illumination should be used for visual tasks and refractive errors corrected.

### ***Foveal hypoplasia***

Foveal hypoplasia, or incomplete development of the fovea, is another cause of nystagmus in early infancy. Although this condition is most often associated with albinism or aniridia, it may also be isolated or familial and may be related to a defect in the *PAX6* gene. On ophthalmoscopic examination, the foveal reflex is poor or absent, and the macula exhibits hypoplasia to varying degrees, which can also be seen in patients with complete achromatopsia.

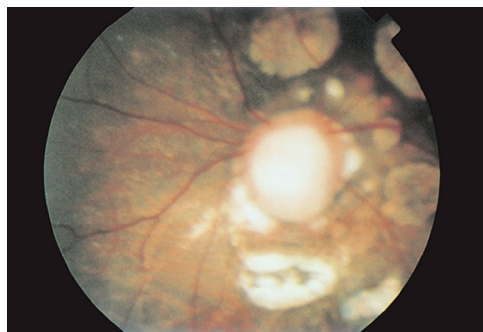Al-Saleh AA, Hellani A, Abu-Amro KK. Isolated foveal hypoplasia: report of a new case and detailed genetic investigation. *Int Ophthalmol*. 2011;31(2):117–120.

**Diagnosis** Fundus examination showing foveal hypoplasia is diagnostic. OCT may be useful.

**Treatment** No treatment is currently available.

### ***Aicardi syndrome***

Aicardi syndrome is a presumed X-linked autosomal dominant disorder characterized by the clinical triad of widespread round or oval depigmented chorioretinal lacunae (Fig 25-13), infantile spasms, and agenesis of the corpus callosum. Chorioretinal lacunae have been shown to occur in 88% of patients; optic nerve abnormalities, in 81%. Colobomas,



**Figure 25-13** Aicardi syndrome. Fundus photograph showing optic disc coloboma and chorioretinal lacunae.

persistent pupillary membranes, and microphthalmia may also occur. Aicardi syndrome is typically lethal in males.

Fruhman G, Eble TN, Gambhir N, Sutton VR, Van den Veyver IB, Lewis RA. Ophthalmologic findings in Aicardi syndrome. *J AAPOS*. 2012;16(3):238–241.

**Diagnosis** The clinical picture provides the foundation for diagnosis.

**Treatment** No treatment is currently available.

### Hereditary Macular Dystrophies

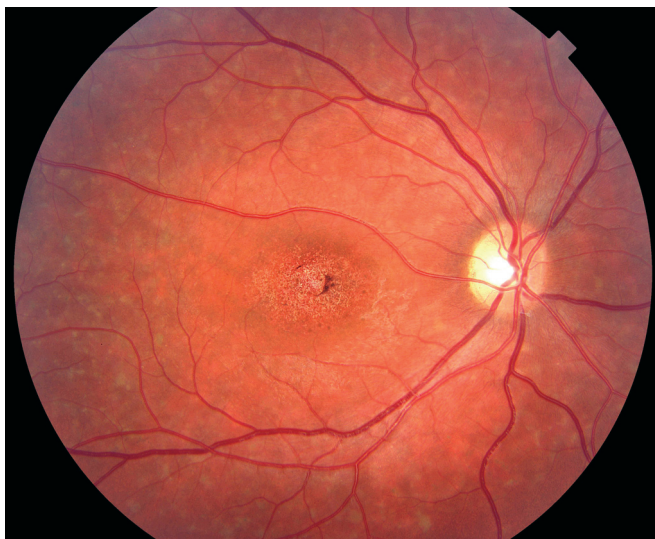
Macular abnormalities are seen in a number of hereditary disorders. The abnormality can be associated with a hereditary systemic disease (eg, the cherry-red spot in GM<sub>2</sub> gangliosidosis type I) or can reflect a primary retinal disorder, such as Stargardt disease or Best disease. Only primary retinal disorders are discussed here.

#### **Stargardt disease**

Stargardt disease (juvenile macular degeneration) is the most common hereditary macular dystrophy. Inheritance is usually autosomal recessive; in rare cases, it is autosomal dominant. Most cases are caused by mutations in the retina-specific adenosine triphosphate-binding transporter gene (*ABCA4*). Children with Stargardt disease usually present between ages 8 and 15 years with a decrease in vision, photophobia, or color vision abnormalities. The condition is bilateral, symmetric, and progressive; visual acuity levels off at approximately 20/50–20/200.

**Diagnosis** The disease often progresses through stages. Initially, the fundus appears normal even when vision is decreased, and the condition may be misdiagnosed as functional vision loss. The first ophthalmoscopic changes observed are loss of foveal reflex, followed by development of a characteristic macular bull's-eye atrophy surrounded by round or pisciform yellowish flecks, which develop in the posterior pole at the level of the RPE. If the flecks are scattered throughout the fundus, the condition may be referred to as *fundus flavimaculatus*. Before the flecks develop, the macula often appears atrophic due to diseased RPE, inducing a peculiar light-reflecting quality resembling that of beaten bronze (Figs 25-14, 25-15).





**Figure 25-14** Stargardt disease. Macular atrophy, pisciform yellow-white flecks, and a beaten-bronze appearance. Note the peripapillary sparing of retina. (Courtesy of Marc T. Mathias, MD.)

The “dark choroid” sign on fluorescein angiography is distinctive but is not present in all patients. This phenomenon is due to the accumulation of lipofuscin within the RPE, which blocks the choroidal fluorescence. Fluorescein angiography has been largely replaced by fundus autofluorescence (FAF) testing for the confirmation of Stargardt disease. FAF reveals both increased autofluorescence due to lipofuscin accumulation in the RPE and reduced autofluorescence in areas of RPE atrophy and photoreceptor loss (see Fig 25-15C, D). OCT imaging of the macula can reveal lipofuscin accumulation in the RPE and photoreceptor loss.

Results of visual field testing may be normal in the early stages of the disease. Disease progression will result in a central scotoma.

ERG results are often normal in the early stages of Stargardt disease. Stargardt disease can be associated with a progressive cone-rod dystrophy that has a much worse visual prognosis and an extinguished ERG.

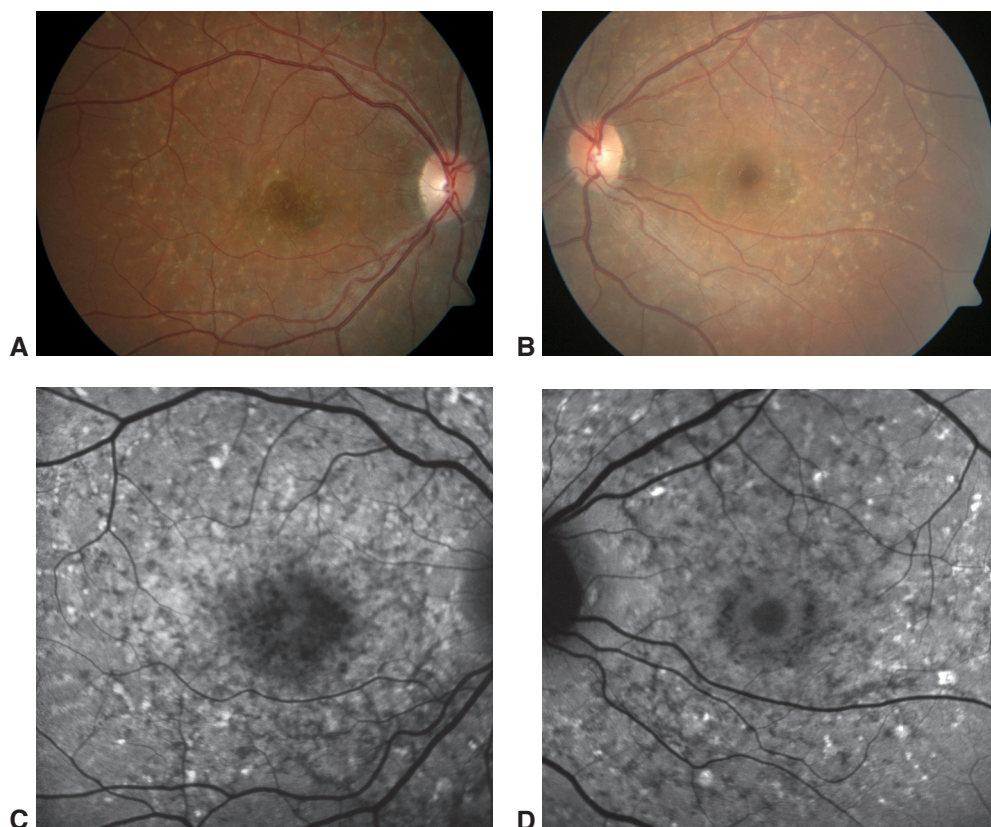
Detection of *ABCA4* mutations via genetic testing may be diagnostic.

**Treatment** Gene therapy for Stargardt disease has been used in animal models and is being studied in phase 1/2a clinical trials in humans.

Han Z, Conley SM, Naash MI. Gene therapy for Stargardt disease associated with *ABCA4* gene. *Adv Exp Med Biol.* 2014;801:719–724.

### **Best disease**

Classic Best disease, or *juvenile-onset vitelliform macular dystrophy (VMD)*, is an autosomal dominant retinal disorder with variable penetrance and expressivity. The condition is caused by mutations in the *BEST1* gene on chromosome 11, which encodes for the protein



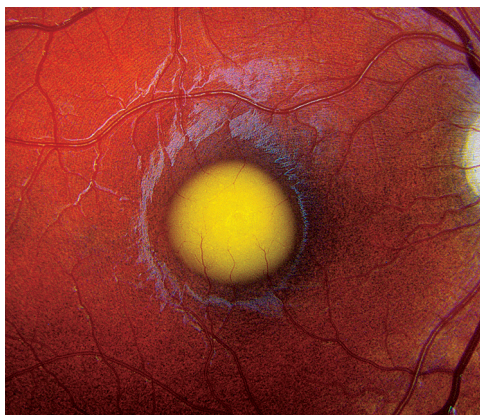**Figure 25-15** Fundus photographs from a patient with Stargardt disease. The right eye (**A**) and left eye (**B**) demonstrate classic pisciform yellow-white flecks throughout the macula, with mottling of the central retinal pigment epithelium (RPE). Corresponding right (**C**) and left (**D**) fundus autofluorescence (FAF) images reveal mottled hypo- and hyperautofluorescence with hyperautofluorescent flecks (corresponding to the pisciform flecks) and a bull's-eye maculopathy, greater in the left eye than in the right eye. (Courtesy of Marc T. Mathias, MD.)

bestrophin. Patients usually present asymptotically in childhood with the classic retinal appearance, or later in life with decrease in vision.

Over the last decade, a rare, distinct phenotype—*autosomal dominant vitreoretinopathopathy (ADVIRC)*—has been recognized. ADVIRC results from exon-skipping mutation in *BEST1*. A separate, distinct phenotype caused by biallelic null mutations in *BEST1* also exists. The various phenotypes caused by heterozygous or biallelic mutations of *BEST1* are collectively termed *bestrophinopathies*.

Pasquay C, Wang LF, Lorenz B, Preising MN. Bestrophin 1—phenotypes and functional aspects in bestrophinopathies. *Ophthalmic Genet.* 2015;36(3):193–212.

**Diagnosis** The retina may appear normal at first, but between 4 and 10 years of age, the “egg yolk,” or vitelliform, stage begins (Fig 25-16). A yellow-orange cystlike structure is



**Figure 25-16** Best disease, “egg yolk” stage. (Courtesy of Joseph Morales, CRA, COA. Cover image for *Ophthalmology Retina* [Sept/Oct 2017 issue].)

seen, usually in the macula; however, the lesion may occur elsewhere, and occasionally there are multiple lesions. The lesions are usually 1.5–5.0 disc diameters in size. The egg yolk–like appearance is associated with good central vision.

With time, the cystic material may become granular, giving rise to the “scrambled egg” stage. At this stage, central vision usually remains good, with visual acuity roughly 20/30. The cyst may rupture and become partially resorbed; a pseudohypopyon may form from cystic contents. *Choroidal neovascular membranes (CNVMs)* and *pigment epithelial detachments (PEDs)* develop in 20% of patients (Fig 25-17A). Subretinal hemorrhage may occur, and visual acuity may deteriorate to 20/100 or worse. FAF reveals central macular hyperautofluorescence due to vitelliform material (Fig 25-17B). Fluorescein angiography reveals central macular hyperfluorescence due to staining of the vitelliform material as well as late leakage from a CNVM, if present (Fig 25-17C, D). Spectral-domain OCT (SD-OCT) imaging can further illustrate the central macular abnormalities (Fig 25-17E, F).

The EOG is usually abnormal in affected patients and carriers. This disorder is one of the few in which the EOG is abnormal and the ERG is normal. *BEST1* gene mutations are found in 60%–83% of affected patients. Carriers can be identified by the presence of an abnormal EOG with a normal retina or a *BEST1* gene mutation.

Meunier I, Sénéchal A, Dhaenens CM, et al. Systematic screening for *BEST1* and *PRPH2* in juvenile and adult vitelliform macular dystrophies: a rationale for molecular analysis. *Ophthalmology*. 2011;118(6):1130–1136.

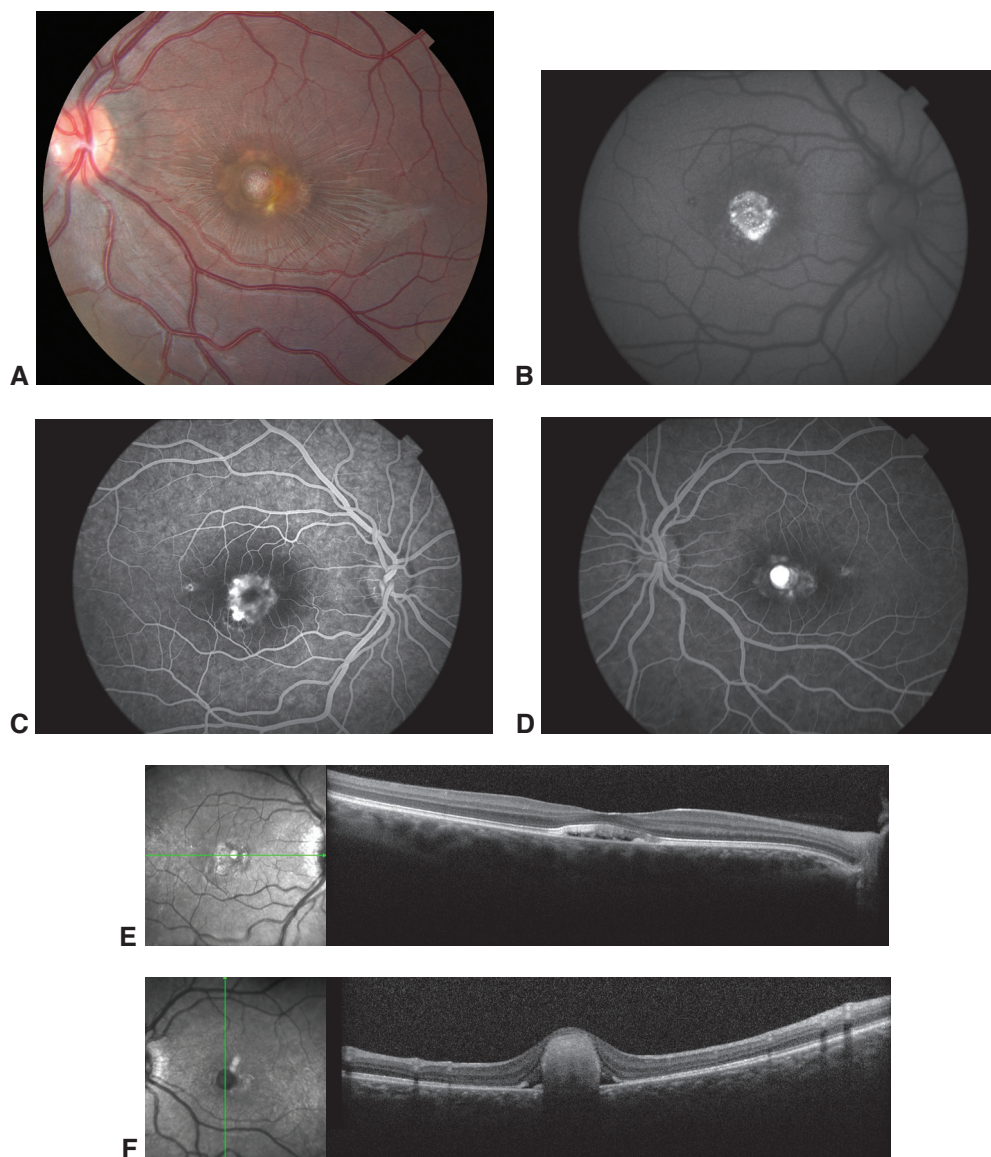
**Treatment** No treatment is indicated unless subretinal neovascularization occurs.

## Hereditary Vitreoretinopathies

Hereditary vitreoretinopathies include a broad range of disease entities. The ones discussed here characteristically present in childhood.

### Juvenile retinoschisis

Juvenile retinoschisis (splitting of the retina) is an X-linked disease caused by mutations in the *RS1* gene, which encodes for the retinal protein retinoschisin, an adhesion protein that is believed to be essential to the health of Müller cells. Affected males usually present



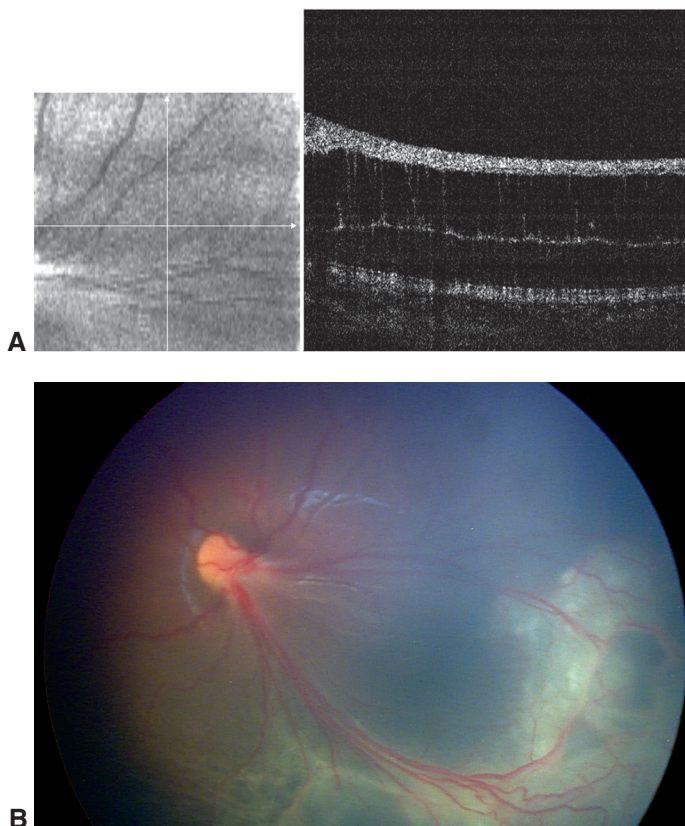
**Figure 25-17** Best disease. **A**, Left eye with vitelliform lesion and central dome-shaped choroidal neovascular membrane (CNVM). **B**, Right eye with central macular hyperautofluorescence due to vitelliform material, as seen on FAF imaging. **C**, Fluorescein angiography image (right eye) reveals central macular hyperfluorescence due to staining of vitelliform material. **D**, Fluorescein angiography image (left eye) shows late central hyperfluorescence from leakage of CNVM. **E**, Spectral-domain OCT (SD-OCT) image (right eye) reveals subretinal hyperreflective material with a hyporeflective cleft corresponding to the vitelliform lesion. **F**, SD-OCT image (left eye) reveals a large subfoveal pigment epithelial detachment with subretinal hyperreflective material and subretinal fluid. (Courtesy of Marc T. Mathias, MD.)

in early childhood with decreased vision. Visual acuity varies but usually deteriorates to roughly 20/200.

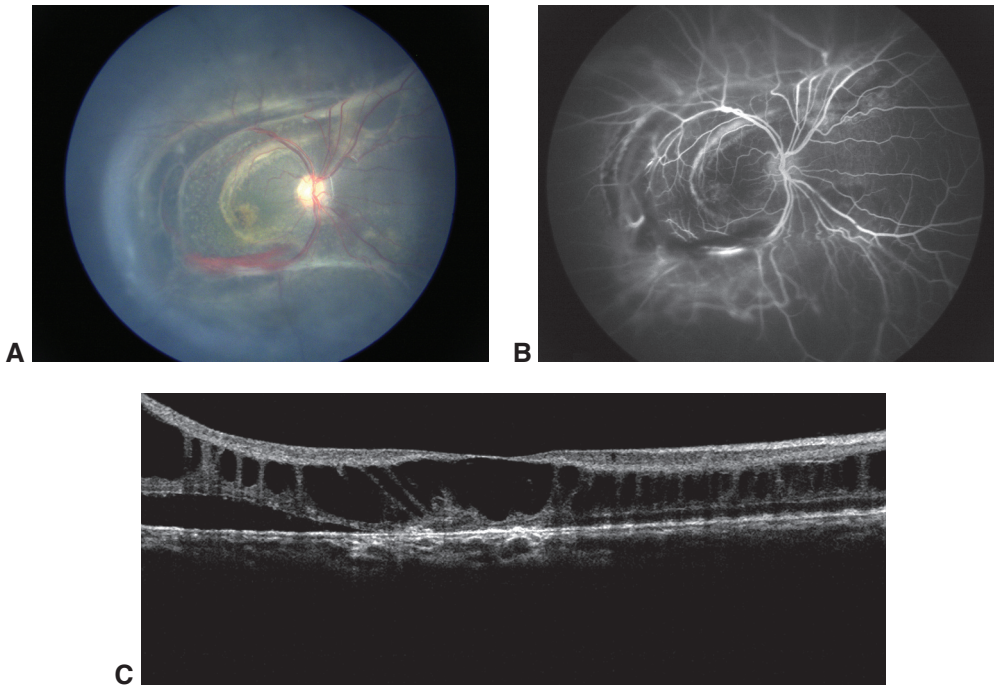
**Diagnosis** Foveal retinoschisis is present in almost all cases; peripheral retinoschisis, in approximately 50% of patients. The fovea has a stellate or spokelike configuration that may resemble cystoid macular edema; it becomes less distinct over time. SD-OCT shows schisis spaces in the middle layers of the macula (Fig 25-18A). Vitreous veils or strands are common, and vitreal syneresis, or liquefaction, is prominent. Complications include vitreous hemorrhage and various types of retinal detachment (Figs 25-18B, 25-19). The ERG shows a reduction of the scotopic b-wave with preservation of the a-wave.

**Treatment** Contact sports should be avoided because the retina in affected eyes is more susceptible to trauma. Gene replacement has shown some success in mouse models. Use of carbonic anhydrase inhibitors to treat cystic macular lesions is under investigation.

Verbakel SK, van de Ven JP, Le Blanc LM, et al. Carbonic anhydrase inhibitors for the treatment of cystic macular lesions in children with X-linked juvenile retinoschisis. *Invest Ophthalmol Vis Sci.* 2016;57(13):5143–5147.



**Figure 25-18** Juvenile retinoschisis. **A**, SD-OCT image shows schisis of retina. **B**, Combined tractional and rhegmatogenous retinal detachment. (Courtesy of Scott C. Oliver, MD.)



**Figure 25-19** Three-year-old with juvenile retinoschisis. **A**, Central and extensive peripheral retinoschisis with mild vitreous and preretinal hemorrhage. There is a large circumferential tractional retinal detachment around the arcades, encroaching on the central macula. A retinal hole is also present. **B**, Fluorescein angiography reveals an extensive tractional detachment. **C**, Macular OCT image demonstrates retinoschisis with a tractional detachment and subretinal fluid encroaching on the fovea. (Courtesy of Marc T. Mathias, MD.)

### **Stickler syndrome**

Stickler syndrome is a group of connective tissue disorders with variable phenotypic expression. The most common type of Stickler syndrome is autosomal dominant, has ocular and systemic findings, and is caused by a mutation in *COL2A1*, the gene that encodes for type II procollagen. Some mutations in the gene cause an ocular-only phenotype.

**Diagnosis** The diagnosis is made based on the clinical features as well as the results of genetic testing. Common ocular abnormalities include an optically empty vitreous due to vitreous liquefaction, high myopia, lattice degeneration, and proliferative vitreoretinopathy. In addition, there is a high incidence of retinal detachment secondary to retinal breaks. Anterior chamber angle anomalies, ectopia lentis, cataracts, ptosis, and strabismus are less common.

Characteristic systemic abnormalities are a flat midface, progressive hearing loss, cleft palate, Pierre Robin sequence, mitral valve prolapse, and progressive arthropathy with spondyloepiphyseal dysplasia. Although the arthropathy may not be symptomatic initially, children with Stickler syndrome often show radiographic abnormalities of the long bones and joints, and associated symptoms develop.

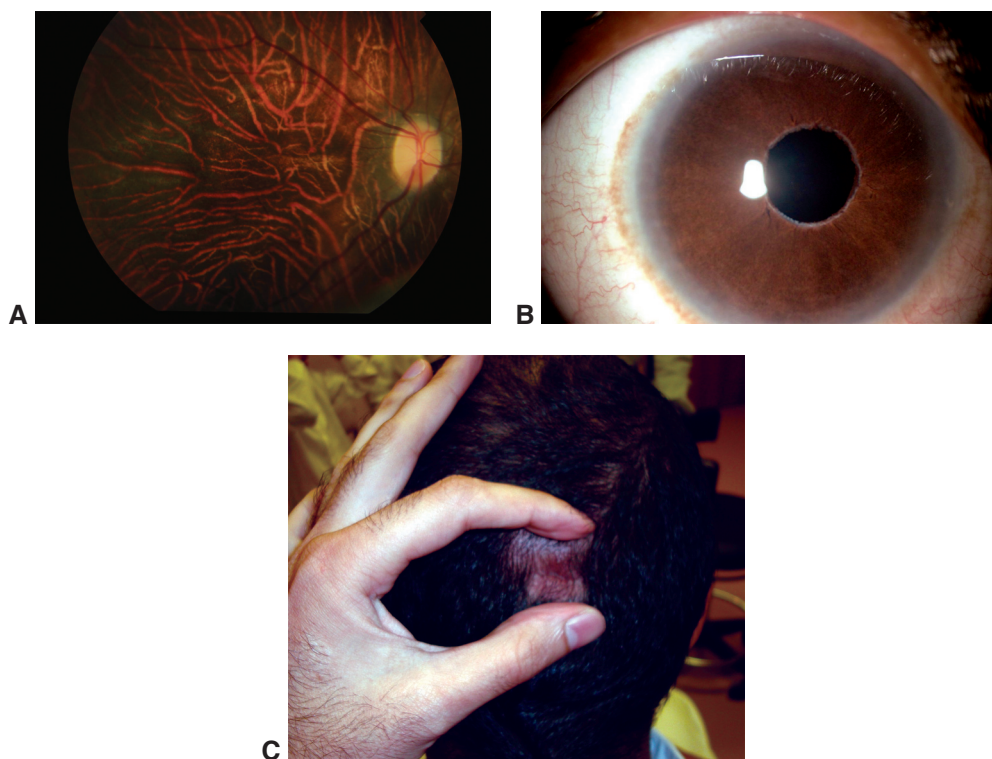
**Treatment** The retinal detachments are often difficult to repair because these patients may have large retinal breaks posteriorly and the incidence of proliferative vitreoretinopathy is high. The incidence of vitreous loss during cataract surgery is high, as is the rate of subsequent retinal detachment. Retinal folds and breaks should be treated before cataract extraction. Prophylactic retinopathy may be appropriate in certain patients.

Fincham GS, Pasea L, Carroll C, et al. Prevention of retinal detachment in Stickler syndrome: the Cambridge prophylactic cryotherapy protocol. *Ophthalmology*. 2014;121(8):1588–1597.

### **Knobloch syndrome**

Knobloch syndrome is a vitreoretinopathy caused by biallelic mutations in *COL18A1*. It is classically defined by the triad of occipital encephalocele, high myopia, and predisposition to retinal detachment.

**Diagnosis** The ocular phenotype is characterized by a distinct vitreoretinal degeneration—very severe RPE atrophic changes with prominent choroidal vessels (Fig 25-20A) out of proportion to the degree of myopia, macular atrophic lesions with or without a “punched-out” appearance, and white fibrillar vitreous condensations. These eyes have a strong



**Figure 25-20** Knobloch syndrome. **A**, With severe chorioretinal atrophy. **B**, With cryptless iris. **C**, With scalp abnormality. (Courtesy of Arif O. Khan, MD.)

predisposition to spontaneous retinal detachment. Smooth (cryptless) irides are universal in affected eyes (Fig 25-20B); ectopia lentis is an occasional finding. Taken together, these ocular findings are pathognomonic for biallelic *COL18A1* mutations.

ERG shows cone–rod dysfunction. Pigment dispersion glaucoma has been reported in 2 patients.

Systemic manifestations are variable and not always present; they include occipital abnormalities (Fig 25-20C) (ranging from scalp abnormalities to encephalocele), congenital renal malformations, developmental delay, seizures, and heterotopic gray matter.

**Treatment** Therapy is based on disease manifestations.

Khan AO, Aldahmesh MA, Mohamed JY, Al-Mesfer S, Alkuraya FS. The distinct ophthalmic phenotype of Knobloch syndrome in children. *Br J Ophthalmol.* 2012;96(6):890–895.

### **Norrie disease**

Norrie disease is an X-linked recessive disorder of retinal dysplasia caused by a mutation in the *NDP* gene, which encodes for the protein norrin. Affected boys are typically born blind and have varying degrees of hearing impairment and intellectual disability.

**Diagnosis** The condition is characterized by a distinctive retinal appearance: a globular, severely dystrophic retina with pigmentary changes in the avascular periphery. During the first few days or weeks of life, a bilateral, yellowish retinal detachment appears, followed by a whiter mass behind the clear lens. Over time, the lenses, and later the cornea, opacify; phthisis bulbi may ensue by age 10 years or earlier. Female carriers show peripheral retinal abnormalities.

**Treatment** No treatment exists.

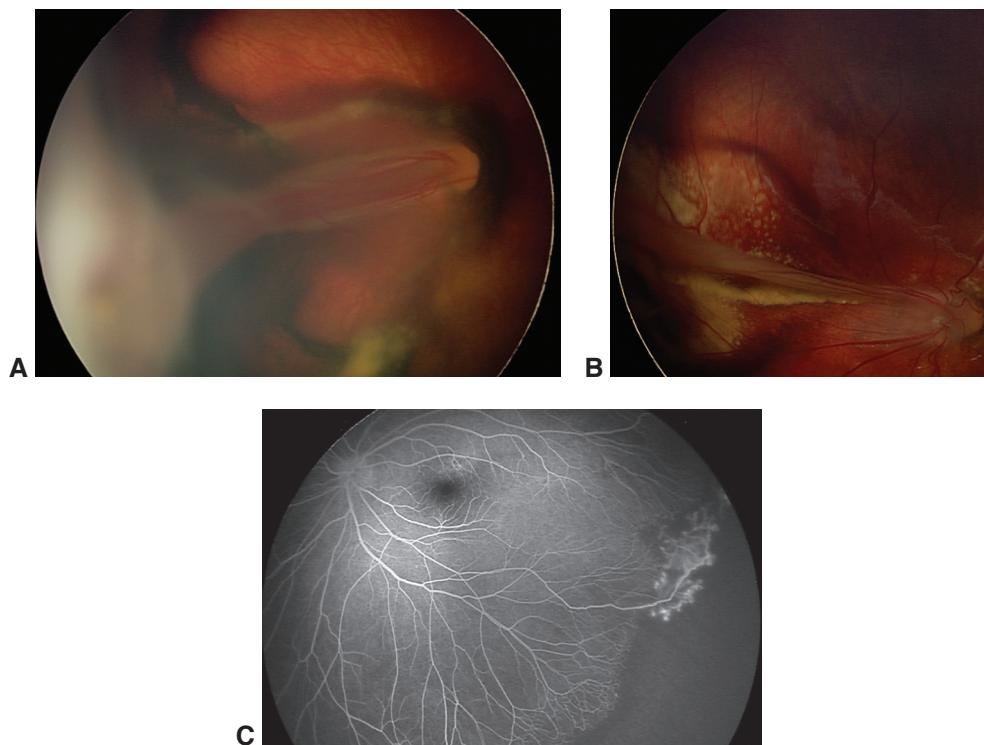
### **Familial exudative vitreoretinopathy**

Familial exudative vitreoretinopathy (FEVR) is a disease of abnormal retinal vascularization similar to that seen in ROP (discussed earlier in the chapter). There is failure of the peripheral retina to vascularize. FEVR is typically autosomal dominant, but autosomal recessive and X-linked forms exist as well, the latter resulting from mutations in the same gene involved in Norrie disease (*NDP*).

Khan AO, Lenzner S, Bolz HJ. A family harboring homozygous *FZD4* deletion supports the existence of recessive *FZD4*-related familial exudative vitreoretinopathy. *Ophthalmic Genet.* 2017;38(4):380–382.

**Diagnosis** Posterior pole findings in FEVR include retinal traction, folds, breaks, and detachment secondary to vitreous traction (Fig 25-21A). Posterior vitreous detachment and thick peripheral intraretinal and subretinal exudates may develop (Fig 25-21B). The disease is bilateral and can mimic ROP but affects infants born at full term. Fluorescein angiography shows areas of retinal nonperfusion and neovascularization (Fig 25-21C). Examination of family members is important in the diagnosis of FEVR. Affected family members can show marked variation in severity, from minimal straightening of retinal vessels and peripheral nonperfusion to total retinal detachment.





**Figure 25-21** Familial exudative vitreoretinopathy. **A**, Tractional retinal detachment with a knot of anterior fibrotic tissue. **B**, Tractional detachment treated with a radially oriented sponge. Note the subretinal exudates. **C**, Fluorescein angiography image shows peripheral avascular retina and hyperfluorescence from leakage of peripheral vessels. (Courtesy of Scott C. Oliver, MD.)

**Treatment** Cryopexy, photocoagulation, vitrectomy, and cataract surgery have been used to manage patients with this disorder.

## Infectious Diseases

---

### Herpes Simplex Virus and Cytomegalovirus

Herpes simplex virus and cytomegalovirus are discussed in Chapter 28.

### Human Immunodeficiency Virus

The ocular complications of HIV infection have been noted only rarely since the advent of potent antiretroviral therapy. Such complications typically occur only in children with advanced HIV infection who are severely immunocompromised. For more information, see BCSC Section 9, *Uveitis and Ocular Inflammation*, and Section 12, *Retina and Vitreous*.

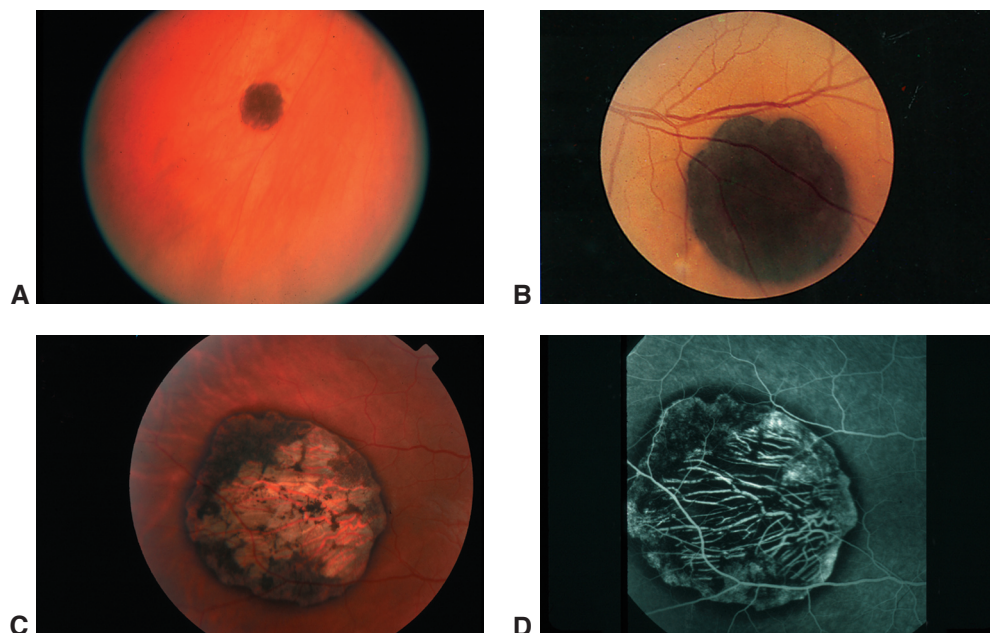
## Tumors

### Choroidal and Retinal Pigment Epithelial Lesions

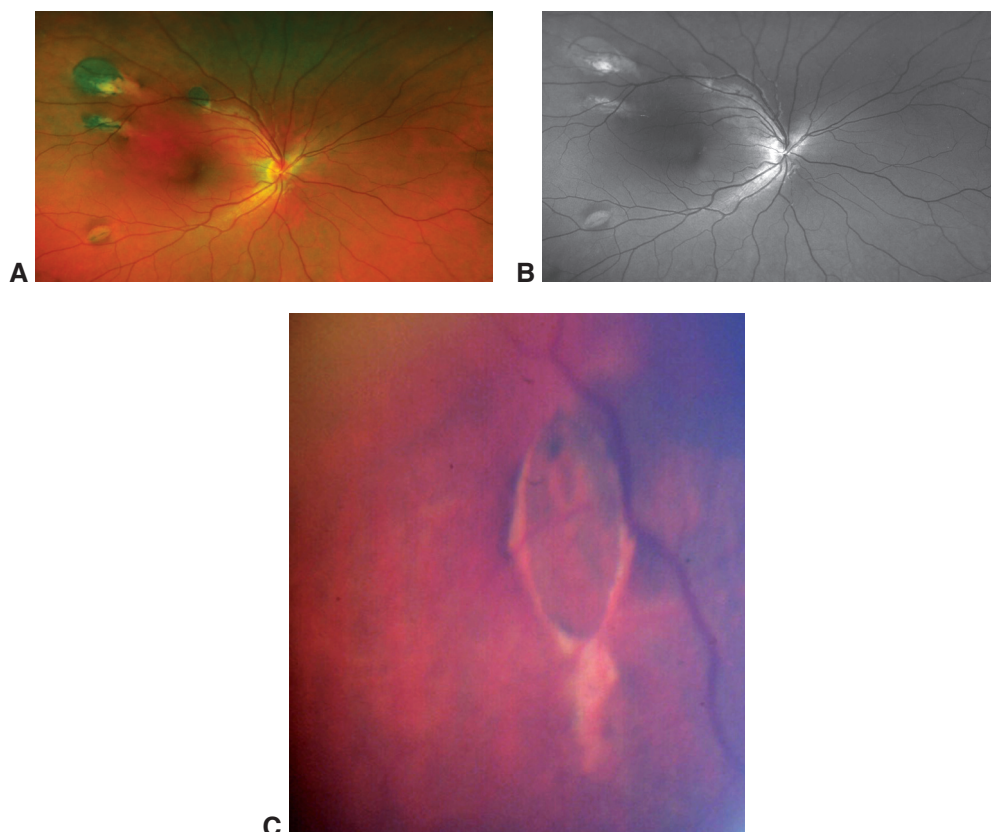
A pigmented fundus lesion in a child is usually benign. Flat choroidal nevi are common and are not a cause for concern. Malignant melanoma of the choroid is extremely rare in children. Choroidal osteoma is a benign bony tumor of the uveal tract that may occur in childhood, usually presenting with decreased vision. Diffuse hemangioma of the choroid associated with Sturge-Weber syndrome is discussed in Chapter 28. Patients with neurofibromatosis type 1 often have flat, tan-colored spots in the choroid (see Chapter 28).

*Congenital hypertrophy of the retinal pigment epithelium (CHRPE)* is a sharply demarcated, flat, hyperpigmented lesion that may be isolated or multifocal (Fig 25-22). Such lesions are sometimes grouped, in which case they are also called *bear tracks*.

Pigmented lesions similar to CHRPE have been associated with Gardner syndrome, an autosomal dominant condition caused by a mutation in the *APC* gene, located at 5q22.2. Patients with Gardner syndrome have many polyps of the colon, which carry a very high risk for malignant transformation. Affected individuals often require a colectomy in early adulthood to prevent cancer. They may also have skeletal hamartomas and various other soft-tissue tumors. The pigmented retinal lesions associated with Gardner



**Figure 25-22** Congenital hypertrophy of the RPE (CHRPE). Examples of varying clinical appearances. **A**, Small lesion. **B**, Medium-sized lesion; note the homogeneous black color and well-defined margins of this nummular lesion. **C**, Color fundus photograph of a large lesion. **D**, Corresponding fluorescein angiogram of the large lesion. Note the loss of RPE architecture and highlighted choroidal vasculature. (Parts A, C, and D courtesy of Timothy G. Murray, MD.)



**Figure 25-23** Gardner Syndrome. **A**, Ultra-wide-angle fundus photograph shows multiple pigmented retinal lesions with areas of depigmentation oriented radially to the optic nerve. **B**, FAF reveals areas of hypo- and hyperautofluorescence within pigmented lesions. **C**, Retinal lesion with a “fish-tail” configuration. (Parts A and B courtesy of Cara E. Capitena, MD; part C courtesy of Robert W. Herd, MD.)

syndrome are different from CHRPE in that they are typically multiple, bilateral, and dispersed; in addition, they often have a surrounding halo and tail of depigmentation that is oriented radially and directed toward the optic nerve (Fig 25-23).

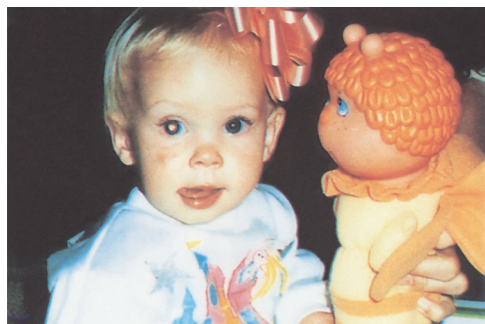*Combined hamartoma of the retina and RPE* is an ill-defined, elevated, variably pigmented tumor that may be juxtapapillary or located in the retinal periphery. The tumor is often minimally elevated; retinal traction and tortuous retinal vessels are often present. In peripheral tumors, dragging of the retinal vessels is a prominent feature. The tumors have a variable composition of glial tissue and RPE. This condition can be associated with neurofibromatosis (type 1 or 2), incontinentia pigmenti, X-linked retinoschisis, and facial hemangiomas. Bilateral lesions in a child should raise suspicion for neurofibromatosis type 2.

Traboulsi EI. Ocular manifestations of familial adenomatous polyposis (Gardner syndrome). *Ophthalmol Clin North Am.* 2005;18(1):163–166.

## Retinoblastoma

Retinoblastoma is the most common malignant intraocular tumor of childhood and one of the most common pediatric solid tumors, with an incidence of 1:14,000–1:20,000 live births. It is equally common in both sexes and has no racial predilection. Retinoblastoma is a neuroblastic tumor and is therefore biologically similar to neuroblastoma and medulloblastoma. The tumor can be unilateral or bilateral; 30%–40% of cases are bilateral. In familial and bilateral cases, retinoblastoma is typically diagnosed during the first year of life; in sporadic unilateral cases, between 1 and 3 years of age. Approximately 90% of cases are diagnosed before 3 years of age; onset later than age 5 years is rare but can occur.

The most common initial sign is leukocoria (white pupillary reflex), which is usually first noticed by the family and described as a glow, glint, or cat's-eye appearance (Fig 25-24). The differential diagnosis of leukocoria is presented in Table 25-7. Approximately 25% of cases present with strabismus (esotropia or exotropia). Less common presentations include vitreous hemorrhage, hyphema, ocular or periocular inflammation, glaucoma, proptosis, and pseudohypopyon.



**Figure 25-24** Leukocoria of the right eye, which is visible in this family photograph of a 1-year-old girl with retinoblastoma. (Courtesy of A. Linn Murphree, MD.)

**Table 25-7 Differential Diagnosis of Leukocoria**

---

Cataract
Coats disease
Coloboma of choroid or optic disc
Congenital retinal fold
Corneal opacity
Familial exudative vitreoretinopathy
High myopia or anisometropia
Myelinated nerve fibers
Norrie disease
Organizing vitreous hemorrhage
Persistent fetal vasculature
Photographic artifact
Retinal detachment
Retinal dysplasia
Retinoblastoma
Retinopathy of prematurity
Toxocariasis
Uveitis

---

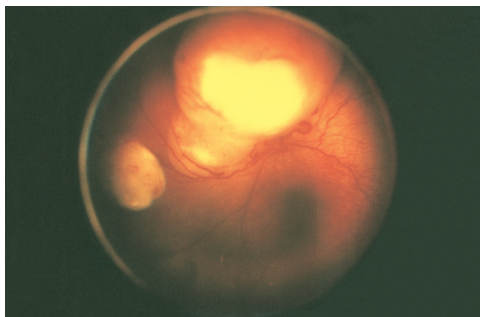
**Diagnosis**

Diagnosis of retinoblastoma is usually based on its ophthalmoscopic appearance. Intraocular retinoblastoma can exhibit a variety of growth patterns. With endophytic growth, it appears as a white to cream-colored mass that breaks through the internal limiting membrane (Fig 25-25). Endophytic retinoblastoma is sometimes associated with vitreous seeding, in which individual cells or fragments of tumor tissue become separated from the main mass, as shown in Figure 25-26. Vitreous seeds may be few and localized or so extensive that the clinical picture resembles endophthalmitis. Occasionally, malignant cells enter the anterior chamber and form a pseudohypopyon.

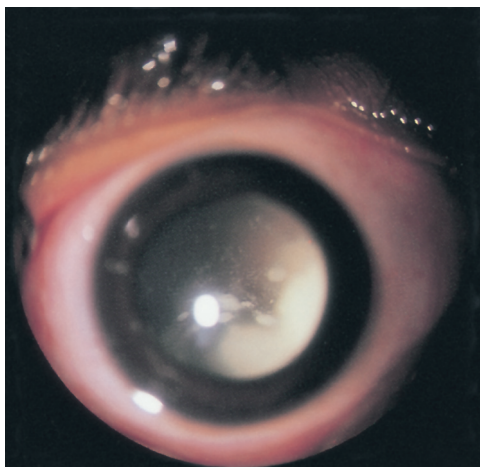
Exophytic tumors are usually yellow-white and occur in the subretinal space; the overlying retinal vessels are commonly larger in caliber and more tortuous (Fig 25-27). Exophytic retinoblastoma growth is often associated with subretinal fluid accumulation, which can obscure the tumor and closely mimic the appearance of an exudative retinal detachment suggestive of advanced Coats disease. Retinoblastoma cells have the potential to implant on previously uninvolved retinal tissue and grow, thereby creating an impression of multicentricity in an eye with only a single primary tumor.

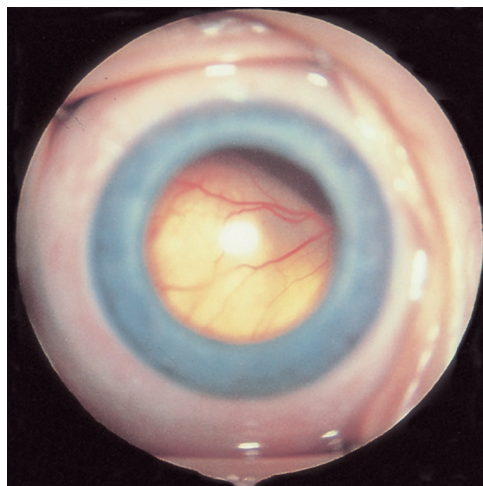
Large tumors often show signs of both endophytic and exophytic growth. Small retinoblastoma lesions appear as a grayish mass and are frequently confined between the

**Figure 25-25** Fundus photograph showing multiple endophytic retinoblastoma lesions, left eye. (Courtesy of A. Linn Murphree, MD.)



**Figure 25-26** Endophytic retinoblastoma with vitreous seeding.





**Figure 25-27** Exophytic retinoblastoma with overlying detached retina.

internal and external limiting membranes. A third pattern, diffuse infiltrative retinoblastoma, is usually unilateral and nonhereditary. It is found in children older than 5 years. The tumor presents with conjunctival injection, anterior chamber seeds, pseudohypopyon, large clumps of vitreous cells, and retinal infiltration of tumor. Because no distinct tumor mass is present, diagnostic confusion with inflammatory conditions is common.

Spontaneous regression of retinoblastoma is possible. It can be asymptomatic, resulting in the development of a benign retinocytoma, or it can be associated with inflammation and, ultimately, phthisis bulbi. In either case, the genetic implications are the same as for an individual with an active retinoblastoma.

The most common retinal lesion simulating retinoblastoma is seen in Coats disease. The presence of crystalline material, extensive subretinal fluid, and peripheral vascular abnormalities—combined with the absence of calcium—suggests Coats disease. *Astrocytic hamartomas* and *hemangioblastomas* are benign retinal tumors that may simulate the appearance of small retinoblastomas. Both are usually associated with neuro-oculocutaneous syndromes (see Chapter 28).

Evaluation of a patient with presumed retinoblastoma requires imaging of the head and orbits, which can confirm the diagnosis and assess for extraocular extension and intracranial disease. Computed tomography is discouraged because of the possible increased risk of secondary tumors due to radiation exposure. Magnetic resonance imaging and ultrasonography are recommended. More invasive tests are reserved for atypical cases. Aspiration of ocular fluids for diagnostic testing should be performed only under the most unusual circumstances because such procedures can disseminate malignant cells. Recently, however, it was demonstrated that cell-free tumor-derived DNA may be obtained from aqueous humor.

The characteristic histologic features of retinoblastoma include Flexner-Wintersteiner rosettes, which are usually present, and fleurettes, which are less common. Both represent limited degrees of retinal cellular differentiation. Homer Wright rosettes are also

frequently present but are less specific for retinoblastoma because they are common in other neuroblastic tumors. Calcification of varying extent is usually present.

Berry JL, Xu L, Murphree AL, et al. Potential of aqueous humor as a surrogate tumor biopsy for retinoblastoma. *JAMA Ophthalmol.* 2017;135(11):1221–1230.

de Graaf P, Göricke S, Rodjan F, et al; European Retinoblastoma Imaging Collaboration. Guidelines for imaging retinoblastoma: imaging principles and MRI standardization. *Pediatr Radiol.* 2012;42(1):2–14.

**Genetics** The retinoblastoma gene (*RB1*) maps to a locus within the q14 band of chromosome 13 and codes for a protein, pRB, that suppresses tumor formation. For retinoblastoma to occur, both *RB1* genes must have a mutation. Approximately 60% of retinoblastoma cases arise from somatic nonhereditary mutations of both alleles of *RB1* in a retinal cell. These mutations generally result in unifocal and unilateral tumors. In the other 40% of patients, a germline mutation in 1 of the 2 alleles of *RB1* either is inherited from an affected parent (10% of all retinoblastoma cases) or occurs spontaneously in 1 of the gametes. A second somatic mutation in a retinal cell is all that is necessary for retinoblastoma to develop; such cases are often multicentric and bilateral.

Genetic counseling for families of retinoblastoma patients is complex (Table 25-8). Both parents and all siblings should be examined. In approximately 1% of cases, a parent may be found to have an unsuspected fundus lesion that represents a spontaneously regressed retinoblastoma (retinocytoma).

Genetic testing for retinoblastoma is important for determining the risk of subsequent cancers (both retinoblastoma and other primary neoplasms) in the affected child and the risk of retinoblastoma in other family members. The probability of detecting the *RB1* gene depends on many factors, including the capabilities of the molecular diagnostic laboratory, the presence of tumor tissue, and the ability to test other affected family members.

Preimplantation genetic testing can be performed, and in vitro fertilization techniques have been used successfully to select embryos that are free from the germinal *RB1* mutation.

Dhar SU, Chintagumpala M, Noll C, Chévez-Barrios P, Paysse EA, Plon SE. Outcomes of integrating genetics in management of patients with retinoblastoma. *Arch Ophthalmol.* 2011;129(11):1428–1434.

**Classification of retinoblastoma** The International Classification of Retinoblastoma (ICRB; Table 25-9) is useful for predicting the success of chemoreduction and has superseded the Reese-Ellsworth classification, which was originally developed to predict globe salvage after external-beam radiotherapy. The American Joint Committee on Cancer (AJCC) also has a staging system for retinoblastoma that addresses both intraocular and extraocular disease (see BCSC Section 4, *Ophthalmic Pathology and Intraocular Tumors*).

Shields CL, Mashayekhi A, Au AK, et al. The International Classification of Retinoblastoma predicts chemoreduction success. *Ophthalmology.* 2006;113(12):2276–2280.

**Table 25-8 Genetic Counseling for Retinoblastoma**

If Parent:	Has Bilateral Retinoblastoma	Has Unilateral Retinoblastoma	Is Unaffected
Chance of offspring having retinoblastoma	45% affected	7%–15% affected	<1% affected
Laterality	45% affected <ul style="list-style-type: none"> <li>85% bilateral → 100% multi-focal → 45%</li> <li>15% unilateral                             <ul style="list-style-type: none"> <li>96% multi-focal → 45%</li> <li>4% uni-focal → 45%</li> </ul> </li> </ul> 55% unaffected → 0%	7%–15% affected <ul style="list-style-type: none"> <li>85% bilateral → 100% multi-focal → 45%</li> <li>15% unilateral                             <ul style="list-style-type: none"> <li>96% multi-focal → 45%</li> <li>4% uni-focal → 45%</li> </ul> </li> </ul> 85%–93% unaffected → 0%	<1% affected <ul style="list-style-type: none"> <li>33% bilateral → 100% multi-focal → 5%*</li> <li>67% unilateral                             <ul style="list-style-type: none"> <li>15% multi-focal → &lt;1%*</li> <li>85% uni-focal → &lt;1%*</li> </ul> </li> </ul> 99% unaffected → 0%
Focality	45% affected <ul style="list-style-type: none"> <li>85% bilateral → 100% multi-focal → 45%</li> <li>15% unilateral                             <ul style="list-style-type: none"> <li>96% multi-focal → 45%</li> <li>4% uni-focal → 45%</li> </ul> </li> </ul> 55% unaffected → 0%	7%–15% affected <ul style="list-style-type: none"> <li>85% bilateral → 100% multi-focal → 45%</li> <li>15% unilateral                             <ul style="list-style-type: none"> <li>96% multi-focal → 45%</li> <li>4% uni-focal → 45%</li> </ul> </li> </ul> 85%–93% unaffected → 0%	<1% affected <ul style="list-style-type: none"> <li>33% bilateral → 100% multi-focal → 5%*</li> <li>67% unilateral                             <ul style="list-style-type: none"> <li>15% multi-focal → &lt;1%*</li> <li>85% uni-focal → &lt;1%*</li> </ul> </li> </ul> 99% unaffected → 0%
Chance of next sibling having retinoblastoma	45%	45%	<1%*

\*If parent is a carrier, then 45%

Table created by David H. Abramson, MD.



**Table 25-9 International Classification of Retinoblastoma**

Group	Features
A	Small tumors ( $\leq 3$ mm) confined to the retina; $> 3$ mm from the fovea; $> 1.5$ mm from the optic disc
B	Tumors ( $> 3$ mm) confined to the retina in any location, with clear subretinal fluid $\leq 6$ mm from the tumor margin
C	Localized vitreous and/or subretinal seeding ( $< 6$ mm total from tumor margin) If there is more than 1 site of subretinal or vitreous seeding, the total of these sites is $< 6$ mm
D	Diffuse vitreous and/or subretinal seeding ( $\geq 6$ mm total from tumor margin) If there is more than 1 site of subretinal or vitreous seeding, the total of these sites is $\geq 6$ mm Subretinal fluid $> 6$ mm from tumor margin
E	No visual potential or Presence of any of the following: <ul style="list-style-type: none"> <li>• tumor in the anterior segment</li> <li>• tumor in or on the ciliary body</li> <li>• neovascular glaucoma</li> <li>• vitreous hemorrhage obscuring the tumor or significant hyphema</li> <li>• phthisical or prephthisical eye</li> <li>• orbital cellulitis-like presentation</li> </ul>

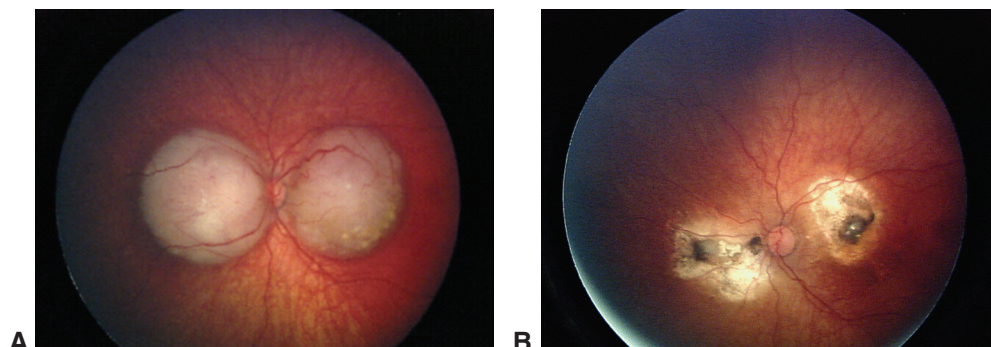
Modified from Shields CL, Mashayekhi A, Au AK, et al. The International Classification of Retinoblastoma predicts chemoreduction success. *Ophthalmology*. 2006;113(12):2276–2280.

### **Treatment**

The management of retinoblastoma has changed dramatically over the past decade and continues to evolve. Many specialists may be involved, including ocular oncologists, pediatric ophthalmologists, geneticists, genetic counselors, pediatric oncologists, and radiation oncologists. External-beam radiation is seldom used to treat intraocular retinoblastoma because of its high association with development of craniofacial deformity and secondary tumors in the field of radiation. When the likelihood of salvaging vision is low, primary enucleation of eyes with advanced unilateral retinoblastoma is often performed to avoid the adverse effects of systemic chemotherapy. To prevent extraocular spread of the tumor, the surgeon should minimize manipulation of the globe and obtain a long segment of optic nerve. Small retinoblastoma tumors can often be treated with either laser photocoagulation or cryotherapy.

Primary systemic chemotherapy (chemoreduction) followed by local therapy (consolidation) has been used to spare vision for larger tumors (Fig 25-28) and is often used in cases of bilateral retinoblastoma. Most studies of chemoreduction for retinoblastoma have used vincristine, carboplatin, and an epipodophyllotoxin. Others have added cyclosporine. Chemotherapy is rarely successful when used alone and often requires local therapy (cryotherapy, laser photocoagulation, thermotherapy, or plaque radiotherapy) as well. Adverse effects of chemoreduction treatment include low blood count, hair loss, hearing loss, renal toxicity, neurologic and cardiac disturbances, and possible increased risk for acute myelogenous leukemia.

Intra-arterial chemotherapy has recently been reported as an alternative to systemic chemoreduction for unilateral retinoblastoma in group B, C, D, or E eyes. Chemotherapy



**Figure 25-28** **A**, Left eye of an infant with bilateral retinoblastoma; 2 tumors straddle the optic nerve. **B**, After chemoreduction and laser consolidation, the tumors are nonviable. The child's visual acuity was 20/25 at age 5 years.

is delivered via cannulation of the ophthalmic artery in single or multiple sessions. Many chemotherapy agents have been used; melphalan is the most common. Overall, the results show higher rates of globe salvage in eyes treated initially and in those that did not respond to prior treatments. Systemic complications include neutropenia and metastasis. Ocular complications include vascular occlusion, blepharoptosis, cilia loss, temporary dysmotility, and periocular edema in the distribution of the supratrochlear artery. There is concern about the radiation that is delivered during the procedure, especially for patients with germline *RBI* gene mutations, who are at higher risk for malignant tumors.

Intravitreal chemotherapy has been used for refractory and recurrent vitreous seeding from retinoblastoma. Periocular injections have been used for adjuvant chemotherapy.

Treated retinoblastoma sometimes disappears altogether, but more often it persists as a calcified mass (type 1, or “cottage cheese,” pattern) or a noncalcified, translucent grayish lesion (type 2, or “fish flesh,” pattern), which may be difficult to distinguish from untreated tumor. Type 3 regression has elements of both types 1 and 2, and type 4 regression is a flat, atrophic scar. A child with treated retinoblastoma must be observed closely for new or recurrent tumor formation, with frequent examinations under anesthesia if necessary.

Extraocular retinoblastoma, though uncommon in the United States, is still problematic in developing countries, primarily because of delay in diagnosis. The 4 major types are optic nerve involvement, orbital invasion, central nervous system (CNS) involvement, and distant metastasis. Treatment of extraocular retinoblastoma includes intensive multimodality chemotherapy, autologous hematopoietic stem cell rescue, and external-beam radiotherapy. Long-term disease-free survival is possible if the CNS is not involved; otherwise, the prognosis is usually poor.

Patients with trilateral retinoblastoma have a primitive neuroectodermal tumor (PNET) of the pineal gland or parasellar region in addition to retinoblastoma. In patients with unilateral retinoblastoma, the risk of trilateral retinoblastoma has been less than 0.5%; in those with bilateral retinoblastoma, less than 5%–15%. However, the rate of trilateral retinoblastoma appears to be lower in patients treated with chemoreduction. Treatment usually involves a multimodal approach, and the prognosis is poor.

Abramson DH, Dunkel IJ, Brodie SE, Marr B, Gobin YP. Superselective ophthalmic artery chemotherapy as primary treatment for retinoblastoma (chemosurgery). *Ophthalmology*. 2010;117(8):1623–1629.

Shields CL, Alset AE, Say EA, Caywood E, Jabbour P, Shields JA. Retinoblastoma control with primary intra-arterial chemotherapy: outcomes before and during the intravitreal chemotherapy era. *J Pediatr Ophthalmol Strabismus*. 2016;53(5):275–284.

**Monitoring** Identification of *RBI* mutations is very useful in determining how frequently to monitor patients. Patients with unilateral tumors who have somatic mutations are not at risk for development of additional tumors (ocular or systemic). Patients who undergo globe salvage require frequent examinations to monitor for tumor recurrence. In these patients, examinations under anesthesia are typically performed every 4–8 weeks until age 3 years. Recurrence of retinoblastoma is common and can occur years after treatment.

In patients with germline mutations, periodic MRI of the brain is performed to screen for CNS metastases and PNET, which have poor prognoses. Results of genetic testing can also help determine whether siblings need to be monitored. If genetic testing is not available, siblings should be monitored routinely during the first 2 years of life.

Because of their risk of developing secondary malignancies, patients with germline mutations require long-term follow-up by oncologists and ophthalmologists. Nonocular tumors are common in these patients; the estimated incidence rate is 1% per year of life (eg, 10% prevalence by age 10 years, 30% by age 30 years). The incidence is higher among patients treated with external-beam radiation before 1 year of age. The most common secondary tumors (and the mean age at diagnosis) are PNET (2.7 years), sarcoma (13 years), melanoma (27 years), and carcinomas (29 years). For patients with second nonocular tumors, the risk of additional malignant tumors is even greater.

Correa ZM, Berry JL. Review of retinoblastoma. Pediatric Ophthalmology Education Center. April 28, 2016. Available at <https://www.aao.org/disease-review/review-of-retinoblastoma>.

Woo KI, Harbour JW. Review of 676 second primary tumors in patients with retinoblastoma: association between age at onset and tumor type. *Arch Ophthalmol*. 2010;128(7):865–870.

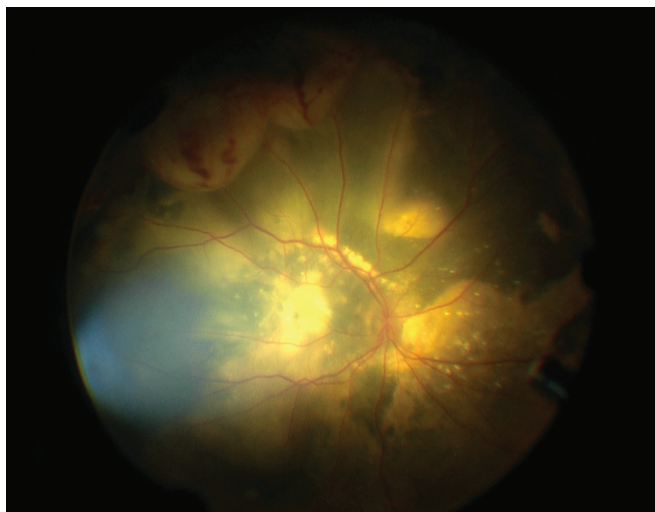
## Acquired Disorders

---

### Coats Disease

The classic findings in Coats disease are yellow subretinal and intraretinal lipid exudates associated with retinal vascular abnormalities—most often telangiectasia, tortuosity, aneurysmal dilatations, and retinal capillary nonperfusion. The clinical presentation varies, ranging from mild changes to total retinal detachment (Fig 25-29).

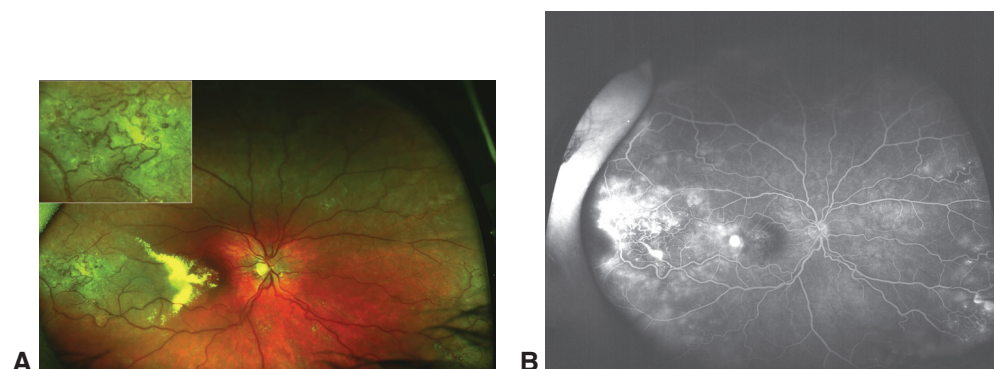
Males are affected more frequently than females, and the condition is usually, but not always, unilateral. The average age at diagnosis is 6–8 years, but the disease has also been observed in infants. The etiology of Coats disease is unknown. Associations with various gene deletions have been reported, but the disease is isolated in most cases.



**Figure 25-29** Advanced Coats disease with extensive subretinal exudation and total retinal detachment. Superior retinal macrocysts—associated with macroaneurysms and dilated, tortuous vessels—are present. (Courtesy of Scott C. Oliver, MD.)

### Diagnosis

The diagnosis of Coats disease requires the presence of abnormal retinal vessels, which occasionally are small and difficult to find. The subretinal exudate is thought to come from the leaking anomalous vessels. Fluorescein angiography may be helpful in identifying leakage from the telangiectatic vessels and in assessing the effectiveness of therapy (Fig 25-30). Oral fluorescein can be used in place of intravenous fluorescein in the ambulatory setting to monitor disease and avoid examination under anesthesia.



**Figure 25-30** Coats disease. **A**, Ultra-wide-angle color photograph reveals foveal exudation with temporal macroaneurysms and telangiectasias. Inset shows magnification of macroaneurysms and telangiectasias. Subtle nasal telangiectasias are also present. **B**, Image obtained with oral fluorescein angiography shows extensive leakage from temporal macroaneurysms, mild leakage from temporal and nasal telangiectasias, and macular leakage with some staining. (Courtesy of Scott C. Oliver, MD.)

The differential diagnosis includes persistent fetal vasculature, ROP, toxocariasis, FEVR, Norrie disease, retinal dysplasia, endophthalmitis, leukemia, and retinoblastoma. Calcium is frequently detected by ultrasonography in retinoblastoma but is distinctly rare in Coats disease. Coats disease often presents with xanthocoria (yellow pupillary reflex), whereas retinoblastoma presents with leukocoria.

### **Treatment**

Treatment is directed at obliterating the abnormal leaking vessels and includes cryotherapy, laser photocoagulation, vitrectomy, and silicone oil. Exudative retinal detachments and subretinal fibrosis develop in eyes with progressive disease. Once the fovea is detached and the subretinal exudate becomes organized, the prognosis for restoration of central vision is poor. Use of intravitreal bevacizumab in addition to laser treatment has been reported, but one study found that this approach was associated with a higher incidence of vitreoretinal fibrosis and tractional retinal detachment.

Mulvihill A, Morris B. A population-based study of Coats disease in the United Kingdom II: investigation, treatment, and outcomes. *Eye (Lond)*. 2010;24(12):1802–1807.

Ramasubramanian A, Shields CL. Bevacizumab for Coats disease with exudative retinal detachment and risk of vitreoretinal traction. *Br J Ophthalmol*. 2012;96(3):356–359.

# Optic Disc Abnormalities



This chapter includes a related video, which can be accessed by scanning the QR code provided in the text or going to [www.aao.org/bcscvideo\\_section06](http://www.aao.org/bcscvideo_section06).

## Developmental Anomalies

---

Developmental abnormalities of the optic nerve may or may not limit vision. To maximize visual potential in a child with an optic disc (also called *optic nerve head*) abnormality, treatment of possible superimposed amblyopia should always be considered.

### Optic Nerve Hypoplasia

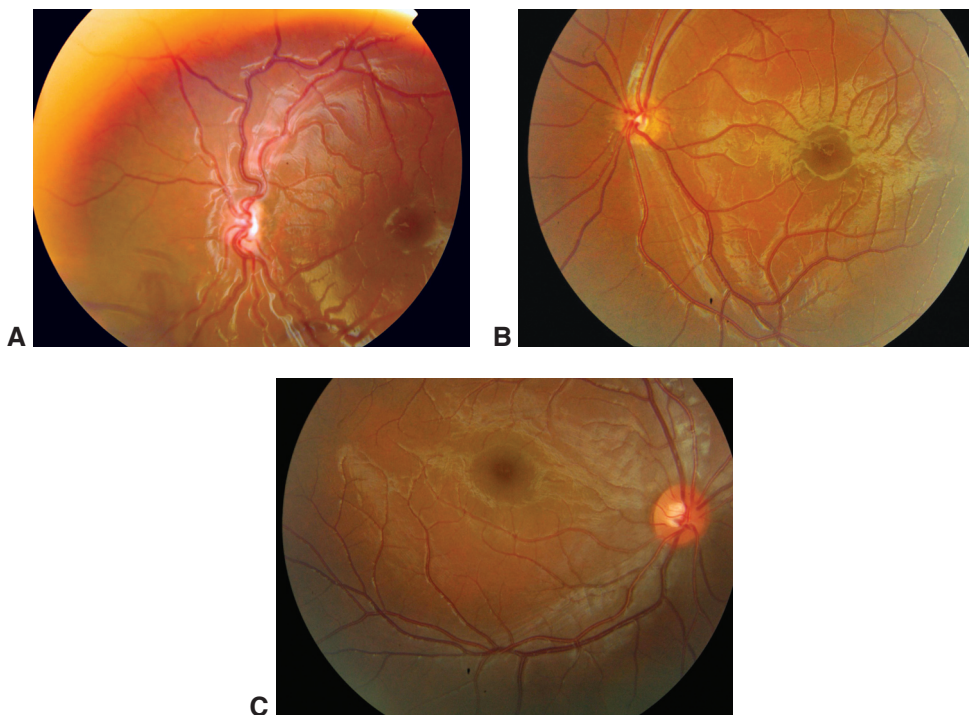
Optic nerve hypoplasia (ONH), the most common developmental optic disc anomaly, is characterized by a decreased number of optic nerve axons. It can be unilateral, bilateral, or segmental and is often asymmetric if bilateral. The typical affected disc can be pale, gray, and relatively small with vascular tortuosity (Fig 26-1A). A yellow-to-white ring around the disc (corresponding to abnormal extension of retina over the lamina cribrosa), known as the *double ring sign*, may be present. When the double ring sign is present, the hypoplastic disc–ring complex can be mistaken for a normal-sized optic nerve with normal cup–disc ratio (Fig 26-1B, C).

Visual acuity can range from 20/20 to no light perception. The extent of papillomacular fiber involvement and any associated amblyopia determines visual acuity.

ONH is usually idiopathic and sporadic. It is more prevalent in fetal alcohol syndrome. Segmental ONH may be associated with maternal diabetes mellitus. ONH may be associated with central nervous system (CNS) abnormalities and pituitary gland dysfunction.

*Septo-optic dysplasia (de Morsier syndrome)* is the association of ONH with absence of the septum pellucidum and agenesis of the corpus callosum (Figs 26-2, 26-3). As isolated abnormalities, these neuroimaging findings are not associated with neurodevelopmental or endocrinologic problems. Cerebral hemisphere abnormalities such as schizencephaly, periventricular leukomalacia, and encephalomalacia occur in approximately 45% of patients with ONH and are associated with neurodevelopmental defects.

Patients with ONH can have pituitary gland abnormalities, which are important to rule out in children who present with ONH. Magnetic resonance imaging (MRI) in affected patients reveals an ectopic posterior pituitary bright spot at the upper infundibulum. This finding is associated with pituitary hormone deficiencies, including growth



**Figure 26-1** **A**, Left optic nerve hypoplasia. Note the small, pale disc with vascular tortuosity. **B**, Left optic nerve hypoplasia with the double ring sign. When viewed quickly, the hypoplastic disc–ring complex may be mistaken for a normal-sized optic nerve. **C**, The normal right optic disc of the patient shown in part B. (Courtesy of Arif O. Khan, MD.)

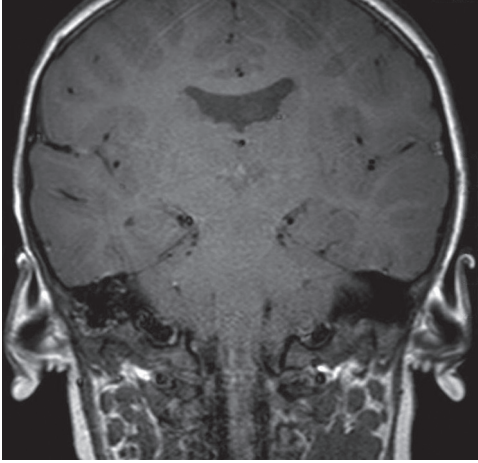
hormone deficiency, hypothyroidism, hyperprolactinemia, hypocortisolism, panhypopituitarism, and diabetes insipidus. A history of neonatal jaundice suggests hypothyroidism; neonatal hypoglycemia or seizures indicate possible panhypopituitarism. Patients with ONH and hypocortisolism, especially with diabetes insipidus, can have problems with thermal regulation and dehydration and must be monitored carefully during febrile illnesses.

Children with periventricular leukomalacia can have a variant of ONH that may be mistaken for glaucomatous cupping. The optic nerve has a large cup within a normal-sized optic disc secondary to transsynaptic degeneration of optic axons, a consequence of lesions in the optic radiations. This form of ONH is not associated with endocrine deficiencies.

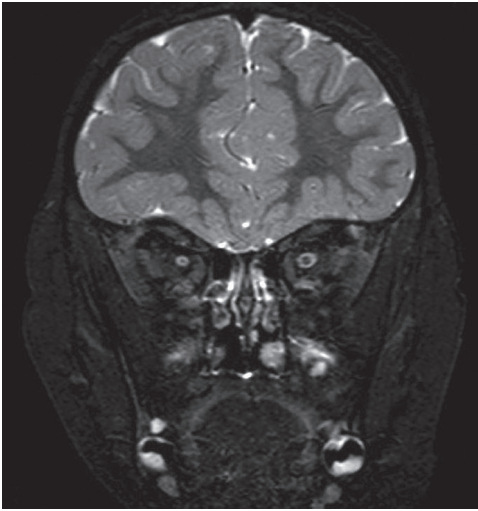
Garcia-Filion P, Borchert M. Optic nerve hypoplasia syndrome: a review of the epidemiology and clinical associations. *Curr Treat Options Neurol*. 2013;15(1):78–89.

### Morning Glory Disc Anomaly

Morning glory disc anomaly (MGDA) is the result of abnormal development of the distal optic stalk at its junction with the primitive optic vesicle. The anomaly is typically unilateral and is more common in girls. Serous retinal detachments occur in one-third of cases.



**Figure 26-2** Coronal T1-weighted magnetic resonance imaging (MRI) scan of the lateral ventricles: the septum pellucidum (interventricular septum) is absent. (Courtesy of Jane L. Weissman, MD.)



**Figure 26-3** Coronal T2-weighted MRI scan of the orbits: the right optic nerve is smaller and more T2 hyperintense than the left optic nerve. (Courtesy of Jane L. Weissman, MD.)

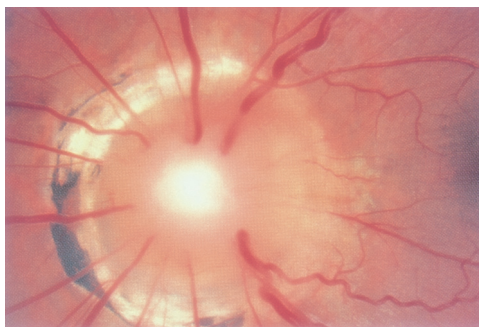MGDA has been associated with basal encephalocele in patients with midline abnormalities, PHACE syndrome (*posterior fossa malformations, hemangiomas, arterial lesions, cardiac and eye anomalies*), and carotid circulation abnormalities (moyamoya disease).

MGDA typically appears as a funnel-shaped excavation of the posterior fundus that incorporates an enlarged optic disc with elevated surrounding retinal pigment epithelium and an increased number of blood vessels looping at the edges of the disc (Fig 26-4). A core of white glial tissue occupies the normal position of the optic cup. This tissue may have contractile elements, as the optic cup can sometimes be seen to open and close with some periodicity.

Visual acuity ranges from 20/20 to no light perception, but it is usually 20/100 to 20/200. Because of the potential for associated CNS abnormalities, MRI and MR angiography should be considered.



**Figure 26-4** Morning glory disc anomaly, left eye.



### Optic Nerve Coloboma

Optic nerve coloboma results from incomplete closure of the embryonic fissure. It can be associated with iris coloboma and adjacent or peripheral chorioretinal coloboma. Optic nerve coloboma can be unilateral or bilateral and is often asymmetric.

Typically, there is an inferonasal excavation of the optic disc that, when mild, may be confused with glaucomatous damage. More extensive defects appear as an enlargement of the peripapillary area with a deep central excavation lined by a glistening white tissue; blood vessels overlie this deep cavity (Fig 26-5). When chorioretinal coloboma is coexistent, there is a risk for retinal detachment. Visual acuity is related to involvement of the papillomacular or foveal region and is difficult to predict.

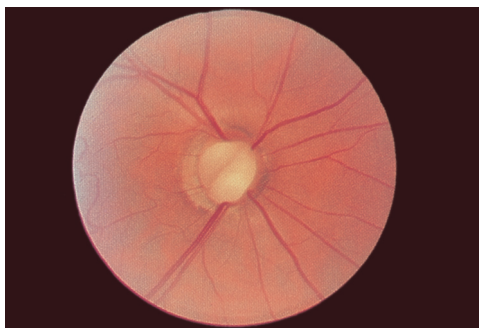Ocular colobomas may be associated with multiple systemic abnormalities and a number of syndromes, such as the CHARGE syndrome (coloboma, heart defects, choanal atresia, mental retardation, genitourinary abnormalities, and ear abnormalities).

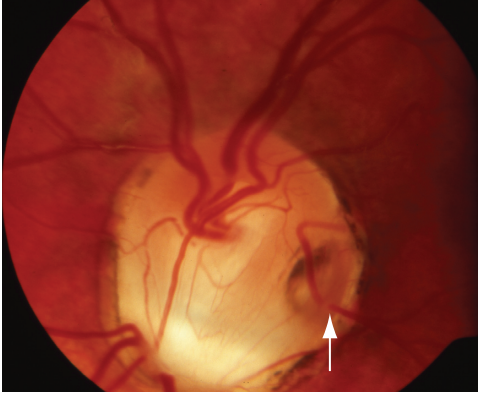### Optic Nerve Pit

Optic nerve pit (optic hole) represents herniation of dysplastic retina into a collagen-lined pocket extending posteriorly, often into the subarachnoid space, through a defect in the lamina cribrosa. It is typically unilateral. There is an association with serous macular detachments in the second and third decades of life.

The typical appearance is a round or oval, gray, white, or yellowish depression in the inferotemporal quadrant or central portion of the disc, often covered with a gray veil of tissue and emerging cilioretinal vessels (Fig 26-6).

**Figure 26-5** Optic nerve coloboma, right eye.





**Figure 26-6** Left optic nerve with a temporal optic nerve pit (*arrow*) and a mild inferonasal disc coloboma. Cilioretinal vessels can be seen emanating from the optic nerve pit. (Courtesy of Paul Phillips, MD.)

Some have considered this entity to be a variant of coloboma, but it is distinct and there is no association with iris or chorioretinal coloboma.

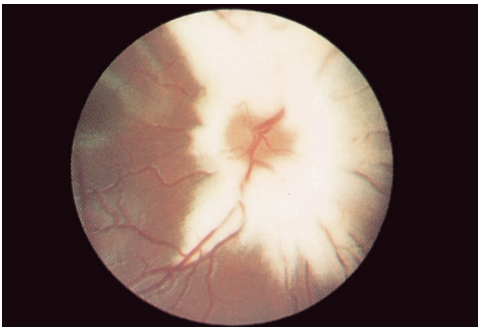
### Myelinated Retinal Nerve Fiber Layer

Myelination of the optic nerve normally stops at the lamina cribrosa. Inappropriate myelination anterior to the lamina cribrosa causes scotomata or central vision loss. Particularly when the macula is involved, myelinated retinal nerve fibers are associated with ipsilateral high myopia and resultant anisometric amblyopia. In some cases, the macula is hypoplastic.

Clinically, myelinated nerve fibers appear as a white superficial retinal area, the frayed and feathered edges of which tend to follow the same orientation as that of the normal retinal nerve fibers (Fig 26-7). Retinal vessels that pass within the superficial layer of the nerve fibers are obscured. The myelinated fibers may occur as a single spot or as several noncontiguous patches. The most common location is along the disc margin.

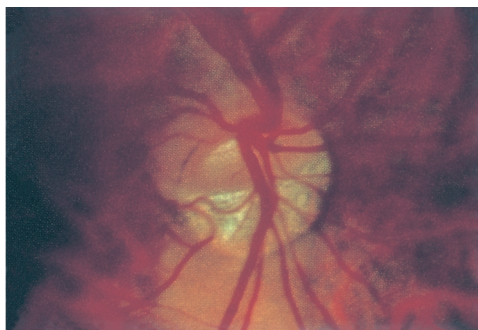
### Tilted Disc

In a patient with a tilted disc, often the superior pole of the optic disc appears elevated, with posterior displacement of the inferior nasal disc. Alternatively, the disc is tilted horizontally, resulting in an oval disc with an oblique long axis (Fig 26-8). Tilted disc is often



**Figure 26-7** Myelinated nerve fibers of the optic nerve and retina, right eye.

**Figure 26-8** Tilted disc, right eye.



associated with a scleral crescent located inferiorly or inferonasally, situs inversus, posterior ectasia of the inferior nasal fundus, and myopia and astigmatism.

Patients may demonstrate superotemporal visual field defects, which may resolve with refractive correction. Tilted discs, myopic astigmatism, bilateral decreased vision, and visual difficulty at night suggest the possibility of X-linked congenital stationary night blindness (see Chapter 25). Acquired tilted disc and peripapillary crescent formation have been documented in children with myopic progression.

Kim TW, Kim M, Weinreb RN, et al. Optic disc changes with incipient myopia of childhood. *Ophthalmology*. 2012;119(1):21–26.

### **Bergmeister Papilla**

A form of persistent fetal vasculature, Bergmeister papilla is a benign prepapillary glial remnant of the hyaloid artery, which is normally resorbed before birth. In some cases, a hyaloid artery remnant extends from the optic disc to the lens (typically inferonasally) and may contain blood.

### **Megalopapilla**

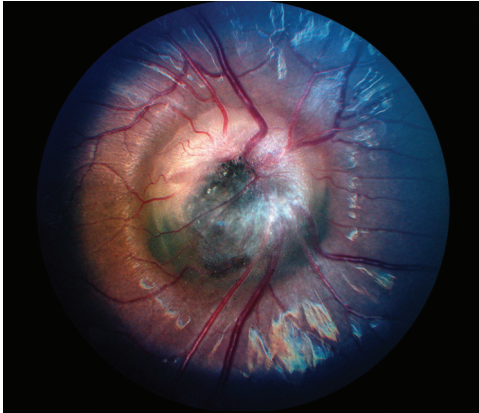
Megalopapilla is an abnormally large optic disc (area >2.5 mm<sup>2</sup>). The commonly associated large cup can be mistaken for glaucomatous damage.

### **Peripapillary Staphyloma**

Peripapillary staphyloma is a posterior bulging of the sclera encompassing the optic disc. White sclera encircling the disc is often visible. Vision is usually poor. The condition is usually unilateral and rarely bilateral.

### **Optic Nerve Aplasia**

Optic nerve aplasia, a lack of optic nerve axons and retinal blood vessels, is very rare. The choroidal pattern is clearly visible. When bilateral, optic nerve aplasia is usually associated with other CNS malformations; when unilateral, it can occur with normal brain development.



**Figure 26-9** Melanocytoma of the optic disc and adjacent retina. (Courtesy of Scott Lambert, MD.)

### Melanocytoma of the Optic Disc

Melanocytoma is a darkly pigmented tumor with little or no growth potential. It usually involves the optic disc and adjacent retina (Fig 26-9).

## Optic Atrophy

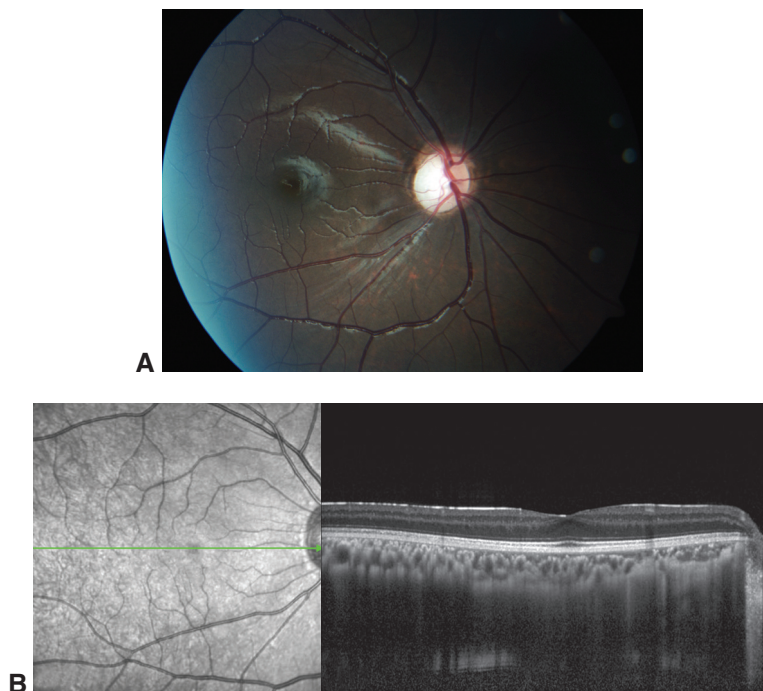
Optic atrophy in children can be inherited (autosomal dominant, autosomal recessive, X-linked, or mitochondrial) or can be secondary to anterior visual pathway disease such as inflammation (optic neuritis), perinatal hypoxic–ischemic injury, hydrocephalus, or optic nerve or chiasmal tumors. Table 26-1 lists causes of acquired optic atrophy. Neuroimaging should be considered for all patients with optic atrophy of undetermined etiology because tumor or hydrocephalus is present in over 40% of these cases. Specific underlying gene defects may be inferred from coexisting systemic features (eg, Wolfram syndrome or Behr optic atrophy).

### Dominant Optic Atrophy, Kjer Type

Dominant optic atrophy is characterized by bilateral slow loss of central vision, usually before 10 years of age. It is caused by heterozygous mutations in *OPA1*. Visual acuity ranges from 20/40 to 20/100, with visual acuity rarely worse than 20/200. Visual field tests show

**Table 26-1 Causes of Acquired Optic Atrophy in Childhood**

Craniopharyngioma
Hereditary optic atrophy
Hydrocephalus
Optic nerve/chiasmal glioma
Optic neuritis
Perinatal hypoxic–ischemic injury
Postpapilledema
Retinal degenerative disease



**Figure 26-10** **A**, The optic disc, right eye, shows temporal pallor. The left eye was similar in this boy with dominant optic atrophy and confirmed heterozygous *OPA1* mutation. **B**, Corresponding optical coherence tomography image shows a lack of nerve fiber and ganglion cell layers (left eye was similar). (Courtesy of Arif O. Khan, MD.)

central or cecentral scotomata with normal peripheral isopters. Color vision testing reveals a blue dyschromatopsia. The optic disc shows a characteristic temporal wedge of pallor, often with triangular excavation (Fig 26-10).

### Recessive Optic Atrophy

Recessive optic atrophy is characterized by severe bilateral vision loss before 5 years of age, often associated with nystagmus. Wolfram syndrome is optic atrophy caused by biallelic mutations in *WFS1*, with variable expressivity of hearing loss and diabetes mellitus. Similarly, Behr optic atrophy is caused by biallelic mutations in *OPA1*, with variable expressivity of neurologic findings such as ataxia, pyramidal signs, spasticity, bladder dysfunction, and intellectual disability.

### Leber Hereditary Optic Neuropathy

Leber hereditary optic neuropathy is a maternally inherited (mitochondrial) disease characterized by acute or subacute bilateral loss of central vision, optic disc edema in the acute phase, acquired red-green dyschromatopsia, and central or cecentral scotomata in otherwise healthy patients (usually males) in their second to fourth decade of life. See BCSC Section 5, *Neuro-Ophthalmology*, for further discussion.

## Optic Neuritis

Optic neuritis in childhood is often seen after systemic infections such as viral illnesses. It can also be associated with immunizations and bee stings. The cause of the postinfectious form of viral optic neuritis is unknown. It has been speculated that an autoimmune process, triggered by a previous viral infection, results in a demyelinating injury.

Optic neuritis in children, in contrast with that in adults, is more often bilateral and associated with disc edema. Vision loss can be severe. Over half of affected children have systemic symptoms, including headache, nausea, vomiting, lethargy, or malaise.

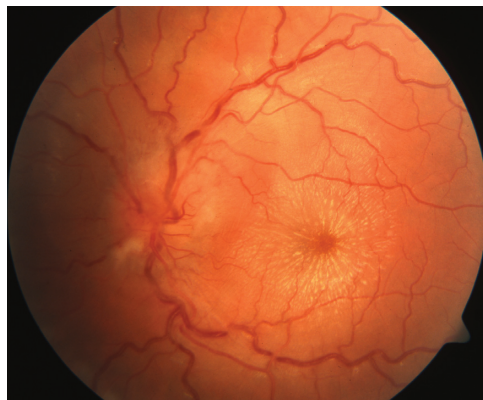In children, optic neuritis can occur as an isolated neurologic deficit or as a component of more generalized neurologic disease, such as acute disseminated encephalomyelitis, neuromyelitis optica, or multiple sclerosis. The relationship between optic neuritis and the later development of multiple sclerosis, which is common in adults, is less clear in children. In a small subset of children with optic neuritis, signs and symptoms consistent with multiple sclerosis develop. Older age and MRI findings extrinsic to the visual system are associated with increased risk of multiple sclerosis.

Treatment of optic neuritis in children is controversial. As vision loss is often bilateral, treatment with intravenous corticosteroids should be considered in order to hasten visual recovery. The Optic Neuritis Treatment Trial did not specifically address the issue of treatment in children, so it is difficult to apply the results of this study to these patients. See also BCSC Section 5, *Neuro-Ophthalmology*.

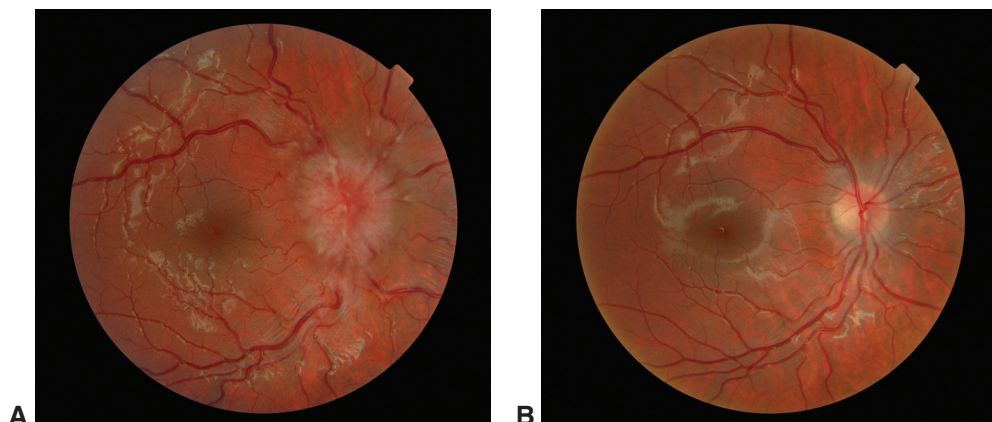*Neuroretinitis* denotes inflammatory disc edema associated with a stellate pattern of exudates in the macula (macular star; Fig 26-11). Common etiologies differ by region. In North America, a common etiology is *Bartonella henselae* infection (cat-scratch disease). Other infectious etiologies include mumps, toxocariasis, tuberculosis, and syphilis. Patients with neuroretinitis are not at risk for development of multiple sclerosis.

Children initially suspected to have optic neuritis should be reevaluated for potential emergence of macular edema, which would reclassify the diagnosis as neuroretinitis.

Waldman AT, Stull LB, Galetta SL, Balcer LJ, Liu GT. Pediatric optic neuritis and risk of multiple sclerosis: meta-analysis of observational studies. *J AAPOS*. 2011;15(5):441–446.



**Figure 26-11** Neuroretinitis. Inflammatory optic disc edema with a macular star. (Courtesy of Paul Phillips, MD.)



**Figure 26-12** Papilledema in the right eye of a child with idiopathic intracranial hypertension before treatment (**A**) and 3 months after treatment with oral acetazolamide (**B**). Resolution in the left eye was similar. Also see Video 26-1. (Courtesy of Robert W. Hered, MD.)

## Papilledema

*Papilledema* refers to optic disc edema secondary to elevated intracranial pressure (ICP) (Fig 26-12). It is typically bilateral. Initially, visual acuity, color vision, and pupillary reactions are normal. However, visual dysfunction may occur as a result of severe or chronic papilledema. Classic signs include disc hyperemia, retinal hemorrhages and exudates, and obscuration of vessels at the disc margin.

A number of conditions (eg, hydrocephalus, intracranial mass lesions, meningitis, idiopathic intracranial hypertension) can cause increased ICP in children and thus disc swelling (Table 26-2). A full evaluation, including neuroimaging possibly followed by lumbar puncture, is indicated. In infants, increased ICP results in firmness and distention of the open fontanelles. Significantly elevated pressure is usually accompanied by nausea, vomiting, and headaches. Older children may describe transient visual obscurations. Sixth nerve palsy can be a sign of elevated ICP.

### Idiopathic Intracranial Hypertension

Idiopathic intracranial hypertension (IIH), or *pseudotumor cerebri*, is characterized by increased ICP with normal-sized or small ventricles on neuroimaging, and normal cerebrospinal fluid. IIH is uncommon in childhood but can occur at any age. It may be associated with viral infections, excessive vitamin A, and certain drugs (eg, tetracycline, corticosteroids, nalidixic acid, thyroid medications, and growth hormone). Magnetic resonance venography is recommended to rule out cerebral venous sinus thrombosis. In *prepubescent* children with IIH, the incidence of obesity is lower compared with that in adult IIH patients, and the male to female ratio is approximately equal. *Postpubescent* children with IIH have a clinical profile similar to that of adult IIH patients, with a higher incidence of obesity and female preponderance. Down syndrome is also associated with IIH.

**Table 26-2 Conditions Associated With Pediatric Optic Disc Swelling**


---

Papillitis
Optic neuritis (postinfectious)
Toxoplasmosis
Lyme disease
<i>Bartonella</i> infection
Neuroretinitis
<i>Toxocara</i> infection of disc
Leber hereditary optic neuropathy
Papilledema
Intracranial mass
Meningitis
Idiopathic intracranial hypertension
Dural sinus thrombosis
Cranial synostosis
Hydrocephalus
Chiari malformation
Aqueductal stenosis
Dandy-Walker syndrome
Infection
Hypertension
Optic nerve glioma
Leukemic infiltrate
Pseudopapilledema
Astrocytoma of optic disc (tuberous sclerosis)
Optic disc drusen
Hyperopic discs
Prominent disc glial tissue

---

Common presenting symptoms are headache, vision loss, transient visual obscurations, and diplopia. Papilledema may be noted on routine examination of an asymptomatic child. Examination frequently reveals excellent visual acuity with bilateral papilledema. Unilateral or bilateral sixth nerve palsy may be present. The patient should be monitored closely for decreased visual acuity, visual field loss, and worsening headaches. Visual field tests can be difficult to interpret in children but should be performed if possible.

Treatment of IIH begins with discontinuation of any causative medications. Medical treatment includes acetazolamide and topiramate (see Fig 26-12). Video 26-1 shows the gradual resolution (over a 3-month period) of papilledema in a child being treated for IIH. Surgical treatment options include optic nerve sheath fenestration or shunting procedures (lumbar or ventriculoperitoneal), both of which can reduce the incidence of vision loss. Shunting procedures are preferred for patients with good visual function and severe headaches unresponsive to medical management. With treatment, the visual prognosis is excellent for most patients, although vision loss can occur secondary to chronic papilledema. In most cases, spontaneous resolution occurs within 12–18 months of initial treatment.

See BCSC Section 5, *Neuro-Ophthalmology*, for further discussion.



**VIDEO 26-1** Gradual resolution of papilledema during treatment of idiopathic intracranial hypertension.

*Courtesy of Robert W. Hered, MD.*



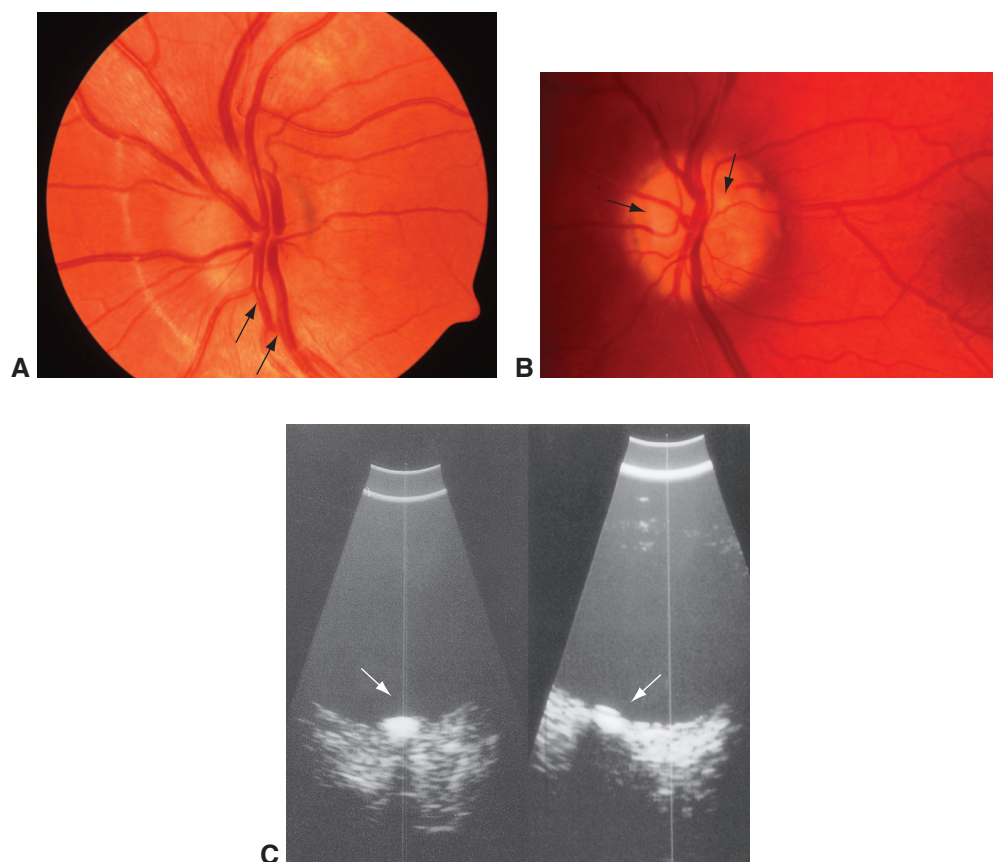
Access all Section 6 videos at [www.aao.org/bcscvideo\\_section06](http://www.aao.org/bcscvideo_section06).



## Pseudopapilledema

*Pseudopapilledema* refers to any elevated anomaly of the optic disc that resembles papilledema (see Table 26-2). Conditions that are frequently confused with papilledema in children include disc drusen, hyperopic discs, and prominent disc glial tissue. Pseudopapilledema can be differentiated from true papilledema by the absence of disc hyperemia and retinal hemorrhages and exudates, and by the lack of obscuration of vessels at the disc margin (Fig 26-13). Pseudopapilledema can be associated with anomalous branching of the large peripapillary retinal vessels. However, clinical examination findings can be ambiguous.

Most children with pseudopapilledema do not have other related ophthalmic or systemic abnormalities. However, pseudopapilledema is associated with retinal dystrophy, Down syndrome, and Alagille syndrome. Down syndrome is associated with IIH as well; thus, an elevated optic disc in a child with Down syndrome should not be assumed to



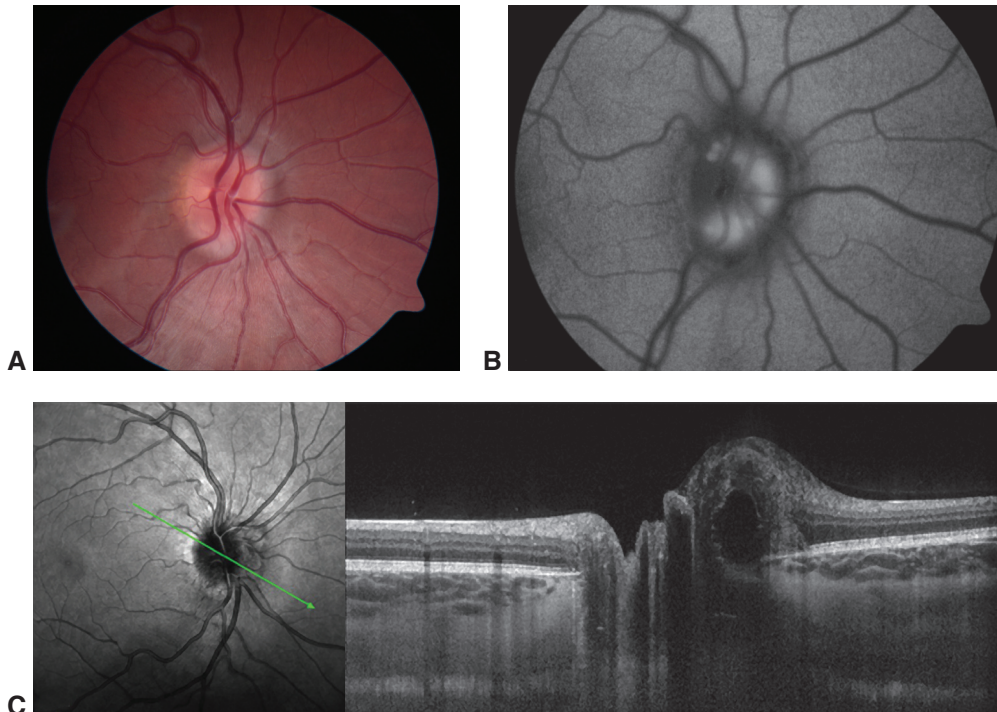
**Figure 26-13** **A**, Pseudopapilledema. There is anomalous branching (*arrows*) of the large retinal vessels without disc hyperemia, retinal hemorrhages, or exudates. **B**, Optic disc drusen seen as refractile opacities on the disc surface (*arrows*). **C**, Ultrasonographic image shows a bright spot in the optic disc (*arrows*), consistent with drusen. (*Parts A and B* courtesy of Paul Phillips, MD; *part C* courtesy of Edward G. Buckley, MD.)

be benign. If clinical symptoms and signs of elevated ICP (headaches, sixth nerve palsy, true papilledema) are present, neuroimaging followed by lumbar puncture should be obtained.

## Drusen

Intrapapillary drusen, the most common cause of pseudopapilledema in children, can appear within the first or second decade of life (Fig 26-14; see also Fig 26-13B). Drusen are frequently inherited (autosomal dominant); thus, examination of the parents is helpful when drusen are suspected in children.

Clinically, the elevated disc does not obscure the retinal arterioles lying anteriorly and often has an irregular border suggesting the presence of drusen beneath the surface. There is no dilatation of the papillary network, and superficial retinal hemorrhages and exudates are absent. Peripapillary subretinal hemorrhages and subretinal neovascular membranes rarely occur. When drusen are not buried, they appear as shiny refractile bodies visible on the disc surface, with a gray-yellow translucent appearance. Visual field defects are frequently associated; inferior nasal field defects are common. Concentric narrowing, an arcuate scotoma, and central defects can also occur. These defects can be slowly progressive. Visual acuity is rarely affected.



**Figure 26-14** **A**, Superficial optic disc drusen, right eye. **B**, Appearance with autofluorescence. **C**, Optical coherence tomography image from a different child with drusen reveals the typical “lumpy bumpy” appearance. (Courtesy of Wayne T. Cornblath, MD.)

In some patients, fundus evaluation can identify drusen as the cause of the swollen disc appearance. In others, B-scan ultrasonography can be helpful in detecting bright calcific reflections at the optic disc (see Fig 26-13C). Autofluorescence imaging and optical coherence tomography can also be useful (see Fig 26-14).

Most children with optic disc drusen do not have other related ophthalmic or systemic abnormalities. However, children with retinal dystrophy or pseudoxanthoma elasticum have a higher incidence of optic disc drusen compared with the general population.

# Ocular Trauma in Childhood

## Special Considerations in the Management of Pediatric Ocular Trauma

---

Trauma is one of the most important causes of ocular morbidity in childhood. The management of eye trauma in very young patients requires special consideration of issues common in or unique to this patient population. One issue is the evaluation and treatment of accidental or nonaccidental trauma despite inadequate patient cooperation or an unreliable history. If the physician uses force to examine the child's eye, there is a risk of exacerbating the damage caused by penetrating wounds or blunt impact. When preliminary assessment indicates that prompt surgical treatment may be necessary, it is appropriate to defer detailed physical examination of the eye until the patient is in the operating room and under general anesthesia.

Another issue is the potential for the injury to cause amblyopia. In children younger than 5–7 years, deprivation amblyopia associated with traumatic cataract or other media opacity can cause severe, long-term reduction of vision even after appropriate management of the original physical damage. Minimizing the interval between the injury and the restoration of optimal media clarity and optics, including adequate aphakic refractive correction, is thus a high priority. Monocular occlusion following injury should be kept to a minimum; the expected benefit from an occlusive dressing must be weighed against the risk of disturbing binocular function or inducing amblyopia in a very young child.

## Accidental Trauma

---

In younger children, most accidental ocular trauma occurs during casual play with other children. Older children and adolescents are most likely to be injured while participating in sports. Fireworks, BB guns, and various projectiles are less frequent causes of pediatric ocular trauma, but they are likely to cause severe injuries. The incidence of severe eye injury is particularly high in children aged 11–15 years compared with that in other age groups. Injured boys outnumber girls by a factor of 3 or 4 to 1.

Most serious childhood eye injuries could, in principle, be prevented by appropriate adult supervision and by regular use of protective eyewear during sports activities. These measures are particularly important for the child who already has monocular vision loss.

American Academy of Pediatrics, Committee on Sports Medicine and Fitness; American Academy of Ophthalmology, Eye Health and Public Information Task Force. Protective eyewear for young athletes. *Ophthalmology*. 2004;111(3):600–603.

### **Corneal Abrasion**

Corneal abrasion is one of the most common ocular injuries in children and adults. Disruption of the corneal epithelium is usually associated with immediate pain, foreign-body sensation, tearing, and discomfort with blinking. Topical cycloplegic drops and antibiotic ointment may help reduce discomfort and the risk of infection, respectively. Traumatic corneal epithelial defects usually heal within 1–2 days. A pressure patch to keep the eyelids closed is not necessary for most abrasions. Many children find the patch uncomfortable, and patching does not reduce the time required for the abrasion to heal.

### **Thermal Injury**

Cigarette burns of the cornea are the most common thermal injuries to the ocular surface in childhood. Usually, these occur in toddlers and are accidental, not manifestations of abuse. The burns usually result from the child running into a cigarette held at eye level by an adult. Despite the alarming initial white appearance of coagulated corneal epithelium, cigarette burns typically heal in a few days and without scarring. Treatment is the same as treatment of corneal abrasions (discussed in the previous section).

### **Chemical Injury**

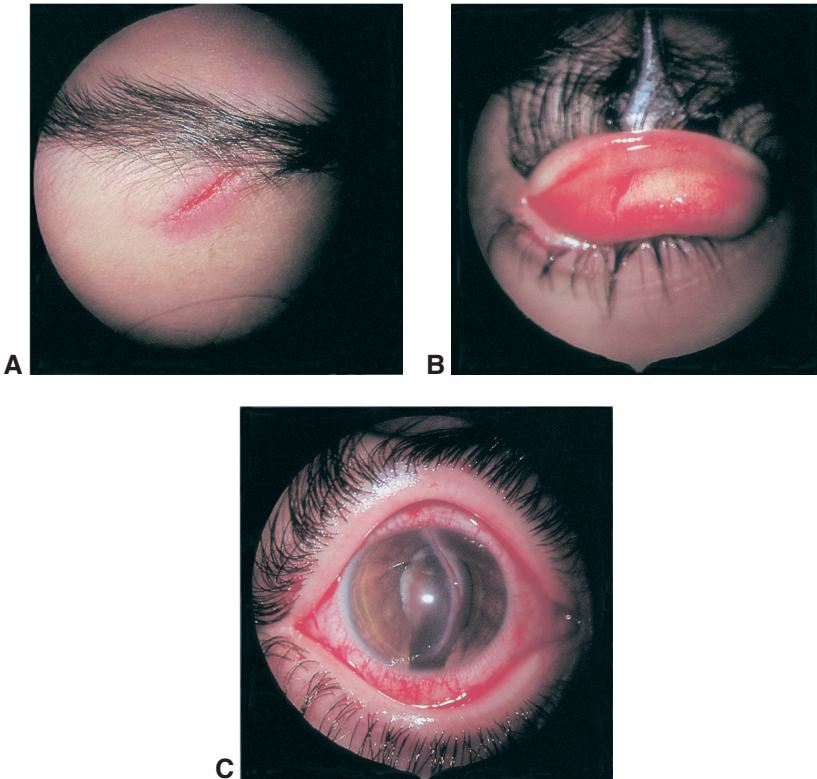
Chemical burns in childhood are generally caused by organic solvents or soaps in household cleaning agents. Even burns involving almost total loss of corneal epithelium are likely to heal in a week or less with or without patching. Acid and alkali burns in children, as in adults, can be much more serious. The initial and most important step in management of all chemical injuries is immediate copious irrigation and meticulous removal of any particulate matter from the conjunctival fornices. See BCSC Section 8, *External Disease and Cornea*, for additional discussion.

### **Corneal Foreign Body**

Corneal foreign bodies in children can sometimes be dislodged with a forceful stream of irrigating solution. After topical anesthetic is applied, a cotton swab or blunt spatula can often be used to remove the corneal foreign body, with or without a slit lamp; use of sharp instruments should be avoided. If these methods are unsuccessful, the child may require sedation or general anesthesia to facilitate removal of the foreign body.

### **Penetrating or Perforating Injury**

Unless an adult has witnessed the traumatic incident, the history cannot be relied upon to exclude the possibility of penetrating injury to the globe. The anterior segment and fundus must be thoroughly inspected. An examination under anesthesia may be necessary



**Figure 27-1** **A**, Small skin entry wound, right brow region, in a 7-year-old boy. The wound was created by a thrown dart. **B**, Conjunctival exit wound indicates complete perforation of the eyelid. **C**, Extensive injury to the anterior segment of the same eye.

when a penetrating injury is suspected. An area of subconjunctival hemorrhage or chemosis or a small break in the skin of the eyelid may be the only surface manifestation of scleral perforation by a sharp-pointed object, such as a pencil or scissors blade (Fig 27-1). Distortion of the pupil may be the most evident sign of a small corneal or limbal perforation. Imaging should be considered if there is any reason to suspect an intraocular or orbital foreign body.

Corneoscleral lacerations in children are repaired using the same principles employed for these repairs in adults (see BCSC Section 8, *External Disease and Cornea*). Corneal wounds heal relatively rapidly in very young patients; sutures should be removed correspondingly earlier. Small conjunctival lacerations are often self-sealing.

After a penetrating injury to the cornea, fibrin clots may form quickly in the anterior chamber of a child's eye, and these can simulate the appearance of fluffy cataractous lens cortex. To avoid rendering the eye aphakic unnecessarily (and thereby compromising vision rehabilitation), the clinician should not remove the lens as part of primary wound repair unless absolutely certain that the anterior capsule has been ruptured. Even if lens cortex is exposed, postponing cataract surgery for 1–2 weeks, until severe posttraumatic

inflammation has resolved, may result in a smoother postoperative recovery and reduced risk of complications without significantly worsening the visual prognosis. See also BCSC Section 11, *Lens and Cataract*.

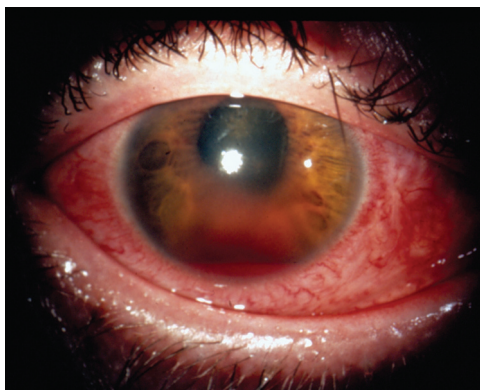Full-thickness eyelid lacerations, especially those involving a canaliculus, should be repaired meticulously; sedation or general anesthesia may be required, even in older children. Working near the eyes with sharp instruments and draping the face to create a sterile field are likely to frighten an awake child and add to the difficulty of the repair. Clearly superficial wounds can be repaired in the emergency department. For superficial wounds, use of an absorbable suture is acceptable if the physician wishes to avoid the need to remove nonabsorbable sutures.

## Blunt Injury

### *Hyphema*

As with all forms of pediatric trauma, the precise occurrence that led to the hyphema may be difficult to determine. The possibility of abuse must be considered, as must the possibility of a nontraumatic etiology: retinoblastoma, juvenile xanthogranuloma of the iris, and bleeding diathesis resulting from leukemia or other blood dyscrasia are relatively rare but important causes of spontaneous hyphema during the early years of life. When the findings are suspicious and the iris and fundus cannot be adequately seen, ultrasonography or magnetic resonance imaging should be performed to rule out intraocular tumor. If a bleeding disorder is suspected, a complete blood count and coagulation studies should be performed.

Intraocular pressure (IOP), an important factor in therapeutic decision making for patients with traumatic hyphema, is often difficult to monitor in the pediatric patient. The risks of inaccurate measurements and of further traumatizing the injured eye may outweigh the potential value of obtaining measurements in uncooperative children. With small hyphemas (Fig 27-2), concern about pressure is greatest in patients with sickle cell trait or disease. Sickling may develop in the anterior chamber, elevating IOP and retarding resorption of blood, or in the retinal circulation, causing vascular occlusion. All African American children with traumatic hyphema require sickle cell screening to evaluate for these conditions.



**Figure 27-2** Small hyphema. Note the layering of blood inferiorly. (Courtesy of Edward L. Raab, MD.)

As in adults, medical management of hyphema in children remains controversial. Care must be taken to minimize the risk of rebleeding, which usually occurs between 3 and 7 days postinjury as a result of clot lysis and retraction. Outpatient management with activity restriction and close follow-up is generally accepted. However, if parental cooperation is questionable or if the patient has sickle trait, hospitalization for several days after injury, when the risk of rebleeding is greatest, remains justifiable. Many ophthalmologists routinely use cycloplegic and corticosteroid drops to facilitate fundus examination, improve comfort, and reduce the risk of inflammatory complications and rebleeding. The value of these topical agents is unproven, and some clinicians prefer to use them selectively for control of pain or obvious inflammation, or to avoid them altogether to minimize manipulation of the eye. Pressure-lowering medication is appropriate for eyes known or strongly suspected to have elevated IOP. Aspirin-containing compounds and nonsteroidal anti-inflammatory drugs can increase the risk of rebleeding and should be avoided.

Many treatments have been proposed to prevent rebleeding in traumatic hyphema, although none is universally accepted. See Chapter 14 in BCSC Section 8, *External Disease and Cornea*, for a discussion of treatment considerations for traumatic hyphema.

The difficulty of detecting early corneal blood staining in a child and the risk that staining may cause severe deprivation amblyopia, coupled with the problems of accurately measuring IOP, justify early surgical intervention whenever a total hyphema persists for 4–5 days. In children with sickle cell trait or disease, it may be necessary to perform surgery even earlier if elevated pressures (>25 mm Hg for over 24 hours) occur.

Late glaucoma is a potential complication of traumatic hyphema in children, as in adults, and may occur with no symptoms. Gonioscopy can be performed after the eye has healed and the child is able to cooperate. Annual follow-up should be continued in children with a history of traumatic hyphema, in light of the potential late complications of cataract, retinal detachment, and glaucoma.

## **Orbital Fractures**

### ***Orbital floor fractures***

Blunt facial trauma is the usual cause of orbital floor fractures. The term *blowout fracture* is used when the rim remains intact. Orbital floor fracture is thought to be due to either of the following: an acute increase in intraorbital pressure, which occurs when a direct impact occludes the orbital entrance; or compression of the rim, which results in buckling of the floor. Orbital floor fracture can be part of more extensive fractures of the orbit and midface. In some cases, the mechanism causing floor fractures extends to include the medial wall as well.

Periorbital ecchymosis and diplopia are common in the immediate posttrauma period. Injury to the inferior rectus muscle or to its nerve, with resultant weakness, may be caused by hemorrhage or ischemia, in addition to restriction. This injury can occur either at the time of the fracture or during its repair. Injury to the inferior rectus muscle can manifest as either limited elevation or depression. Hypoesthesia in the cutaneous distribution of the infraorbital nerve can also occur.

In a patient with limited elevation, a positive forced duction test indicates the presence of restriction. Bradycardia, heart block, nausea, or syncope can occur as a vagal response



to entrapment. When the entrapment involves the more anterior portion of the orbital floor or when there is associated injury to the inferior rectus muscle or its nerve, there can also be limited depression. Reduced saccadic velocity and force generation on attempted downgaze suggest weak muscle action. Orbital computed tomography and high-resolution, multipositional magnetic resonance imaging are useful for revealing the presence and extent of the injury.

A special presentation, the *white-eyed blowout fracture*, is characterized by marked restriction (in both directions) of vertical ocular motility despite minimal signs of soft-tissue injury. This restriction is due to entrapment of the inferior rectus muscle or orbital tissue either beneath a trapdoor fracture or, unique to children, in a linear opening caused by flexion deformity of the floor. In this condition, early surgery, rather than observation, is required in order to minimize permanent muscle and nerve damage.

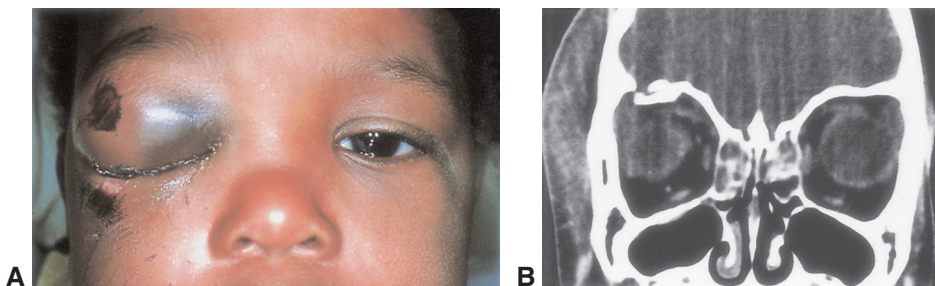
Wei LA, Durairaj VD. Pediatric orbital floor fractures. *J AAPOS*. 2011;15(2):173–180.

**Management** There are several approaches to the management of orbital floor fractures. Some clinicians advocate surgical exploration in all cases, irrespective of the results of forced duction testing. The justification for this approach is that, especially with large bony defects, progressive herniation of orbital contents into the adjacent maxillary sinus can occur, resulting in disfiguring enophthalmos. Others recommend waiting for a few days to 2 weeks to allow periorbital ecchymosis to subside. For these surgeons, the main indication to operate is evidence of restriction with unresolved diplopia in primary position. Diplopia immediately after the injury is common and is not necessarily an indication for urgent intervention. Management of persistent diplopia is covered in Chapter 11.

### **Orbital roof fractures**

Though rare in older patients, orbital roof fractures are common in children younger than 10 years. Isolated roof fractures typically result from impact to the brow region in a fall, often from a height of only a few feet. The principal external manifestation is upper eyelid hematoma (Fig 27-3). These fractures often heal without treatment.

For further discussion of diagnosis and management of orbital trauma, see BCSC Section 7, *Oculofacial Plastic and Orbital Surgery*.



**Figure 27-3** Orbital roof fracture in a child, resulting from direct impact to the brow region in a fall. **A**, Marked right upper eyelid swelling from a hematoma originating in the superior orbit, adjacent to a linear fracture. **B**, Coronal computed tomography shows a bone fragment displaced into the right orbit.

## Traumatic Optic Neuropathy

The optic nerve may be damaged by trauma to the head, orbit, or globe. Vision loss is usually immediate and severe with a relative afferent pupillary defect present. Initially, the optic nerve appears normal, but it becomes atrophic within 1–2 months of injury. Management is controversial and may include high-dose intravenous steroids and optic canal decompression.

For further discussion of diagnosis and management of traumatic optic neuropathy, see BCSC Section 5, *Neuro-Ophthalmology*.

## Nonaccidental Trauma

---

Although most eye injuries in childhood are accidental or innocently caused by other children, a significant number of them result from physical abuse by adults. The terms used for intentional physical abuse of a child include *nonaccidental trauma* and *child abuse*. Child abuse includes emotional abuse, sexual abuse, and neglect as well as physical abuse. It is a pervasive problem, with an estimated 750,000 cases per year in the United States.

A reliable history is often difficult to obtain when nonaccidental trauma has occurred. Suspicion of nonaccidental trauma should be aroused when repeated accounts of the circumstances of injury or histories obtained from different individuals are inconsistent or when the events described do not correlate with the injuries (eg, bruises on multiple aspects of the head after “a fall”) or with the child’s developmental level (eg, a 1-month-old “rolling off a bed” or a 4-month-old “climbing out of a high chair”).

Any physician who suspects child abuse is required by law in every US state and Canadian province to report the incident to a designated governmental agency. Once this obligation has been discharged, full investigation of the situation by appropriate specialists and authorities is usually performed. Physicians should be familiar with the regulations in their own country. If possible, ocular abnormalities should be documented photographically or with a detailed drawing to use as evidence in court.

## Abusive Head Trauma

A unique complex of ocular, intracranial, and sometimes other injuries occurs in infants who have been abused by violent shaking. This is recognized as one of the most important manifestations of child abuse. Although the term *shaken baby syndrome* is still occasionally used, it has largely been replaced with the terms *abusive head trauma (AHT)* and *inflicted childhood neurotrauma* because these infants may sustain impact injury as well as shaking injury involving the head.

Patients with AHT are usually younger than 5 years and most often younger than 12 months. When a reliable history is available, it typically involves a parent or other caregiver who shook an inconsolable crying baby in anger or frustration. Often, however, the only information provided is that the child’s mental status deteriorated or that a seizure or respiratory difficulty developed. The involved caregiver may relate that an episode of relatively minor trauma occurred, such as a fall from a bed. Even without a supporting history, the diagnosis of AHT can still be made with confidence on the basis of characteristic clinical findings. It must be kept in mind, however, that answers to important questions

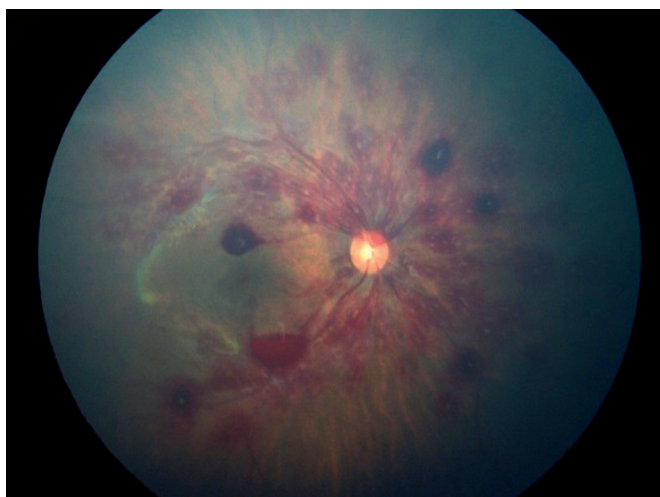concerning the timing and circumstances of injury and the identity of the perpetrator frequently cannot be inferred from medical evidence alone.

Intracranial injury in AHT frequently includes subdural hematoma (typically bilateral over the cerebral convexities or in the interhemispheric fissure) and subarachnoid hemorrhage. Displacement of the brain in relation to the skull and dura mater ruptures bridging vessels, and compression against the cranial bones produces further damage. Neuroimaging may also show intracranial edema, ischemia, or contusion in the acute stage and atrophy in later stages. These findings are thought to result from repetitive, abrupt acceleration-deceleration of the child's head as it whiplashes back and forth during the shaking episode. Some authorities, citing the frequency with which patients with AHT also show evidence of having received blows to the head, think that impact is an essential component, although in many cases no sign of impact is found.

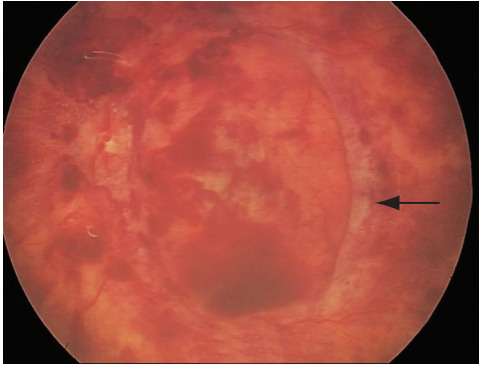
### **Ocular involvement**

The most common ocular manifestation of AHT, present in approximately 80% of cases, is retinal hemorrhage. These hemorrhages can be seen in all layers of the retina and may be unilateral or bilateral. They are found most commonly in the posterior pole but often extend to the periphery (Fig 27-4). Vitreous hemorrhage may also develop, usually as a secondary phenomenon resulting from migration of blood from a preretinal hemorrhage into the vitreous. Occasionally, the vitreous becomes almost completely opacified by dispersed hemorrhage within a few days of injury. Retinal hemorrhages in shaken infants cannot be dated with precision and usually resolve over a period of weeks to months. Vitrectomy should be considered if there is a risk of amblyopia due to persistent vitreous hemorrhage.

Some eyes show evidence of retinal tissue disruption in addition to hemorrhage. Full-thickness perimacular folds in the neurosensory retina, typically with circumferential orientation around the macula that creates a craterlike appearance, are highly characteristic.



**Figure 27-4** Extensive retinal hemorrhages in a 4-month-old infant suspected to have been violently shaken. (Courtesy of Sophia Ying Fang, MD.)



**Figure 27-5** Traumatic retinoschisis with perimacular folds (arrow). (Courtesy of Ken K. Nischal, MD.)

Splitting of the retina (traumatic retinoschisis), either deep to the nerve fiber layer or superficial (involving only the internal limiting membrane), may create cavities of considerable extent that are partially filled with blood, also usually in the macular region (Fig 27-5). Full-thickness retinal breaks and detachment are rare. Retinal folds usually flatten out within a few weeks of injury, but schisis cavities can persist indefinitely.

A striking feature of AHT is the typical lack of external evidence of trauma. The ocular adnexa and anterior segment may appear entirely normal. Occasionally, the trunk or extremities show bruises representing the imprint of the perpetrator's hands. In a minority of cases, broken ribs or characteristic metaphyseal fractures of the long bones result from forces generated during shaking. It must be kept in mind, however, that these patients may have been subjected to other forms of abuse.

When extensive retinal hemorrhage accompanied by perimacular folds and schisis cavities is found in association with intracranial hemorrhage or other evidence of trauma to the brain in an infant, AHT can usually be diagnosed with confidence regardless of other circumstances. Severe accidental head trauma (eg, sustained in a fall from a second-story level or in a motor vehicle collision) is not frequently accompanied by retinal hemorrhage, and hemorrhage is not extensive when present. Retinal hemorrhage is rare and has never been documented to be extensive following cardiopulmonary resuscitation by trained personnel. Severe, fatal, acute head-crush injury rarely causes hemorrhagic retinopathy with perimacular folds, which can be differentiated from AHT by the associated injuries.

Extensive retinal hemorrhage without other ocular findings strongly suggests that intracranial injury has been caused by AHT, but alternative possibilities such as a coagulation disorder must be considered as well. Retinal hemorrhages resulting from birth trauma are common in newborns, but they seldom persist beyond the age of 1 month. Other possible causes of retinal hemorrhage in children include anemia, hypertension, acutely increased intracranial pressure, leukemia, meningitis, glutaricaciduria, and retinopathy of prematurity.

American Academy of Ophthalmology, Hoskins Center. Clinical Statement. *Abusive Head Trauma/Shaken Baby Syndrome—2015*. San Francisco: American Academy of Ophthalmology; 2015. Available at <https://www.aao.org/clinical-statement/abusive-head-traumashaken-baby-syndrome>.

Christian CW, Block R; Committee on Child Abuse and Neglect; American Academy of Pediatrics. Abusive head trauma in infants and children. *Pediatrics*. 2009;123(5):1409–1411.

Maguire SA, Watts PO, Shaw AD, et al. Retinal haemorrhages and related findings in abusive and nonabusive head trauma: a systematic review. *Eye (Lond)*. 2013;27(1):28–36.

### **Prognosis**

In one large study, 29% of children with AHT died of their injuries. Poor visual and pupillary responses were correlated with a higher risk of mortality. Survivors often had permanent impairment ranging from mild learning disability and motor disturbances to severe cognitive impairment and quadriplegia. The most common cause of vision loss is cortical injury followed by optic atrophy. Dense vitreous hemorrhage, usually associated with deep traumatic retinoschisis, carries a poor prognosis for both vision and life.

Kivlin JD, Simons KB, Lazowitz S, Ruttum MS. Shaken baby syndrome. *Ophthalmology*. 2000;107(7):1246–1254.

### **Ocular Injury Secondary to Nonaccidental Trauma**

The presenting sign of child abuse involves the eye in approximately 5% of cases. Blunt trauma inflicted with fingers, fists, or implements such as belts or straps is the usual mechanism of nonaccidental injury to the ocular adnexa or anterior segment. Periorbital ecchymosis, subconjunctival hemorrhage, and hyphema should raise suspicion of recent abuse if the explanation provided is implausible (see the section “Hyphema” earlier in this chapter). Cataract and lens dislocation may be a sign of repeated injury or trauma inflicted earlier. Child abuse should also be suspected with rhegmatogenous retinal detachment in a child without a history of injury or an apparent predisposing factor, such as high myopia.

# Ocular Manifestations of Systemic Disease

This chapter focuses on select systemic disorders with multiple types of ocular involvement. Systemic disorders with 1 primary ocular abnormality are discussed in other chapters in this volume. Often, the ophthalmologist can help to make the correct systemic diagnosis.

## Diseases due to Chromosomal Abnormalities

---

Abnormalities in chromosomal number (aneuploidy: trisomy or monosomy), structure (duplications, deletions, translocations, inversions, or rings), or type (autosomal or sex chromosome) occur in approximately 1 in 150 live births. Table 28-1 lists select chromosomal abnormalities commonly associated with ocular findings. Also see BCSC Section 2, *Fundamentals and Principles of Ophthalmology*, Chapter 6.

## Inborn Errors of Metabolism

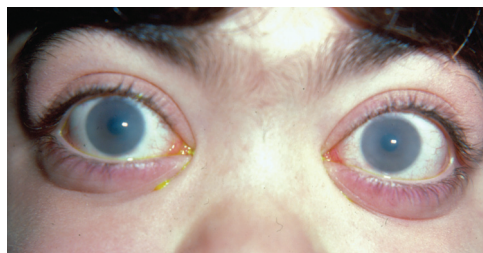---

Inborn errors of metabolism are estimated to occur in 1 in 1400 births and are typically caused by biallelic mutations. Ocular findings can result from direct toxicity of abnormal metabolic products, accumulation of abnormal (or normal) metabolites, errors of synthetic pathways, or deficient production of energy. The age at onset of ocular manifestations of inborn errors of metabolism varies. Table 28-2 summarizes the common ophthalmic manifestations of select conditions. Also see Chapter 21. Following are examples of ocular structural abnormalities secondary to metabolic disorders:

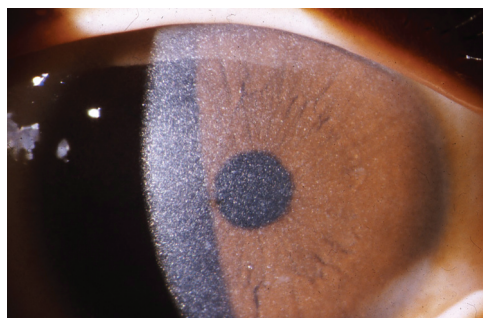
- Corneal clouding or deposits: certain mucopolysaccharidoses (Fig 28-1), cystinosis (Fig 28-2), Schnyder corneal dystrophy (Fig 28-3)
- Corneal pseudodendritic ulcerations: tyrosinemia
- Cataracts: diabetes mellitus, galactosemia, Smith-Lemli-Opitz syndrome, cerebrotendinous xanthomatosis (Fig 28-4)
- Lens luxation or subluxation: homocystinuria (Fig 28-5)
- Retinal degeneration: peroxisomal disorders (Zellweger syndrome, Refsum disease), lysosomal disorders (eg, neuronal ceroid lipofuscinosis), mitochondrial disorders (eg, Kearns-Sayre syndrome [Fig 28-6])

**Table 28-1 Common Chromosomal Abnormalities With Ocular Associations**

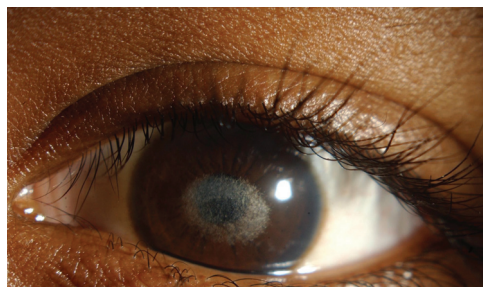<b>Chromosomal Abnormality</b>	<b>Associated Ocular Findings</b>
<b>Trisomy 13, Patau syndrome</b>	<i>More common:</i> microphthalmia, coloboma, retinal dysplasia with frequent islands of intraocular cartilage <i>Less common:</i> cataract, corneal opacification, cyclopia, persistent fetal vasculature, shallow supraorbital ridges, upward-slanting palpebral fissures, absent eyebrows, hypotelorism, hypertelorism, anophthalmia, glaucoma
<b>Trisomy 18, Edwards syndrome</b>	<i>More common:</i> short palpebral fissures, hypertelorism, epicanthus, hypoplastic supraorbital ridge <i>Less common:</i> cataract, microcornea, corneal opacification, congenital glaucoma, retinal depigmentation, colobomatous microphthalmia, cyclopia
<b>Trisomy 21, Down syndrome (most common trisomy)</b>	<i>More common:</i> epicanthus with upward-slanting palpebral fissures, blepharitis, Brushfield spots, congenital or acquired cataract, myopia, congenital nasolacrimal duct obstruction and difficulty with probings, ectropion, strabismus, hypoaccommodation, nystagmus, increased number of vessels at optic disc margin <i>Less common:</i> infantile glaucoma, keratoconus
<b>Deletion 4p, Wolf-Hirschhorn syndrome</b>	<i>More common:</i> colobomatous microphthalmia, epicanthus, downward-slanting palpebral fissures, hypertelorism, strabismus, ptosis, corneal opacification (Peters anomaly) <i>Less common:</i> anterior segment anomalies, cataract
<b>Deletion 5p, cri-du-chat syndrome</b>	<i>More common:</i> upward- or downward-slanting palpebral fissures, hypotelorism or hypertelorism, epicanthus, strabismus <i>Less common:</i> ptosis, decreased tear production, myopia, cataract, glaucoma, tortuous retinal vessels, foveal hypoplasia, optic atrophy, colobomatous microphthalmia
<b>Deletion 18p</b>	<i>More common:</i> hypertelorism, ptosis, epicanthus, and strabismus <i>Less common:</i> cataracts, retinal dysplasia, colobomatous microphthalmia, synophthalmia/cyclopia
<b>Deletion 18q</b>	<i>More common:</i> epicanthus, hypertelorism, downward-slanting palpebral fissures, strabismus, dysplastic or atrophic optic nerve, nystagmus <i>Less common:</i> corneal abnormalities, cataracts, blue sclera, myopia, colobomatous microphthalmia
<b>Monosomy X, Turner syndrome</b>	<i>More common:</i> strabismus, ptosis <i>Less common:</i> cataracts, refractive errors, corneal scars, blue sclera Incidence of color blindness similar to that in unaffected males



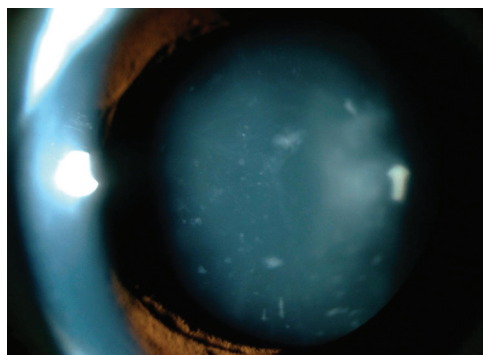
**Figure 28-1** Bilateral corneal clouding in mucopolysaccharidosis VI. (Courtesy of Edward L. Raab, MD.)



**Figure 28-2** Cystinosis with corneal involvement. (Courtesy of Gregg T. Lueder, MD.)



**Figure 28-3** Corneal crystals in a girl with Schnyder corneal dystrophy. (Courtesy of Arif O. Khan, MD.)



**Figure 28-4** Fleck opacities and posterior capsular cataract secondary to cerebrotendinous xanthomatosis in the right eye of a boy. The patient had a history of intractable infantile diarrhea. (Modified with permission from Khan AO, Aldahmesh MA, Mohamed JY, Alkuraya FS. Juvenile cataract morphology in 3 siblings not yet diagnosed with cerebrotendinous xanthomatosis. *Ophthalmology*. 2013;120(5):956–960.)



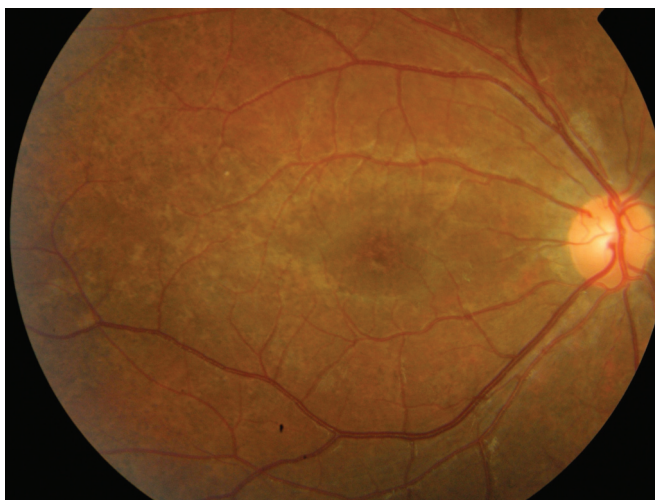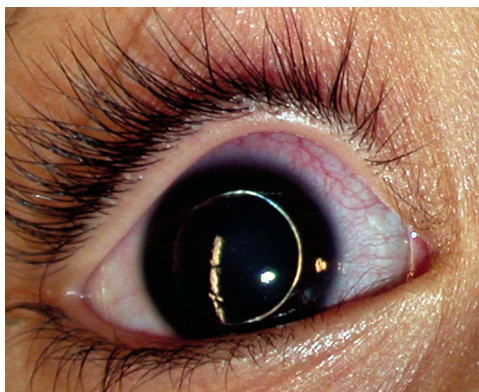
**Table 28-2 Ocular Findings in Mucopolysaccharidoses, Lipidoses, Gangliosidoses, and Miscellaneous Disorders**

Disease (code)*	Enzyme Deficiency	Corneal Clouding	Motility Disorders	Cherry-Red Spot	Retinal Dystrophy	Optic Atrophy	Other	Inheritance
<b>Mucopolysaccharidosis (MPS) syndromes</b>								
MPS IH (Hurler) (607014)	$\alpha$ -L-Iduronidase	+++	-	-	+++	+	Glaucoma; plus papilledema (IH only)	AR
MPS IS (Scheie) (607016)								
MPS II (Hunter) (308900)	Iduronate-2-sulfatase	-	-	-	++	+	-	XR
MPS III (Sanfilippo)	A: Heparan <i>N</i> -sulfatase B: $\alpha$ - <i>N</i> -Acetyl-glucosaminidase C: Acetyl-CoA: $\alpha$ -glucosaminidase <i>N</i> -acetyltransferase	-	-	-	++	Rare	Late blindness	AR
MPS IV (Morquio)	D: <i>N</i> -Acetylglucosamine-6-sulfatase A: <i>N</i> -Acetyl-galactosamine-6-sulfatase A (253200)	++	-	-	Rare	Rare	-	A:AR
MPS V (Maroteaux-Lamy) (253200)	B: $\beta$ -Galactosidase	++	-	-	-	+	Papilledema, glaucoma	B:AR AR
MPS VI (Siv) (253220)	Arylsulfatase B $\beta$ -Glucuronidase	+	-	-	-	-	-	AR
<b>Mucopolipidoses</b>								
Type I (256550)	Neuraminidase	-	+	+	+	-	Hearing loss	AR
Sialidosis (glycoproteinosis)								
*Cherry-red spot myoclonus syndrome"								
Type II (252500)	Multiple lysosomal enzymes (I-cell disease)	++	-	-	-	-	Hurler-like	AR
Type III (252600)	Multiple lysosomal enzymes (pseudo-Hurler polydystrophy)	+++	-	-	-	-	Hurler-like puffy eyelids	AR
Type IV (252650)	Mucopolipin-1 defect	+++	-	-	++	+	Photophobia	AR
<b>Lipidoses</b>								
Niemann-Pick disease (257220)	Sphingomyelinase	+	Nystagmus	+	-	+	Eventual vision loss	AR
Fabry disease (301500)	$\alpha$ -Galactosidase A	Whorl-like	-	-	-	-	Angiokeratoma, spokelike cataract, aneurysmal conjunctival vessels	XR
Gaucher disease								
Type I (230800)	Acid $\beta$ -glucosidase	-	Paralytic strabismus, looped saccades	-	+	-	Pinguecula, conjunctival pigmentation	AR
Type II (230900)								
Type III (231005)								
Metachromatic leukodystrophy (250100)	Arylsulfatase A	-	Nystagmus	+	-	+	Blindness, decreased pupil reaction	AR
Krabbe disease (245200)	Galactosylceramidase	-	Nystagmus	Rare	-	+	Cortical blindness	AR
Fucosidosis (230000)	$\alpha$ -L-Fucosidase	-	-	-	+	-	Hurler-like features, angiokeratoma, tortuous conjunctival vessels	AR

Disease (code)*	Enzyme Deficiency	Conjunctival Tortuosity	Corneal Clouding	Motility Disorders	Cherry-Red Spot	Retinal Dystrophy	Optic Atrophy	High Myopia	Blindness	Inheritance
<b>Gangliosidoses</b>										
Generalized (GM <sub>1</sub> ) gangliosidoses Type I (230500)	β-Galactosidase-1	+	±	ET, nystagmus	50% of patients	-	+	+	+	AR
Type II (230600) (juvenile GM <sub>1</sub> , Derry disease)	β-Galactosidase-1	-	-	ET, nystagmus	-	+	±	-	Late	AR
Type III (230650) (adult GM <sub>1</sub> ) GM <sub>2</sub> gangliosidoses	β-Galactosidase-1	±	Rare	-	-	-	-	-	-	AR
Tay-Sachs disease (272800) Type I (classic infantile)	Hexosaminidase A	-	-	Nystagmus, ophthalmoplegia	+	-	+	-	+	AR
B1 variant (late infantile) Type III (juvenile subacute) Chronic adult	HEXA defect Hexosaminidase A or B HEXA defect	-	+	Strabismus Ocular motor defects	+	+	+	+	+	AR AR AR
Type II (268800) (Sandhoff disease) Type AB, Hexosaminidase activator deficiency	Hexosaminidase A and B Activator deficiency	-	Rare	ET Strabismus	+	-	±	-	+	AR AR
<b>Miscellaneous disorders</b>										
Galactosialidosis (256540) Neuronal ceroid lipofuscinosis	β-Galactosidase, neuraminidase	-	+	-	+	-	+	Dwarfism, seizures, coarse facies	-	AR
CLN1 Infantile Hagberg-Santavuori disease (256730)	Palmitoyl-protein thioesterase 1 (PPT-1)	-	-	+	Macular	+	+	Blindness	-	AR
CLN2 Late infantile Hagberg- Santavuori (204500)	PPT-1	-	-	+	Bull's eye	+	+	Blindness	-	AR
CLN3 Juvenile Batten, Spielmeyer- Vogt disease (204200)	Unknown	-	-	+	Bull's eye	+	+	Blindness	-	AR
CLN4 Adult Kufs disease (204300)	Unknown	-	-	-	-	-	-	-	-	AR
Cystinosis (219800)	Unknown	-	Crystals	-	-	++	-	Conjunctival crystals, renal problems	-	AR
Galactosemia (230400)	Gal-1-PO <sub>4</sub> uridyl transferase	-	-	-	-	-	-	Cataracts if not treated	-	AR
Mannosidosis (248500)	α-Mannosidase	++	++	-	-	+	-	Hurler-like, spokelike cataract margin	-	AR
Homocystinuria (236200)	Cystathionine β-synthase	-	-	-	-	+	-	Dislocated lens, cataract	-	AR
Refsum disease (266500)	Phytanic acid α-hydroxylase	-	-	-	-	++	-	Cataract, night blindness	-	AR

\* Code numbers refer to the system developed by Victor McKusick and colleagues (McKusick VA, Francmano CA, Antonarakis SE. *Mendelian Inheritance in Man: Catalogs of Autosomal Dominant, Autosomal Recessive, and X-Linked Phenotypes*. 10th ed. Baltimore: The Johns Hopkins University Press; 1992). Table updates from Online Mendelian Inheritance in Man ([www.ncbi.nlm.nih.gov/omim](http://www.ncbi.nlm.nih.gov/omim)). Plus (+) and minus (-) signs indicate the relative likelihood of occurrence of ocular findings in these systemic disorders. AR = autosomal recessive; ET = constant esotropia; XR = X-linked recessive.

**Figure 28-5** Lens luxation into the anterior chamber and acute glaucoma as the presenting sign of homocystinuria in a boy. (Courtesy of Arif O. Khan, MD.)



**Figure 28-6** Juvenile retinal dystrophy in a boy with recent slow development of ptosis and ophthalmoplegia, which led to the diagnosis of Kearns-Sayre syndrome. (Courtesy of Arif O. Khan, MD.)

- Central macular cherry-red spot: GM<sub>2</sub> gangliosidosis type I (Tay-Sachs disease) and type II (Sandhoff disease), Niemann-Pick disease. The cherry-red spot disappears over time as the intumescent ganglion cells die and optic atrophy develops. Therefore, the absence of a cherry-red spot should not be used to rule out a diagnosis, especially in older children.

In some disorders, early metabolic control greatly decreases the risk of ocular and systemic sequelae. Therefore, early recognition of metabolic disorders and timely referral to a geneticist are essential. The ophthalmologist can play a key role in the early identification of certain treatable metabolic disorders, examples of which are galactosemia, classic homocystinuria (Chapter 23), cystinosis (Chapter 21), certain mucopolysaccharidoses, and cerebrotendinous xanthomatosis (Chapter 23).

Poll-The BT, Maillette de Buy Wenniger-Prick CJ. The eye in metabolic diseases: clues to diagnosis. *Eur J Paediatr Neurol.* 2011;15(3):197–204.

## Familial Oculorenal Syndromes

### Lowe Syndrome

Lowe (oculocerebrorenal) syndrome is due to hemizygous *OCRL* mutation and is characterized by both bilateral congenital cataract and glaucoma. Pupils are typically miotic. The lenses are small and thick and may exhibit posterior lenticonus. In carrier mothers, they show radially oriented punctate snowflake opacities. Systemic findings include congenital hypotonia, cognitive impairment, and infantile renal tubulopathy (Fanconi type) with resultant aminoaciduria, metabolic acidosis, proteinuria, and rickets.

### Alport Syndrome

Alport syndrome shows different inheritance patterns, but X-linked inheritance is the most common. Ocular findings include anterior lenticonus or anterior subcapsular cataract, posterior polymorphous corneal dystrophy, and fleck retinopathy. Alport syndrome is a basement membrane disease that can include progressive renal failure and deafness.

### Ciliopathies

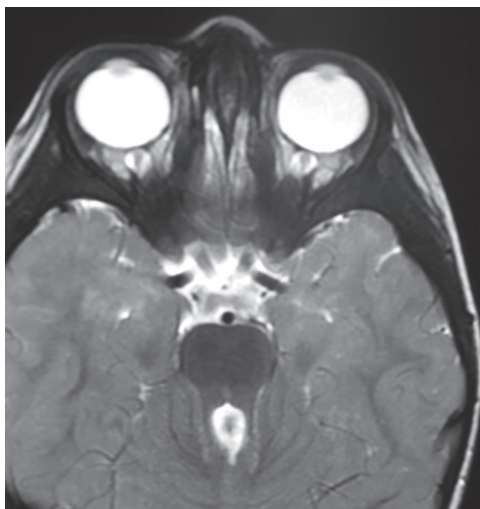
Ciliopathies are disorders of organ-specific or systemic cilia dysfunction. Nonmotile cilia have a variety of specialized functions, such as cell signaling, detection of chemical gradients, and intracellular transport. Retinal involvement is frequent in ciliopathies because the junction between inner and outer segments of the photoreceptor cell is a modified nonmotile cilium. When a child has a retinopathy secondary to a systemic ciliopathy, the most common later organ dysfunction is renal. The possibility of systemic ciliopathy should be considered in all children with early-onset retinal dystrophy.

Systemic ciliopathies include Senior-Løken syndrome (retinopathy, later renal dysfunction), Bardet-Biedl syndrome (retinopathy, polydactyly [Fig 28-7], obesity, later renal dysfunction), Alström syndrome (retinopathy, cardiomyopathy, obesity, later renal



**Figure 28-7** This infant with nystagmus related to retinal dystrophy also had polydactyly (arrow), which led to the diagnosis of Bardet-Biedl syndrome. Systemic features such as renal impairment emerge in later childhood. (Courtesy of Arif O. Khan, MD.)

**Figure 28-8** Magnetic resonance (MR) image showing the classic “molar tooth” sign in a 2-year-old girl, confirming the diagnosis of Joubert syndrome. The patient presented with developmental delay, retinal dystrophy, and oculomotor apraxia. (Courtesy of Arif O. Khan, MD.)



dysfunction), and Joubert syndrome (retinopathy, oculomotor apraxia, developmental delay, characteristic magnetic resonance imaging [MRI] findings [Fig 28-8], later renal dysfunction).

## Neuro-Oculocutaneous Syndromes

Neuro-oculocutaneous syndromes (phakomatoses) are characterized by systemic hamartomas of the eye, central nervous system (CNS), and skin. Diagnosis is clinical, according to the latest published consensus criteria. Ocular involvement is frequent and can help confirm the specific diagnosis. An overview of these conditions is provided in Table 28-3.

### Neurofibromatosis Type 1

Neurofibromatosis type 1 (NF1) is characterized by multiple melanocytic and neuroglial lesions. See Table 28-3 for a list of common features.

#### **Melanocytic lesions**

*Café-au-lait spots*, the most common cutaneous expression of NF1, are uniformly hyperpigmented macules of varying size (Fig 28-9). Some are usually present at birth; the number and size increase during the first decade of life. Unaffected individuals may have 1–3 café-au-lait spots, but greater numbers are rare except in association with NF1. Melanocytic lesions of the uveal tract are also common.

*Lisch nodules* are small (usually <1 mm), sharply demarcated, dome-shaped excrescences of the iris (Fig 28-10). Lisch nodules most often develop between ages 5 and 10 years and are present in nearly all adults with NF1. Multiple flat choroidal lesions 1–2 times the size of the optic disc are common. These lesions are difficult to visualize by conventional fundus examination, but near-infrared reflectance imaging has a high sensitivity for detection. Melanocytic lesions in NF1 do not affect vision.

**Table 28-3 Overview and Select Key Features of Neuro-Oculocutaneous Syndromes**

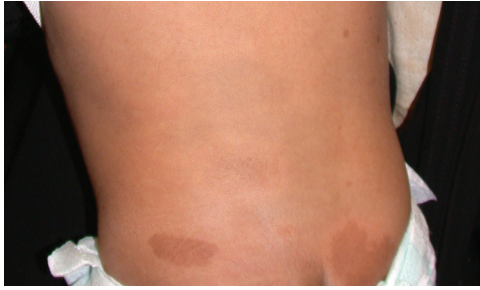Disease	Gene Symbol/ Chromosome Location	Inheritance Pattern	Ocular Features	Cutaneous Features	CNS and Other Systemic Features	Incidence and Comments
Neurofibromatosis type 1 (von Recklinghausen disease)	<i>NF1</i> (17q11.2); tumor suppressor	AD	Eyelid neurofibroma, glaucoma, Lisch nodules, optic pathway glioma	Café-au-lait spots, neurofibromas	Sphenoid dysplasia, other tumors	1/3500 New mutations common; variable expressivity common
Neurofibromatosis type 2	<i>NF2</i> (22q12); tumor suppressor	AD	Cataract, retinal com- bined hamartoma, epiretinal membrane	Café-au-lait spots	Acoustic neuromas, spinal cord tumors	1/33,000 New mutations common
Tuberous sclerosis (Bourneville disease)	<i>TSC1</i> (9q34), <i>TSC2</i> (16p13.3); tumor suppressor	AD	Retinal astrocytic hamartomas	Angiofibromas, hypopigmented macules, subungual fibromas	Seizures, cognitive impairment, renal cell carcinoma, cardiac rhabdomyoma	1/10000 New mutations very common
von Hippel–Lindau disease (retinal angiomatosis)	<i>VHL</i> (3p26- p25); tumor suppressor	AD	Retinal capillary hemangioblastoma	—	Hemangioblastoma, renal cell carcinoma, pheochromocytoma	1/36000 High penetrance; benign and malignant tumors

(Continued)

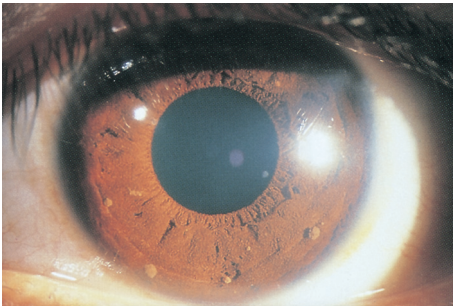
**Table 28-3 (continued)**

<b>Disease</b>	<b>Gene Symbol/ Chromosome Location</b>	<b>Inheritance Pattern</b>	<b>Ocular Features</b>	<b>Cutaneous Features</b>	<b>CNS and Other Systemic Features</b>	<b>Incidence and Comments</b>
Sturge-Weber syndrome (encephalofacial angiomatosis)	GNAQ (9q21)	Somatic mosaicism	Diffuse choroidal cavernous angioma, glaucoma	Nevus flammeus	Meningeal angiomas, seizures	1/50000 Nevus flammeus alone not pathognomonic
Ataxia-telangiectasia (Louis-Bar syndrome)	ATM (11q22.3)	AR	Saccadic initiation failure, conjunctival telangiectasias	Telangiectasias	Cerebellar dysfunction, immunodeficiency, malignancy	1/40000 ATM is regulator of tumor-suppressor genes and DNA repair
Incontinentia pigmenti (Bloch-Sulzberger syndrome)	IKBKG (Xq28)	X-linked dominant	Retinal vasculopathy	Vesicles with evolution to hyperpigmented lesions	Seizures, cognitive impairment	Evolution of skin lesions can occur in utero
Wyburn-Mason syndrome	Nonhereditary	Sporadic	Retinal racemose angioma	If present, lesions are on face	Intracranial AVMs with bleeding as sequelae	Isolated finding more common than syndrome
Klippel-Trénaunay-Weber syndrome	Nonhereditary	Sporadic	Glaucoma	Nevus flammeus similar to that in Sturge-Weber syndrome	—	Extremity with vascular nevus, varicosities, hypertrophy of bone and soft tissue, AVM

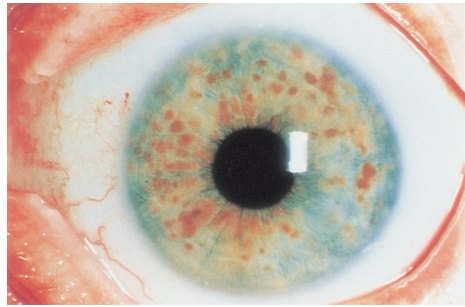
AD = autosomal dominant; AR = autosomal recessive; AVM = arteriovenous malformation; CNS = central nervous system.



**Figure 28-9** Multiple café-au-lait spots in an infant with unilateral glaucoma; neurofibromatosis type 1 (NF1) was ultimately diagnosed. (Courtesy of Arif O. Khan, MD.)



**A**



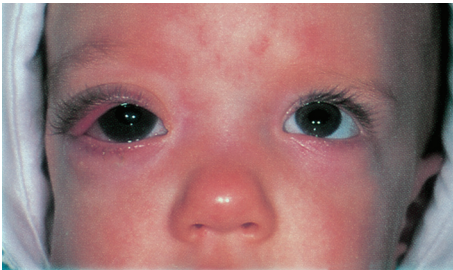**B**

**Figure 28-10** Lisch nodules of the iris in 2 patients with NF1. The brown iris has lighter-colored Lisch nodules (**A**), whereas the blue iris has darker-colored nodules (**B**).

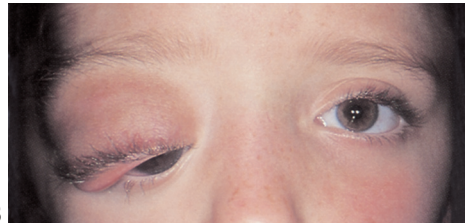### **Neuroglial lesions**

*Nodular cutaneous and subcutaneous neurofibromas, or fibroma molluscum,* are by far the most common lesions of neuroglial origin. They typically develop in late childhood.

*Plexiform neurofibromas* are seen in approximately 30% of cases. These are extensive, soft subcutaneous swellings with indistinct margins, often with hyperpigmentation or hypertrichosis of the overlying skin. Hypertrophy of underlying soft tissue and bone (regional gigantism) is often present. Plexiform neurofibromas develop earlier than nodular lesions, are frequently evident in infancy or childhood, and may cause severe disfigurement and functional impairment. Approximately 10% involve the face, commonly the upper eyelid and orbit (Fig 28-11). Greater involvement of the upper eyelid's temporal



**A**



**B**

**Figure 28-11** Plexiform neurofibroma involving the right upper eyelid, associated with ipsilateral buphthalmos, in a girl with NF1. **A**, Age 8 months. **B**, Age 8 years.



portion results in an S-shaped configuration. Tumor bulk may cause complete ptosis. Glaucoma in the ipsilateral eye is found in up to 50% of cases.

Complete excision of an eyelid plexiform neurofibroma is generally not possible. Treatment is directed toward the relief of specific symptoms. Surgical debulking and frontalis suspension procedures can reduce ptosis sufficiently to allow binocular vision. Clinical trials examining use of biologic agents to treat these lesions are under way.

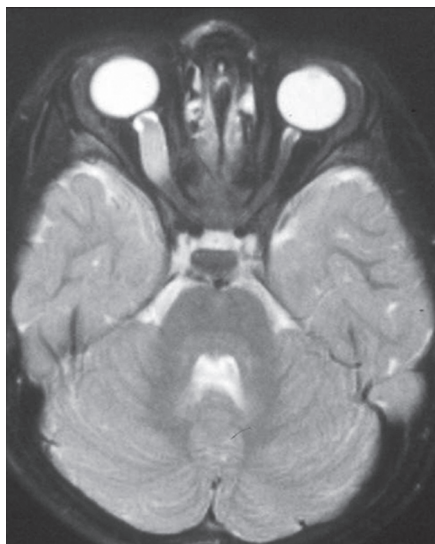
*Optic pathway glioma* is a low-grade pilocytic astrocytoma involving the optic nerve, chiasm, or both. It is present in approximately 15% of affected patients and is symptomatic in 1%–5% (almost always before age 10 years, after a period of brief rapid enlargement). The efficacy of treatment (ie, chemotherapy, radiation) is unclear because of the condition's highly variable natural history, including relative stability after rapid growth and spontaneous improvement in a few cases. MRI usually shows cylindrical or fusiform enlargement (Fig 28-12), often with exaggerated sinuousness or kinking, creating an appearance of discontinuity or localized constriction on axial images. In addition to causing bilateral vision loss, tumors involving primarily the chiasm may result in significant morbidity, including hydrocephalus and hypothalamic dysfunction. Chiasmatic glioma in patients with NF1 carries a better prognosis than in individuals without NF1.

Other less common neuroglial abnormalities include spinal and gastrointestinal neurofibromas, pheochromocytomas, prominence of corneal nerves ( $\leq 20\%$ ), localized orbital neurofibromas, and retinal hamartomas.

Jakacki RI, Dombi E, Potter DM, et al. Phase I trial of pegylated interferon- $\alpha$ -2b in young patients with plexiform neurofibromas. *Neurology*. 2011;76(3):265–272.

### **Other manifestations**

Additional manifestations include various benign tumors that involve the skin or the eye (eg, juvenile xanthogranuloma, retinal capillary hemangioma), several forms of malignancy (leukemia, rhabdomyosarcoma, pheochromocytoma, Wilms tumor), bony defects



**Figure 28-12** Axial MR image of a right optic pathway glioma in a child with NF1. (Courtesy of Ken K. Nischal, MD.)

such as scoliosis, pseudarthrosis of the tibia, and hypoplasia of the sphenoid bone (which may cause ocular pulsation). Sphenoid dysplasia may be associated with neurofibromas in the ipsilateral superficial temporal fossa as well as in the deep orbit. Several ill-defined abnormalities of the CNS (macrocephaly, aqueductal stenosis, seizures, and developmental delay) are also seen with greater frequency in patients with NF1. The diagnosis of NF1 should be considered in any child who presents with unilateral glaucoma.

An appropriate interval for periodic ophthalmic reassessment in childhood is 1–2 years, unless a specific abnormality requires closer observation.

Fisher MJ, Loguidice M, Gutmann DH, et al. Visual outcomes in children with neurofibromatosis type 1–associated optic pathway glioma following chemotherapy: a multicenter retrospective analysis. *Neuro Oncol.* 2012;14(6):790–797.

Kalamarides M, Acosta MT, Babovic-Vuksanovic D, et al. Neurofibromatosis 2011: a report of the Children’s Tumor Foundation annual meeting. *Acta Neuropathol.* 2012;123(3):369–380.

## Neurofibromatosis Type 2

Neurofibromatosis type 2 (NF2) is diagnosed clinically by the presence of bilateral acoustic neuromas (eighth cranial nerve tumors) or by a first-degree relative with NF2 and presence of a unilateral acoustic neuroma, neurofibroma, meningioma, schwannoma, glioma, or early-onset posterior subcapsular cataract. Patients typically present in their teens or early adulthood with signs or symptoms related to the eighth nerve tumor(s), including decreased hearing or tinnitus. The most characteristic ocular finding in NF2 is lens opacity, especially posterior subcapsular cataract or wedge-shaped cortical cataracts. Up to 80% of patients have epiretinal membranes or combined hamartomas of the retina and retinal pigment epithelium (RPE). Lisch nodules of the iris can occur in NF2 but are infrequent. Salient features are summarized in Table 28-3.

## Tuberous Sclerosis

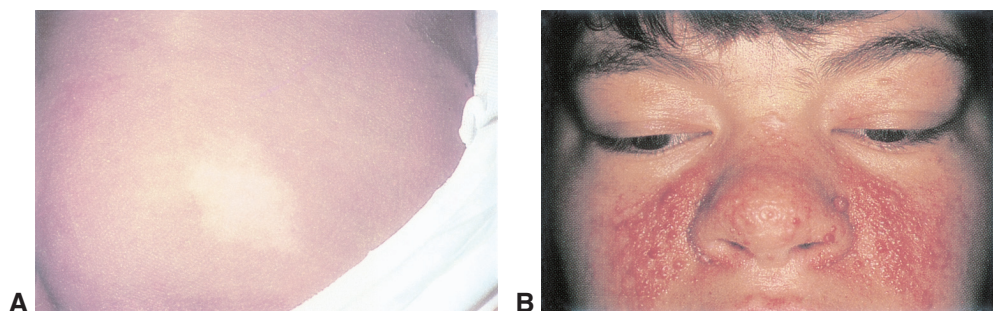
Tuberous sclerosis (TS) is characterized by benign tumor growth in multiple organs, predominantly the skin, brain, heart, kidney, and eye. Prominent extraocular features are summarized in Table 28-4, with examples shown in Figures 28-13 and 28-14. The classic *Vogt triad* of clinical findings is cognitive impairment, seizures, and facial angiofibromas. The facial angiofibromas are not usually present in young children, but hypomelanotic macules (“ash-leaf spots”) are.

The most frequent and characteristic ocular manifestation of TS is retinal phakoma, frequently termed *astrocytic hamartoma* (Fig 28-15). Pathologically, this growth arises from the innermost layer of the retina and is composed of nerve fibers and relatively undifferentiated cells that appear to be of glial origin. Phakomas are usually found near the posterior pole and involve the retina, the optic disc, or both. They vary in size from approximately half to twice the diameter of the disc. Vision is rarely affected.

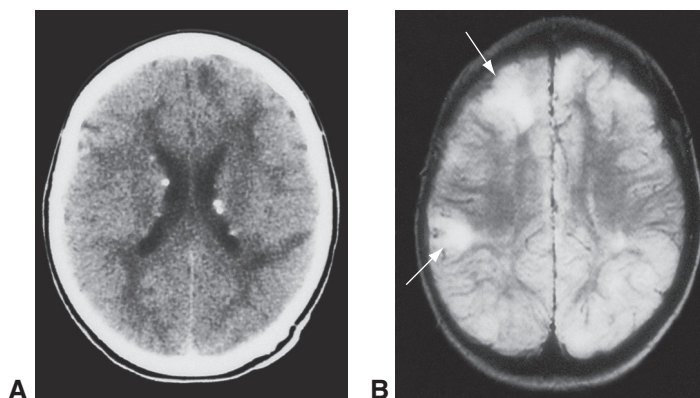
Retinal phakomas have 3 distinct appearances. The first is typically found in very young children; these phakomas are relatively flat with a smooth surface, indistinct margins, and a gray-white color that makes them difficult to detect. The second is a sharply demarcated, elevated, yellow-white, calcified lesion with an irregular surface that has been

**Table 28-4 Extraocular Features in Tuberous Sclerosis**

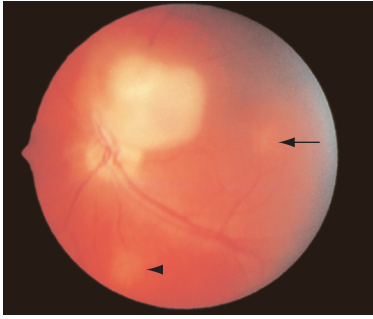
Feature	Characteristic
Ash-leaf spot	Sharply demarcated, hypopigmented skin lesion Visibility increased by ultraviolet light
Adenoma sebaceum	Facial angiofibromas Occurrence in three-quarters of patients Can be mistaken for acne Onset during childhood
Subungual fibroma	Most common but can be periungual
Shagreen patch	Typically located in lumbosacral area Onset after puberty
Seizures	Periventricular or basal ganglia calcification (representing benign astrocytomas) Tuberous malformations of the cortex Cognitive impairment in 50% of patients
Other tumors	Cardiac rhabdomyomas Bone and kidney lesions



**Figure 28-13** Cutaneous lesions of tuberous sclerosis. **A**, Hypomelanotic macule (ash-leaf spot). **B**, Adenoma sebaceum of the face.



**Figure 28-14** Brain lesions of tuberous sclerosis. **A**, Axial computed tomography image showing small periventricular calcifications. **B**, Axial T2-weighted MR image demonstrating tuberous malformations (*arrows*).



**Figure 28-15** Fundus lesions of tuberous sclerosis, left eye. In addition to the large phakoma partially overlying the optic disc, a small hypopigmented lesion (*arrow*) appears in the temporal macula, and a barely visible second phakoma (*arrowhead*) partially obscures a retinal blood vessel near the edge of the photograph, directly below the disc. The lesions of tuberous sclerosis can vary considerably in their opaqueness and visibility.

compared to that of a mulberry. These lesions are more often found in older patients, on or adjacent to the optic disc. The third type is a transitional lesion that combines features of the first 2.

Phakomas are present in 30%–50% of patients with TS. One to several phakomas may be found in a single eye, and 40% of cases are bilateral. There is no evidence that the number of lesions increases with age, but individual tumors have been documented to grow over time. Phakomas are not pathognomonic of TS; they occur occasionally in association with neurofibromatosis and in the eyes of unaffected persons. Retinal lesions are more common in individuals with mutations in the *TSC2* gene. Hypopigmented lesions analogous to ash-leaf spots are occasionally seen in the iris or choroid.

Management of TS patients by the ophthalmologist includes monitoring of vision and ocular lesions. Difficult-to-control seizures respond to vigabatrin: up to 95% of patients experience significant reduction of seizures. However, patients treated with vigabatrin are at risk for ocular complications, which may be difficult or impossible to monitor in patients with TS.

Aronow ME, Nakagawa JA, Gupta A, Traboulsi EI, Singh AD. Tuberous sclerosis complex: genotype/phenotype correlation of retinal findings. *Ophthalmology*. 2012;119(9):1917–1923.

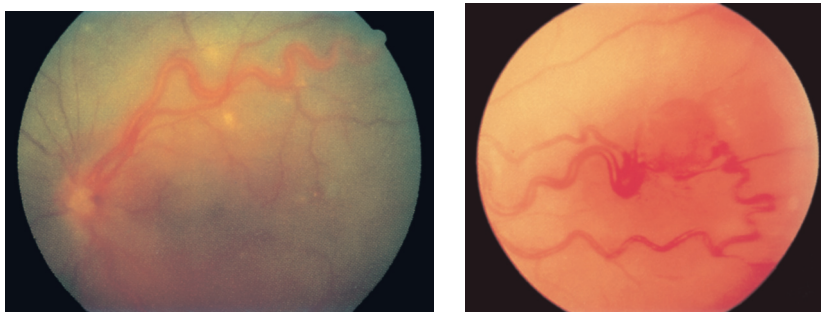
### Von Hippel–Lindau Disease

The retinal lesions seen in von Hippel–Lindau disease (VHL; angiomas of the retina and cerebellum) and originally described by von Hippel are capillary hemangioblastomas. These lesions usually become visible ophthalmoscopically between ages 10 and 35 years, with an average age at onset of 25 years. Retinal capillary hemangioblastomas are found in up to 85% of patients with the *VHL* mutation. Multiple tumors are present in the same eye in about one-third of cases and bilaterally in as many as one-half of cases. Tumors typically occur in the peripheral fundus, but lesions adjacent to the optic disc have been described. Prominent extraocular features of VHL are summarized in Table 28-5.

The hallmark of the mature tumor is a pair of markedly dilated vessels (artery and vein) running between the lesion and the optic disc, indicating significant arteriovenous shunting (Fig 28-16). Characteristic paired or twin retinal vessels of normal caliber may be present before the tumor becomes visible.

**Table 28-5 Extraocular Features in von Hippel–Lindau Disease**

Feature	Characteristic
Brain hemangioblastomas	Usually located in cerebellum Exudation from thin tumor vessel walls causes significant fluid accumulations
Cysts and tumors	Potential for cyst or tumor development in kidneys (renal cell carcinoma), pancreas, liver, epididymis, and adrenal glands (pheochromocytoma)
Rare skin lesions	Café-au-lait spots and port-wine stains (nevus flammeus) seen occasionally
Shagreen patch	Typically located in lumbosacral area Onset after puberty
Seizures	Periventricular or basal ganglia calcification (representing benign astrocytomas) Tuberous malformations of the cortex Cognitive impairment in 50% of patients
Other tumors	Cardiac rhabdomyomas Bone and kidney lesions

**Figure 28-16** Retinal angiomatosis, left eye, in a patient with von Hippel–Lindau disease.

Histologically, retinal capillary hemangioblastomas consist of relatively well-formed capillaries; however, fluorescein angiography shows that these vessels are leaky. Transudation of fluid into the subretinal space causes lipid accumulation, retinal detachment, and consequent vision loss.

Retinal capillary hemangioblastomas can be effectively treated with cryotherapy or laser photocoagulation in two-thirds of cases or more, particularly when the lesions are still small. Antiangiogenic therapy has also shown potential. Early diagnosis increases the likelihood of successful treatment. The ocular lesions of VHL are asymptomatic prior to retinal detachment. Therefore, children at risk for the disease should undergo periodic ophthalmologic evaluation beginning at approximately age 5 years.

Early diagnosis of systemic tumors can significantly reduce morbidity and mortality. Molecular genetic testing has been suggested for patients with early-onset (<30 years)

cerebellar hemangioblastoma, early-onset retinal capillary hemangioblastoma, or familial clear cell renal carcinoma.

Maher ER, Neumann HP, Richard S. Von Hippel–Lindau disease: a clinical and scientific review. *Eur J Hum Genet.* 2011;19(6):617–623.

Toy BC, Agrón E, Nigam D, Chew EY, Wong WT. Longitudinal analysis of retinal hemangioblastomatosis and visual function in ocular von Hippel–Lindau disease. *Ophthalmology.* 2012;119(12):2622–2630.

## Sturge-Weber Syndrome

Sturge-Weber syndrome (SWS; encephalofacial angiomatosis) consists of a facial cutaneous vascular malformation (port-wine stain) with ipsilateral leptomeningeal vascular malformation. Extraocular features are summarized in Table 28-6, with examples shown in Figures 28-17 and 28-18.

Any portion of the ocular circulation may be anomalous in SWS. When the skin lesion involves the eyelids, increased conjunctival vascularity commonly produces a pinkish discoloration. An abnormal plexus of episcleral vessels is often present.

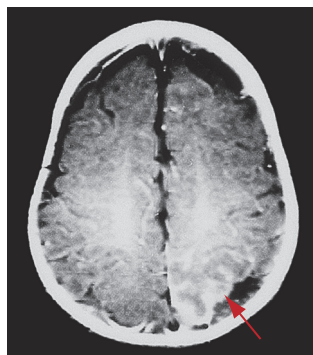
The retina sometimes shows tortuous vessels and arteriovenous communications. Choroidal hemangioma is the most significant retinal anomaly associated with SWS. The tumor is composed of well-formed choroidal vessels, which give the fundus a uniform deep-red color that has been compared to that of tomato ketchup (Fig 28-19). Sometimes only the posterior pole is involved; in other cases, the entire fundus is affected. Choroidal hemangiomas are usually asymptomatic in childhood. During adolescence or adulthood, the choroid sometimes becomes markedly thickened. Degeneration or detachment of the overlying retina may follow. No treatment has been proven to prevent or reverse such deterioration, but scattered application of laser photocoagulation may help.

Glaucoma is the most common and most serious ocular complication. It has been reported to occur in up to approximately 70% of patients with SWS. Causes of elevated intraocular pressure (IOP) include elevated episcleral venous pressure, hyperemia of the ciliary body with hypersecretion of aqueous, and developmental anomaly of the anterior chamber angle. Involvement of the skin of the upper eyelid, choroidal hemangioma, iris heterochromia, and episcleral hemangioma increase the likelihood of glaucoma. Onset of glaucoma can be at birth or later in childhood.

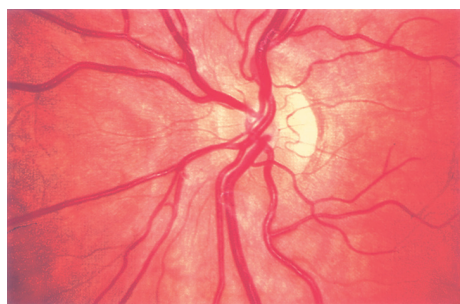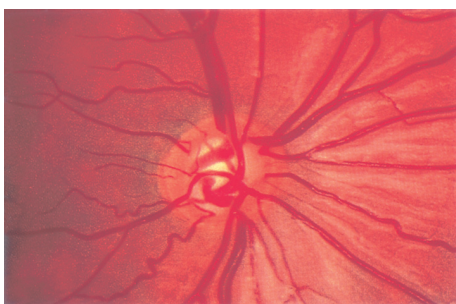
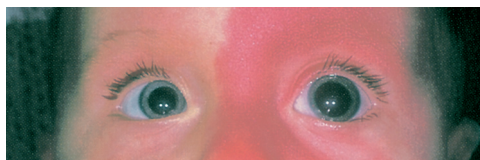**Table 28-6 Extraocular Features in Sturge-Weber Syndrome**

Feature	Characteristics
Port-wine stain	Congenital facial cutaneous vascular malformation (dilatation of the deep dermal plexus)
Leptomeningeal vascular malformation	Hemifacial lesion, typically unilateral Ipsilateral to port-wine stain Potentially associated with cerebral calcification (occipital, parietal, temporal, and occasionally frontal lobe), seizures, focal neurologic defect, and highly variable cognitive impairment

**Figure 28-17** Axial gadolinium-enhanced T1-weighted MR image shows vascular malformation with underlying cortical atrophy (*arrow*) in the left occipital lobe of a 4-month-old girl with Sturge-Weber syndrome.



**Figure 28-18** Facial port-wine stain involving the left eyelids, associated with ipsilateral buphthalmos, in an infant girl with Sturge-Weber syndrome and glaucoma.



**Figure 28-19** Fundus appearance in an adolescent boy with Sturge-Weber syndrome. Note the glaucomatous disc cupping and deeper red color of surrounding choroid, right eye (**A**), compared with the healthy fellow eye (**B**).

SWS glaucoma is difficult to treat. Initial therapy with topical eyedrops can be effective, especially in cases of later onset. Surgery is indicated in early-onset cases and when medical treatment is inadequate. Adequate long-term control of IOP can frequently be achieved, but multiple operations are typically necessary. A particular risk of glaucoma surgery in SWS is intraoperative or postoperative exudation or hemorrhage from anomalous choroidal vessels; this complication is caused by rapid ocular decompression. The surgeon must exercise special care with implanted glaucoma drainage devices to prevent excessive early postoperative hypotony. Postsurgical accumulation of choroidal or subretinal fluid may be dramatic, but spontaneous resorption usually occurs within 1–2 weeks.

Angle surgery (goniectomy and trabeculotomy) has been used successfully in some patients with SWS. Treatment of affected skin with a pulsed dye laser has been shown to reduce vascularity, considerably improving appearance without causing significant damage to dermal tissue.

Khaier A, Nischal KK, Espinosa M, Manoj B. Periocular port wine stain: the Great Ormond Street Hospital experience. *Ophthalmology*. 2011;118(11):2274–2278.e1.

## Ataxia-Telangiectasia

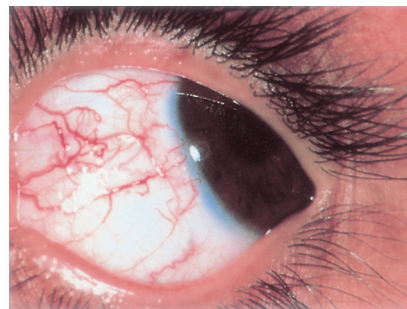
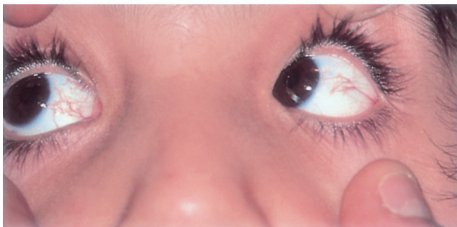Ataxia-telangiectasia (AT; Louis-Bar Syndrome) involves primarily the cerebellum, ocular surface, skin, and immune system. Extraocular features are summarized in Table 28-7.

Ocular motor abnormalities are found in many patients with AT and are frequently among the earliest manifestations. Characteristically, there is poor initiation of saccades with preservation of vestibular-ocular movements, as in congenital ocular motor apraxia. Head thrusts are used to compensate for saccades. Strabismus and nystagmus may also be present.

Telangiectasia of the conjunctiva occurs in 91% of patients and develops between the ages of 3 and 5 years. Involvement is initially interpalpebral but away from the limbus (Fig 28-20); it eventually becomes generalized. Similar vessel changes can appear in the skin of the eyelids and other sun-exposed areas.

**Table 28-7 Extraocular Features in Ataxia-Telangiectasia**

Feature	Characteristics
Neurologic findings	Truncal ataxia usually noted during second year of life Subsequent development of dysarthria, dystonia, and choreoathetosis Progressive deterioration of motor function, leading to serious disability by age 10 years Intellectual disability and microcephaly in some patients
Immunologic findings	Defective T-cell function is usually associated with hypoplasia of the thymus and decreased levels of circulating immunoglobulin Recurrent respiratory tract infections (frequent cause of mortality) Increased susceptibility to malignancy (frequent cause of mortality)
Oncologic findings	Greatly increased sensitivity to the tissue-damaging adverse effects of therapeutic radiation and many chemotherapeutic agents Increased risk of malignancy and radiation damage can also occur in heterozygous carriers
Shagreen patch	Typically located in lumbosacral area Onset after puberty



**Figure 28-20** Abnormally dilated and tortuous interpalpebral conjunctival vessels in a child with ataxia-telangiectasia, seen only in the interpalpebral fissure.



Individuals with AT are much more sensitive to the tissue-damaging adverse effects of therapeutic radiation and many chemotherapeutic agents. Defective T-cell function in patients with AT is usually associated with hypoplasia of the thymus and decreased levels of circulating immunoglobulin. Recurrent respiratory tract infections and increased susceptibility to malignant tumors are frequent causes of mortality.

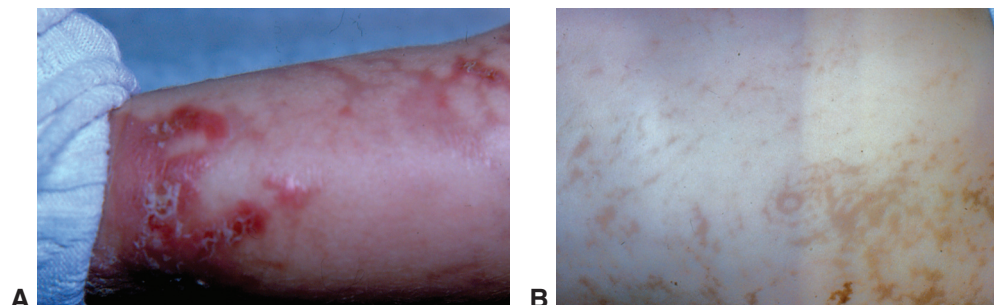
### Incontinentia Pigmenti

Incontinentia pigmenti (IP; Bloch-Sulzberger syndrome) affects the skin, brain, and eyes. Extraocular features are summarized in Table 28-8, with examples of skin lesions shown in Figure 28-21. The condition has an X-linked dominant inheritance pattern, with a presumed lethal effect on the hemizygous male fetus.

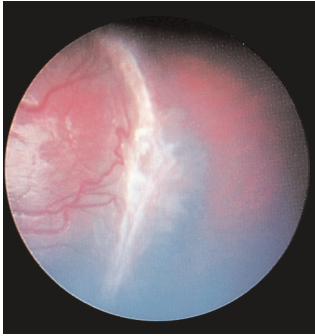
Ocular involvement occurs in 35%–77% of cases and tends to be unilateral or very asymmetric if bilateral, typically in the form of proliferative retinal vasculopathy that closely resembles retinopathy of prematurity. At birth, the only detectable abnormality may be incomplete peripheral retinal vascularization. Abnormal arteriovenous connections,

**Table 28-8 Extraocular Features in Incontinentia Pigmenti**

Feature	Characteristics
Dermatologic findings	Usually normal skin appearance at birth Development of erythema and bullae during the first few days of life, usually on the extremities (see Fig 28-21A) Persistence of lesions for weeks to months When healed, appearance of lesions as clusters of small, hyperpigmented macules in a characteristic “splashed paint” distribution (see Fig 28-21B), most prominently on the trunk
Neurologic findings	Microcephaly, hydrocephalus, seizures, and varying degrees of cognitive impairment in one-third of patients
Dental findings	Missing and malformed teeth in roughly two-thirds of cases
Other findings	Scoliosis, skull deformities, cleft palate, and dwarfism, among other findings, occur less commonly



**Figure 28-21** Pigmented skin lesions of incontinentia pigmenti. **A**, Bullous lesions. **B**, Hyperpigmented macules. (Courtesy of Edward L. Raab, MD.)



**Figure 28-22** Vascular abnormalities of the temporal retina, right eye, in a 2-year-old with incontinentia pigmenti. Note the avascularity peripheral to the circumferential white vasoproliferative lesion, which showed profuse leakage on fluorescein angiography.

microvascular abnormalities, and neovascular membranes develop at or near the junction of the vascular and avascular retina (Fig 28-22). Rapid progression sometimes leads to total retinal detachment and retrolental membrane formation within the first few months of life. Microphthalmia, cataract, glaucoma, optic atrophy, strabismus, and nystagmus may occur, usually secondary to end-stage retinopathy.

Sequential retinal evaluations for the first 1–2 years of life are necessary to identify eyes that require treatment. The retinopathy of IP has been managed by photocoagulation or cryotherapy with varying degrees of success. Treatment is usually applied primarily to the avascular peripheral retina, as in the management of retinopathy of prematurity.

O'Doherty M, Mc Creery K, Green AJ, Tuwir I, Brosnahan D. Incontinentia pigmenti—ophthalmological observation of a series of cases and review of the literature. *Br J Ophthalmol.* 2011;95(1):11–16.

### Wyburn-Mason Syndrome

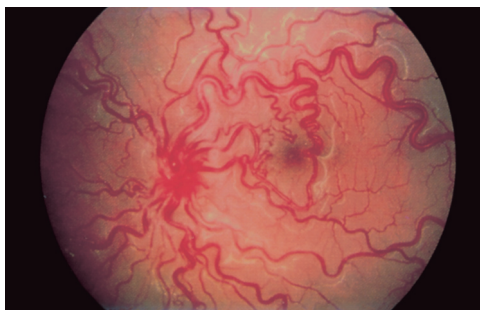
Wyburn-Mason syndrome (racemose angioma) is a nonhereditary arteriovenous malformation of the eye and brain. Extraocular features are summarized in Table 28-9.

Ocular manifestations are unilateral and congenital, and they may progress during childhood. The typical lesion consists of markedly dilated and tortuous vessels that shunt blood directly from arteries to veins (Fig 28-23). These vessels do not leak fluid. Vision ranges from normal to markedly reduced. Intraocular hemorrhage and secondary neovascular glaucoma are possible complications. More than half of affected eyes are blind, and an additional one-quarter have severe visual impairment.

**Table 28-9 Extraocular Features in Wyburn-Mason Syndrome**

Feature	Characteristics
Dermatologic findings	Maxillofacial or cutaneous facial AVM
Neurologic findings	AVM, especially in midbrain Frequent source of hemorrhage May result in seizures, mental changes, hemiparesis, and papilledema

**Figure 28-23** Wyburn-Mason syndrome, or racemose angioma of the retina, left eye.



No treatment is indicated for primary lesions. Treatment may be considered for associated complications, such as scatter photocoagulation for ischemic venous occlusive disease, vitrectomy for nonclearing vitreous hemorrhage, and cyclodestructive treatment for neovascular glaucoma.

### Klippel-Trénaunay Syndrome

Klippel-Trénaunay syndrome (KTS) is a neuro-oculocutaneous disorder consisting of a vascular nevus involving an extremity, varicosities of that extremity, and hypertrophy of bone and soft tissue. When arteriovenous malformation is also present, the disease is called *Klippel-Trénaunay-Weber syndrome*. Occurrence of KTS is sporadic and the etiology is unknown. Ophthalmic findings include vascular anomalies of the orbit, iris, retina, choroid, and optic nerve, as well as optic nerve and chiasmal gliomas. There is also a risk of glaucoma.

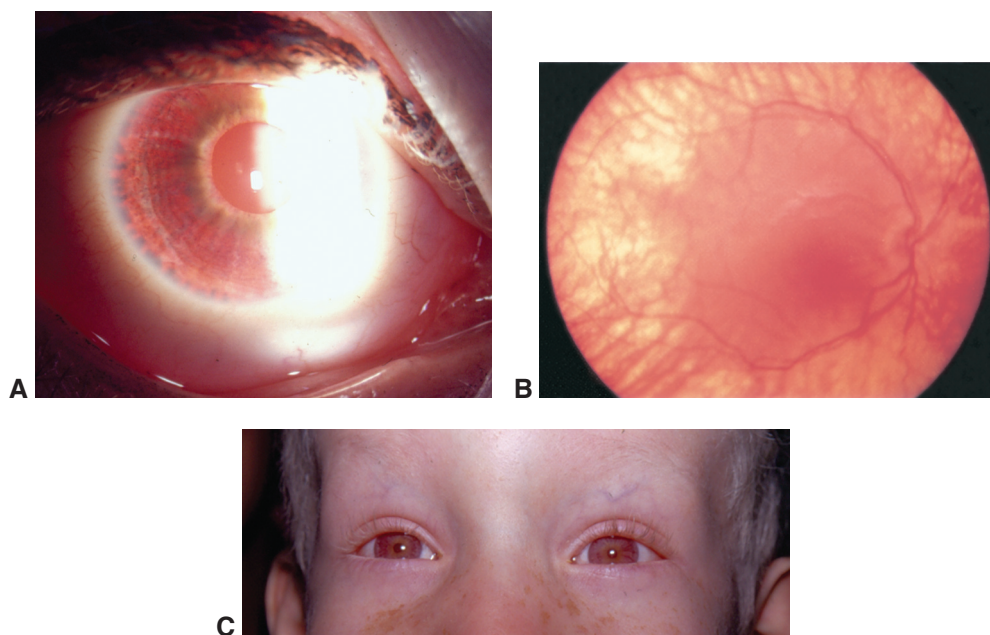
KTS is a complex syndrome with no single treatment protocol. Treatment is individualized to the patient. At present, many of the symptoms may be treated, but there is no cure for this syndrome.

## Albinism

Albinism is a group of conditions that involve the synthesis of melanin in the skin and eye (*oculocutaneous albinism [OCA]*) or the eye alone (*ocular albinism [OA]*).

### Diagnosis

The major ophthalmic findings in all types of OCA and OA are iris transillumination from decreased pigmentation, foveal aplasia or hypoplasia, and a characteristic deficit of pigment in the retina, especially peripheral to the posterior pole (Fig 28-24A, B). Nystagmus, photophobia, high refractive errors, and reduced central visual acuity are often present, and visual acuity ranges from 20/25 to 20/200. If a child has significant foveal hypoplasia, nystagmus will begin at 2–3 months of age. The severity of the visual impairment tends to be proportional to the degree of nystagmus and foveal hypoplasia. Optical coherence tomography has demonstrated that the size of the photoreceptor outer segment is the strongest predictor of visual acuity. An abnormally large number of crossed fibers



**Figure 28-24** **A**, Transillumination of iris in albinism, right eye. **B**, Fundus in albinism, right eye, demonstrating complete lack of pigment and macular hypoplasia. **C**, Child with oculocutaneous albinism type 2. Note the white hair, eyebrows, and lashes and light-colored irides and freckles. (Parts A and C courtesy of Edward L. Raab, MD.)

appear in the optic chiasm of patients and animals with albinism, precluding stereopsis and often inducing strabismus. Asymmetric visual evoked potentials are often seen in affected patients and may be helpful in diagnosis.

There are 4 major types of OCA, all of which exhibit various degrees of skin and hair pigmentation (Fig 28-24C). They are autosomal recessive and are caused by different gene mutations (Table 28-10).

Ocular albinism (OA1), also called *Nettleship-Falls ocular albinism*, is usually caused by a mutation in the *GPR143* gene on the X chromosome. This gene controls melanosome number and size; the mutation results in macromelanosomes, which may be revealed by skin biopsy. Affected individuals appear to have decreased pigment in the eyes but not the skin. Patches of decreased pigment in the fundus and iris transillumination are apparent in many female carriers.

Albinism can be part of a broader syndrome, such as Hermansky-Pudlak syndrome or Chédiak-Higashi syndrome, both of which are autosomal recessive. *Hermansky-Pudlak syndrome* occurs with higher frequency in Puerto Rico and consanguineous populations and is characterized by pulmonary interstitial fibrosis and bleeding abnormalities. *Chédiak-Higashi syndrome* is a rare condition characterized by increased susceptibility to bacterial infections. Whenever albinism is diagnosed in a child, the clinician should inquire whether the patient has bleeding or bruising tendencies or experiences frequent infections.

**Table 28-10 Classification of Major Types of Oculocutaneous Albinism (OCA)**

Type of OCA	Defective Gene	Locus	Associated Findings
OCA1A	Tyrosinase gene ( <i>TYR</i> )	11q14–q21	White skin and hair; no tyrosinase; poorest vision
OCA1B	Tyrosinase gene ( <i>TYR</i> )	11q14–q21	“Yellow variant”; some tyrosinase activity
OCA minimal pigment (MP)	Tyrosinase gene ( <i>TYR</i> )	11q14–q21	Some tyrosinase activity
OCA temperature-sensitive	Tyrosinase gene ( <i>TYR</i> )	11q14–q21	Tyrosine function in cooler areas of body only
OCA2	<i>OCA2</i> gene	15q11.2–q12	Most prevalent worldwide; seen frequently in African Americans
OCA3	Tyrosinase-related protein 1 gene ( <i>TYRP1</i> )	9p23	“Red rufous” type; reddish hair; seen in persons of African descent; mild visual abnormalities
OCA4	Membrane-associated transporter protein gene ( <i>MATP</i> )	5p13.3	Common in Japanese population

Khan AO, Tamimi M, Lenzner S, Bolz HJ. Hermansky-Pudlak syndrome genes are frequently mutated in patients with albinism from the Arabian Peninsula. *Clin Genet.* 2016;90(1):96–98.

Mohammad S, Gottlob I, Kumar A, et al. The functional significance of foveal abnormalities in albinism measured using spectral-domain optical coherence tomography. *Ophthalmology.* 2011;118(8):1645–1652.

## Treatment

Significant refractive errors are treated with prescription glasses. Strabismus surgery is performed when appropriate. Tinted glasses may be used for patients with photophobia. Patients with OCA are at risk for skin cancer and should be counseled about limiting sun exposure.

Levin AV, Stroh E. Albinism for the busy clinician. *J AAPOS.* 2011;15(1):59–66.

## Diabetes Mellitus

Type 1, or insulin-dependent, diabetes mellitus was formerly called *juvenile-onset diabetes mellitus*. The prevalence of retinopathy in this condition is directly proportional to the duration of diabetes mellitus after puberty. Poor glucose control can cause cataract. Retinopathy rarely occurs less than 15 years after the onset of diabetes mellitus. Proliferative diabetic retinopathy is rare in pediatric cases (see BCSC Section 12, *Retina and Vitreous*). Diabetes mellitus, especially in young children, may be part of *DIDMOAD syndrome* (*diabetes insipidus, diabetes mellitus, optic atrophy, and deafness*). This

condition, which is also known as *Wolfram syndrome*, is associated with congenital cataracts as well. BCSC Section 1, *Update on General Medicine*, discusses diabetes mellitus in greater detail.

To screen for diabetic retinopathy, the American Academy of Ophthalmology recommends annual ophthalmic examinations beginning 5 years after the onset of type 1 diabetes mellitus.

Treatment is discussed in BCSC Section 12, *Retina and Vitreous*.

American Academy of Ophthalmology Retina/Vitreous Panel. Preferred Practice Pattern Guidelines. *Diabetic Retinopathy*. San Francisco, CA: American Academy of Ophthalmology; 2017. Available at [www.aao.org/ppp](http://www.aao.org/ppp).

## Intrauterine or Perinatal Infection

---

Maternally transmitted congenital infections cause ocular damage through one or more of the following means: direct action of the infecting agent, which damages tissue; a teratogenic effect, which causes malformation; or delayed reactivation of the agent after birth, which damages developed tissue by direct action or inflammation.

Most perinatal disorders have a broad spectrum of clinical presentation, ranging from silent disease to life-threatening tissue and organ damage. Common, classic types of congenital infections are represented in the mnemonic *TORCH*: toxoplasmosis, rubella, cytomegalovirus, and herpesviruses.

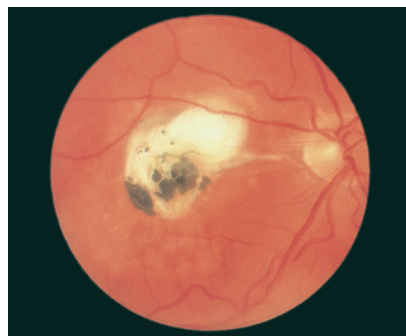
### Toxoplasmosis

Systemic infection in humans by the obligate intracellular parasite *Toxoplasma gondii* is common and usually goes undiagnosed. Felines are the definitive host. Signs and symptoms may include fever, lymphadenopathy, and sore throat. The percentage of antibody titer–positive persons in the United States increases with age (younger than 5 years, 5%; older than 80 years, 60%).

The incidence of congenital toxoplasmosis ranges from 1 to 10 per 10,000 live births. Toxoplasmosis can be acquired congenitally via transplacental transmission from an infected mother to the fetus. Congenital infection can result in retinitis, hepatosplenomegaly, intracranial calcifications, microcephaly, and developmental delay.

Ocular manifestations besides retinitis include choroiditis, iritis, and anterior uveitis (Fig 28-25). The area of active retinal inflammation is usually thickened and cream colored with an overlying vitritis, frequently in the macula. This area may be at the edge of an old, flat, atrophic scar (a so-called satellite lesion). Previously, apparently acquired *Toxoplasma* retinitis was thought to represent reactivation of a congenital infection; however, recent evidence suggests that most of these patients are infected postnatally. Diagnosis is primarily clinical.

Ocular toxoplasmosis does not require treatment unless it threatens vision. Systemic treatment involves the use of one or more antimicrobial drugs with or without oral corticosteroids. Commonly used antimicrobial agents are pyrimethamine and



**Figure 28-25** Toxoplasmosis chorioretinitis, right eye.

sulfadiazine. Corticosteroids should typically be used with antimicrobial coverage. Intravitreal injection of clindamycin and dexamethasone has been reported as a possible alternative treatment.

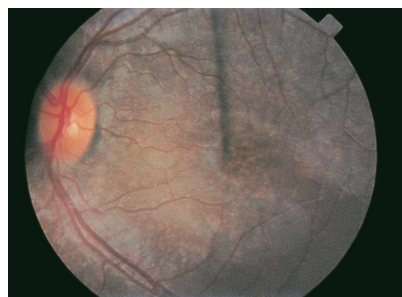
Further details regarding diagnosis and management can be found in BCSC Section 9, *Uveitis and Ocular Inflammation*.

### Rubella

Congenital rubella (German measles) syndrome is a well-defined combination of ocular, otologic, and cardiac abnormalities, accompanied by microcephaly and variable developmental delay. The incidence has decreased markedly in North America since widespread vaccination of children was instituted in the late 1960s; however, rubella remains a cause of infant morbidity and mortality in less-developed countries.

Ocular abnormalities include a peculiar nuclear cataract that is sometimes floating in a liquefied lens cortex, glaucoma, microphthalmia, and retinal abnormalities that vary from a subtle salt-and-pepper retinopathy (most common finding; Fig 28-26) to pseudoretinitis pigmentosa. Diagnosis is based on this characteristic clinical picture and is supported by results of serologic testing. The virus itself can be isolated from pharyngeal swabs and from the lens contents at the time of cataract surgery.

Lensectomy is usually required for cataracts. Infected eyes are prone to postoperative inflammation and subsequent secondary membrane formation. Thus, topical steroids and



**Figure 28-26** Fundus photograph from a 6-year-old patient with rubella syndrome (electroretinography results were normal).

mydriatics should be used aggressively. In adults, rubella virus infection has been identified as a probable cause of Fuchs heterochromic uveitis.

## Cytomegalovirus

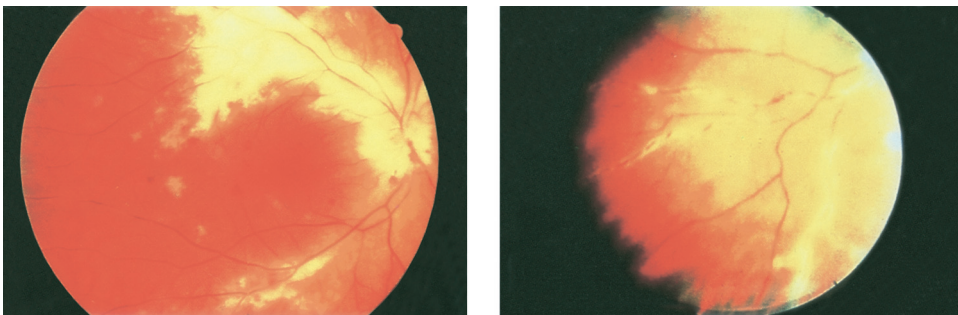
Cytomegalovirus (CMV), a member of the herpesvirus family, is a ubiquitous virus that can cause a wide range of infection, from asymptomatic acquired infection in immunocompetent individuals to severe infections in newborn infants and immunocompromised patients. Over 80% of adults in developed countries have antibodies to the virus.

Congenital infection with CMV is the most common congenital infection in humans; it occurs in approximately 1% of infants. Clinically apparent disease is present in 10%–15% of infected neonates, and 20%–30% of these cases are fatal. Transmission to the fetus or newborn can occur transplacentally, from contact with an infected birth canal during delivery, or from ingestion of infected breast milk or maternal secretions. Congenital CMV disease is characterized by fever, jaundice, hematologic abnormalities, deafness, microcephaly, and periventricular calcifications.

Ophthalmic manifestations of congenital CMV infection occur primarily in infants with systemic symptoms and include retinochoroiditis (Fig 28-27), optic nerve anomalies, microphthalmia, cataract, and uveitis. The retinochoroiditis usually presents with bilateral focal involvement consisting of areas of RPE atrophy and whitish opacities mixed with retinal hemorrhages. The retinitis can be progressive, or it may present as a quiescent CMV chorioretinal scar that is difficult to differentiate from the scar seen in toxoplasmosis. CMV retinitis can be acquired in children who are immunocompromised (most frequently by infection with HIV or AIDS or following organ transplantation or chemotherapy). The retinitis is a diffuse retinal necrosis with areas of retinal thickening and whitening, hemorrhages, and venous sheathing. Vitritis may also be present.

Diagnosis is based on the clinical presentation in acquired disease and is supplemented by serologic testing for antibodies to CMV in congenital infection. In infected infants, the virus can be recovered from bodily secretions.

Infants with severe systemic or sight-threatening disease are usually treated with ganciclovir. Medications that are available for treatment of older immunocompromised children include ganciclovir, valganciclovir, foscarnet, cidofovir, and fomivirsen.



**Figure 28-27** Active cytomegalovirus retinochoroiditis in a premature infant, right eye.



## Herpes Simplex Virus

Herpes simplex virus (HSV) is a member of the herpesvirus family, which includes 2 types of simplex virus (HSV-1 and HSV-2), herpes zoster, Epstein-Barr virus, and CMV. Neonatal HSV infection occurs in 1 in 3000 to 20,000 births and is usually secondary to HSV-2. HSV-1 typically affects the eyes, skin, and mouth region and is transmitted by close personal contact. HSV-2 is typically associated with genital infection through venereal transmission.

Congenital HSV infection is usually acquired during passage through an infected birth canal. The neonatal infection is confined to the CNS, skin, oral cavity, and eyes in one-third of cases. It commonly manifests with vesicular skin lesions, ulcerative mouth sores, and keratoconjunctivitis. Disseminated disease occurs in two-thirds of cases and can involve the liver, adrenal glands, and lungs. Eye involvement in congenital infection can include conjunctivitis, keratitis, retinochoroiditis, and cataracts. Keratitis can be epithelial or stromal. Retinal involvement can be severe and may include massive exudates and retinal necrosis.

Affected infants are treated with systemic acyclovir. The mortality rate from disseminated disease is significant, and survivors usually have permanent ocular and CNS impairment.

Marquez L, Levy ML, Munoz FM, Palazzi DL. A report of three cases and review of intrauterine herpes simplex virus infection. *Pediatr Infect Dis J*. 2011;30(2):153-157.

## Syphilis

Syphilis is caused by the spirochete *Treponema pallidum*, and sexual contact is the usual route of transmission. Fetal infection occurs following maternal spirochetemia. The longer the mother has had syphilis, the lower is the risk of transmitting the disease to her child. If a mother has contracted primary or secondary disease, approximately half of her offspring will be infected. In cases of untreated late maternal syphilis, approximately 70% of infants are healthy. The incidence of congenital syphilis in the United States is 15.7 cases per 100,000 live births.

Signs and symptoms of congenital syphilis include unexplained premature birth, large placenta, persistent rhinitis, intractable rash, unexplained jaundice, hepatosplenomegaly, pneumonia, anemia, generalized lymphadenopathy, and metaphyseal abnormalities or periostitis on radiographs. Congenitally acquired infection can lead to neonatal death. Early eye involvement in congenital syphilis is rare.

In some infants, chorioretinitis appears as a salt-and-pepper granularity of the fundus. Pseudoretinitis pigmentosa may follow. In rare cases, anterior uveitis, glaucoma, or both may develop. In other cases, signs and symptoms may not appear until late childhood or adolescence. Widely spaced, peg-shaped teeth; eighth nerve deafness; and interstitial keratitis constitute the *Hutchinson triad*. Other manifestations include saddle nose, short maxilla, and linear scars around body orifices. Bilateral interstitial keratitis, the classic ophthalmic finding in older children and adults, occurs in approximately 10% of patients.

A diagnosis of congenital syphilis is confirmed by identification of *T pallidum* by dark-field microscopy or fluorescent antibody testing. The detection of specific immunoglobulin M is currently the most sensitive serologic method.

Congenital syphilis in neonates is treated with intravenous aqueous crystalline penicillin G. Serologic tests are repeated at 2 to 4, 6, and 12 months after the conclusion of treatment, or until results become nonreactive or the titer has decreased fourfold. Persistent positive titers or a positive cerebrospinal fluid VDRL test result at 6 months should prompt retreatment.

Also see BCSC Section 9, *Uveitis and Ocular Inflammation*.

Centers for Disease Control and Prevention. 2016 sexually transmitted diseases surveillance: syphilis. Available at <https://www.cdc.gov/std/stats16/default.htm>. Accessed March 7, 2018.

## Lymphocytic Choriomeningitis

Lymphocytic choriomeningitis virus (LCMV) is an arenavirus that is transmitted by exposure to infected rodents (including house and laboratory mice and pet hamsters). Infants with congenital LCMV infection present with CNS abnormalities, including hydrocephaly, microcephaly, intracranial calcifications, and cognitive impairment. Chorioretinal scars, which may involve the entire macula, may occur without neurologic abnormalities. The appearance of these scars is similar to that of scars seen in patients with toxoplasmosis, CMV infection, and Aicardi syndrome. The diagnosis of LCMV infection should be considered in infants with chorioretinal scars when results of tests for these more common etiologies are negative. Elevated LCMV antibody titers establish the diagnosis. No specific treatment is available apart from exposure prevention.

## Zika Virus

Zika virus is a flavivirus transmitted by the *Aedes aegypti* mosquito. It has recently been associated with congenital microcephaly and chorioretinal lesions. In a series of 29 infants in Brazil with presumed intrauterine Zika virus infection, ocular abnormalities were present in 10 infants (35%) and were bilateral in 7 infants. The characteristic lesions included posterior pole pigmentary clumping and areas of circumscribed chorioretinal atrophy. In addition, 1 baby showed iris colobomas and lens subluxation. Cerebral visual impairment is common.

de Paula Freitas B, de Oliveira Dias JR, Prazeres J, et al. Ocular findings in infants with microcephaly associated with presumed Zika virus congenital infection in Salvador, Brazil. *JAMA Ophthalmol*. 2016;134(5):529–535.

## Malignant Disease

---

### Leukemia

Leukemia in childhood is acute in 95% of cases and is more often lymphocytic than myelocytic. Acute lymphoblastic leukemia is the most common malignant disease of childhood and is responsible for 30% of all cancer cases; there are 4000 new cases per year in the United States. Although the most common ocular manifestation of leukemia is leukemic retinopathy, all ocular structures can be affected. Ocular involvement is highly correlated with CNS involvement.

Leukemic infiltrates in the anterior segment may lead to heterochromia iridis, a change in the architecture of the iris, frank iris infiltrates, spontaneous hyphemas, leukemic cells in the anterior chamber, and pseudohypopyon. Keratic precipitates may be seen, and glaucoma develops in some affected eyes from tumor cells clogging the trabecular meshwork. Anterior chamber paracentesis for cytologic studies may be diagnostic in cases involving the anterior segment. Systemic chemotherapy, local radiation therapy, and topical steroids may be effective for anterior segment complications. Leukemic involvement of the iris may be confused with juvenile xanthogranuloma.

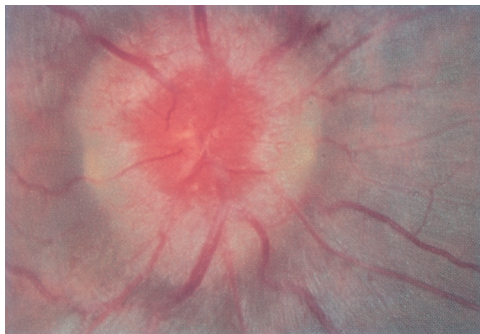
The most common ocular findings are retinal hemorrhages, especially flame-shaped lesions in the nerve fiber layer. They involve the posterior fundus and correlate with other aspects of the disease, such as anemia, thrombocytopenia, and coagulation abnormalities. The hemorrhages may have white centers. Retinal hemorrhages in leukemia can resemble those associated with abusive head trauma (see Chapter 27), and they have been reported as the first manifestation of leukemia. Other forms of retinal involvement include localized perivascular infiltrations, microinfarction, and discrete tumor infiltrations. Histologically, the choroid is the most frequently affected ocular tissue, but choroidal involvement is usually not apparent clinically.

Optic nerve involvement occurs if the disc has been infiltrated by leukemic cells (Fig 28-28), which may cause loss of central vision. Translucent swelling of the disc obscures the normal landmarks; with florid involvement, only a white mass is visible in the region of the disc. The presence of disc edema and loss of central vision in a child with leukemia should be considered a medical emergency because permanent loss of central vision is imminent. Such patients should undergo radiation therapy as soon as possible.

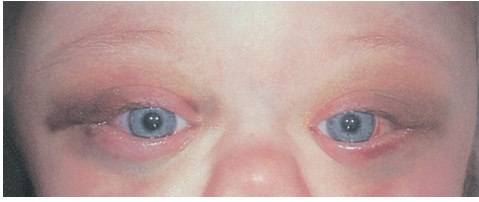
### Neuroblastoma

Neuroblastoma is one of the most common childhood cancers and is the most frequent source of childhood orbital metastasis (89% of cases). It usually originates in either the adrenal gland or the sympathetic ganglion chain in the retroperitoneum or mediastinum. Approximately 20% of all patients with neuroblastoma show clinical evidence of orbital involvement, which is sometimes the initial manifestation of the tumor.

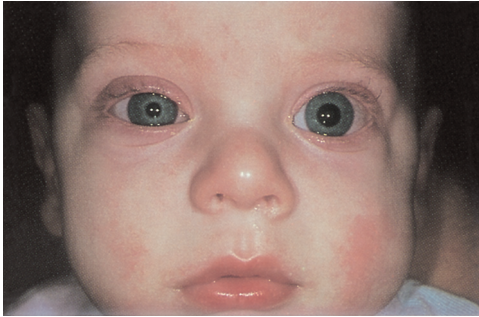The mean age at diagnosis of patients with metastatic orbital neuroblastoma is approximately 2 years; 90% are diagnosed by 5 years of age. Unilateral or bilateral proptosis and



**Figure 28-28** Leukemic infiltration of the optic nerve.



**Figure 28-29** Bilateral orbital metastasis from neuroblastoma in a 2-year-old girl, presenting with periorbital ecchymosis.



**Figure 28-30** Right Horner syndrome, the presenting sign of localized intrathoracic neuroblastoma in a 6-month-old boy.

eyelid ecchymosis are the classic presentations (Fig 28-29). Systemic signs and symptoms may include abdominal fullness and pain, venous obstruction and edema, hypertension caused by renal vascular compromise, and bone pain. Urinalysis for catecholamines is positive in 90%–95% of cases.

*Opsoclonus*, characterized by rapid, multidirectional saccadic eye movements, is a paraneoplastic syndrome that is associated with neuroblastoma and is not related to orbital involvement. It is associated with a good prognosis for survival, but neurologic deficits may persist. Horner syndrome can occur as a result of a primary cervical or apical thoracic neuroblastoma that involves the sympathetic chain (Fig 28-30).

Treatment modalities include surgery, chemotherapy, and radiation therapy. Neuroblastoma that presents in a child younger than 1 year has a more favorable prognosis than that in older children. Approximately 10% of neuroblastomas undergo spontaneous regression.



# Basic Texts

## Pediatric Ophthalmology and Strabismus

---

- Brodsky MC. *Pediatric Neuro-Ophthalmology*. 3rd ed. New York: Springer-Verlag; 2016.
- Buckley EG, Freedman S, Shields MB. *Atlas of Ophthalmic Surgery, Vol III: Strabismus and Glaucoma*. St Louis: Mosby-Year Book; 1995.
- Buckley EG, Plager DA, Repka MX, Wilson ME. *Strabismus Surgery: Basic and Advanced Strategies*. New York: Oxford University Press; 2005.
- Coats DK, Olitsky SE. *Strabismus Surgery and Its Complications*. New York: Springer-Verlag; 2007.
- Dutton J. *Atlas of Clinical and Surgical Orbital Anatomy*. 2nd ed. Philadelphia: Elsevier; 2011.
- Hartnett ME, ed. *Pediatric Retina*. 2nd ed. Philadelphia: Lippincott Williams & Wilkins; 2014.
- Helveston EM. *Surgical Management of Strabismus*. 5th ed. Oostende, Belgium: Wayenborgh Publishing; 2005.\*
- Isenberg SJ, ed. *The Eye in Infancy*. 2nd ed. St Louis: Mosby-Year Book; 1994.
- Jones KL, Jones MC, del Campo M. *Smith's Recognizable Patterns of Human Malformation*. 7th ed. Philadelphia: Saunders; 2013.
- Katowitz JA, Katowitz WR. *Pediatric Oculoplastic Surgery*. 2nd ed. New York: Springer; 2018.
- Lambert SR, Lyons CJ, eds. *Taylor and Hoyt's Pediatric Ophthalmology and Strabismus*. 5th ed. Philadelphia: Elsevier; 2017.
- Leigh RJ, Zee DS. *The Neurology of Eye Movements*. 5th ed. New York: Oxford University Press; 2015.
- Miller NR, Newman NJ, Biousse V, Kerrison JB, eds. *Walsh and Hoyt's Clinical Neuro-Ophthalmology*. 6th ed. Philadelphia: Lippincott Williams & Wilkins; 2005.
- Nelson LB, Olitsky SE, eds. *Harley's Pediatric Ophthalmology*. 6th ed. Philadelphia: Lippincott Williams & Wilkins; 2014.
- Parks MM. *Atlas of Strabismus Surgery*. Philadelphia: Harper & Row; 1983.
- Parks MM. *Ocular Motility and Strabismus*. Hagerstown, MD: Harper & Row; 1975.
- Pratt-Johnson JA, Tillson G. *Management of Strabismus and Amblyopia: A Practical Guide*. 2nd ed. New York: Thieme; 2001.
- Rosenbaum AL, Santiago AP, eds. *Clinical Strabismus Management: Principles and Surgical Techniques*. Philadelphia: Saunders; 1999.
- Tasman W, Jaeger EA, eds. *Duane's Ophthalmology on DVD-ROM*. Philadelphia: Lippincott Williams & Wilkins; 2013.
- Traboulsi EI. *A Compendium of Inherited Disorders and the Eye*. New York: Oxford University Press; 2006.
- von Noorden GK. *Atlas of Strabismus*. 4th ed. St Louis: Mosby; 1983.
- von Noorden GK, Campos EC. *Binocular Vision and Ocular Motility*. 6th ed. St Louis: Mosby; 2002.\*

von Noorden GK, Helveston EM. *Strabismus: A Decision Making Approach*. St Louis: Mosby; 1994.\*

Wilson ME, Saunders RA, Trivedi RH, eds. *Pediatric Ophthalmology: Current Thought and A Practical Guide*. Berlin: Springer; 2009.

Wright KW, Strube YJ, eds. *Color Atlas of Strabismus Surgery: Strategies and Techniques*. 4th ed. New York: Springer; 2015.

Wright KW, Strube YJ, eds. *Pediatric Ophthalmology and Strabismus*. 3rd ed. New York: Oxford University Press; 2012.

\* Available online on the Ophthalmic News and Education (ONE®) Network in the Pediatric Ophthalmology Education Center (<https://www.aao.org/pediatric-ophthalmology-strabismus>) and on the Cybersight website (<https://cybersight.org>).

# Related Academy Materials

The American Academy of Ophthalmology is dedicated to providing a wealth of high-quality clinical education resources for ophthalmologists.

## **Print Publications and Electronic Products**

For a complete listing of Academy products related to topics covered in this BCSC Section, visit our online store at <https://store.aao.org/clinical-education/topic/pediatric-ophth-strabismus.html>. Or call Customer Service at 866-561-8558 (toll free, US only) or +1 415-561-8540, Monday through Friday, between 8:00 AM and 5:00 PM (PST).

## **Online Resources**

Visit the Ophthalmic News and Education (ONE®) Network at [aao.org/onenetwork](http://aao.org/onenetwork) to find relevant videos, online courses, journal articles, practice guidelines, self-assessment quizzes, images, and more. The ONE Network is a free Academy-member benefit.

Access free, trusted articles and content with the Academy's collaborative online encyclopedia, EyeWiki, at [aao.org/eyewiki](http://aao.org/eyewiki).





## Requesting Continuing Medical Education Credit

The American Academy of Ophthalmology is accredited by the Accreditation Council for Continuing Medical Education (ACCME) to provide continuing medical education for physicians.

The American Academy of Ophthalmology designates this enduring material for a maximum of 15 *AMA PRA Category 1 Credits*<sup>™</sup>. Physicians should claim only the credit commensurate with the extent of their participation in the activity.

To claim *AMA PRA Category 1 Credits*<sup>™</sup> upon completion of this activity, learners must demonstrate appropriate knowledge and participation in the activity by taking the posttest for Section 6 and achieving a score of 80% or higher.

This Section of the BCSC has been approved by the American Board of Ophthalmology as a Maintenance of Certification (MOC) Part II self-assessment CME activity.

### **To take the posttest and request CME credit online:**

1. Go to [www.aao.org/cme-central](http://www.aao.org/cme-central) and log in.
2. Click on “Claim CME Credit and View My CME Transcript” and then “Report AAO Credits.”
3. Select the appropriate media type and then the Academy activity. You will be directed to the posttest.
4. Once you have passed the test with a score of 80% or higher, you will be directed to your transcript. *If you are not an Academy member, you will be able to print out a certificate of participation once you have passed the test.*

CME expiration date: June 1, 2021. *AMA PRA Category 1 Credits*<sup>™</sup> may be claimed only once between June 1, 2018, and the expiration date.

For assistance, contact the Academy’s Customer Service department at 866-561-8558 (US only) or +1 415-561-8540 between 8:00 AM and 5:00 PM (PST), Monday through Friday, or send an e-mail to [customer\\_service@aa.org](mailto:customer_service@aa.org).



# Study Questions

Please note that these questions are not part of your CME reporting process. They are provided here for your own educational use and identification of any professional practice gaps. The required CME posttest is available online (see “Requesting CME Credit”). Following the questions are a blank answer sheet and answers with discussions. Although a concerted effort has been made to avoid ambiguity and redundancy in these questions, the authors recognize that differences of opinion may occur regarding the “best” answer. The discussions are provided to demonstrate the rationale used to derive the answer. They may also be helpful in confirming that your approach to the problem was correct or, if necessary, in fixing the principle in your memory. The Section 6 faculty thanks the Self-Assessment Committee for providing these self-assessment questions.

1. In testing preliterate children, what optotype has the best calibration and reliability?
  - a. HOTV
  - b. Tumbling E
  - c. Allen figures
  - d. Lighthouse chart
  
2. In what ocular motility abnormality is a comitant deviation present?
  - a. nasal wall fracture
  - b. infantile esotropia
  - c. thyroid orbitopathy
  - d. sixth nerve palsy
  
3. In abbreviations for types of strabismus, the addition of parentheses around the letter *T* indicates what characteristic of an ocular deviation?
  - a. intermittent
  - b. constant
  - c. inward
  - d. outward
  
4. The lateral muscular branch of the ophthalmic artery supplies which extraocular muscle (EOM)?
  - a. superior rectus
  - b. medial rectus
  - c. inferior rectus
  - d. inferior oblique
  
5. The orbital layer of an EOM has what unique characteristic?
  - a. It inserts on the sclera.
  - b. It inserts on the muscle pulley.

424 • Study Questions

- c. It moves the globe.
  - d. It is topographically closer to the globe.
6. On left gaze, the medial rectus muscle of the right eye adducts the eye. What term is used to describe this muscle as the eye adducts?
- a. agonist
  - b. synergist
  - c. antagonist
  - d. reciprocal
7. What EOM has only a primary action and no secondary or tertiary action?
- a. lateral rectus
  - b. inferior rectus
  - c. superior rectus
  - d. superior oblique
8. In a complete third nerve palsy, what action of the superior oblique muscle exacerbates the abducted position of the paretic eye?
- a. primary
  - b. secondary
  - c. tertiary
  - d. quaternary
9. What is the primary site in the development of amblyopia?
- a. visual cortex
  - b. retinal ganglion cells
  - c. nerve fiber layer
  - d. lateral geniculate body
10. In the treatment of moderate amblyopia, pharmacologic treatment has been shown to have what level of success compared to patching?
- a. minimal
  - b. less
  - c. more
  - d. equal
11. After laser surgery, a child with retinopathy of prematurity (ROP) demonstrates a 30 prism diopter ( $\Delta$ ) right exotropia on Hirschberg testing. When the left eye is covered, the right eye does not move medially. What is the most likely reason for this finding?
- a. anomalous retinal correspondence
  - b. suppression scotoma

- c. positive angle kappa
  - d. negative angle kappa
12. To test for a horizontal deviation using the Maddox rod, in what direction should the cylinders be placed in front of the right eye?
- a. 15° meridian
  - b. 45° meridian
  - c. 90° meridian
  - d. 180° meridian
13. A 6-year-old child presents with a 35Δ intermittent exotropia at distance and a 20Δ intermittent exotropia at near. After the patch test, measurements for this patient are 35Δ exotropia at distance and 30Δ exotropia at near. What is the most likely diagnosis?
- a. pseudodivergence excess intermittent exotropia
  - b. divergence excess intermittent exotropia
  - c. intermittent exotropia with a high accommodative convergence/accommodation (AC/A) ratio
  - d. basic intermittent exotropia
14. A 4-year-old child with an intermittent exotropia has been observed and has had fair control of the deviation. At the most recent visit, a decrease in stereopsis was noted. What most likely explains this finding?
- a. A high AC/A ratio has developed in the patient.
  - b. Consecutive esotropia has developed in the patient.
  - c. The patient has increased tenacious proximal fusion.
  - d. Sensory testing was performed after alignment testing.
15. A 5-year-old child presents with Y-pattern exotropia. What finding can be expected on examination?
- a. Overelevation of the eye is seen on adduction and slight upgaze.
  - b. Overelevation is seen on horizontal gaze.
  - c. Fundus excyclotorsion is found on fundus examination.
  - d. Vertical deviation is noted with head tilts.
16. What is the most appropriate surgery to perform for a V-pattern esotropia with no inferior oblique overaction?
- a. bilateral medial rectus recession with inferior transposition (inferoplacement)
  - b. bilateral medial rectus recession with superior transposition (superoplacement)
  - c. bilateral lateral rectus resection with inferior transposition (inferoplacement)
  - d. unilateral medial rectus recession and lateral rectus resection with inferior transposition (inferoplacement)

17. What pattern strabismus would be most successfully addressed with bilateral weakening of the inferior oblique muscles?
  - a. A pattern
  - b. V pattern
  - c. X pattern
  - d. Y pattern
  
18. A 2-year-old child presents with a 30° right head turn. The patient cannot abduct the right eye, and there is narrowing of the palpebral fissure on adduction. What is the most appropriate management?
  - a. magnetic resonance imaging (MRI) of the brain and brainstem
  - b. lumbar puncture for opening pressure
  - c. muscle biopsy and genetics testing
  - d. right medial rectus recession
  
19. With what syndrome has Duane retraction syndrome been associated?
  - a. Goldenhar syndrome
  - b. Klinefelter syndrome
  - c. Turner syndrome
  - d. Waardenburg syndrome
  
20. What defines type 2 Duane retraction syndrome?
  - a. poor adduction and exotropia
  - b. poor abduction and esotropia
  - c. poor abduction and adduction
  - d. poor abduction and exotropia
  
21. For what condition is botulinum toxin type A most effective?
  - a. small-angle esotropia
  - b. large-angle exotropia
  - c. A-pattern esotropia
  - d. chronic sixth nerve palsy
  
22. A 6-year-old child undergoes bilateral 5-mm medial rectus recession for 35Δ esotropia. One week after surgery, there is a measurement of 30Δ exotropia. What is the most appropriate test to perform next?
  - a. test of EOM movements
  - b. measurement of stereopsis
  - c. measurement of vertical deviations
  - d. slit-lamp examination

23. What sort of anomaly is represented by a choroidal coloboma?
- agenesis
  - hypoplasia
  - hyperplasia
  - dysraphism
24. For a 5-month-old child with poor visual behavior but no nystagmus, what diagnosis is likely?
- retinal dystrophy
  - cerebral visual impairment
  - pregeniculate visual impairment
  - congenital cataract
25. Blepharophimosis-ptosis-epicanthus inversus syndrome is usually inherited in what manner?
- autosomal dominant
  - autosomal recessive
  - X-linked dominant
  - X-linked recessive
26. Crouzon syndrome differs from Apert syndrome in that the latter is associated with what finding?
- hypertelorism
  - proptosis
  - significant syndactyly
  - inferior scleral show
27. What is the most common type of strabismus associated with craniosynostosis?
- A-pattern esotropia
  - V-pattern esotropia
  - V-pattern exotropia
  - A-pattern exotropia
28. A 4-day-old infant presents with chemosis, significant discharge, and corneal ulceration. What is the most likely diagnosis?
- chemical conjunctivitis
  - herpes simplex virus conjunctivitis
  - Neisseria gonorrhoeae* conjunctivitis
  - chlamydial conjunctivitis



29. What is an early ocular manifestation of Stevens-Johnson syndrome?
- mucopurulent conjunctivitis
  - symblepharon
  - corneal vascularization
  - entropion
30. A child with new-onset ptosis should be examined for what other finding?
- cataract
  - anisocoria
  - anisometropic amblyopia
  - astigmatism
31. In a patient with Horner syndrome, instillation of apraclonidine would be expected to have what effect?
- dilation of the affected pupil and no effect on the normal pupil
  - dilation of the normal pupil and no effect on the affected pupil
  - dilation of both pupils
  - no effect on the affected pupil when the lesion is postganglionic
32. Abnormal development of what ocular structure is the pathologic defect in primary congenital glaucoma?
- anterior chamber angle tissue
  - Descemet membrane
  - iris
  - optic nerve
33. On gonioscopy, how does the anterior chamber angle of a normal infant eye differ from that of an adult eye?
- The trabecular meshwork is more highly pigmented.
  - The Schwalbe line is often less distinct.
  - The junction between the scleral spur and the ciliary body is easily seen.
  - The uveal meshwork is more difficult to see through.
34. Bilateral posterior subcapsular cataract is diagnosed in a 9-year-old child. What aspect of the examination is most likely to reveal the cause of the cataract?
- medication list
  - musculoskeletal examination
  - family history
  - review of systems

35. What test is most likely to determine the etiology of anterior uveitis in a child?
  - a. antinuclear antibodies
  - b. rheumatoid factor
  - c. HLA-B27
  - d. Lyme serology
36. Tubulointerstitial nephritis is associated with what ocular condition?
  - a. bilateral anterior uveitis
  - b. cataract formation
  - c. serous retinal detachment
  - d. papilledema
37. What is an example of type 1 ROP?
  - a. zone I, any stage ROP with plus disease
  - b. zone I, stage 1 ROP without plus disease
  - c. zone II, stage 3 ROP without plus disease
  - d. zone I, stage 2 ROP without plus disease
38. Leber congenital amaurosis can be best diagnosed with what test?
  - a. A-scan ultrasonography
  - b. electroretinography
  - c. fluorescein angiography
  - d. optical coherence tomography
39. What percentage of retinoblastoma cases arise from somatic nonhereditary mutation of both alleles of *RBI* in a retinal cell?
  - a. 10%
  - b. 40%
  - c. 60%
  - d. 80%
40. Children with optic nerve hypoplasia should undergo MRI to evaluate for what finding?
  - a. bifid septum pellucidum
  - b. empty sella
  - c. ectopic posterior pituitary bright spot
  - d. chiasmal glioma
41. A basal encephalocele is discovered on routine MRI. What is the most likely associated ophthalmic anomaly?
  - a. optic nerve hypoplasia
  - b. optic nerve pit

430 • Study Questions

- c. optic nerve coloboma
  - d. morning glory disc anomaly
42. Spontaneous hyphema can occur with what intraocular lesion?
- a. juvenile xanthogranuloma of the iris
  - b. iris nevus
  - c. iris capillary hemangioma
  - d. iris cyst
43. What is the most common ocular manifestation of abusive head trauma?
- a. corneal abrasion
  - b. hyphema
  - c. subconjunctival hemorrhage
  - d. retinal hemorrhage
44. What condition is associated with an abnormally high number of crossed fibers in the optic chiasm?
- a. ocular albinism
  - b. optic nerve hypoplasia
  - c. achromatopsia
  - d. morning glory disc anomaly

# Answer Sheet for Section 6

## Study Questions

Question	Answer	Question	Answer
1	a b c d	23	a b c d
2	a b c d	24	a b c d
3	a b c d	25	a b c d
4	a b c d	26	a b c d
5	a b c d	27	a b c d
6	a b c d	28	a b c d
7	a b c d	29	a b c d
8	a b c d	30	a b c d
9	a b c d	31	a b c d
10	a b c d	32	a b c d
11	a b c d	33	a b c d
12	a b c d	34	a b c d
13	a b c d	35	a b c d
14	a b c d	36	a b c d
15	a b c d	37	a b c d
16	a b c d	38	a b c d
17	a b c d	39	a b c d
18	a b c d	40	a b c d
19	a b c d	41	a b c d
20	a b c d	42	a b c d
21	a b c d	43	a b c d
22	a b c d	44	a b c d



# Answers

1. **a.** Various optotypes are available for recognition visual acuity testing in preliterate children. LEA symbols and the HOTV test are reliably calibrated and have high testability rates for preschool-aged children. For a shy child, testability may be improved by having the child point to match optotypes on a chart with those on a hand-held card rather than verbally identify them. Several symbol charts, such as Allen figures and the Lighthouse chart, are not recommended by the World Health Organization and the National Academy of Sciences because the optotypes are considered confusing, culturally biased, or nonstandardized. The Tumbling E Chart is accurate but conceptually difficult for many preschool children.
2. **b.** A comitant deviation is one in which the size of the deviation does not vary by more than a few prism diopters ( $\Delta$ ) in different positions of gaze or with either eye used for fixating. This occurs in infantile esotropia. A restrictive orbitopathy or a paretic process would lead to an incomitant deviation, in which the measurement varies significantly in different positions of gaze.
3. **a.** The addition of parentheses around the *T* indicates an intermittent tropia.
4. **a.** The muscular branches of the ophthalmic artery provide the most important blood supply to the extraocular muscles (EOMs). The *lateral muscular branch* supplies the lateral rectus, superior rectus, superior oblique, and levator palpebrae superioris muscles; the *medial muscular branch*, the larger of the two, supplies the inferior rectus, medial rectus, and inferior oblique muscles.
5. **b.** The EOMs exhibit a distinct 2-layer organization: an outer *orbital layer*, which acts only on connective tissue pulleys, and an inner *global layer*, whose tendon inserts on the sclera to move the globe.
6. **a.** There are 3 important terms relating to the muscles used in monocular eye movements: *agonist*, the primary muscle moving the eye in a given direction; *synergist*, the muscle in the same eye as the agonist that acts with the agonist to produce a given movement; and *antagonist*, the muscle in the same eye as the agonist that acts in the direction opposite to that of the agonist.
7. **a.** With the eye in primary position, the horizontal (medial and lateral) rectus muscles move the eye only horizontally and thus have a primary horizontal action but no secondary or tertiary action.
8. **c.** In a complete third nerve palsy, the only functioning EOMs are the lateral rectus and superior oblique. The tertiary action of the superior oblique is abduction that exacerbates the outward position of the eye.
9. **a.** Positron emission tomography has shown that cortical blood flow and glucose metabolism are lower during stimulation of the amblyopic eye compared with the normal eye, suggesting the visual cortex as the primary site of amblyopia.
10. **d.** Pharmacologic treatment of moderate amblyopia (visual acuity of 20/100 or better) is as effective as patching and may also be successful in more severe amblyopia (visual acuity of 20/125 to 20/400), particularly in younger children.
11. **c.** *Angle kappa* is the angle between the visual axis and the anatomical pupillary axis of the eye. The fovea is usually slightly temporal to the pupillary axis, making the corneal light reflection slightly nasal to the center of the cornea. This is termed *positive angle kappa*. A

large positive angle kappa (eg, from temporal dragging of the macula in cicatricial retinopathy of prematurity [ROP]) can simulate exotropia.

12. **d.** In the *Maddox rod test*, a series of parallel cylinders convert a point source of light into a line image perpendicular to the cylinders. To test for horizontal deviations, the Maddox rod cylinders are placed horizontally in front of the right eye (180° meridian). The patient, fixating on a point source of light, sees a vertical line with the right eye and the point source of light with the left.
13. **a.** When the exodeviation at distance is larger than the deviation at near fixation by 10Δ or more but the distance and near measurements become similar after 30–60 minutes of binocular occlusion using a patch (the *patch test*), pseudodivergence excess intermittent exotropia is the likely diagnosis. An intermittent exotropia may become constant after disruption of binocular fusion with patch testing. In true divergence excess intermittent exotropia, the distance–near discrepancy would persist after patch testing. A patient with distance–near discrepancy may have a high accommodative convergence/accommodation (AC/A) ratio, which would be defined by persistence of the distance–near discrepancy after the patch test but resolution of this discrepancy with a +3.00 add. In a patient with basic intermittent exotropia, the measurement of the deviation at distance would be within 10Δ of the deviation measurement at near without patch testing or a +3.00 add.
14. **d.** Because visual acuity and alignment tests are dissociating and may adversely affect assessment of strabismus control, they should be performed after sensory tests for stereopsis and fusion. Stereopsis may decrease with worsening control of the deviation. Development of a high AC/A ratio would imply a decreased exotropia at near. A spontaneous consecutive esotropia would be rare in a patient with intermittent exotropia. Improved tenacious proximal fusion would improve stereopsis.
15. **a.** In patients with a Y pattern, the exodeviation is greater in upgaze, while the deviation is similar in primary position and in downgaze. This is often seen with pseudo-overaction of the inferior oblique muscle. There may be overelevation of the eye on adduction and slight upgaze, as opposed to true inferior oblique overaction, which is seen with overelevation on horizontal gaze. Other findings that would indicate true inferior oblique overaction include fundus excyclotorsion and vertical deviation with head tilts.
16. **a.** In a V-pattern esotropia, the medial rectus muscles can be recessed and moved toward the apex of the deviation, which would be inferiorly in this case. Lateral muscles should be moved away from the apex of the deviation. A useful mnemonic is MALE: *m*edial rectus muscle to the *a*pex, *l*ateral rectus muscle to the *e*mpy space. When horizontal muscle recession-resection is performed, displacement should be in opposite directions, but this will cause symptomatic torsion if the patient has vision in the eye.
17. **b.** Inferior oblique overaction commonly causes a V pattern. A patterns are most commonly caused by superior oblique overaction. X and Y patterns result from pseudo-overaction of the inferior oblique muscles, and weakening them would not collapse the pattern.
18. **d.** The patient described has type 1 Duane retraction syndrome. A medial rectus recession on the affected side would correct the head turn and centralize the field of binocular vision. While limited abduction may be a result of a sixth nerve palsy, globe retraction causing narrowing of the palpebral fissures is diagnostic of Duane retraction syndrome. Magnetic resonance imaging (MRI) is thus not necessary for further evaluation of a sixth nerve palsy. A lumbar puncture to check for elevated intracranial pressure, which may be indicated in

the presence of a sixth nerve palsy, is also not indicated. A muscle biopsy for strabismus is used in cases of suspected chronic progressive external ophthalmoplegia (CPEO) to evaluate for ragged red fibers or mitochondrial DNA changes. A child with CPEO would be expected to present with ptosis and limitation of eye movements but not globe retraction.

19. **a.** Duane retraction syndrome has been associated with Goldenhar syndrome (hemifacial microsomia, ocular dermoids, preauricular skin tags, and eyelid colobomas) and Wilder-vanck syndrome (sensorineural hearing loss and Klippel-Feil anomaly with fused cervical vertebrae). Klinefelter syndrome (XXY) and Turner syndrome (XO) are chromosomal abnormalities. Waardenburg syndrome is characterized by hearing loss, retinitis pigmentosa, and a white forelock.
20. **a.** Type 1, the most common form of Duane retraction syndrome, is defined as poor abduction and esotropia. A patient may adopt a head turn to establish binocular fusion, and the esotropia may be seen only in primary gaze or with a head turn to the opposite direction. Type 2 is defined by limited adduction and exotropia. Type 3 is defined as poor abduction and adduction; either esotropia or exotropia may result. Poor abduction should not result in an exotropia.
21. **a.** Clinical trials for botulinum toxin show that it is effective in small-angle strabismus, postoperative residual strabismus, and acute paralytic strabismus. It can be used in active thyroid eye disease and as a supplement to rectus muscle recessions for large-angle strabismus. Botulinum toxin injection is not effective as single treatment for large-angle strabismus, A or V patterns, or chronic paralytic strabismus.
22. **a.** The extreme overcorrection suggests that there is a slipped medial rectus muscle. This would be evident by limited adduction in either eye. In this patient, absence of stereopsis would be expected but not helpful diagnostically. Vertical measurements would not be helpful, nor would findings from a slit-lamp examination.
23. **d.** Dysraphism represents a failure to fuse. Agenesis represents developmental failure, as is found in anophthalmia, whereas hypoplasia is due to developmental arrest. Developmental excess such as that seen with distichiasis is the cause of hyperplasia.
24. **b.** When vision loss is due to pathology posterior to the lateral geniculate nucleus, nystagmus is generally not present. Retinal dystrophy and congenital cataracts represent pathology anterior to the lateral geniculate nucleus and are associated with nystagmus.
25. **a.** Blepharophimosis-ptosis-epicanthus inversus syndrome may occur as a sporadic or autosomal dominant disorder. It consists of blepharophimosis, congenital ptosis, telecanthus, and epicanthus inversus. Surgery may be necessary early in life.
26. **c.** Crouzon and Apert syndromes appear similar clinically. However, Apert syndrome is associated with an extreme amount of syndactyly. Both syndromes are associated with hypertelorism, proptosis, and inferior scleral show.
27. **c.** Patients with craniosynostoses can have various types of horizontal strabismus. V-pattern exotropia is the most common type.
28. **c.** Ophthalmia neonatorum caused by *Neisseria gonorrhoeae* typically presents in the first 3–4 days of life. In severe cases, it is associated with marked chemosis, significant discharge, and a risk of corneal perforation. Chemical conjunctivitis is a mild, self-limited inflammation occurring in the first 24 hours of life due to instillation of silver nitrate. Herpes simplex virus conjunctivitis usually presents later, often in the second week of life. Chlamydial



conjunctivitis usually occurs around 1 week of age and is associated with minimal to moderate discharge and possible pseudomembrane formation.

29. **a.** Stevens-Johnson syndrome is a hypersensitivity reaction that affects the skin and mucous membranes. Early ocular involvement may range from conjunctivitis to corneal perforation. Symblepharon, corneal vascularization, and eyelid anomalies such as entropion or ectropion are later sequelae.
30. **b.** Horner syndrome caused by a lesion along the oculosympathetic pathway must be ruled out in a patient with new-onset ptosis. Affected patients have anisocoria that is greater in dim light and ptosis secondary to paralysis of the Müller muscle. In a child, new-onset Horner syndrome can be idiopathic or secondary to trauma, surgery, or neuroblastoma along the sympathetic chain in the chest. Cataract would not cause acute ptosis. Anisometropic amblyopia and astigmatism would not occur with an acute ptosis; they can develop secondary to long-standing, significant ptosis.
31. **a.** Apraclonidine reverses the anisocoria. It causes dilation of the affected pupil but has no effect on the normal pupil. It will dilate the affected pupil regardless of whether the lesion is pre- or postganglionic.
32. **a.** The basic pathophysiologic defect in primary congenital glaucoma is decreased aqueous outflow due to abnormal development of neural crest–derived tissue of the anterior chamber angle. Although abnormalities of the Descemet membrane, iris, and optic nerve all occur in primary congenital glaucoma, they are secondary effects from the increased intraocular pressure that occurs in this disease.
33. **b.** The anterior chamber angle of a normal infant eye differs from that of an adult's eye in the following ways: The Schwalbe line is less distinct. The trabecular meshwork is less highly pigmented. Because the uveal meshwork is more translucent than in adult eyes, it is more difficult to see through and therefore the junction between the scleral spur and ciliary body is less easily seen.
34. **a.** Posterior subcapsular cataracts (PSCs) are less common in children than in adults. They are usually acquired and often bilateral. PSCs tend to progress. Causes of PSC include corticosteroid use, uveitis, retinal abnormalities, radiation exposure, and trauma. PSCs can be seen in association with neurofibromatosis type 2. A review of the medication list is most likely to be useful in determining the etiology. In the absence of signs of uveitis, a musculoskeletal examination is less likely to be beneficial. As most PSCs are acquired, family history is also less likely to be helpful.
35. **a.** The most common identifiable etiology of anterior uveitis in a child is juvenile idiopathic arthritis, which occurs in 15%–47% of cases. Antinuclear antibody positivity is typically present in these children; rheumatoid factor is typically negative. Although juvenile spondyloarthropathies are associated with anterior uveitis in children, they are less common; thus, HLA-B27 testing is less likely to be beneficial. Infectious etiologies of anterior uveitis in children are less common, and results of serologic testing are less likely to reveal the etiology in these patients.
36. **a.** Tubulointerstitial nephritis and uveitis (TINU) syndrome is kidney disease associated with chronic or recurrent anterior uveitis in adolescents; the median age at onset is 15 years. The renal disease is characterized by low-grade fever, fatigue, pallor, and weight loss. The uveitis is usually bilateral and may occur before, simultaneously with, or after the renal disease. TINU nephritis is not commonly associated with cataract, serous retinal detachment, or papilledema.

37. **a.** Type 1 ROP is zone I, any stage with plus disease; zone I, stage 3 ROP without plus disease; or zone II, stage 2 or 3 ROP with plus disease. Type 2 ROP is zone I, stage 1 or 2 without plus disease; or zone II, stage 3 ROP without plus disease.
38. **b.** Leber congenital amaurosis is a group of hereditary retinal dystrophies that affect both the rod and cone photoreceptors. It is characterized by severe vision loss in infancy, nystagmus, and poorly reactive pupils. An electroretinogram is typically used to make the diagnosis, showing extinguished waveforms. A-scan ultrasonography, fluorescein angiography, and optical coherence tomography would not be helpful in making the diagnosis.
39. **c.** Retinoblastoma occurs when both copies of *RB1*, a tumor suppressor gene, have mutations. Approximately 60% of retinoblastoma cases arise from somatic nonhereditary mutations of both alleles of *RB1* in a retinal cell. These mutations generally result in unifocal and unilateral tumors. In the other 40% of cases, a germline mutation in 1 of the 2 alleles of *RB1* either is inherited from an affected parent (10% of all retinoblastoma cases) or occurs spontaneously in 1 of the gametes.
40. **c.** Optic nerve hypoplasia is characterized by a decreased number of optic nerve axons. It is associated with absence of the septum pellucidum, not a bifid septum pellucidum; with agenesis of the corpus callosum; and with pituitary gland abnormalities. MRI reveals an ectopic posterior pituitary bright spot at the upper infundibulum. This finding is associated with pituitary hormone deficiencies. Optic nerve hypoplasia is not associated with an empty sella on MRI. Chiasmal gliomas are associated with optic nerve elevation, not optic nerve hypoplasia.
41. **d.** Morning glory disc anomaly typically appears as a funnel-shaped excavation of the posterior fundus that incorporates an enlarged optic disc with elevated surrounding retinal pigment epithelium and an increased number of blood vessels looping at the edges of the disc. It is sometimes associated with a basal encephalocele, PHACE (posterior fossa malformations, hemangiomas, arterial lesions, cardiac and eye anomalies) syndrome, and moyamoya disease. Optic nerve hypoplasia is associated with pituitary abnormalities and septo-optic dysplasia, not basal encephalocele. An optic nerve pit is not associated with encephalocele or other midline defects. Optic nerve coloboma is associated with CHARGE (coloboma, heart defects, choanal atresia, mental retardation, genitourinary abnormalities, and ear abnormalities) syndrome, but not encephalocele.
42. **a.** Although trauma is the most common cause of hyphema in children, spontaneous hyphemas can occur in juvenile xanthogranuloma of the iris, retinoblastoma, leukemia, and blood dyscrasias. Iris nevus, iris capillary hemangioma, and iris cyst are not associated with spontaneous hyphema formation.
43. **d.** The most common ocular manifestation of abusive head trauma (AHT), present in approximately 80% of cases, is retinal hemorrhage. These hemorrhages can be seen in all layers of the retina and may be unilateral or bilateral. They are found most commonly in the posterior pole but can also be present peripherally. The anterior segment and ocular adnexa are often normal. Hyphema, corneal abrasion, and subconjunctival hemorrhages are less commonly seen in AHT.
44. **a.** Ocular albinism is associated with iris transillumination, foveal aplasia or hypoplasia, and decreased retinal pigmentation. Both human and animal studies have shown an abnormally high number of crossed fibers in the optic chiasm, which precludes stereopsis and is associated with strabismus. Optic nerve hypoplasia and morning glory disc are not associated with abnormalities in the crossed fibers of the optic chiasm. Achromatopsia is not typically associated with optic nerve abnormalities.



# Index

(*f*=figure; *t*=table)

- AAO. *See* American Academy of Ophthalmology  
AAP. *See* American Academy of Pediatrics  
Abatacept, 322  
ABCA4 gene, 339  
Abducens nerve  
  extraocular muscle innervation by, 19  
  palsy of  
    description of, 95–97, 96*f*, 140  
    in Möbius syndrome, 135  
Abduction  
  definition of, 33  
  lateral rectus muscle, 35*f*  
Ab interno trabeculectomy, 287  
Ablepharon, 193  
Ablepharon-macrostomia syndrome, 193  
Abnormal head position (AHP), in torticollis, 82  
Abusive head trauma (AHT), 381–384, 382–383*f*  
AC. *See* Accommodative convergence  
AC/A ratio. *See* Accommodative convergence/  
  accommodation (AC/A) ratio  
Accidental trauma, 375–381, 377–378*f*, 380*f*  
Accommodation  
  dynamic retinoscopy measurements of, 9  
  hypoaccommodation, 9  
Accommodative amplitude, 188  
Accommodative convergence (AC), 39, 59  
Accommodative convergence/accommodation (AC/A)  
  ratio  
  definition of, 71  
  description of, 39  
  high  
    in accommodative esotropia, 90–92  
    bifocal glasses for, 102  
    in intermittent exotropia, 100  
  measurement of, 71  
  response, 71  
  stimulus, 71  
Accommodative esodeviations  
  cycloplegic examinations for, 11  
  surgical treatment of, 102  
Accommodative esotropia  
  amblyopia associated with, 91  
  definition of, 90  
  description of, 57  
  evaluation of, 91  
  high AC/A ratio, 90–92  
  management of, 91–92  
  nonrefractive, 90  
  partially, 90–92  
  pathogenesis of, 90–91  
  refractive, 90–92  
  types of, 86*t*, 90–91  
Acetazolamide, for idiopathic intracranial hypertension,  
  371  
Acetylcholine receptor antibodies, 142  
Achromatopsia, 337–338  
Acid burns, 376  
Acne rosacea, 244  
Acoustic neuromas, 397  
Acquired nonaccommodative esotropia  
  basic, 93  
  consecutive esotropia, 95  
  cyclic esotropia, 93  
  description of, 92  
  divergence insufficiency, 94  
  near reflex spasm, 94  
  sensory esotropia, 93–94  
  types of, 86*t*  
Acquired strabismus, 16  
ACTA2 gene, 268  
Active force generation test, 73  
Active pulley hypothesis, 28  
Acute lymphoblastic leukemia, 413  
Acute paralytic strabismus, 175  
Acute respiratory distress, 230  
Acyclovir, for herpes zoster, 243  
Adalimumab, 322  
ADAMTS4 gene, 268  
ADAMTS10 gene, 309  
ADAMTSL4 gene, 268  
Adduction  
  definition of, 33  
  overdepression in  
    causes of, 17, 116*t*, 116–118  
    description of, 17  
    pattern strabismus and, 107, 108*f*, 109  
    superior oblique muscle overaction as cause of,  
      118, 118*f*, 137  
  overelevation in  
    causes of, 17, 116*t*, 116–118  
    description of, 17  
    inferior oblique muscle overaction as cause of,  
      117*f*, 117–118  
    pattern strabismus and, 107, 108*f*, 109  
  underdepression in, 17  
  undererelevation in, 17  
Adenovirus  
  conjunctivitis caused by, 241–242  
  keratitis caused by, 269  
  pharyngoconjunctival fever caused by, 242  
Adherence syndrome, 172  
Adipose tissue, in orbit, 25  
Adjustable sutures, in extraocular muscle surgery,  
  165  
Adnexa  
  abnormalities of, in craniosynostosis, 209  
  in cryptophthalmos, 191  
  description of, 181  
Adolescents, bacterial conjunctivitis in, 240*f*, 240–241  
 $\alpha_2$ -Adrenergic agonists, 289*t*, 290  
Adult inclusion conjunctivitis, 241  
Advancement  
  definition of, 164*t*  
  of inferior oblique muscle, 166  
  of plica semilunaris, 171  
  of thickened Tenon capsule too close to limbus, 171

- ADVIRC. *See* Autosomal dominant vitreoretinopathopathy
- Aedes aegypti*, 413
- Afferent pupillary defects, in amblyopia, 56
- Afterimage test, 51, 79, 79*f*
- Agensis
- corpus callosum, 361
  - definition of, 183*t*
- Age-related distance esotropia, 94
- Aggressive posterior retinopathy of prematurity (AP-ROP), 326, 327*t*, 330*f*, 333
- Agonist, 33
- AHP. *See* abnormal head position
- AHT. *See* Abusive head trauma
- Aicardi syndrome, 338–339, 339*f*
- Alagille syndrome, 255
- Albinism
- definition of, 406
  - diagnosis of, 406–408
  - iris transillumination associated with, 265, 406, 407*f*
  - treatment of, 408
  - types of, 408*t*
- Alexander's law, 147
- Alignment, ocular. *See* Ocular alignment
- Alkali burns, 376
- Allen figures, 7
- Allergic conjunctivitis, 246*f*, 246–248
- Allergic reactions, 170, 171*f*
- Allergic shiners, 246
- Allergy, ocular, 246*f*, 246–249, 247*t*, 248*t*
- Alport syndrome, 391
- Alström syndrome, 391
- Alternate cover test
- description of, 65–66, 66*f*
  - exodeviation evaluations, 100
  - prism, 65–66, 66*f*
- Alternating fixation, 16
- Alternating heterotropia, 64
- Alternating suppression, 49
- Amaurosis, Leber congenital, 335–336, 337*f*
- Amblyopia
- in accommodative esotropia, 91
  - afferent pupillary defects in, 56
  - anisometropic
    - clinical features of, 54–55
    - critical period for, 45
    - occlusion therapy for, 58
    - strabismus amblyopia versus, 54–55
  - cataracts as cause of
    - congenital, 55
    - removal of, 57
  - causes of, 45–46
  - classification of, 54–56
  - corneal opacities as cause of, 262
  - crowding phenomenon associated with, 56
  - definition of, 5, 53
  - detection of, 56
  - diagnosis of, 56–57
  - epidemiology of, 53
  - evaluation of, 56–57
  - extraocular muscle surgery in, 160
  - fixation preference testing, 56–57
  - grating acuity associated with, 54, 56–57
  - infantile esotropia and, 87–89
  - isoametropic, 55
  - meridional, 46
  - monofixation syndrome and, 52
  - occlusion therapy for, 58, 96, 102
  - optical defocus caused by, 45
  - pathophysiology of, 53–54
  - post-cataract surgery management of, 304
  - prevalence of, 53
  - recurrence of, 61
  - refractive, 54–55
  - reverse, 55–56, 59–60
  - screening for, 56
  - severity assessments, 56–57
  - strabismic
    - anisometropic amblyopia versus, 54–55
    - clinical features of, 54
    - critical period for, 45
    - development of, 46–47
    - eccentric fixation in, 54
    - grating acuity associated with, 54, 56
    - occlusion therapy for, 58
    - pathophysiology of, 54
    - visual acuity in, 54
    - with third nerve palsy, 138
    - trauma as cause of, 375
  - treatment of
    - atropine sulfate, 59
    - binocular, 59
    - cataract removal, 57
    - challenges associated with, 59–61
    - complications of, 59–61
    - cycloplegics, 59
    - lack of adherence to, 60
    - occlusion therapy, 58, 96
    - optical, 58–59
    - pharmacologic, 58–59
    - plus lenses, 59
    - recurrence of, 61
    - refractive correction, 57–58
    - strabismus secondary to, 59–60
    - termination of, 61
    - unresponsiveness to, 60–61
  - unresponsiveness of, to treatment, 60–61
  - vision development and, 53
  - vision loss associated with, 53, 56
  - visual acuity assessments in, 56
  - visual deficits caused by, 53–54
  - visual deprivation
    - causes of, 55
    - congenital cataracts as cause of, 55
    - congenital nevocellular nevi as cause of, 200
    - corneal blood staining as cause of, 379
    - critical period for, 53
    - reverse amblyopia, 55–56
- Amblyoscope, major, 70, 70*f*
- Amblyoscope testing
- description of, 51
  - sensory adaptation assessments using, 79–80
- American Academy of Ophthalmology (AAO) Initiative in Vision Rehabilitation, 189
- retinopathy of prematurity screening guidelines, 329
- vision rehabilitation guidelines from, 189

- American Academy of Pediatrics (AAP)  
 retinopathy of prematurity screening guidelines, 329  
 uveitis screening in juvenile idiopathic arthritis, 314
- American Association for Pediatric Ophthalmology and Strabismus retinopathy of prematurity screening guidelines, 329
- Anderson procedure, for nystagmus, 155
- Anesthesia  
 for extraocular muscle surgery, 174–175  
 general, 174  
 peribulbar, 174  
 retrobulbar, 174
- Aneurysmal bone cyst, 222
- Angiofibromas, facial, 397
- Angiotensin-converting enzyme, 319
- Angle kappa  
 definition of, 67  
 negative, 67, 68*f*  
 pictorial representation of, 68*f*  
 positive, 67, 68*f*
- Angle surgery, in Sturge-Weber syndrome, 402
- Aniridia, 266*f*, 266–267, 285
- Anisocoria, 275
- Anisometropia  
 abnormal visual experience caused by, 44  
 anterior polar cataracts associated with, 295
- Anisometropic amblyopia  
 clinical features of, 54–55  
 critical period for, 45  
 epibulbar dermoids as cause of, 256  
 occlusion therapy for, 58  
 strabismus amblyopia versus, 54–55
- Ankyloblepharon, 193–194, 194*f*
- Ankyloblepharon–ectodermal dysplasia–clefing syndrome. *See* Hay-Wells syndrome
- Ankyloblepharon filiforme adnatum, 193–194, 194*f*
- Annular ring, 182
- Annulus of Zinn  
 horizontal rectus muscles from, 20  
 inferior rectus muscle from, 20  
 superior oblique muscle from, 20  
 superior rectus muscle from, 20  
 vertical rectus muscles from, 20
- Anomalous binocular vision, 50
- Anomalous retinal correspondence (ARC)  
 afterimage test for, 79*f*  
 definition of, 50  
 diplopia and visual confusion eliminated with, 49*f*  
 eccentric fixation versus, 51  
 harmonious, 76  
 Maddox rod testing in, 68  
 major amblyoscope for, 70  
 red-glass test findings in, 76*f*  
 after strabismus surgery, 50  
 testing for, 50–51  
 unharmonious, 76
- Anophthalmia, 209, 210*f*, 263
- Antagonist  
 contralateral, inhibitional palsy of, 120–121, 121*f*  
 definition of, 33
- Anterior capsule, 302
- Anterior chamber  
 growth and development of, 181  
 paracentesis, 414
- Anterior chamber angle crowding, retinopathy of prematurity as risk factor for, 334
- Anterior ciliary artery, 23
- Anterior lens opacities, 295
- Anterior polar cataracts (APCs), 55, 295, 295*f*
- Anterior segment. *See also* Cornea; Iris  
 blood supply to  
 description of, 172  
 extraocular muscle blood supply and, 30  
 disorders of  
 characteristics of, 320*t*  
 cornea. *See* Corneal disorders  
 description of, 253  
 globe anomalies, 263  
 iris anomalies, 264–267, 264–267*f*  
 pupil abnormalities, 267–268, 268*f*  
 examination of  
 in children, 10, 187  
 in nystagmus evaluations, 154  
 inflammation of, in uveitis, 320  
 ischemia of, 172–173, 173*f*  
 in primary congenital glaucoma, 282, 282*f*  
 tumors of, 271–274
- Anterior uveitis  
 description of, 312  
 differential diagnosis of, 312*t*  
 idiopathic causes of, 316  
 juvenile idiopathic arthritis as cause of, 312–315, 313–314*t*, 314*f*, 322  
 juvenile spondyloarthropathies as cause of, 315, 315*t*  
 Kawasaki disease as cause of, 316  
 laboratory tests for, 321*t*  
 screening for, 314–315  
 trauma as cause of, 316  
 tubulointerstitial nephritis and uveitis syndrome as cause of, 316
- Antibiotics  
 blepharitis treated with, 245  
 congenital nasolacrimal duct obstruction treated with, 231–232, 234  
 corneal abrasion treated with, 376
- Anti-elevation syndrome, 168–169
- Antihistamines, for ocular allergies, 247*t*
- Anti-inflammatory drugs, for ocular allergies, 247*t*
- Antimetabolites, for uveitis, 322
- Anti-VEGF agents, for retinopathy of prematurity, 333
- A-pattern strabismus  
 clinical features of, 109  
 clinically significant, 109  
 definition of, 107  
 etiology of, 107–109, 108*f*  
 exotropia, 108*f*, 112  
 in exotropia, 109  
 heterotropy as cause of, 28  
 horizontal rectus muscle transposition for, 112  
 identification of, 109  
 intorsion as cause of, 107, 110  
 medial rectus muscle displacement for, 110, 111*f*  
 palpebral fissure slanting associated with, 196

- superior oblique muscle overaction associated with, 107
- superior oblique tenotomy for, 112
- surgical treatment of, 112, 112*t*
- APCs. *See* Anterior polar cataracts
- Apert syndrome, 206–207, 207*f*, 209*f*
- Aphakia
  - congenital, 305
  - post–cataract surgery management of, 304
- Aphakic glaucoma, 285
- Apoptosis, retinal ganglion cell, 44
- Apraclonidine, 275, 289*t*, 290
- AP-ROP. *See* Aggressive posterior retinopathy of prematurity
- Arachnodactyly, 307, 308*f*
- ARC. *See* Anomalous retinal correspondence
- Arc of contact, 32
- ARS. *See* Axenfeld-Rieger syndrome
- Arteriohepatic dysplasia, 255
- Arteriovenous malformations, orbital, 222
- Arthritis
  - enteropathic, 315*t*
  - enthesitis-related, 315*t*
  - juvenile idiopathic, 312–315, 313–314*t*, 314*f*, 322
  - reactive, 315*t*
- Association, 183
- Asthenopia, 101
- Astrocytic hamartomas, 353, 397, 399*f*
- Ataxia-telangiectasia, 393*t*, 403*f*, 403*t*, 403–404
- Atopic keratoconjunctivitis, 249
- ATP7B* gene, 270
- Atropine sulfate
  - amblyopia treated with, 59
  - in children, 11, 11*t*
- Autosomal dominant vitreoretinopathies (ADVIRC), 341
- Axenfeld-Rieger syndrome (ARS)
  - description of, 255, 255*f*, 264–265, 264–265*f*, 268*f*
  - glaucoma associated with, 285
- Axial length, in primary congenital glaucoma, 283
- Azathioprine, for uveitis, 322
- Bacterial conjunctivitis, 240*f*, 240–241
- Bacterial orbital cellulitis, 213, 214*f*
- Bagolini striated lenses
  - description of, 51–52
  - sensory adaptation testing using, 77*f*, 77–78
- Bailey-Lovie chart, 8
- Balloon dacryoplasty, 234–235, 235*f*
- Band keratopathy, 322
- Bardet-Biedl syndrome, 391, 391*f*
- Bartonella henselae*, 240–241, 369
- Base-out prisms
  - convergence insufficiency and, 103
  - convergence paralysis and, 106
  - dissociated vertical deviation and, 129
  - nystagmus treated with, 155
- Basic acquired nonaccommodative esotropia, 93
- Basic intermittent exotropia, 101
- Bathopsis, 43
- Batten, Spielmeier-Vogt disease, 389*t*
- Bear tracks, 349
- BEAT-ROP. *See* Bevacizumab Eliminates the Angiogenic Threat of Retinopathy of Prematurity
- Behr optic atrophy, 368
- Bell phenomenon, 126*f*, 197
- Bergmeister papilla, 298, 366
- Best disease, 340–342, 342*f*
- BEST1* gene, 340–342
- Bestrophinopathies, 341
- Beta-blockers. *See*  $\beta$ -Blockers
- Betaxolol, 288, 289*t*
- Bevacizumab
  - Coats disease treated with, 360
  - retinopathy of prematurity treated with, 333
- Bevacizumab Eliminates the Angiogenic Threat of Retinopathy of Prematurity (BEAT-ROP), 333
- Bicanalicular intubation, 234
- Bielschowsky head-tilt test, 75, 122
- Bifocals, for high AC/A ratio accommodative esotropia, 91–92
- Binocular function
  - field of single binocular vision assessment, 81–82, 82*f*
  - prism adaptation test, 82
- Binocular fusion, 60, 91
- Binocular treatment, for amblyopia, 59
- Binocular vision
  - abnormalities of
    - diplopia, 47–48
    - visual confusion, 47, 47*f*
  - anomalous, 50
  - in cyclic strabismus, 93
  - development of, 43
  - fusion, 42–43
  - monocular visual deprivation effects on, 45
  - Panum's area of single, 42, 42*f*, 48
  - retinal correspondence, 41–42
  - single, 81–82, 82*f*
- Blau syndrome, 319
- Blepharitis, 244–245, 244–245*f*
- Blepharophimosis-ptosis-epicanthus inversus syndrome (BPES), 197–198, 198*f*
- Blindness
  - congenital stationary night, spasmus nutans syndrome associated with, 151
  - from retinopathy of prematurity, 335
- Blinking, excessive, 201–202
- Blink reflex, 185
- $\beta$ -Blockers
  - childhood glaucoma treated with, 288, 289*t*
  - hemangioma treated with, 220
- Block-Sulzberger syndrome. *See* Incontinentia pigmenti
- Blowout fracture, 379
- Blue-cone monochromatism, 337–338
- Blue dyschromatopsia, 368
- Blunt injury/trauma, 378–379
- Bone cyst, aneurysmal, 222
- Bone growth disorders, nonsynostotic, 212
- Botryoid tumors, 217
- Botulinum toxin injections
  - adverse effects of, 176
  - chemodenervation using, 175–176
  - complications of, 176
  - in extraocular muscle symmetric surgery, 160
  - in eyelids, 146
  - indications for, 175–176
  - infantile esotropia treated with, 89

- mechanism of action, 175
- near reflex spasm treated with, 94
- pharmacology of, 175
- results of, 175–176
- strabismus treated with, 175
- techniques for, 175–176
- Bourneville disease. *See* Tuberous sclerosis
- BPES. *See* Blepharophimosis–ptosis–epicanthus inversus syndrome
- Brachycephaly, 205
- Brain lesions, of tuberous sclerosis, 398*f*
- Branchial arch syndromes, 210–211, 210–211*f*
- Brimonidine, 289*t*, 290
- Brittle cornea syndrome, 262
- Brown syndrome
  - acquired, 136
  - clinical features of, 136–137, 137*f*
  - congenital, 136
  - as congenital cranial dysinnervation disorder, 131
  - description of, 117
  - diagnosis of, 137
  - forced duction test for, 137
  - iatrogenic, 168
  - inferior oblique muscle palsy versus, 124, 125*t*, 137
  - management of, 137–138
  - primary position hypotropia with, 137
  - rheumatoid arthritis and, 137
  - superior oblique muscle weakening for, 138, 166
  - surgical treatment of, 138
- Brown tumor of bone, 222
- Brückner test
  - in amblyopia screening, 56
  - description of, 9, 67–68
- Brushfield spots, 272
- Buphthalmos, 283
- Burkitt lymphoma, 218
- Burns, 376
  
- Café-au-lait spots, 392, 395*f*
- Calvarium, 203
- Canaliculus, 378
- Capsulorrhexis, 302
- Carbonic anhydrase inhibitors, 289*t*, 290
- Cardiff Acuity Test, 9, 187
- Cardinal positions of gaze, 31, 32*f*, 35, 64
- Cataracts
  - acquired, 293
  - amblyopia caused by, 55, 57
  - anterior polar, 55, 295, 295*f*
  - autosomal dominant transmission of, 294
  - bilateral, 293, 294*t*
  - congenital, 293
  - corticosteroids as cause of, 321
  - etiology of, 294, 294–295*t*
  - evaluation of, 299*t*, 299–301
  - general features of, 293–294
  - history-taking for, 299*t*, 300
  - infantile, 293
  - laboratory workup for, 299*t*, 301
  - lamellar, 55, 296, 296*f*
  - morphology of, 294–299, 295*t*, 295–298*f*
  - next-generation gene sequencing for, 301
  - nuclear
    - infantile, 295, 296*f*
    - in rubella, 410
  - ocular anomalies associated with, 293, 294*t*
  - ocular examination of, 300
  - peripheral vacuolar, 298
  - persistent fetal vasculature associated with, 298*f*, 298–299
  - polar, 55
  - posterior capsular, 387*f*
  - posterior lenticonus associated with, 296–297, 297*f*
  - posterior subcapsular, 297
  - removal of, 57
  - retinoscopy evaluations, 299
  - in rubella, 410
  - sectoral, 297–298
  - slit-lamp examination of, 300
  - types of, 293
  - visual deprivation amblyopia caused by, 55
  - visual function affected by, 300
  - workup for, 299*t*, 301
- Cataract surgery
  - amblyopia managed with, 57, 304
  - anterior capsule management in, 302
  - aphakia management after, 304
  - in children, 301–305
  - complications of, 304–305
  - corneal decompensation after, 304
  - endophthalmitis after, 305
  - glaucoma after, 304
  - glaucoma secondary to, 285
  - intraocular lens placement
    - description of, 301
    - issues associated with, 303–304
    - lensectomy with, 302–304
    - posterior capsulectomy/vitrectomy with, 303
    - power calculations, 303
  - lensectomy, 302
  - macular edema after, 304–305
  - medical therapy after, 304
  - postoperative care after, 304
  - primary posterior capsulectomy, 303
  - retinal detachment after, 304
  - strabismus after, 304
  - timing of, 301
  - in uveitis patients, 323
- Cat-scratch disease, 240, 369
- Cavernous sinus thrombosis, 214
- CCDDs. *See* Congenital cranial dysinnervation disorders
- CCT. *See* Central corneal thickness
- CDCR. *See* Conjunctivodacryocystorhinostomy
- Cecocentral scotomata, 368
- Cellulitis
  - orbital, 213–215, 214*f*
  - preseptal, 170, 212–214
- Central, Steady, and Maintained (CSM) method, 6
- Central corneal thickness (CCT), 181, 281
- Central corneal transparency disorders, 257–258*t*, 257–263, 258*f*
- Central fusion, 42
- Central fusion disruption, 48, 79, 104
- Central posterior keratoconus, 259



- Central scotomata, 368
- Central suppression, 48
- Central suppression scotoma, 4Δ base-out prism test for, 79
- Central vestibular instability nystagmus, 149
- Cerebral hemisphere abnormalities, 361
- Cerebral palsy, hypoaccommodation in, 9
- Cerebral visual impairment (CVI), 186–187
- Cerebrotendinous xanthomatosis, 387*f*
- CFEOM. *See* Congenital fibrosis of the extraocular muscles
- Chalazia, 198–199, 199*f*, 244
- CHARGE syndrome, 364
- Chavasse theory, of infantile esotropia, 87
- CHED. *See* Congenital hereditary endothelial dystrophy
- Chédiak-Higashi syndrome, 407
- Chemical conjunctivitis, 239
- Chemical injury, 376
- Chemotherapy, for retinoblastoma, 356–357
- Cherry-red spot myoclonus syndrome, 388*t*, 390
- Chiasmal glioma, 396
- Chickenpox, 242–243
- Child abuse
  - abusive head trauma, 381–384, 382–383*f*
  - ocular trauma caused by, 381, 384
- Childhood glaucoma
  - algorithm for, 279*f*
  - aphakic, 285
  - classification of, 277, 278*t*, 279*f*
  - corticosteroids as cause of, 284
  - definition of, 277
  - follow-up of, 290–291
  - genetics of, 277–278
  - juvenile open-angle glaucoma, 278, 284
  - primary congenital glaucoma
    - anterior segment findings in, 282, 282*f*
    - axial length in, 283
    - central corneal thickness in, 281
    - clinical manifestations of, 279–280, 280*f*
    - corneal edema in, 279–280
    - corneal findings in, 280*f*, 280–281
    - definition of, 278
    - diagnostic examination for, 280–283, 282–283*f*
    - differential diagnosis of, 281*t*
    - genetics of, 277–278
    - gonioscopy for, 282, 282*f*
    - goniotomy for, 285, 286*f*
    - incidence of, 278
    - natural history of, 283–284
    - optical coherence tomography of, 283
    - optic nerve findings in, 282–283, 283*f*
    - pathophysiology of, 278
    - surgical treatment of, 285–287, 286*f*
    - tonometry in, 281–282
    - trabeculotomy, 286*f*, 286–287
  - prognosis for, 290–291
  - secondary
    - acquired condition, 284
    - after cataract surgery, 285
    - classification of, 278*t*
    - nonacquired conditions associated with, 284*t*
  - treatment of
    - β-blockers, 288, 289*t*
    - cyclocryotherapy, 287
    - description of, 285
    - endoscopic photocoagulation, 287–288, 288*f*
    - goniotomy for, 285, 286*f*
    - medical/medications, 288–290, 289*t*
    - surgery, 285–288, 286*f*, 288*f*
    - trabeculotomy, 286*f*, 286–287
    - tube shunt implantation surgery, 287
    - vision loss caused by, 290
- Children
  - amblyopia in, 5
  - bacterial conjunctivitis in, 240*f*, 240–241
  - cataracts in. *See* Cataracts
  - cataract surgery in, 301–305
  - confrontation visual field testing in, 4, 10
  - conjunctivitis in, 240*f*, 240–241. *See also*
    - Conjunctivitis
  - difficult, eye examination in, 5
  - eyedrop administration in, 11–12
  - eye examination in
    - anterior segment examination, 10
    - Brückner test, 9
    - communication during, 4
    - cycloplegic refraction, 10–12
    - difficult child, 5
    - distance fixation targets, 3, 4*f*
    - dynamic retinoscopy, 9
    - fundus, 12
    - general considerations and strategies for, 3–5
    - intraocular pressure measurement, 10
    - 1 toy, 1 look rule, 3, 4*f*
    - in outpatient setting, 3, 4*f*
    - practitioner positioning during, 4
    - pupil testing, 10
    - red reflex, 9
    - “safe” environment for, 4
    - slit-lamp examination, 4–5
    - tonometry, 10
    - visual acuity assessment. *See* Children, visual acuity assessment
    - visual field testing, 10
    - vocabulary during, 4
  - history-taking in, 3–5
  - intraocular pressure in
    - measurement of, 181
    - normal level of, 282
  - iris heterochromia in, 274, 274*t*, 274*f*
  - nasolacrimal duct obstruction in, 235
  - nystagmus in, 147–157. *See also* Nystagmus
  - optic neuritis in, 369, 369*f*
  - orbital inflammation in, 215–216
  - preverbal, visual acuity assessment in, 8–9, 154
  - ptosis in, 198
  - slit-lamp examination in, 4–5
  - uveitis in. *See* Uveitis
  - vision rehabilitation in, 188–189, 189*t*
  - visual acuity assessment in
    - age-specific approaches, 5
    - alternative methods, 8–9
    - Central, Steady, and Maintained method of, 6
    - eye charts for, 6*t*, 6–8, 7*f*
    - fixation and following behavior for, 5
    - fixation behavior, 5–6

- HOTV test, 6, 6*t*, 7*f*  
 induced tropia test, 6  
 in nystagmus, 8  
 occluders used in, 8  
 optotypes for, 6*t*, 6–8, 7*f*  
 preferential looking, 5, 8–9, 9*f*, 182, 300  
 preverbal children, 8–9, 154  
 sequence of, 8  
 symbol charts for, 7  
 visual evoked potential for, 9, 182, 300  
 visual impairment in, 186–187
- Chlamydia trachomatis*  
 conjunctivitis caused by, 238–239, 239*f*, 241  
 trachoma caused by, 241
- Chloroma, 218
- Chorioretinal coloboma, 364
- Chorioretinal lacunae, 338, 339*f*
- Chorioretinitis  
 syphilitic, 412  
*Toxoplasma*, 409, 410*f*
- Choristoma, 223, 256
- Choristomatous tumors, 225–226
- Choroidal hemangioma, 401
- Choroidal lesions, 349–350
- Choroidal neovascular membranes (CNVMs), 342, 343*f*
- Choroidal nevi, 349
- Choroidal osteoma, 349
- CHRD1* gene, 254
- Chromosomal abnormalities, 385, 386*t*
- Chronic progressive external ophthalmoplegia (CPEO), 141–142, 143*t*
- CHRPE. *See* Congenital hypertrophy of the retinal pigment epithelium
- CHSD. *See* Congenital hereditary stromal dystrophy
- CI. *See* Convergence insufficiency
- Ciancia syndrome, 88, 95
- Cigarette burns, 376
- Ciliary artery, 23
- Ciliary body tumors, 273*f*, 273–274
- Ciliary muscle, 20
- Ciliary spasm, 94
- Ciliochoroidal effusion, 284
- Ciliopathies, 336, 391–392, 391–392*f*
- Clindamycin, for toxoplasmosis, 410
- CMN. *See* Congenital motor nystagmus
- CMV. *See* Cytomegalovirus
- CNLDO. *See* Congenital nasolacrimal duct obstruction
- CNVMs. *See* Choroidal neovascular membranes
- Coats disease  
 clinical findings of, 358, 359*f*  
 diagnosis of, 359–360  
 differential diagnosis of, 360  
 fluorescein angiography findings, 359, 359*f*  
 gender predilection of, 358  
 retinoblastoma versus, 352–353, 360  
 treatment of, 360
- Co-contractive retraction with jaw–eyelid synkinesis syndrome. *See* Marcus Gunn jaw-winking syndrome
- Cogan syndrome, 269
- COL2A1* gene, 345
- COL18A1* gene, 346–347
- COL25A1* gene, 133
- Coloboma  
 chorioretinal, 364  
 as craniofacial malformation, 209  
 eyelid, 193, 193*f*  
 globe, 263  
 inferonasal disc, 365*f*  
 iris, 266, 266*f*  
 lens, 305*f*, 305–306  
 optic nerve, 364–365*f*
- Colobomatous cyst, 224
- Combined hamartoma of the retina and retinal pigment epithelium, 350
- Comitant deviations  
 definition of, 16  
 in infantile esotropia, 88
- Complete achromatopsia, 337–338
- Cone–rod dystrophy, in Stargardt disease, 340
- Cones, foveal density of, 44
- Confrontation visual field testing, 4, 10
- Congenital aphakia, 305
- Congenital cranial dysinnervation disorders (CCDDs)  
 Brown syndrome as, 131  
 congenital fibrosis of the extraocular muscles, 134–135  
 definition of, 131  
 Duane retraction syndrome. *See* Duane retraction syndrome  
 Möbius syndrome, 97, 135–136, 136*f*
- Congenital esotropia, 86*t*  
 amblyopia associated with, 87–89  
 botulinum toxin injections for, 89  
 Chavasse theory of, 87  
 Ciancia syndrome, 88, 95  
 clinical features of, 87–88  
 cross-fixation associated with, 87–88, 88*f*  
 cyclopegic refraction for, 88  
 definition of, 87  
 evaluation of, 87–88  
 management of, 88–89  
 medial rectus muscle recession for, 89  
 mental illness and, 87  
 ocular alignment in, 88–89  
 pathogenesis of, 87  
 prematurity as risk factor for, 87  
 smooth-pursuit asymmetry associated with, 88  
 surgical treatment of, 89  
 Worth “sensory” concept of, 87
- Congenital Esotropia Observational Study, 89
- Congenital fibrosis of the extraocular muscles (CFEOM), 134–135
- Congenital glaucoma  
 corneal opacities associated with, 257*t*, 260, 261*f*  
 primary. *See* Primary congenital glaucoma
- Congenital hereditary endothelial dystrophy (CHED), 257*t*, 258*f*, 258–259
- Congenital hereditary stromal dystrophy (CHSD), 257*t*, 259
- Congenital hypertrophy of the retinal pigment epithelium (CHRPE), 349, 349*f*
- Congenital iris ectropion syndrome, 267
- Congenital lacrimal fistula, 228, 229*f*
- Congenital miosis, 267–268
- Congenital motor nystagmus (CMN), 148–149, 149*t*, 153–154

- Congenital mydriasis, 268
- Congenital nasolacrimal duct obstruction (CNLDO)
- antibiotics for, 231–232, 234
  - balloon dacryoplasty for, 234–235, 235*f*
  - bilateral, 232*f*
  - clinical features of, 230, 232*f*
  - complex, 230, 233–234
  - description of, 227, 230
  - examination of, 230
  - infantile glaucoma versus, 230
  - intubation for, 234–235
  - massage for, 231–232
  - nasolacrimal probing for, 232–235, 233*f*
  - nonsurgical management of, 231–232
  - prevalence of, 230
  - recurrence of, 234
  - simple, 230, 231*f*
  - spontaneous resolution of, 231
  - stents for, 234–235
  - surgical management of, 232–233
  - tearing caused by, 230
- Congenital nevocellular nevi, 200–201, 201*f*
- Congenital sensory nystagmus, 149, 150*t*, 154
- Congenital stationary night blindness (CSNB)
- electroretinography findings, 338
  - spasmus nutans syndrome associated with, 151
- Congenital strabismus, 16
- Congenital superior oblique palsy, 69
- Congenital syphilis, 269, 412–413
- Congenital tarsal kink, 194–195
- Conjugate horizontal gaze, 182
- Conjunctival disorders
- epithelial inclusion cysts, 250
  - nevi, 250, 250*f*
  - ocular melanocytosis, 250–251, 251*f*
  - papillomas, 250
  - Stevens-Johnson syndrome, 251–252, 252*f*
  - toxic epidermal necrolysis, 251–252
- Conjunctival hyperemia, 237, 238*t*
- Conjunctival scarring, 146
- Conjunctival telangiectasia, 303*f*, 403
- Conjunctivitis
- adenoviral, 241–242
  - adult inclusion, 241
  - allergic, 246*f*, 246–248
  - bacterial, 240*f*, 240–241
  - blepharitis as cause of, 244–245, 244–245*f*
  - chemical, 239
  - Chlamydia trachomatis* as cause of, 238–239, 239*f*
  - Epstein-Barr virus as cause of, 243
  - follicular, 241, 243
  - herpes simplex virus as cause of, 239, 242
  - infectious, 237–243
  - ligneous, 249
  - molluscum contagiosum as cause of, 243, 244
  - neonatal inclusion, 238
  - ophthalmia neonatorum
    - Chlamydia trachomatis* as cause of, 238–239, 239*f*
    - definition of, 237
    - epidemiology of, 237
    - etiology of, 237
    - herpes simplex virus as cause of, 239
    - Neisseria gonorrhoeae* as cause of, 238*f*, 238–239
    - Neisseria meningitidis* as cause of, 238
    - prevalence of, 237
    - prophylaxis for, 239
    - perennial allergic, 246–248
    - seasonal allergic, 246*f*, 246–248
    - signs and symptoms of, 237
    - varicella-zoster virus as cause of, 242–243
    - viral, 241–243, 243–244*f*
- Conjunctivodacryocystorhinostomy (CDCR), 227–228
- Conjunctivoplasty, 172
- Connective tissue tumors, 222
- Consecutive esotropia, 95
- Consecutive exotropia, 16, 104
- Consecutive strabismus, 16
- Constant exotropia, 103–105, 104*f*
- Constant suppression, 49
- Contact lenses
- amblyopia treated with, 304
  - lens dislocation treated with, 310
- Contour interaction bars, 7*f*, 8
- Contour stereopsis, 81
- Contralateral antagonist, inhibitional palsy of, 120–121, 121*f*
- Convergence
- accommodative, 39, 59
  - assessment of, 71
  - definition of, 39
  - fusional, 39, 43, 72
  - near point of, 71
  - proximal (instrument), 39
  - symmetric, 41
  - tonic, 40
  - voluntary, 40
- Convergence insufficiency (CI), 103
- Convergence paralysis, 105–106
- Convergence-retraction nystagmus, 152–153
- Convergence spasm, 94
- Corectopia, 268
- Cornea
- abrasion of, 376
  - clouding of, 179, 385, 387*f*
  - delle of, 172, 172*f*
  - diameter of, 179, 281
  - epithelial defects of, 376
  - foreign body in, 376
  - growth and development of, 181
  - keratitis-related scarring of, 245*f*
  - penetrating injury to, 376
  - in primary congenital glaucoma, 280*f*, 280–281
  - shield ulcer of, 248, 249*f*
  - thermal injury to, 376
  - tumors of, 271
- Corneal decompensation, after cataract surgery, 304
- Corneal disorders
- acquired, 269
  - central corneal transparency, 257–258*t*, 257–263, 258*f*
  - congenital hereditary endothelial dystrophy, 257*t*
  - congenital hereditary stromal dystrophy, 257*t*, 259
  - cornea plana, 255, 255*f*
  - in cystinosis, 270, 387*f*
  - dermolipoma, 256–257
  - diffuse corneal transparency, 257–258*t*, 257–263, 258*f*
  - epibulbar dermoid, 256, 256*f*, 257*t*

- in Fabry disease, 270, 388*t*
- in familial dysautonomia, 270
- forceps injury, 257*t*
- infections, 257*t*
- keratitis, 269
- keratoconus, 254
- keratoglobus, 254
- keratoplasty for, 262–263
- megalocornea, 253*f*, 253–254
- microcornea, 254, 254*f*
- in mucopolysaccharidoses, 257*t*, 270, 385, 387*f*, 388*t*
- peripheral corneal transparency, 255–256*f*, 255–257
- posterior corneal defect, 257*t*
- posterior embryotoxon, 255, 255*f*
- in Schnyder corneal dystrophy, 270, 387*f*
- sclerocornea, 257*t*
- size- or shape-related, 253–254, 253–254*f*
- systemic conditions that cause, 269–271
- treatment of, 262–263
- in tyrosinemia type II, 270
- ulcers, 248, 249*f*, 262–263
- in Waardenburg syndrome, 270
- in Wilson disease, 270
- Corneal edema
  - acute, 254
  - in primary congenital glaucoma, 279–280
- Corneal exposure, 207
- Corneal haze, 270
- Corneal light reflex tests
  - Hirschberg test, 67, 68*f*
  - Krimsky test, 67, 68*f*, 104*f*
  - ocular alignment assessments using, 67–68, 68*f*
- Corneal opacities
  - congenital hereditary endothelial dystrophy as cause of, 257*t*, 258*f*, 258–259
  - congenital hereditary stromal dystrophy as cause of, 259
  - differential diagnosis of, 257*t*
  - infantile glaucoma as cause of, 257*t*, 260, 261*f*
  - Peters anomaly, 259, 260*f*
  - posterior corneal depression, 259
  - primary, 258*t*
  - sclerocornea, 260, 261*f*
  - secondary, 258*t*
  - STUMPED mnemonic for, 257*t*, 257–258
  - total, 260, 261*f*
- Cornea plana, 255, 255*f*
- Corneoscleral lacerations, 377
- Coronary artery aneurysm, 316
- Corpus callosum agenesis, 361
- Cortical inattention, 186
- Cortical visual impairment, 186
- Corticosteroids
  - cataracts caused by, 321
  - glaucoma caused by, 321
  - glaucoma secondary to, 284
  - intraocular implants, 321
  - ocular allergies treated with, 247*t*, 248
  - optic neuritis treated with, 369
  - risks associated with long-term use of, 321
  - sub-Tenon injections of, 320
  - Thygeson superficial punctate keratitis treated with, 269
  - toxoplasmosis treated with, 409–410
  - uveitis treated with, 320–321
  - vernal keratoconjunctivitis treated with, 249
- Cover tests
  - alternate, 65–66, 66*f*
  - cover-uncover test, 64, 65*f*
  - ocular alignment assessments using, 64–67, 65–66*f*
- Cover-uncover test, 64, 65*f*
- CPEO. *See* Chronic progressive external ophthalmoplegia
- Cranial nerve III. *See* Oculomotor nerve
- Cranial nerve IV. *See* Trochlear nerve
- Cranial nerve VI. *See* Abducens nerve
- Cranial nerve VII palsy, 136*f*
- Cranial sutures, 203–204, 204*f*
- Craniofacial malformations
  - anophthalmia, 209, 210*f*
  - Apert syndrome, 206–207, 207*f*, 209*f*
  - branchial arch syndromes, 210–211, 210–211*f*
  - Crouzon syndrome, 206, 206*f*
  - fetal alcohol syndrome, 211–212, 212*f*
  - nonsynostotic, 209–212
  - Pfeiffer syndrome, 207
  - Pierre Robin sequence, 211
  - Saethre-Chatzen syndrome, 207, 208*f*
  - Treacher Collins syndrome, 211, 211*f*
- Craniometaphyseal dysplasia, 212
- Craniosynostosis
  - anatomy of, 203–204
  - Apert syndrome, 206–207, 207*f*, 209*f*
  - brachycephaly, 205
  - complications of
    - corneal exposure, 207
    - globe luxation, 207–208
    - ocular adnexal abnormalities, 209
    - optic nerve abnormalities, 208–209
    - proptosis, 207
    - strabismus, 208
  - Crouzon syndrome, 206, 206*f*
  - definition of, 203
  - dolichocephaly, 205
  - etiology of, 205–206
  - Kleeblattschädel, 205
  - Pfeiffer syndrome, 207
  - plagiocephaly, 204–205
  - Saethre-Chatzen syndrome, 207, 208*f*
  - scaphocephaly, 205
  - syndromes associated with, 206–207
- Cri-du-chat syndrome, 386*t*
- Crossed diplopia, 75
- Cross-fixation, in infantile esotropia, 87–88, 88*f*
- Crouzon syndrome, 206, 206*f*
- Crowding phenomenon
  - in amblyopia, 56
  - definition of, 54
- Cryotherapy for Retinopathy of Prematurity (CRYO-ROP), 326, 331
- Cryptophthalmos, 191, 193, 193*f*
- CSM method. *See* Central, Steady, and Maintained (CSM) method
- CSNB. *See* Congenital stationary night blindness
- CTNS gene, 270
- Cupping, of optic disc, 187, 402*f*
- CVI. *See* Cerebral visual impairment

- Cyclic esotropia, 93  
 Cyclic strabismus, 93  
 Cyclocryotherapy, 287  
 Cyclodeviations  
   double Maddox rod test for, 69, 69f  
   fusion affected by, 79  
 Cyclopentolate hydrochloride, 11, 11t  
 Cycloplegic agents  
   adverse effects of, 11–12  
   amblyopia treated with, 59  
   in children, 11–12  
   corneal abrasion treated with, 376  
   near reflex spasm treated with, 94  
 Cycloplegic refraction  
   agents used in, 11–12  
   in amblyopia treatment, 57  
   in children, 10–12  
   in infantile esotropia, 88  
   technique of, 11  
 Cyclosporine, for vernal keratoconjunctivitis, 249  
 Cyclovergence, fusional, 40  
 Cyclovertical strabismus, 162  
*CYP1B1* gene, 259, 277  
 Cyst(s)  
   colobomatous, 224  
   dermoid, 223–224, 223–224f  
   epithelial inclusion, 250  
   iris, 272f, 272–273  
   microphthalmia with, 224, 225f  
 Cystathionine  $\beta$ -synthase, 308  
 Cysteamine, 270  
 Cystinosis, 270, 387f, 389t  
 Cytomegalovirus (CMV), 411, 411f
- Dacryocystitis, acute, 229  
 Dacryocystocele, 213, 225, 228–230, 229f  
 Dacryocystorhinostomy, for nasolacrimal duct obstruction, 236  
 DALK. *See* Deep anterior lamellar keratoplasty  
 Dark adaptation, in congenital stationary night blindness, 338  
 Decussation, optic nerve, 43  
 Deep anterior lamellar keratoplasty (DALK), 263, 270  
 Deformational plagiocephaly, 204–205  
 Delayed visual maturation (DVM), 186–187  
 Deletion 4p, 386t  
 Deletion 5p, 386t  
 Deletion 18p, 386t  
 Deletion 18q, 386t  
 Delle, 172, 172f  
 Demarcation line, in retinopathy of prematurity, 328f  
*Demodex*, 245  
 Demodicosis, 245  
 de Morsier syndrome. *See* Septo-optic dysplasia  
 Denervation and extirpation, 164t  
 Deorsumduction, 33  
 Deorsumversion, 37  
 Depression of eye, 33, 38  
 Deprivation amblyopia, 55, 379  
 Depth perception, stereopsis versus, 43  
 Dermoid cysts, 223–224, 223–224f  
 Dermolipomas, 210, 256–257  
 Derry disease, 389t
- Descemet membrane  
   breaks in  
     description of, 260  
     in primary congenital glaucoma, 280, 280f  
     traumatic, 262, 262f  
   tears in, 254  
 Desmoid tumors, 222  
 Deviations  
   comitant  
     definition of, 16  
     in infantile esotropia, 88  
   esodeviations  
     accommodative, 90. *See also* Accommodative esotropia  
     definition of, 85  
     in divergence insufficiency, 94  
     epidemiology of, 85  
     extraocular muscle surgery amounts for, 160, 160t  
     risk factors for, 85  
     types of, 86t  
   exodeviations  
     control of, 100  
     convergence insufficiency, 103  
     definition of, 99  
     exotropia. *See* Exotropia  
     extraocular muscle surgery amounts for, 160, 161t  
     latent, 99  
     manifest, 99  
     risk factors for, 99  
   incomitant, 16  
   primary, 38  
   secondary, 39  
   strabismic amblyopia and, 46–47  
   terminology used to describe, 15–16  
   variations in size of, 16  
   vertical. *See* Vertical deviations  
 Dexamethasone, for toxoplasmosis, 410  
 Dextrocydversion, 38  
 Dextroversion, 37  
 DHD. *See* Dissociated horizontal deviation  
 Diabetes mellitus, 408–409  
 Diabetic retinopathy, 408–409  
 Diagnostic positions of gaze, 64  
 DIDMOAD syndrome, 408–409  
 Diffuse corneal transparency disorders, 257–258t, 257–263, 258f  
 Diffuse infiltrative retinoblastoma, 353  
 Diffuse neonatal hemangiomatosis, 220  
 Diffuse soft-tissue histiocytosis, 219  
 Diffuse superficial keratitis, 242  
 Diktyoma. *See* Medulloepithelioma  
 Diplopia  
   crossed, 75  
   description of, 47–48  
   esotropia and, 102  
   extraocular muscle surgery as cause of, 168  
   heteronymous, 75  
   homonymous, 75  
   in orbital floor fractures, 127–128  
   paradoxical, 50, 50f  
   physiologic, 48  
   postoperative, 168  
   press-on prisms for, 96

- prisms for, 72
- red-glass test for, 75
- in sixth nerve palsy, 96
- suppression of, 49*f*
- testing for, 75
- in third nerve palsy, 139
- in thyroid eye disease, 140–141
- uncrossed, 75
- Dislocated lens
  - conditions associated with, 306*t*
  - description of, 306
  - ectopia lentis et pupillae, 267–268, 307, 307*f*
  - in homocystinuria, 308–309
  - illustration of, 306*f*
  - inborn errors of metabolism and, 306
  - iridodonesis with, 306
  - isolated/simple ectopia lentis, 307
  - in Marfan syndrome, 307–308, 308*f*
  - refractive error caused by, 310
  - in sulfite oxidase deficiency, 310
  - treatment of, 310
    - in Weill-Marchesani syndrome, 309
- Dissociated horizontal deviation (DHD), 17, 105, 129
- Dissociated strabismus complex (DSC), 17, 105*f*, 129
- Dissociated torsional deviation (DTD), 17, 129
- Dissociated vertical deviation (DVD)
  - age at onset, 129
  - clinical features of, 129, 129*f*
  - definition of, 129
  - description of, 17, 105, 111, 115–116
  - hypertropia and, 115
  - inferior oblique anterior transposition for, 166
  - inferior oblique muscle overaction versus, 129–130
  - management of, 130
- Distance–near incomitance, 162
- Distichiasis, 195, 195*f*
- Divergence
  - fusional, 40, 72
  - fusional vertical, 40
  - synergistic, 133
- Divergence insufficiency, 94
- Divergent strabismus, 15
- Dolichocephaly, 205
- Doll's head maneuver, 88
- Dominant optic atrophy, 367–368, 368*f*
- Donder's law, 31
- Dorsal midbrain syndrome, 105
- Double-elevator palsy. *See* Monocular elevation deficiency
- Double Maddox rod test, 69, 69*f*, 120
- Double ring sign, 361, 362*f*
- Double vision. *See* Diplopia
- Downbeat nystagmus, 152
- Downgaze, 38
- Down syndrome
  - hypoaccommodation in, 9
  - idiopathic intracranial hypertension associated with, 372
  - ocular findings in, 386*t*
  - pseudopapilledema associated with, 372
- Downward-slanting palpebral fissure
  - description of, 196
  - pattern strabismus and, 107, 108*f*
  - syndromes with, 196
- Dragged-fovea diplopia syndrome, 145
- Drusen, optic disc, 373*f*, 373–374
- DSC. *See* Dissociated strabismus complex
- DTD. *See* Dissociated torsional deviation
- Duane retraction syndrome
  - bilateral, 132
  - classification of, 132–133
  - clinical features of, 132–133
  - definition of, 131
  - electromyographic studies of, 132
  - esotropic, 95–97, 132*f*, 133
  - exotropic, 105, 132, 132*f*
  - genetics of, 132
  - globe retraction in, 134
  - incomitant hypertropia associated with, 125
  - management of, 133–134
  - “ocular splits,” 133
  - overdepression in adduction caused by, 117
  - overelevation in adduction caused by, 117
  - prevalence of, 133
  - surgical treatment of, 133–134
  - synergistic divergence associated with, 133
  - systemic/syndromic defects associated with, 131
  - type 1, 132*f*, 132–133
  - type 2, 132, 132*f*
  - type 3, 132–134, 133*f*
- Ductions
  - description of, 33, 83
  - forced. *See* Forced duction testing
  - in infantile esotropia, 37
- DVD. *See* Dissociated vertical deviation
- DVM. *See* Delayed visual maturation
- Dynamic retinoscopy
  - accommodation measurements using, 9
  - in children, 9
- Dysconjugate nystagmus, 151–152
- Dyscoria, 267
- Dysraphism, 183*t*
- Dystopia canthorum, 191, 192*f*
- Early Treatment for Retinopathy of Prematurity (ETROP), 326, 331*t*, 332
- Early Treatment of Diabetic Retinopathy Study (ETDRS) chart, 8
- Eccentric fixation
  - anomalous retinal correspondence versus, 51
  - definition of, 54
  - in strabismic amblyopia, 54
- ECP. *See* Endoscopic photocoagulation
- Ectodermal dysplasia, 194
- Ectopia lentis, isolated/simple, 307
- Ectopia lentis et pupillae, 267–268, 307, 307*f*
- Ectopic lacrimal gland, 226
- Ectopic tissue masses, 223–225*f*, 223–226
- Ectropion, congenital
  - of eyelid, 194
  - of iris, 267
- Ectropion uveae, 267
- Edwards syndrome, 386*t*
- “Egg yolk” stage, of Best disease, 341, 342*f*
- EKC. *See* Epidermic keratoconjunctivitis
- Electromyography
  - definition of, 32
  - motor units on, 32

- Electro-oculography (EOG)  
 Best disease findings, 342  
 hereditary retinal disease evaluations using, 335
- Electroretinography (ERG)  
 achromatopsia findings, 337  
 congenital stationary night blindness findings, 338  
 hereditary retinal disease evaluations, 335  
 Knobloch syndrome findings, 347  
 Leber congenital amaurosis findings, 336
- Elevation of eye, 33, 37–38
- Emmetropization, 180
- Empirical horopter, 41, 42*f*
- Encephalocele, 225
- Encephalofacial angiomatosis. *See* Sturge-Weber syndrome
- Endophthalmitis, after cataract surgery, 305
- Endophytic retinoblastoma, 352, 352*f*
- Endoscopic photocoagulation (ECP), for childhood glaucomas, 287–288, 288*f*
- Enteropathic arthritis, 315*t*
- Enthesitis-related arthritis, 315*t*
- Entropion, congenital, 194
- EOG. *See* Electro-oculography
- Eosinophilic granuloma, 219, 219*f*
- Epiblepharon, 194, 195*f*
- Epibulbar dermoid, 256, 256*f*, 257*t*
- Epibulbar limbal dermoids, 210
- Epicanthus, 196, 196*f*
- Epicanthus inversus, 196
- Epicanthus palpebralis, 196, 196*f*
- Epicanthus supraciliaris, 196
- Epicanthus tarsalis, 196, 196*f*
- Epidemic keratoconjunctivitis (EKC), 213, 242
- Epidermoid cysts, 223
- Epiretinal membrane, retinal distortion caused by, 145
- Epithelial cyst, 170–171
- Epithelial inclusion cysts, 250
- Epstein-Barr virus, 243
- ERG. *See* Electroretinography
- Erythromycin, for chlamydial infections, 239
- Eso- (prefix), 15
- Esodeviations  
 accommodative, 90. *See also* Accommodative esotropia  
 definition of, 85  
 in divergence insufficiency, 94  
 epidemiology of, 85  
 extraocular muscle surgery amounts for, 160, 160*t*  
 risk factors for, 85  
 types of, 86*t*
- Esotropia  
 accommodative  
 amblyopia associated with, 91  
 definition of, 90  
 description of, 57  
 evaluation of, 91  
 high AC/A ratio, 90–92  
 management of, 91–92  
 nonrefractive, 90  
 partially, 90–92  
 pathogenesis of, 90–91  
 refractive, 90–92  
 types of, 86*t*, 90–91
- acquired nonaccommodative  
 basic, 93  
 consecutive esotropia, 95  
 cyclic esotropia, 93  
 description of, 92  
 divergence insufficiency, 94  
 near reflex spasm, 94  
 sensory esotropia, 93–94  
 types of, 86*t*
- age-related distance, 94
- botulinum toxin injection for, 97
- congenital. *See* Esotropia, infantile  
 in congenital fibrosis of the extraocular muscles (CFEOM), 135
- consecutive, 16, 95
- cyclic, 93
- diplopia and, 102
- in Duane retraction syndrome, 95–97, 132*f*, 133
- exotropia following, 16
- high myopia and, 97, 143–144
- Hirschberg test for, 67, 68*f*
- incomitant, 95–97, 96*f*
- infantile, 86*t*  
 amblyopia associated with, 87–89  
 botulinum toxin injections for, 89  
 Chavasse theory of, 87  
 Ciancia syndrome, 88, 95  
 clinical features of, 87–88  
 cross-fixation associated with, 87–88, 88*f*  
 cyclopegic refraction for, 88  
 definition of, 87  
 evaluation of, 87–88  
 management of, 88–89  
 medial rectus muscle recession for, 89  
 mental illness and, 87  
 ocular alignment in, 88–89  
 pathogenesis of, 87  
 prematurity as risk factor for, 87  
 smooth-pursuit asymmetry associated with, 88  
 surgical treatment of, 89  
 V-pattern strabismus associated with, 109, 112*t*  
 Worth “sensory” concept of, 87
- large-angle, 87
- negative angle kappa and, 67, 68*f*
- nystagmus and, 86*t*, 95
- nystagmus blockage syndrome as cause of, 155
- postoperative, 102
- postsurgical, 102
- postsurgical consecutive, 95
- prevalence of, 85
- primary inferior oblique muscle overaction associated with, 117
- pseudoesotropia, 85–87, 86*f*
- risk factors for, 85
- sensory, 93–94
- small-angle, 102
- spontaneous consecutive, 95
- strabismus surgery for, 91
- types of, 86*t*
- V-pattern strabismus associated with, 109, 112*t*
- Etanercept, 322
- ETDRS chart, 8

- ETROP. *See* Early Treatment for Retinopathy of Prematurity
- Euryblepharon, 195
- Ewing sarcoma, 218
- Examination, ocular
- anterior segment examination, 10
  - Brückner test, 9
  - communication during, 4
  - cycloplegic refraction, 10–12
  - difficult child, 5
  - distance fixation targets, 3, 4*f*
  - dynamic retinoscopy, 9
  - fundus, 12
  - general considerations and strategies for, 3–5
  - intraocular pressure measurement, 10
  - 1 toy, 1 look rule, 3, 4*f*
  - in outpatient setting, 3, 4*f*
  - practitioner positioning during, 4
  - pupil testing, 10
  - red reflex, 9
  - “safe” environment for, 4
  - slit-lamp examination, 4–5
  - tonometry, 10
  - visual acuity assessment. *See* Children, visual acuity assessment
  - visual field testing, 10
  - vocabulary during, 4
- Excessive blinking, 201–202
- Exyclo- (prefix), 16
- Excycloduction, 33
- Exo- (prefix), 15
- Exodeviations
- control of, 100
  - convergence insufficiency, 103
  - definition of, 99
  - exotropia. *See* Exotropia
  - extraocular muscle surgery amounts for, 160, 161*t*
  - latent, 99
  - manifest, 99
  - risk factors for, 99
- Exophoria
- definition of, 99
  - diagnosis of, 99
- Exophytic retinoblastoma, 352–353, 353*f*
- Exorbitism, 203
- Exotropia
- alternate cover test for, 66*f*, 99
  - angle kappa and, 67
  - A-pattern strabismus associated with, 109
  - consecutive, 16, 104
  - constant, 103–105, 104*f*
  - in craniosynostosis, 208
  - in Duane retraction syndrome, 105, 132, 132*f*
  - esotropia after, 95
  - high myopia and, 143–144
  - hypertropias associated with, 100
  - infantile, 103–104, 104*f*
  - intermittent
    - age at onset, 99
    - basic, 101
    - characteristics of, 99–100
    - control of, 100
    - course of, 99
- dissociated horizontal deviation and, 105
  - evaluation of, 100–101
  - nonsurgical management of, 101–102
  - normal retinal correspondence in, 99
  - occlusion therapy for, 102
  - patch test for, 101
  - postoperative alignment, 102
  - prisms for, 102
  - recurrence of, 103
  - refractive errors in, 101
  - surgical treatment of, 102–103
  - tenacious proximal fusion in, 71
  - treatment of, 101–103
- Krimsky test, 67, 68*f*, 104*f*
- large-angle, 116
- neuromuscular abnormalities as cause of, 105
- postsurgical, 104
- primary inferior oblique muscle overaction associated with, 117
- pseudoexotropia, 99
- risk factors for, 99
- sensory, 104
- V-pattern strabismus with, 108*f*, 112
- Extorsion
- definition of, 33
  - V-pattern strabismus caused by, 107, 110
- Extraconal fat pads, 28
- Extraocular muscles. *See also specific muscle*
- action of
    - description of, 31–32
    - gaze position and, 34–37, 35–37*f*
    - primary, 34
    - secondary, 34
    - tertiary, 34  - arc of contact, 32
  - arterial system of, 23
  - blood supply of, 23–24, 30
  - congenital fibrosis of, 134–135
  - course of, 19–22
  - fascial relationships of, 25–28, 26–27*f*
  - fiber structure in, 24
  - fibrosis of
    - congenital, 134–135
    - in thyroid eye disease, 140  - global layer of, 24
  - growth and development of, 181–182
  - innervation of, 19–22
  - insertion of, 19–22, 31
  - lost, 162, 169
  - myasthenia gravis effects on, 142
  - ophthalmic artery supply of, 23
  - orbital layer of, 24
  - orbital relationships of, 25–28, 26–27*f*
  - origin of, 19–22
  - pulley system of, 28, 32
  - retrobulbar injection–related damage to, 146
  - slipped, 162, 169, 169*f*
  - structure of, 24, 25*f*
  - 3-step test of, 73–75, 74*f*
  - thyroid eye disease effects, 140
  - venous system of, 23–24
  - yoke muscles, 38



- Extraocular muscle surgery
- adjustable sutures used in, 165
  - in amblyopia, 160
  - anesthesia for, 174–175
  - in awake patients, 165
  - complications of, 168–174
    - adherence syndrome, 172
    - alignment issues, 168
    - allergic reactions, 170, 171*f*
    - anterior segment ischemia, 172–173, 173*f*
    - anti-elevation syndrome, 168–169
    - conjunctival scarring, 171–172, 172*f*
    - delle, 172, 172*f*
    - diplopia, 168
    - epithelial cyst, 170–171
    - eyelid position changes, 173, 173*f*
    - foreign-body granuloma, 170
    - iatrogenic Brown syndrome, 168
    - infections, 170, 170*f*
    - lost muscles, 169
    - orbital cellulitis, 170, 170*f*
    - pulled-in-two syndrome, 169–170
    - pyogenic granuloma, 170, 171*f*
    - refractive changes, 173–174
    - scleral perforation, 170
    - slipped muscles, 169, 169*f*
    - unsatisfactory alignment, 168
  - cyclovertical strabismus, 162
    - distance–near incomitance and, 162
    - for esodeviations, 160, 160*t*
  - esotropia correction with, 159
  - evaluation before, 159
  - for exodeviations, 160, 161*t*
  - exotropia after, 17
  - formulas for, 160–161*t*
  - fornix incision for, 162–163
  - hangback recession, 163
  - horizontal deviations, 161
  - horizontal incomitance and, 161
  - hypertropia treated with, 164–165
  - hypotropia treated with, 164–165
  - incisions for, 162–163
  - incomitance and, 161–162
  - indications for, 159–160
  - limbal incision for, 163
  - malignant hyperthermia secondary to, 174–175
  - monocular horizontal recession–resection procedures, 161
  - nystagmus treated with, 155–157, 156*f*
  - oblique muscles
    - inferior, 164*t*, 165–166
    - tightening procedures, 164*t*, 166–167
    - weakening procedures, 164*t*, 165–166
  - oculocardiac reflex, 174
  - planning of, 160–162
  - posterior fixation, 167
  - postoperative nausea and vomiting secondary to, 174
  - prior surgery and, 162
  - reasons for, 159
  - rectus muscles
    - hypertropia, 164–165
    - hypotropia, 164–165
    - slipped, 169, 169*f*
    - tightening procedures, 163–164, 164*t*
    - weakening procedures, 163, 164*t*
  - stay sutures used in, 167
  - sutures used in
    - adjustable, 165
    - posterior fixation, 167
    - stay, 167
  - symmetric, 160–161*t*
  - techniques for, 164*t*
  - tightening procedures
    - for inferior oblique muscle, 166
    - for oblique muscles, 164*t*, 166–167
    - for rectus muscles, 163–164, 164*t*
    - for superior oblique muscle, 167
  - transposition procedures, 167
  - vertical incomitance and, 161
  - weakening procedures
    - for inferior oblique muscle
      - bilateral, 165
      - indications for, 118
      - for superior oblique muscle palsy, 123, 123*t*
      - surgical procedures for, 164*t*, 165–166
      - for V-pattern strabismus, 111
    - for oblique muscles, 164*t*, 165–166
    - for rectus muscles, 163, 164*t*

## Eye

- congenital anomalies of, 182–183, 183*t*
- dimensions of, 179*t*, 179–180
- growth and development of
  - abnormal, 182–183, 183*t*
  - normal, 179–182
- malformation of, 182–183
- refractive state of, 180*f*, 180–181

## Eye disorders

- atopic keratoconjunctivitis, 249
- blepharitis, 244–245, 244–245*f*
- conjunctivitis. *See* Conjunctivitis
- ligneous conjunctivitis, 249
- ocular allergies, 246*f*, 246–249, 247–248*t*
- ophthalmia neonatorum. *See* Ophthalmia neonatorum
- vernal keratoconjunctivitis, 248–249, 248–249*f*

## Eyedrops

- ocular allergies treated with, 247*t*
- pediatric administration of, 11–12

## Eyelid(s). *See also* Lower eyelid; Upper eyelid

- botulinum toxin injection into, 146
- crease of, 197
- laceration to, 378
- malformations of, 191
- morphologic measurements of, 191, 192*f*
- perforating injury of, 377*f*
- positional changes in, 173, 173*f*
- vertical rectus muscle attachment of, 30*f*

## Eyelid disorders

- ablepharon, 193
- ankyloblepharon, 193–194, 194*f*
- chalazia, 198–199, 199*f*
- coloboma, 193, 193*f*
- congenital, 191–198
- congenital tarsal kink, 194–195
- cryptophthalmos, 191, 193, 193*f*
- distichiasis, 195, 195*f*

- dystopia canthorum, 191, 192*f*  
 ectropion, 194  
 entropion, 194  
 epiblepharon, 194, 195*f*  
 epicanthus, 196, 196*f*  
 epithelial lesions, 200  
 euryblepharon, 195  
 excessive blinking, 201–202  
 hemangiomas, 199  
 hordeola, 198–199  
 infectious, 198–199  
 inflammatory, 198–199  
 Marcus Gunn jaw-winking syndrome, 198  
 neoplasms, 199–200  
 nevi, 200–201, 201*f*  
 noninflammatory, 199–201  
 palpebral fissure slants, 196  
 pilomatrixoma, 200, 200*f*  
 port-wine stain, 199  
 ptosis, 196–198, 197*t*, 198*f*  
 pyogenic granuloma, 199, 199*f*  
 trichotillomania, 201, 201*f*  
 vascular, 199
- Eye movements  
 abnormalities of  
   National Eye Institute classification of, 147  
   nystagmus. *See* Nystagmus  
 active force generation test, 73  
 binocular  
   vergences, 37, 39–40  
   versions, 37–39  
 electromyography of, 32–33  
 forced duction test, 73  
 monocular  
   ductions, 33  
   field of action, 33–34  
   gaze position effects on extraocular muscle action,  
     34–37, 35–37*f*  
   primary action, 34  
   secondary action, 34  
   terminology associated with, 33  
   tertiary action, 34  
 motor units, 32–33  
 optokinetic system of, 40  
 saccadic system of, 40  
 saccadic velocity, 73  
 smooth-pursuit system of, 40  
 supranuclear control systems for, 40  
 vergence system of, 40  
 vestibular-ocular system of, 40
- Fabry disease, 270, 388*t*  
 Facial angiofibromas, 397  
 Facial asymmetry, torticollis and, 82  
 Facultative suppression, 49  
 Fadenoperation, 128, 164*t*  
 FAF. *See* Fundus autofluorescence  
 Familial dysautonomia, 271  
 Familial exudative vitreoretinopathy (FEVR), 347–348,  
   348*f*  
 Familial juvenile systemic granulomatosis, 319  
 Familial oculorenal syndromes, 391–392, 391–392*f*  
 Farkas canthal index, 191
- Fascia, orbital, 27  
 Fascia bulbi, 26  
*FBN1* gene, 307  
 Fells modification of Harada-Ito procedure, 167  
 Fetal alcohol syndrome, 183, 211–212, 212*f*, 361  
 FEVR. *See* Familial exudative vitreoretinopathy  
 Fibrillin-1, 307  
 Fibrin clots, 377  
 Fibroblast growth factor receptor genes, 206  
 Fibrous dysplasia, 222  
 Fistula, congenital lacrimal, 228, 229*f*  
 Fixation  
   alternating, 16  
   amblyopia evaluations, 56–57  
   assessments of, in preverbal children, 300  
   eccentric  
     anomalous retinal correspondence versus, 51  
     definition of, 54  
   maintained, 6  
   monocular, 16  
   near, 64  
   steady, 6  
   uncentral, 6  
   uncentral, unsteady, and unmaintained, 6  
   in visual acuity assessment in children, 5–6  
 Fixation reflex, 300  
 Fleischer rings, 254  
 Flexner-Wintersteiner rosettes, 353  
 Fluorescein angiography  
   Best disease on, 342, 343*f*  
   Coats disease on, 359, 359*f*  
 Fluoroquinolones, for bacterial conjunctivitis, 240  
 Folic acid supplementation, in methotrexate therapy, 322  
 Follicular conjunctivitis, 241, 243  
 Fontanelles, 204*f*  
 Forced duction testing  
   for Brown syndrome, 137  
   for consecutive esotropia, 95  
   description of, 73  
   for orbital floor fractures, 379  
 Foreign body, corneal, 376  
 Foreign-body granuloma, 170  
 Form-vision deprivation amblyopia, 55  
 Fornix incision, 162–163  
 Foster modification, 167  
 4Δ base-out prism test, 78*f*, 78–79  
 Fourth nerve palsy, 140  
 Fovea  
   cone density in, 44  
   development of, 44  
   hypoplasia of, 154, 338, 406  
   retinoschisis, 344  
*FOXC1* gene, 265  
*FOXL2* gene, 197  
 Fractures  
   blowout, 379  
   orbital floor, 127–128, 128*f*, 379–380, 380*f*  
   orbital roof, 380, 380*f*  
*Francisella tularensis*, 240  
 Fraser syndrome, 193  
 Frisby Davis Distance Stereotest, 81  
*FRMD7* gene, 149, 153  
 Frontalis suspension, for eyelid ptosis, 197

- Fucosidosis, 388*t*
- Full-time occlusion  
 amblyopia treated with, 58  
 reverse amblyopia caused by, 60
- Fundus  
 examination of, in children, 12  
 Leber congenital amaurosis findings, 336, 337*f*  
 ocular torticollis findings, 84  
 optic disc drusen evaluations, 374  
 primary congenital glaucoma-related findings, 284
- Fundus autofluorescence (FAF)  
 Best disease on, 343*f*  
 Gardner syndrome on, 350*f*  
 optic disc drusen on, 373*f*, 374  
 Stargardt disease on, 340
- Fundus flavimaculatus, 339
- Fungal orbital cellulitis, 215
- Fusion  
 binocular, 60, 91  
 central, 42  
 in cyclic strabismus, 93  
 definition of, 42  
 motor, 43  
 peripheral, 51–52  
 sensory, 43  
 stereopsis, 43
- Fusional convergence, 39, 43, 72
- Fusional cyclovergence, 40
- Fusional divergence, 40, 72
- Fusional vergences, 72, 72*t*
- Fusional vertical divergence, 40
- Fusion maldevelopment nystagmus syndrome, 83, 88,  
 95, 148, 150–151, 151*f*, 154
- Galactosemia, 389*t*
- Galactosialidosis, 389*t*
- Gangliosidoses, 388–389*t*
- Gardner syndrome, 349, 350*f*
- Gaucher disease, 388*t*
- Gaze  
 cardinal positions of, 31, 32*f*, 35, 64  
 direction of, 147  
 downgaze, 38  
 left, 37  
 positions of, 31  
 cardinal, 31, 32*f*, 35, 64  
 definition of, 64  
 diagnostic, 64  
 extraocular muscle action and, 34–37  
 field of action, 33  
 ocular alignment assessment using, 64  
 primary, 31, 64  
 secondary diagnostic, 31  
 for strabismus, 64  
 tertiary diagnostic, 31  
 for vertical strabismus, 64  
 right, 37  
 upgaze, 37
- General anesthesia, 174
- Gene therapy  
 Leber congenital amaurosis treated with, 337  
 Stargardt disease treated with, 340
- German measles, 410
- Germline mutations, 358
- Glaucoma  
 after cataract surgery, 304  
 childhood. *See* Childhood glaucoma  
 corticosteroids as cause of, 321  
 infantile, 230  
 pediatric. *See* Childhood glaucoma  
 port-wine stain and, 199  
 retinopathy of prematurity as risk factor for,  
 334  
 in Sturge-Weber syndrome, 401–402
- Glaucoma surgery, in uveitis patients, 323
- Global layer, of extraocular muscles, 24, 27
- Globe  
 congenital and developmental anomalies of, 263  
 luxation of, 207–208  
 penetrating injury to, 376  
 retraction of  
 in Duane retraction syndrome, 134  
 in induced convergence-retraction, 153
- Glycoproteinosis, 388*t*
- GM<sub>1</sub> gangliosidoses, 389*t*
- GM<sub>2</sub> gangliosidoses, 389*t*
- Goldenhar syndrome  
 craniofacial malformations associated with, 210*f*,  
 210–211  
 dermolipomas associated with, 256  
 description of, 131  
 epibulbar dermoids associated with, 256, 256*f*
- Goldmann applanation, 281
- Gonioscopy, 282, 282*f*
- Goniotomy  
 primary congenital glaucoma treated with, 285,  
 286*f*  
 in uveitis patients, 323
- GPR143* gene, 407
- Gradient method, for accommodative convergence/  
 accommodation ratio measurement, 71
- Granulocytic sarcoma, 218
- Granuloma  
 foreign-body, 170  
 macular, 317*f*  
 pyogenic, 170, 171*f*  
 unifocal eosinophilic, 219, 219*f*
- Granulomatous arthritis, pediatric, 318
- Grating acuity  
 definition of, 54  
 in strabismic amblyopia, 54  
 testing for, 8, 9*f*, 56–57
- Ground-in prisms, for nystagmus, 155
- Haab striae, 260, 261*f*, 280*f*, 280–281
- Hagberg-Santavuori disease, infantile, 389*t*
- Hangback recession, 163
- Harada-Ito procedure  
 description of, 124  
 Fells modification of, 167
- Harboyan syndrome, 259
- Harmonious anomalous retinal correspondence, 76
- Hay-Wells syndrome, 194
- Head trauma, abusive, 381–384, 382–383*f*
- Heimann-Bielschowsky phenomenon, 152
- Hemangioblastomas, 353, 400, 400*t*

- Hemangioma  
 definition of, 219  
 eyelid, 199  
 orbital, 219–221  
 plaque, 220, 220f  
 propranolol for, 220, 221f  
 systemic disease associated with, 220  
 treatment of, 220–221
- Hemifacial microsomia, 210, 210f
- Hemifacial spasm, 202
- Hemorrhages  
 intralesional, 221, 221f  
 peripapillary, 373  
 retinal  
   in abusive head trauma, 382–383, 382–383f  
   in leukemia, 414  
   subarachnoid, 382  
   subretinal, 373
- Hepatolenticular degeneration. *See* Wilson disease
- Hereditary macular dystrophies  
 Best disease, 340–342, 342f  
 Stargardt disease, 339–340, 340–341f
- Hereditary vitreoretinopathies, familial exudative, 347–348, 348f
- Hering's law of motor correspondence, 38, 115–116, 121
- Hermansky-Pudlak syndrome, 407
- Herpes simplex virus (HSV)  
 conjunctivitis caused by, 239, 242  
 keratitis caused by, 269  
 neonatal, 412  
 ocular manifestations of, 412  
 ophthalmia neonatorum caused by, 239
- Herpes zoster, 243, 243f
- Hess screen, 120
- Heterochromia, pediatric iris, 274, 274t, 274f
- Heteronymous diplopia, 75
- Heterophoria  
 definition of, 15  
 heterotropia versus, 64
- Heterophoria method, for accommodative convergence/accommodation ratio measurement, 71
- Heterotopy, 28
- Heterotropia  
 alternating, 64  
 definition of, 15  
 heterophoria versus, 64  
 in monofixation syndrome, 51
- Hexosaminidase activator deficiency, 389t
- High AC/A ratio  
 in accommodative esotropia, 90–92  
 bifocal glasses for, 102  
 in intermittent exotropia, 100
- High myopia  
 esotropia associated with, 97, 143–144  
 exotropia associated with, 143–144
- Hirschberg test, 67, 68f
- Histiocytosis X. *See* Langerhans cell histiocytosis
- HIV. *See* Human immunodeficiency virus
- Homer Wright rosettes, 353
- Homocystinuria, 308–309, 389t
- Homonymous diplopia, 75
- Homonymous hemianopia, 83
- Hordeola, 198–199
- Horizontal deviations  
 in craniosynostosis, 208  
 dissociated, 17, 105, 105f, 129  
 extraocular muscle surgery for, 161  
 Maddox rod test for, 69
- Horizontal rectus muscles  
 anatomy of, 20, 35f  
 inferior zone of, 24  
 innervation of, 34  
 in pattern strabismus, 109–110  
 primary position of, 35, 35f  
 recession/resection of  
   description of, 139  
   for esodeviations, 160  
   monocular, 161  
   for nystagmus correction, 157  
 superior zone of, 24  
 transposition of, 110, 112
- Horizontal rotations, 31
- Horner syndrome, 274–275, 415f
- Horner-Trantas dot, 248, 249f
- Horopter  
 definition of, 41  
 empirical, 41, 42f
- Horror fusionis, 48
- HOTV test, 6, 6t, 7f
- HSV. *See* Herpes simplex virus
- Human immunodeficiency virus, 348
- Hunter syndrome, 388t
- Hurler syndrome, 270, 388t
- Hutchinson triad, 412
- Hyaloid artery, 366
- Hyper- (prefix), 15
- Hyperchromic heterochromia, 274t
- Hyperemia, conjunctival, 237, 238t
- Hyperopia, 180
- Hyperplasia, 183t
- Hypertelorism, ocular, 191
- Hypertropia  
 dissociated vertical deviation and, 115  
 exotropia associated with, 100  
 extraocular muscle surgery for, 164–165  
 incomitant, 125  
 inferior rectus muscle weakness as cause of, 128  
 rectus muscle surgery for, 164–165  
 superior oblique muscle palsy associated with, 123
- HypHEMA, 378f, 378–379
- Hypo- (prefix), 16
- Hypoaccommodation, 9
- Hypochromic heterochromia, 274t
- Hypoplasia, 183t
- Hypotelorism  
 ocular, 191  
 orbital, 203
- Hypotropia  
 extraocular muscle surgery for, 164–165  
 high myopia associated with, 143–144  
 in monocular elevation deficiency, 126, 126f  
 primary position, with Brown syndrome, 137  
 pseudoptosis associated with, 30  
 rectus muscle surgery for, 164–165

- Iatrogenic Brown syndrome, 168  
 Icare tonometer, 10, 281  
 I-cell disease, 388*t*  
 ICE syndrome. *See* Iridocorneal endothelial (ICE) syndrome  
 ICP. *See* Intracranial pressure  
 ICRB. *See* International Classification of Retinoblastoma  
 ICROP. *See* International Classification of Retinopathy of Prematurity  
 Idiopathic intracranial hypertension (IIH), 370*f*, 370–371  
 IEP. *See* Individualized education plan  
 IGF-I. *See* Insulin-like growth factor I, in retinopathy of prematurity pathophysiology  
 IIH. *See* Idiopathic intracranial hypertension  
*IKBKAP* gene, 271  
 Inborn errors of metabolism  
   lens dislocation and, 306  
   ocular findings in, 385, 387*f*, 388–389*t*, 390*f*  
   prevalence of, 385  
 Incisions  
   fornix, 162–163  
   limbal, 163  
 Inclusion cysts, 250  
 Incomitant deviation, 16  
 Incomitant esotropia, 95–97, 96*f*  
 Incomitant strabismus  
   abnormal head position caused by, 83  
   prism alternate cover test for, 66  
 Incomplete achromatopsia, 337  
 Incontinentia pigmenti, 393*t*, 404*t*, 404–405, 404–405*f*  
 Incyclo- (prefix), 16  
 Incyclo-diplopia, 119  
 Incyclo-duction, 33  
 Individualized Education Plan (IEP), 188  
 Induced convergence-retraction, 152–153  
 Induced tropia test, 6  
 Infant(s). *See also* Newborns  
   abusive head trauma, 381–384, 382–383*f*  
   cataracts in, 293  
   chlamydial infection in, 239  
   cytomegalovirus infection in, 411, 411*f*  
   delayed visual maturation in, 186–187  
   extraocular muscles in, 181–182  
   intraocular pressure in  
     measurement of, 181  
     normal level of, 282  
   retinal hemorrhage in, 382–383, 382–383*f*  
   vision in  
     decreased, 187–188  
     development of, 185  
     impairments in, 186–187  
 Infantile esotropia, 86*t*  
   amblyopia associated with, 87–89  
   botulinum toxin injections for, 89  
   Chavasse theory of, 87  
   Ciancia syndrome, 88, 95  
   clinical features of, 87–88  
   cross-fixation associated with, 87–88, 88*f*  
   cyclopedic refraction for, 88  
   definition of, 87  
   evaluation of, 87–88  
   management of, 88–89  
   medial rectus muscle recession for, 89  
   mental illness and, 87  
   ocular alignment in, 88–89  
   pathogenesis of, 87  
   prematurity as risk factor for, 87  
   smooth-pursuit asymmetry associated with, 88  
   surgical treatment of, 89  
   V-pattern strabismus associated with, 109, 112*t*  
   Worth “sensory” concept of, 87  
 Infantile exotropia, 103–104, 104*f*  
 Infantile glaucoma. *See also* Primary congenital glaucoma  
   corneal opacities associated with, 257*t*, 260, 261*f*  
   description of, 230  
 Infantile Hagberg-Santavuori disease, 389*t*  
 Infantile malignant osteopetrosis, 212  
 Infantile nystagmus syndrome, 83, 148–149, 149*t*, 156*f*, 187, 335  
 Infantile strabismus  
   description of, 16  
   dissociated vertical deviation associated with, 129  
   fusion maldevelopment nystagmus syndrome associated with, 151, 154  
   primary inferior oblique muscle overaction associated with, 117  
 Infection  
   corneal, 257*t*  
   eyelid disorders caused by, 198–199  
   postoperative, 170, 170*f*  
   preseptal cellulitis caused by, 212–213  
 Inferior oblique muscle  
   action of, 34*t*, 38*f*  
   advancement of, 166  
   anatomy of, 19*f*  
   anteriorization/anterior transposition of  
     anti-elevation syndrome caused by, 168  
     description of, 166  
   characteristics of, 21*t*  
   elevator function of, 73  
   field of action for, 33  
   innervation of  
     description of, 19  
     surgical considerations and, 29  
   origin of, 20, 21*t*, 28  
   overaction of  
     bilateral, 117  
     clinical features of, 117–118  
     in craniosynostosis, 208  
     description of, 17  
     latent dissociated vertical deviation versus, 129–130  
     management of, 118  
     overelevation in adduction caused by, 117*f*, 117–118  
     primary, 117  
     secondary, 117  
     in superior oblique muscle paralysis, 166  
   V-pattern strabismus caused by, 107  
   Y-pattern strabismus caused by, 113  
   palsy of  
     Brown syndrome versus, 124, 125*t*, 137  
     clinical features of, 124, 124*f*, 125*t*  
     management of, 124–125  
   pseudo-overaction of, 109, 113  
   pulley system, 28  
   tightening of, 166

- transposition of
  - anterior, 166
- underaction of, 17
- weakening of
  - bilateral, 165
  - indications for, 118
  - for superior oblique muscle palsy, 123, 123*t*
  - surgical procedures for, 164*t*, 165–166
  - for V-pattern strabismus, 111
- Inferior orbital vein, 23
- Inferior rectus muscle
  - action of, 34*t*, 36*f*
  - depressor function of, 73
  - flap tears of, 127–128
  - innervation of, 19
  - lateral border of, 29
  - neurofibrovascular bundle, 29
  - origin of, 20, 22*f*
  - recession/resection of
    - description of, 29
    - eyelid position affected by, 173
  - surgery considerations for, 29
  - weakening of
    - for nystagmus, 156
    - procedures for, 163, 164*t*
- Inferior rectus tendon, 19*f*
- Inferonasal disc coloboma, 365*f*
- Inflammation
  - eyelid disorders associated with, 198–199
  - nonspecific orbital, 215–216, 216*f*
  - orbital, 215–216
  - in uveitis, 320–322
- Infliximab, 322
- Infraduction, 33
- Infraorbital artery, 23
- INO. *See* Internuclear ophthalmoplegia
- Insulin-dependent diabetes mellitus, 408
- Insulin-like growth factor I (IGF-I), in retinopathy of
  - prematurity pathophysiology, 325, 326*t*
- Intermediate uveitis, 312*t*, 316, 316*f*, 320, 321*t*
- Intermittent exotropia
  - age at onset, 99
  - basic, 101
  - characteristics of, 99–100
  - control of, 100
  - course of, 99
  - dissociated horizontal deviation and, 105
  - evaluation of, 100–101
  - nonsurgical management of, 101–102
  - normal retinal correspondence in, 99
  - occlusion therapy for, 102
  - patch test for, 101
  - postoperative alignment, 102
  - prisms for, 102
  - recurrence of, 103
  - refractive errors in, 101
  - surgical treatment of, 102–103
  - tenacious proximal fusion in, 71
  - treatment of, 101–103
- Intermittent strabismus, 182
- Intermuscular septum, 28–29
- International Classification of Retinoblastoma (ICRB),
  - 354, 356*t*
- International Classification of Retinopathy of
  - Prematurity (ICROP), 325, 327*t*
- Internuclear ophthalmoplegia (INO), 144
- Interpupillary distance, 203
- Intorsion
  - A-pattern strabismus caused by, 107, 110
  - definition of, 33
- Intraconal fat pads, 28
- Intraconal orbital abscesses, 214
- Intracranial pressure (ICP), 209, 370
- Intralesional hemorrhage, 221, 221*f*
- Intranasal cysts, 229
- Intraocular lens (IOL)
  - description of, 301
  - issues associated with, 303–304
  - lens dislocation treated with, 310
  - lensectomy with, 302–304
  - posterior capsulectomy/vitreotomy with, 303
  - power calculations, 303
- Intraocular pressure (IOP)
  - in childhood glaucoma, 277, 279, 290–291
  - digital palpation of, 10
  - follow-up for, 290–291
  - in hyphema, 378
  - measurement of, in children
    - description of, 10, 181
    - tonometry for, 281
  - medications for reducing, 288, 289*t*
  - normal level of, 282
- Intrapapillary drusen, 373*f*, 373–374
- Intrauterine/perinatal infections
  - cytomegalovirus, 411, 411*f*
  - description of, 409
  - herpes simplex virus, 412
  - lymphocytic choriomeningitis, 413
  - rubella, 410*f*, 410–411
  - syphilis, 412–413
  - toxoplasmosis, 409–410, 410*f*
  - Zika virus, 413
- Inverse Knapp procedure, 128
- IOL. *See* Intraocular lens
- IOP. *See* Intraocular pressure
- Iridocorneal endothelial (ICE) syndrome, 268
- Iridocyclitis, 412
- Iridodonesis, 306, 308
- Iris
  - abnormalities of, 264–267, 264–267*f*
  - aniridia, 266*f*, 266–267
  - in Axenfeld-Rieger syndrome, 264–265, 264–265*f*
  - Brushfield spots of, 272
  - coloboma of, 266, 266*f*
  - congenital ectropion of, 267
  - cysts of, 272*f*, 272–273
  - in familial dysautonomia, 270
  - growth and development of, 181
  - heterochromia of, 274, 274*t*, 274*f*
  - hypoplasia of, 264–267, 264–267*f*
  - juvenile xanthogranuloma of, 271
  - Lisch nodules of, 271–272, 272*f*, 392, 395*f*, 397
  - mammillations of, 271–272, 272*f*
  - nodules of, 271–272, 272*f*
  - persistent pupillary membrane, 264, 264*f*, 266*f*
  - pigment epithelium cysts, 272, 272*f*

- systemic conditions that affect, 269–270
- transillumination of, 265, 406, 407*f*
- tumors of, 271–273, 272*f*
- in Waardenburg syndrome, 270
- Iris bombé, 285
- Iris-claw lenses, 310
- Iritis, 412
- Isoametropic amblyopia, 55
- Isolated/simple ectopia lentis, 307
  
- Jerk nystagmus, 147
- JIA. *See* Juvenile idiopathic arthritis
- JOAG. *See* Juvenile open-angle glaucoma
- Joubert syndrome, 144, 392, 392*f*
- Juvenile ankylosing spondylitis, 315*t*
- Juvenile fibromatosis, 222
- Juvenile idiopathic arthritis (JIA), 312–315, 313–314*t*, 314*f*, 322
- Juvenile macular degeneration. *See* Stargardt disease
- Juvenile-onset vitelliform macular dystrophy. *See* Best disease
- Juvenile open-angle glaucoma (JOAG), 278, 284
- Juvenile ossifying fibroma, 222
- Juvenile psoriatic arthritis, 315*t*
- Juvenile retinal dystrophy, 390*f*
- Juvenile retinoschisis
  - abusive head trauma as cause of, 383
  - description of, 342–343
  - diagnosis of, 344–345*f*
  - treatment of, 344
- Juvenile spondyloarthropathies, 315, 315*t*
- Juvenile xanthogranuloma, 271
  
- Kabuki syndrome, 195
- Kasabach-Merritt syndrome, 220
- Kawasaki disease, 316
- Kayser-Fleischer ring, 270
- Kearns-Sayre syndrome, 142
- KERA* gene, 255
- Keratitis
  - adenovirus caused by, 269
  - congenital syphilis as cause of, 269
  - corneal involvement, 269
  - corneal scarring caused by, 245*f*
  - diffuse superficial, 242
  - in herpes simplex virus, 412
  - herpes simplex virus as cause of, 269
  - infectious, 269
  - interstitial, 269
  - noninfectious, 269
  - nummular, 243
  - punctate epithelial, 269
  - Thygeson superficial punctate, 269
- Keratoconjunctivitis
  - atopic, 249
  - vernal, 248–249, 248–249*f*
- Keratoconus, 254, 259
- Keratoglobus, 254
- Kerato-irido-lenticular dysgenesis. *See* Peters anomaly
- Keratoplasty, for corneal disorders, 262–263
- Kestenbaum procedure, for nystagmus, 155, 156*f*, 156*t*
- Kleeblattschädel, 205
- Klippel-Trénaunay syndrome (KTS), 406
- Klippel-Trénaunay-Weber syndrome, 199, 251, 394*t*, 406
- Knapp procedure, 127
  - inverse, 128
- Knobloch syndrome, 346*f*, 346–347
- Koeppel-type goniolens, 282, 282*f*
- Krabbe disease, 388*t*
- Krimsky test, 67, 68*f*, 104*f*
- KTS. *See* Klippel-Trénaunay syndrome
  
- Labyrinth, 40
- Lacerations
  - corneoscleral, 377
  - eyelid, 378
  - medial rectus muscle, 146
- Lacrimal artery, 23
- Lacrimal canaliculi atresia, 227–228, 228*f*
- Lacrimal drainage system abnormalities
  - congenital, 227–230
  - congenital lacrimal fistula, 228, 229*f*
  - dacryocystocele, 213, 225, 228–230, 229*f*
  - lacrimal puncta or canaliculi atresia, 227–228, 228*f*
  - obstruction. *See* Nasolacrimal duct obstruction
- Lacrimal fistula, congenital, 228, 229*f*
- Lacrimal fossa, 181
- Lacrimal gland, ectopic, 226
- Lacrimal puncta atresia, 227–228, 228*f*
- $\lambda$ -pattern strabismus
  - clinical features of, 110
  - surgical treatment of, 113
- Lamellar cataracts, 55, 296, 296*f*
- Lamina cribrosa, 364
- Lancaster red-green test, 69, 120
- Langerhans cell histiocytosis (LCH), 218–219
- Lang stereopsis tests, 81
- Large-angle esotropias, 87
- Latent exodeviations, 99
- Latent nystagmus, 88, 95, 129, 150–151, 154
- Latent strabismus, 15
- Latent transforming growth factor beta-binding protein 2 (LTBP2), 306
- Lateral geniculate body
  - description of, 43
  - neurons of, 44
- Lateral rectus muscle
  - abduction of, 35*f*
  - action of, 34*t*, 35*f*
  - anomalous innervation of, 109
  - characteristics of, 21*t*
  - contracture of, 109
  - field of action, 33
  - innervation of, 19
  - lost, 95
  - origin of, 20, 21*t*
  - recession/resection of
    - for Duane retraction syndrome, 134
    - for exodeviations, 160
    - for high myopia, 143
    - for intermittent exotropia, 102
    - for third nerve palsy, 139
    - for X-pattern strabismus, 113
  - slipped, 95
  - superior transposition of, 113

- Lateral rectus tendon, 19*f*  
 LCA. *See* Leber congenital amaurosis  
 LCH. *See* Langerhans cell histiocytosis  
 LCMV. *See* Lymphocytic choriomeningitis virus  
 LEA Grating Acuity Test, 8  
 LEA symbols, 6, 7*f*  
 Leber congenital amaurosis (LCA), 335–336, 337*f*  
 Leber hereditary optic neuropathy, 368  
 Left hypotropia (LHoT), 17  
 Left jerk nystagmus, 148*f*, 150  
 Lens  
   dislocation of  
     conditions associated with, 306*t*  
     description of, 306  
     ectopia lentis et pupillae, 267–268, 307, 307*f*  
     in homocystinuria, 308–309  
     illustration of, 306*f*  
     inborn errors of metabolism and, 306  
     iridodonesis with, 306  
     isolated/simple ectopia lentis, 307  
     in Marfan syndrome, 307–308, 308*f*  
     refractive error caused by, 310  
     in sulfite oxidase deficiency, 310  
     treatment of, 310  
     in Weill-Marchesani syndrome, 309  
   iris-claw, 310  
   luxated, 268, 306, 390*f*  
   subluxation of  
     description of, 268, 306  
     in homocystinuria, 309  
     in Marfan syndrome, 308*f*  
     surgery for, 310  
 Lens disorders  
   coloboma, 305*f*, 305–306  
   congenital aphakia, 305  
   spherophakia, 305  
 Lensectomy, 302, 410  
 Lentiglobus, 296  
 Leptomeningeal vascular malformation, 401*t*  
 Leukemia, 218, 413–414  
 Leukocoria, 299, 351, 351*t*, 351*f*  
 Levator palpebrae superioris muscle  
   action of, 34*t*  
   anatomy of, 19*f*, 26*f*  
   characteristics of, 21*t*, 22  
   innervation of, 19  
   origin of, 21*t*, 22  
   superior rectus muscle attachment to, 29  
 Levocycloverion, 38  
 Levoversion, 37  
 LHoT. *See* Left hypotropia  
 Lighthouse chart, 7  
 Ligneous conjunctivitis, 249  
 Limbal incision, 163  
 Limbal vernal keratoconjunctivitis, 248, 249*f*  
 Lipidoses, 388*t*  
 Lipodermoids, 210  
 Lipofuscin, 340  
 Lisch nodules, 271–272, 272*f*, 392, 395*f*, 397  
 Listing's law, 31  
 Listing's plane, 31  
 Lobular capillary hemangioma. *See* Pyogenic granuloma  
 Lockwood ligament, 28  
 LogMAR visual acuity chart, 7*f*, 8  
 Louis-Bar syndrome. *See* Ataxia-telangiectasia  
 Lower eyelid, inferior rectus muscle attachment to, 30*f*  
 Lowe syndrome, 391  
 Low vision  
   information sources on, 189*t*  
   rehabilitation for, 188–189, 189*t*  
 LTBP2. *See* Latent transforming growth factor  
   beta-binding protein 2  
 LTBP2 gene, 277  
 Lymphangioma, 221  
 Lymphatic malformation, orbital, 221–222  
 Lymphocytic choriomeningitis virus (LCMV), 413  
 Lymphoma  
   Burkitt, 218  
   orbital, 218  
 MAC. *See* Microphthalmia, anophthalmia, coloboma  
 Macrolides, for blepharitis, 245  
 Macular dragging, in retinopathy of prematurity, 334, 334*f*  
 Macular dystrophies, hereditary  
   Best disease, 340–342, 342*f*  
   Stargardt disease, 339–340, 340–341*f*  
 Macular edema, after cataract surgery, 304–305  
 Macular granuloma, 317*f*  
 Maddox rod test  
   double, 69, 69*f*, 120  
   ocular alignment assessments using, 68–69, 69*f*  
 Magnetic resonance imaging  
   optic nerve on, 363*f*  
   Sturge-Weber syndrome findings, 402*f*  
 Maintained fixation, 6  
 Major amblyoscope, 70, 70*f*  
 Malherbe calcifying epitheliomas. *See* Pilomatricoma  
 Malignant hyperthermia (MH), 174–175  
 Malignant osteopetrosis, infantile, 212  
 Mammillations, iris, 271–272, 272*f*  
 Mandibulofacial dysostosis. *See* Treacher Collins syndrome  
 Manifest exodeviations, 99  
 Manifest latent nystagmus, 88, 95, 151  
 Manifest strabismus, 15  
 Mannosidosis, 389*t*  
 Marcus Gunn jaw-winking syndrome, 198  
 Marfan syndrome  
   cardiovascular abnormalities associated with, 307–308  
   clinical features of, 307, 308*f*  
   lens dislocation associated with, 307–308, 308*f*  
   ocular abnormalities associated with, 308, 308*f*  
 Marginal myotomy, 164*t*  
 Margin-reflex distance (MRD), 197  
 Maroteaux-Lamy syndrome, 388*t*  
 Masked bilateral superior oblique muscle palsy, 122  
 Mast-cell stabilizers, for ocular allergies, 247*t*, 248  
 Medial longitudinal fasciculus (MLF), 144  
 Medial rectus muscle  
   action of, 31, 34*t*, 35*f*  
   adduction of, 35*f*  
   botulinum toxin injection of, 97  
   characteristics of, 21*t*  
   displacement of, for A-pattern strabismus, 110, 111*f*  
   excision of, 146



- field of action, 33
- inadvertent excision of, 146
- innervation of, 19
- laceration of, 146
- origin of, 20, 21*t*
- recession/resection of
  - for convergence insufficiency, 103
  - for Duane retraction syndrome, 133
  - for esotropia from nystagmus blockage syndrome, 155
  - for infantile esotropia, 89
  - for internuclear ophthalmoplegia, 144
  - for Möbius syndrome, 136
- restriction of, 97
- slipped, 169, 169*f*
- surgery considerations for, 29
- Medial rectus tendon, 19*f*
- Medulloepithelioma, 273*f*, 273–274
- Megalocornea, 253*f*, 253–254
- Megalopapilla, 366
- Meibomian glands
  - blepharitis with dysfunction of, 244, 244*f*
  - distichiasis of, 195, 195*f*
- Melanocytic lesions, 392, 395*f*
- Melanocytoma, of optic disc, 367, 367*f*
- Melanocytosis, ocular, 250–251, 251*f*
- Melanosus oculi, 250–251
- Melphalan, 357
- Membranous conjunctivitis, 251
- Meningioma, orbital, 223
- Meningocele, 225
- Metachromatic leukodystrophy, 388*t*
- Metastases
  - orbital neuroblastoma, 414, 415*f*
  - orbital tumors, 218
- Methicillin-resistant *Staphylococcus aureus* (MRSA), 213, 240
- Methotrexate, for uveitis, 322
- MFRP* gene, 263
- MGDA. *See* Morning glory disc anomaly
- MH. *See* Malignant hyperthermia
- Microcornea, 254, 254*f*
- Microphthalmia
  - with cyst, 224, 225*f*
  - description of, 209
- Microphthalmia, anophthalmia, coloboma (MAC), 263
- Microspherophakia, 307
- Microtropia, 51
- Mitten deformity, 206, 207*f*
- Mittendorf dot, 298
- MLF. *See* Medial longitudinal fasciculus
- Möbius syndrome, 97, 135–136, 136*f*
- “Molar tooth” sign, 392*f*
- Molluscum contagiosum, 199, 243, 244
- Molybdenum cofactor deficiency. *See* Sulfite oxidase deficiency
- Monocanalicular stents, 234
- Monochromatism
  - blue-cone, 337–338
  - rod, 337
- Monoclonal antibodies, 322
- Monocular cover-uncover test, 64, 65*f*
- Monocular elevation deficiency, 125–127, 126*f*
- Monocular eye movements
  - ductions, 33
  - field of action, 33–34
  - gaze position effects on extraocular muscle action, 34–37, 35–37*f*
  - primary action, 34
  - secondary action, 34
  - terminology associated with, 33
  - tertiary action, 34
- Monocular fixation, 16
- Monocular nystagmus, 152
- Monocular visual deprivation
  - binocularity affected by, 45
  - description of, 44
  - visual cortex affected by, 45
- Monofixation syndrome
  - amblyopia and, 52
  - definition of, 51
  - diagnosis of, 51–52
  - management of, 52
  - Worth 4-dot test for, 81
- Monosomy X, 386*t*
- Morning glory disc anomaly (MGDA), 362–363, 364*f*
- Morquio syndrome, 270
- Motility disorders
  - chronic progressive external ophthalmoplegia (CPEO), 141–142, 143*t*
  - esotropia and hypotropia associated with high myopia, 143–144
  - internuclear ophthalmoplegia, 144
  - myasthenia gravis, 142*f*, 142–143, 143*t*
  - ocular motor apraxia, 144–145
  - superior oblique myokymia, 145
  - thyroid eye disease, 140–141, 141*f*, 143*t*, 215
- Motor fusion, 43
- Motor physiology
  - eye movements. *See* Eye movements
  - gaze positions, 31
  - ocular rotations, 31
  - principles of, 31–32
  - terminology associated with, 31–32
- Motor units
  - description of, 32–33
  - recruitment of, during fixation or following movement, 33
- Moyamoya disease, 363
- MPS. *See* Mucopolysaccharidoses
- MRD. *See* Margin–reflex distance
- MRSA. *See* Methicillin-resistant *Staphylococcus aureus*
- Mucocele, 224
- Mucocutaneous lymph node syndrome. *See* Kawasaki disease
- Mucopolysaccharidoses, 388*t*
- Mucopolysaccharidoses (MPSs), corneal disorders in, 257*t*, 270, 385, 387*f*, 388*t*
- Mucormycosis, 215, 215*f*
- Multifocal choroiditis, 319
- Multifocal eosinophilic granuloma, 219
- Muscle cone, 26, 26*f*
- Myasthenia gravis, 142*f*, 142–143, 143*t*
- Mycobacterium leprae*, 240
- Mycobacterium tuberculosis*, 240
- Mycophenolate mofetil, for uveitis, 322

- Mydriasis, congenital, 268  
 Myectomy, 164*t*  
 Myelinated retinal nerve fiber layer, 365, 365*f*  
 Myelin sheaths, 44  
 Myofibromas, 222  
 Myokymia, superior oblique, 145  
 Myopia  
   high  
     esotropia associated with, 97, 143–144  
     exotropia associated with, 143–144  
   prevalence of, 180  
   in retinopathy of prematurity, 334  
 Myotomy, 164*t*
- Nanophthalmos, 263  
 Nasal endoscopy, for nasolacrimal duct obstruction, 235  
 Nasolacrimal duct obstruction (NLDO)  
   congenital  
     antibiotics for, 231–232, 234  
     balloon dacryoplasty for, 234–235, 235*f*  
     bilateral, 232*f*  
     clinical features of, 230, 232*f*  
     complex, 230, 233–234  
     description of, 227, 230  
     examination of, 230  
     infantile glaucoma versus, 230  
     intubation for, 234–235  
     massage for, 231–232  
     nasolacrimal probing for, 232–235, 233*f*  
     nonsurgical management of, 231–232  
     prevalence of, 230  
     recurrence of, 234  
     simple, 230, 231*f*  
     spontaneous resolution of, 231  
     stents for, 234–235  
     surgical management of, 232–233  
     tearing caused by, 230  
   dacryocystorhinostomy for, 236  
   nasal endoscopy for, 235  
   in older children, 235  
   recurrent, 234  
 Nasolacrimal probing, for congenital nasolacrimal duct obstruction, 232–235, 233*f*  
 National Eye Institute (NEI) classification of eye movement abnormalities, 147  
 NDP gene, 347  
 Nd:YAG laser capsulotomy, 302  
 Near fixation, 64  
 Near point of convergence, 71  
 Near reflex spasm, 94  
 Near synkinesis, 39  
 Near triad, 39  
 Negative angle kappa, 67, 68*f*  
 NEI classification of eye movement abnormalities, 147  
*Neisseria gonorrhoeae*, 238*f*, 238–239  
*Neisseria meningitidis*, 238  
 Neonatal inclusion conjunctivitis, 238  
 Neoplasms, orbital. *See also* Tumor(s)  
   benign, 219–223  
   differential diagnosis of, 216–217  
   eyelid, 199–200  
   hemangiomas, 219–221  
   hematopoietic, 218–219  
   histiocytic, 218–219  
   Langerhans cell histiocytosis, 218–219  
   leukemia, 218  
   lymphoma, 218  
   lymphoproliferative, 218–219  
   metastatic, 218  
   neuroblastoma, 218  
   primary malignant, 217–218  
   rhabdomyosarcoma, 217*f*, 217–218  
   sarcomas, 218  
   vascular, 219–221, 220–221*f*  
 Nettleship-Falls ocular albinism, 407  
 Neural tumors, 223  
 Neuroblastoma, 218, 414–415, 415*f*  
 Neurofibromatosis type 1 (NF1)  
   clinical features of, 393*t*  
   manifestations of, 396–397  
   melanocytic lesions in, 392, 395*f*  
   neuroglial lesions in, 395*f*, 395–396  
   plexiform neurofibromas in, 395*f*, 395–396  
   sphenoid dysplasia associated with, 397  
 Neurofibromatosis type 2 (NF2), 393*t*, 397  
 Neurofibrovascular bundle, 29  
 Neuroglial lesions, 395*f*, 395–396  
 Neuroimaging  
   cerebral visual impairment evaluations, 188  
   superior oblique muscle palsy evaluations, 119  
 Neuromuscular blocking agents, 174  
 Neuronal ceroid lipofuscinosis, 389*t*  
 Neuro-oculocutaneous syndromes  
   ataxia-telangiectasia, 393*t*, 403*f*, 403*t*, 403–404  
   characteristics of, 392  
   clinical features of, 393–394*t*  
   incontinentia pigmenti, 393*t*, 404*t*, 404–405, 404–405*f*  
   Klippel-Trénaunay syndrome (KTS), 406  
   neurofibromatosis type 1. *See* Neurofibromatosis type 1  
   neurofibromatosis type 2, 393*t*, 397  
   tuberous sclerosis, 393*t*, 397–399, 398*f*, 398*t*  
   von Hippel-Lindau syndrome, 393*t*, 399–401, 400*f*, 400*t*  
   Wyburn-Mason syndrome, 222, 394*t*, 405*t*, 405–406  
 Neuroretinitis, 369, 369*f*  
 Neutral density filter effect, 54  
 Nevi/nevus  
   conjunctival, 250, 250*f*  
   eyelid, 200–201, 201*f*  
   flammeus. *See* Port-wine stain  
   of Ota, 251  
 Newborns. *See also* Infant(s)  
   dysconjugate eye movements in, 185  
   extraocular muscles in, 182  
   pupils in, 10  
   skew deviation in, 185  
   sunsetting in, 185  
   visual acuity of, 44  
   visual development in, 185  
 Newcastle Control Score for Intermittent Exotropia, 100  
 Next-generation gene sequencing, 301  
 NF1. *See* Neurofibromatosis type 1  
 NF2. *See* Neurofibromatosis type 2  
 Niemann-Pick disease, 388*t*  
 NLDO. *See* Nasolacrimal duct obstruction  
 NOD2 gene, 319

- Nonaccidental trauma  
 abusive head trauma, 381–384, 382–383*f*  
 ocular injury secondary to, 384
- Nonalternating suppression, 49
- Nonrefractive accommodative esotropia, 90
- Nonspecific orbital inflammation (NSOI), 215–216, 216*f*
- Nonsteroidal anti-inflammatory drugs, for ocular allergies, 247*t*
- Normal retinal correspondence (NRC)  
 afterimage test for, 79*f*  
 in intermittent exotropia, 100  
 strabismus and, 48, 49*f*  
 testing for, 51
- Norrie disease, 347
- NRC. *See* Normal retinal correspondence
- NSOI. *See* Nonspecific orbital inflammation
- Nuclear cataracts  
 infantile, 295, 296*f*  
 in rubella, 410
- Null point/zone  
 in congenital motor nystagmus, 148, 156  
 in jerk nystagmus, 147
- Nummular keratitis, 243
- Nystagmus  
 acquired, 151–152  
 Anderson procedure for, 155  
 central vestibular instability, 149  
 chin-down position, 156  
 chin-up position, 156  
 congenital motor, 148–149, 149*t*, 153–154  
 congenital sensory, 149, 150*t*, 154  
 convergence-retraction, 152–153  
 definition of, 147  
 diagnosis of, 84  
 downbeat, 152  
 dysconjugate, 151–152  
 esotropia and, 86*t*, 95  
 evaluation of, 153–154  
 features of, 147  
 fusion maldevelopment nystagmus syndrome, 83, 88, 95, 148, 150–151, 151*f*, 154  
 gaze direction and, 147  
 head-tilt correction in, 156  
 in hereditary retinal disease, 335  
 history-taking for, 153  
 horizontal rectus muscle surgery for, 157  
 induced convergence-retraction, 152–153  
 infantile nystagmus syndrome, 83, 148–149, 149*t*, 156*f*, 187, 335  
 inheritance patterns, 153  
 jerk, 147  
 Kestenbaum procedure for, 155, 156*f*, 156*t*  
 latent, 88, 95, 129, 150–151, 154  
 manifest latent, 88, 95, 151  
 monocular, 152  
 monocular occlusion effects on intensity of, 154  
 nomenclature for, 147  
 ocular examination for, 153–154  
 pendular, 147  
 periodic alternating, 149  
 prevalence of, 147  
 prisms for, 155  
 pupil responses in, 154  
 retinal dystrophy and, 391*f*  
 see-saw, 152  
 sensory, 187  
 spasmus nutans syndrome, 151–152  
 strabismus associated with, 154, 156–157  
 surgery for, 155–157, 156*f*, 156*t*  
 treatment of, 155–157  
 vertical, 152  
 visual acuity assessments in, 8, 153–154
- Nystagmus blockage syndrome, 95, 148, 155
- Nystagmus-like disorders, 152–153
- Oblique muscles  
 anatomy of, 20–22, 21*t*  
 inferior. *See* Inferior oblique muscle  
 overactions of, 17, 117  
 pseudo-overactions, 116  
 superior. *See* Superior oblique muscle  
 tightening procedures for, 164*t*, 166–167  
 weakening procedures for, 164*t*, 165–166
- Occlusion therapy  
 adherence to, 60  
 amblyopia treated with, 58, 96, 102  
 basic acquired nonaccommodative esotropia  
 secondary to, 93  
 full-time, 58, 60  
 intermittent exotropia treated with, 102  
 part-time, 58  
 reverse amblyopia caused by, 60
- OCRL gene, 391
- OCT. *See* Optical coherence tomography
- Ocular adnexa  
 abnormalities of, in craniosynostosis, 209  
 description of, 181
- Ocular albinism, 406–407. *See also* Albinism
- Ocular alignment  
 assessment of  
 alternate cover test, 65–66, 66*f*  
 corneal light reflex tests, 67–68, 68*f*  
 cover tests, 64–67, 65–66*f*  
 diagnostic positions of gaze, 64  
 Lancaster red-green test for, 69  
 Maddox rod test, 68–69, 69*f*  
 major amblyoscope for, 70, 70*f*  
 monocular cover test, 64, 65*f*  
 prism alternate cover test, 65–66, 66*f*  
 red reflex tests, 67–68  
 simultaneous prism and cover test, 66–67  
 subjective tests for, 68–70  
 after extraocular muscle surgery, 168  
 in infantile esotropia, 88–89
- Ocular allergies, 246*f*, 246–249, 247*t*, 248*t*
- Ocular hypertelorism, 191
- Ocular hypotelorism, 191
- Ocular instability of infancy, 87
- Ocular melanocytosis, 250–251, 251*f*
- Ocular motor apraxia, 144–145
- Ocular rotations  
 assessment of, 71  
 definition of, 31  
 horizontal, 31  
 torsional, 31

- tube shunt effects on, 146
  - vertical, 31
- “Ocular splits,” 133
- Ocular tics, 201–202
- Ocular torsion, 107
- Ocular torticollis, 82–84, 83*t*
- Oculocardiac reflex, 174
- Oculocerebrorenal syndrome. *See* Lowe syndrome
- Oculocutaneous albinism. *See* Albinism
- Oculodermal melanocytosis, 251
- Oculodigital reflex, 185
- Oculomotor nerve
  - divisions of, 19
  - extraocular muscle innervation by, 19–20
  - palsy of. *See* Third nerve palsy
  - superior division palsy of, 128
- ODAd. *See* Overdepression in adduction
- OEAd. *See* Overelevation in adduction
- OMIM, 294
- 1 toy, 1 look rule, for pediatric eye examination, 3, 4*f*
- OPA1* gene, 367
- Open-angle glaucoma
  - aphakic, 285
  - juvenile, 278, 284
- Ophthalmia neonatorum
  - Chlamydia trachomatis* as cause of, 238–239, 239*f*
  - definition of, 237
  - epidemiology of, 237
  - etiology of, 237
  - herpes simplex virus as cause of, 239
  - Neisseria gonorrhoeae* as cause of, 238*f*, 238–239
  - Neisseria meningitidis* as cause of, 238
  - prevalence of, 237
  - prophylaxis for, 239
- Ophthalmic artery, 23
- Ophthalmic examination, in children
  - anterior segment examination, 10
  - Brückner test, 9
  - communication during, 4
  - cycloplegic refraction, 10–12
  - difficult child, 5
  - distance fixation targets, 3, 4*f*
  - dynamic retinoscopy, 9
  - fundus, 12
  - general considerations and strategies for, 3–5
  - intraocular pressure measurement, 10
  - 1 toy, 1 look rule, 3, 4*f*
  - in outpatient setting, 3, 4*f*
  - practitioner positioning during, 4
  - pupil testing, 10
  - red reflex, 9
  - “safe” environment for, 4
  - slit-lamp examination, 4–5
  - tonometry, 10
  - visual acuity assessment. *See* Children, visual acuity assessment
  - visual field testing, 10
  - vocabulary during, 4
- Opsoclonus, 153, 415
- Optical coherence tomography (OCT)
  - optic disc drusen on, 373*f*
  - in primary congenital glaucoma evaluations, 283
- Optic atrophy
  - Behr, 368
  - causes of, 367, 367*t*
  - dominant, 367–368, 368*f*
  - Leber hereditary optic neuropathy, 368
  - recessive, 368
- Optic disc
  - coloboma of, 339*f*
  - cupping of, 187, 402*f*
  - drusen of, 373*f*, 373–374
  - megalopapilla, 366
  - melanocytoma of, 367, 367*f*
  - papilledema of
    - definition of, 370
    - idiopathic intracranial hypertension and, 370*f*, 370–371
  - peripapillary staphyloma of, 366
  - pseudopapilledema of, 372–373*f*, 372–374
  - swelling of, 371*t*
  - tilted, 365–366, 366*f*
- Optic disc cup, 282, 283*f*
- Optic nerve
  - aplasia of, 366
  - coloboma of, 364–365*f*
  - craniosynostosis-related abnormalities of, 208–209
  - decussation of, 43
  - developmental anomalies of, 361–367, 362–367*f*
  - hypoplasia of, 154, 361–362, 362*f*
  - leukemic infiltration of, 414, 414*f*
  - magnetic resonance imaging of, 363*f*
  - morning glory disc anomaly of, 362–363, 364*f*
  - myelination of, 365, 365*f*
  - in primary congenital glaucoma, 282–283, 283*f*
- Optic nerve pit, 364–365, 365*f*
- Optic neuritis, 369, 369*f*
- Optic neuropathy, traumatic, 381
- Optic pathway glioma, 223, 396, 396*f*
- Optokinetic system, 40
- Optotypes
  - age-appropriate, 8
  - contour interaction bars around, 7*f*, 8, 54
  - crowding phenomenon for, 54
  - LEA symbols, 6, 7*f*
  - for visual acuity assessment in children, 6*t*, 6–8, 7*f*
- Orbit
  - adipose tissue in, 25
  - development of, 181
  - extraocular muscles in, 25–28, 26–27*f*
  - fascia of, 27
  - morphologic measurements of, 191, 192*f*
- Orbital cellulitis, 170, 170*f*, 213–215, 214*f*
- Orbital disorders
  - craniosynostosis. *See* Craniosynostosis
  - dermoid cysts, 223–224, 223–224*f*
  - ectopic lacrimal gland, 226
  - ectopic tissue masses, 223–225*f*, 223–226
  - encephalocele, 225
  - inflammation, 215–216
  - malformations
    - arteriovenous, 222
    - lymphatic, 221–222
    - vascular, 221–222
    - venous, 222
  - meningocele, 225

- metastatic tumors, 218
- microphthalmia with cyst, 224, 225*f*
- mucocoele, 224
- mucormycosis, 215, 215*f*
- neoplasms
  - benign, 219–223
  - differential diagnosis of, 216–217
  - hemangiomas, 219–221
  - hematopoietic, 218–219
  - histiocytic, 218–219
  - Langerhans cell histiocytosis, 218–219
  - leukemia, 218
  - lymphoma, 218
  - lymphoproliferative, 218–219
  - metastatic, 218
  - neuroblastoma, 218
  - primary malignant, 217–218
  - rhabdomyosarcoma, 217*f*, 217–218
  - sarcomas, 218
  - vascular, 219–221, 220–221*f*
- orbital cellulitis, 213–215, 214*f*
- preseptal cellulitis, 212–214
- space-occupying lesions, 216
- teratoma, 225*f*, 225–226
- tumors
  - bony, 222
  - connective tissue origin, 222
  - neural origin, 223
- Orbital floor fractures, 127–128, 128*f*, 379–380, 380*f*
- Orbital layer, of extraocular muscles, 24
- Orbital myositis, 216
- Orbital roof fractures, 380, 380*f*
- Orbital veins, 23
- Orthophoria
  - abbreviation for, 17
  - definition of, 15
- Orthoptics
  - convergence insufficiency treated with, 103
  - fusional vergence affected by, 72
  - for suppression, 50
- Orthotropia
  - definition of, 15
  - treatment of, 58
- Otoliths, 40
- Overdepression in adduction (ODAd)
  - causes of, 17, 116*t*, 116–118
  - description of, 17
  - pattern strabismus and, 107, 108*f*, 109
  - superior oblique muscle overaction as cause of, 118, 118*f*, 137
- Overelevation in adduction (OEAd)
  - causes of, 17, 116*t*, 116–118
  - description of, 17
  - inferior oblique muscle overaction as cause of, 117*f*, 117–118
  - pattern strabismus and, 107, 108*f*, 109
- Palpebral fissure
  - in blepharophimosis–ptosis–epicanthus inversus syndrome (BPES), 198
  - in Brown syndrome, 137
  - in cryptophthalmos, 191
  - dermolipomas of, 257
  - downward-slanting
    - description of, 196
    - pattern strabismus and, 107, 108*f*
    - syndromes with, 196
  - growth and development of, 181
  - inferior rectus muscle alteration effect on, 29, 30*f*
  - in Möbius syndrome, 135
  - slants of, 196
- Palpebral vernal keratoconjunctivitis, 248, 248*f*
- Panretinal photocoagulation, for retinopathy of prematurity, 332, 333*f*
- Panum's area of single binocular vision, 42, 42*f*, 48
- Panuveitis, 318*f*, 318–319
- Papilledema
  - definition of, 370
  - idiopathic intracranial hypertension and, 370*f*, 370–371
- Papillomas, 250
- Paradoxical diplopia, 50, 50*f*
- Paradoxical pupils, 335, 336*t*
- Paralysis, convergence, 105–106
- Paralytic strabismus
  - extraocular muscle surgery for, 161
  - Hering's law of motor correspondence and, 38
- Paranasal sinusitis, 213, 214*f*
- Parasympathomimetics, 289*t*
- Parinaud oculoglandular syndrome, 240*f*, 240–241
- Parkinson disease, convergence insufficiency associated with, 103
- Parks-Bielschowsky 3-step test, 73, 120
- Pars planitis, 316
- Partially accommodative esotropia, 90–92
- Part-time occlusion, for amblyopia, 58
- Patau syndrome, 386*t*
- Patching. *See* Occlusion therapy
- Pathologic suppression, 48
- Pattern strabismus
  - A-
    - clinical features of, 109
    - clinically significant, 109
    - definition of, 107
    - etiology of, 107–109, 108*f*
    - exotropia, 108*f*, 112
    - in exotropia, 109
    - horizontal rectus muscle transposition for, 112
    - identification of, 109
    - intorsion as cause of, 107, 110
    - medial rectus muscle displacement for, 110, 111*f*
    - palpebral fissure slanting associated with, 196
    - superior oblique muscle overaction associated with, 107
    - superior oblique tenotomy for, 112
    - surgical treatment of, 112, 112*t*
  - anomalous innervation as cause of, 109
  - λ-
    - clinical features of, 110
    - surgical treatment of, 113
  - management of, 110–113, 111*f*, 112*t*
  - ocular torsion as cause of, 107
  - surgical correction of, 110–113, 111*f*, 112*t*
  - types of, 107
  - V-
    - bilateral superior oblique palsy and, 122
    - in Brown syndrome, 137

- clinical features of, 109  
 clinically significant, 109  
 craniofacial anomalies and, 107  
 in craniosynostosis, 208  
 definition of, 107  
 etiology of, 107–109, 108f  
 exotropia with, 108f, 111  
 extorsion as cause of, 107, 110  
 heterotropy as cause of, 28  
 identification of, 109  
 infantile esotropia associated with, 109, 112  
 inferior oblique muscle overaction associated with, 107  
 palpebral fissure slanting associated with, 196  
   clinical features of, 109–110  
   definition of, 107  
   downward-slanting palpebral fissures and, 107, 108f  
   etiology of, 107–109, 108f  
   horizontal rectus muscles and, 109  
   identification of, 109–110  
 superior oblique palsy and, 122  
 surgical treatment of, 111–112, 112t
- X-  
 clinical features of, 110  
 surgical treatment of, 113
- Y-  
 clinical features of, 109–110  
 surgical treatment of, 113
- Patti Stripes Square Wave Grating Paddles, 8  
 Pauciarticular juvenile idiopathic arthritis, 313, 314t  
*PAX6* gene, 267, 338  
 PCG. *See* Primary congenital glaucoma  
 Pediatric glaucoma. *See* Childhood glaucoma  
 Pediatric granulomatous arthritis, 318  
 PEDs. *See* Pigment epithelial detachments  
 Pendular nystagmus, 147  
 Penetrating injury, 376–378, 377f  
 Penicillin G, for syphilis, 413  
 Perennial allergic conjunctivitis, 246–248  
 Perforating injury, 376–378, 377f  
 Peribulbar anesthesia, 174  
 Perimacular folds, in abusive head trauma, 382–383  
 Perinatal infections. *See* Intrauterine/perinatal infections  
 Periodic alternating nystagmus, 149  
 Periorbital ecchymoses, 379, 384  
 Peripapillary hemorrhages, 373  
 Peripapillary staphyloma, 366  
 Peripheral corneal transparency abnormalities, 255–256f, 255–257  
 Peripheral fusion, 51–52  
 Peripheral suppression, 48  
 Peripheral vacuolar cataracts, 298  
 Peritomy, 163  
 Periventricular leukomalacia, 187, 361–362  
 Perkins Tonometer, 10, 281  
 Persistent fetal vasculature (PFV), 298f, 298–299, 301  
 Persistent pupillary membrane, 264, 264f, 266f  
 Peters anomaly, 259, 260f  
 Peters-plus syndrome, 259  
 Pfeiffer syndrome, 207  
 PFV. *See* Persistent fetal vasculature  
 PHACE syndrome, 220, 363  
 Phakomas, retinal, 397, 399  
 Pharyngoconjunctival fever, 242  
 -phoria (suffix), 16  
 Photocoagulation, for retinopathy of prematurity, 332, 333f  
 Photoreceptors, 44  
 Phototherapeutic keratectomy, for band keratopathy, 322  
 Physiologic anisocoria, 275  
 Physiologic suppression, 48  
 Pierre Robin sequence, 183, 211  
 Pigment epithelial detachments (PEDs), 342  
 Pigment epithelium cysts, of iris, 272, 272f  
 Pilocytic astrocytoma, 396  
 Pilomatrixoma, 200, 200f  
 PITS. *See* Pulled-in-two syndrome  
*PITX2* gene, 265  
 Plagiocephaly, 204–205  
 Plaque hemangioma, 220, 220f  
 Plexiform neurofibromas, 223, 395f, 395–396  
 Plica semilunaris  
   advancement of, 171  
   hypertrophy of, 172f  
 Plication, 164t  
 Plus disease, 326, 327t, 330f  
 Plus lenses  
   amblyopia treated with, 59  
   convergence paralysis treated with, 106  
 PMMA lenses, 302  
 PNET. *See* Primitive neuroectodermal tumor  
 Poland syndrome, 135  
 Polar cataracts, anterior, 55, 295, 295f  
 Polarized Worth 4-dot test, 80  
 Polyarticular juvenile idiopathic arthritis, 313, 314t  
 Polydactyly, 391, 391f  
 Polymethyl methacrylate (PMMA) lenses, 302  
 Port-wine stain (PWS), 199, 401, 401t, 402f  
 Positive angle kappa, 67, 68f  
 Posterior capsular cataract, 387f  
 Posterior capsulectomy, 303  
 Posterior capsule opacification, 302  
 Posterior corneal depression, 259  
 Posterior embryotoxon, 255, 255f  
 Posterior fixation  
   definition of, 164t, 167  
   suture for, 164t  
 Posterior fossa malformations, hemangiomas, arterial lesions, and eye anomalies. *See* PHACE syndrome  
 Posterior lenticonus, 296–297, 297f  
 Posterior microphthalmos, 263  
 Posterior pole  
   distortion of, 317f  
   familial exudative vitreoretinopathy findings, 347, 348f  
   traction of, 334f  
 Posterior subcapsular cataracts (PSCs), 297  
 Posterior uveitis  
   definition of, 317  
   differential diagnosis of, 312t  
   inflammation in, 320  
   laboratory tests for, 321t  
   toxocariasis as cause of, 317f, 317–318  
   toxoplasmosis as cause of, 317  
 Posterior vitrectomy, 303

- Posterior vitreous detachment, 347
- Postoperative nausea and vomiting, 174
- Postsurgical consecutive esotropia, 95
- Postsurgical esotropia, 102
- Postsurgical exotropia, 104
- PRDM5* gene, 254
- Preferential looking, for visual acuity assessment, 5, 8–9, 9*f*, 182, 300
- Pregeniculate visual impairment, 186–187
- Preliterate children, optotypes for visual acuity assessment in, 6*t*, 6–7, 7*f*
- Pre-plus disease, 326, 327*t*, 330*f*
- Preseptal cellulitis, 170, 212–214
- Press-on prisms, for diplopia, 96
- Prethreshold disease, 326
- Preverbal children
- fixation assessments in, 300
  - visual acuity assessment methods in, 8–9, 154
- Primary congenital glaucoma (PCG)
- anterior segment findings in, 282, 282*f*
  - axial length in, 283
  - central corneal thickness in, 281
  - clinical manifestations of, 279–280, 280*f*
  - corneal edema in, 279–280
  - corneal findings in, 280*f*, 280–281
  - definition of, 278
  - diagnostic examination for, 280–283, 282–283*f*
  - differential diagnosis of, 281*t*
  - genetics of, 277–278
  - gonioscopy for, 282, 282*f*
  - goniotomy for, 285, 286*f*
  - incidence of, 278
  - natural history of, 283–284
  - optical coherence tomography of, 283
  - optic nerve findings in, 282–283, 283*f*
  - pathophysiology of, 278
  - surgical treatment of, 285–287, 286*f*
  - tonometry in, 281–282
  - trabeculectomy, 286*f*, 286–287
- Primary deviation
- definition of, 38
  - secondary deviation versus, 115
- Primary divergence insufficiency, 94
- Primary megalocornea, 253–254
- Primary position hypotropia, with Brown syndrome, 137
- Primary position of gaze, 31, 64
- Primary posterior capsulectomy, 303
- Primary telecanthus, 203
- Primary visual cortex, abnormal visual experience effects on, 53
- Primitive neuroectodermal tumor (PNET), 357–358
- Prism(s)
- base-out
    - convergence insufficiency and, 103
    - convergence paralysis and, 106
    - dissociated vertical deviation and, 129
    - nystagmus treated with, 155
  - convergence insufficiency treated with, 103
  - convergence paralysis treated with, 106
  - diplopia treated with, 72
  - intermittent exotropia treated with, 102
  - nystagmus treated with, 155
  - visual acuity assessment in children using, 6
- Prism Adaptation Study, 93
- Prism adaptation test, 82
- Prism alternate cover test, 65–66, 66*f*
- Prism and cover test
- exodeviation evaluations, 100
  - simultaneous, 66–67
- Probing, for congenital nasolacrimal duct obstruction, 232–234, 233*f*
- Propranolol, for hemangioma, 220, 221*f*
- Proptosis
- in craniosynostosis, 207
  - nonspecific orbital inflammation as cause of, 215
- Prostaglandin analogues, 289*t*, 290
- Proximal (instrument) convergence, 39
- PRSS56* gene, 263
- PSCs. *See* Posterior subcapsular cataracts
- Pseudocolobomas, 211
- Pseudoesotropia, 85–87, 86*f*, 99
- Pseudoexotropia
- description of, 99
  - in retinopathy of prematurity, 334, 335*f*
- Pseudo-Hurler polydystrophy, 388*t*
- Pseudohypopyon, 342
- Pseudomembranous conjunctivitis, 251
- Pseudopapilledema, 372–373*f*, 372–374
- Pseudopolyopia, 268, 268*f*
- Pseudoproptosis, 217, 283
- Pseudoptosis, in hypotropia, 30
- Pseudotumor cerebri. *See* Idiopathic intracranial hypertension
- Ptosis
- classification of, 197*t*
  - congenital, 196–198, 197*t*, 198*f*
  - evaluation of, 197
- Pulled-in-two syndrome (PITS), 169–170
- Pulley system
- abnormalities of, 107
  - of extraocular muscles, 28, 32
- Punctate epithelial keratitis, 269
- Punctate keratitis, 197
- Pupil
- abnormalities of, 267–268, 268*f*
  - anisocoria of, 275
  - congenital miosis of, 267–268
  - corectopia of, 268
  - dilation of, for retinopathy of prematurity examination, 331
  - dyscoria of, 267
  - growth and development of, 181
  - mydriasis of, 268
  - paradoxical, 335, 336*t*
  - pseudopolyopia of, 268, 268*f*
  - tonic, 275
- Pupillary light reflex
- in children, 10
  - development of, 181
- Pupil testing
- in children, 10
  - in nystagmus evaluations, 154
- Pursuit latency, 40
- PWS. *See* Port-wine stain
- Pyogenic granuloma, 170, 171*f*, 199, 199*f*
- Pyrimethamine, for toxoplasmosis, 409

- Random-Dot E test, 81
- Random-dot stereopsis tests, 81
- Randot test, 81
- Ranibizumab, for retinopathy of prematurity, 333
- RBI* gene, 354, 358
- Reactive arthritis, 315*t*
- Recession/resection
- definition of, 164*t*
  - of horizontal rectus muscles
    - description of, 139
    - for esodeviations, 160
    - monocular, 161
    - for nystagmus correction, 157
  - of inferior rectus muscle
    - description of, 29
    - eyelid position affected by, 173
  - of lateral rectus muscle
    - for Duane retraction syndrome, 134
    - for exodeviations, 160
    - for high myopia, 143
    - for intermittent exotropia, 102
    - for third nerve palsy, 139
    - for X-pattern strabismus, 113
  - of medial rectus muscle
    - for convergence insufficiency, 103
    - for Duane retraction syndrome, 133
    - for esotropia from nystagmus blockage syndrome, 155
    - for infantile esotropia, 89
    - for internuclear ophthalmoplegia, 144
    - for Möbius syndrome, 136
- Recessive optic atrophy, 368
- Recruitment, 33
- Rectus muscles. *See also specific muscle*
- capsule of, 26
  - horizontal
    - anatomy of, 20, 35*f*
    - inferior zone of, 24
    - innervation of, 34
    - in pattern strabismus, 109–110
    - primary position of, 35, 35*f*
    - recession/resection of
      - description of, 139
      - for esodeviations, 160
      - monocular, 161
      - for nystagmus correction, 157
    - superior zone of, 24
    - transposition of, 110, 112
  - innervation of, compartmentalization of, 24
  - insertion of, 22, 23*f*
  - posterior fixation of, 164*t*, 167
  - pulley system for, 28
  - “restrained shortest-path model” of, 28
  - tightening procedures for, 163–164, 164*t*
  - vertical
    - anatomy of, 20, 22*f*
    - eyelid attachments to, 30*f*
    - insertion of, 22
    - surgery of
      - for nystagmus, 156
      - for pattern strabismus correction, 111
    - vertical strength of, 35
  - weakening procedures for, 163, 164*t*
- Red eye. *See* Conjunctival hyperemia
- Red-glass test, 51, 75–76, 76*f*
- Red-green dyschromatopsia, 368
- Red reflex
  - media opacity effects on, 68
  - refractive error effects on, 68
  - testing of
    - in children, 9
    - ocular alignment assessments using, 67–68
- Reese-Ellsworth classification, 354
- Refractive accommodative esotropia, 90–92
- Refractive amblyopia, 54–55
- Refractive errors
  - correction of
    - in amblyopia, 57–58
    - in intermittent exotropia, 101
    - from lens dislocation, 310
  - extraocular muscle surgery effects on, 173–174
  - red reflex affected by, 68
- Refractive state, 180*f*, 180–181
- Refsum disease, 389*t*
- Resection. *See* Recession/resection
- Response accommodative convergence/accommodation ratio, 71
- “Restrained shortest-path model,” 28
- Restrictive strabismus, Hering’s law of motor correspondence and, 38
- Retina
  - combined hamartoma of the retina and retinal pigment epithelium, 350
  - growth and development of, 182, 325
  - mesenchymal tissue, 325
  - phakomas of, 397, 399
  - splitting of. *See* Juvenile retinoschisis
  - vascularization of, 182, 325
  - zones of, 328*f*
- Retinal angiomatosis, 400*f*. *See also* von Hippel–Lindau syndrome
- Retinal capillary hemangioblastomas, 400
- Retinal correspondence
  - anomalous
    - afterimage test for, 79*f*
    - definition of, 50
    - diplopia and visual confusion eliminated with, 49*f*
    - eccentric fixation versus, 51
    - Maddox rod testing in, 68
    - major amblyoscope for, 70
    - red-glass test findings in, 76*f*
    - after strabismus surgery, 50
    - testing for, 50–51
  - description of, 41–42
  - normal
    - afterimage test for, 79*f*
    - strabismus and, 48, 49*f*
    - testing for, 51
- Retinal degeneration, 385
- Retinal detachment
  - after cataract surgery, 304
  - extrafoveal, in retinopathy of prematurity, 329*f*
  - retinopathy of prematurity as risk factor for, 334
  - rhegmatogenous, child abuse and, 384
  - scleral perforation as cause of, 170
  - serous, 362



- in Stickler syndrome, 346
- surgical treatment of, 146
- tractional, 348*f*, 360
- Retinal disease and disorders
  - acquired, 358–360, 359*f*
  - Coats disease, 358–360, 359*f*
  - combined hamartoma of the retina and retinal pigment epithelium, 350
  - hereditary
    - achromatopsia, 337–338
    - Aicardi syndrome, 338–339, 339*f*
    - congenital stationary night blindness, 338
    - evaluative tests for, 335
    - foveal hypoplasia, 338
    - Leber congenital amaurosis, 335–336, 337*f*
    - nystagmus associated with, 335
    - paradoxical pupils associated with, 335, 336*t*
  - human immunodeficiency virus complications, 348
  - infectious, 348
  - macular dystrophies
    - Best disease, 340–342, 342*f*
    - Stargardt disease, 339–340, 340–341*f*
  - retinoblastoma. *See* Retinoblastoma
  - retinopathy of prematurity. *See* Retinopathy of prematurity
  - tumors, 349–358
  - vitreoretinopathies
    - familial exudative, 347–348, 348*f*
    - juvenile retinoschisis. *See* Juvenile retinoschisis
    - Knobloch syndrome, 346*f*, 346–347
    - Norrie disease, 347
    - Stickler syndrome, 345–346
- Retinal dystrophy
  - congenital sensory nystagmus from, 154
  - juvenile, 390*f*
  - nystagmus associated with, 391*f*
- Retinal ganglion cells (RGCs)
  - apoptosis of, 44
  - development of, 44
- Retinal hemorrhages
  - in abusive head trauma, 382–383, 382–383*f*
  - in leukemia, 414
- Retinal pigment epithelium (RPE)
  - combined hamartoma of the retina and, 350
  - congenital hypertrophy of, 349, 349*f*
  - in Knobloch syndrome, 346
  - in Leber congenital amaurosis, 336
  - lesions of, 349, 349*f*
  - in Stargardt disease, 339, 341*f*
- Retinal rivalry, 47, 47*f*
- Retinitis, cytomegalovirus, 411
- Retinoblastoma
  - bilateral, 357*f*
  - chemotherapy for, 356–357
  - classification of, 354, 356*t*
  - Coats disease versus, 352–353, 360
  - description of, 299, 351
  - diagnosis of, 352–353*f*, 352–354
  - diffuse infiltrative, 353
  - endophytic, 352, 352*f*
  - evaluation of, 353
  - exophytic, 352–353, 353*f*
  - extraocular, 357
  - Flexner-Wintersteiner rosettes associated with, 353
  - genetics of, 354, 355*f*
  - histologic features of, 353–354
  - leukocoria associated with, 351, 351*t*, 351*f*
  - monitoring of, 358
  - recurrence of, 358
  - secondary malignancies in, 358
  - spontaneous regression of, 353
  - treatment of, 356–358
  - trilateral, 357
- Retinochoroiditis, cytomegalovirus, 411, 411*f*
- Retinogeniculocortical pathway
  - abnormal visual experience affecting, 44–47, 45–46*f*
  - development of, 44–47
- Retinopathy, diabetic, 408–409
- Retinopathy of prematurity (ROP)
  - aggressive posterior, 326, 327*t*, 330*f*, 333
  - anti-VEGF agents for, 333
  - bevacizumab for, 333
  - blindness caused by, 335
  - cicatricial, 67
  - classification of, 325–326, 327*t*, 328–330*f*, 331*t*
  - complications of, 334–335
  - cryotherapy for, 331
  - demarcation line in, 328*f*
  - diagnosis of, 329, 331
  - digital retinal photography for, 331
  - discovery of, 325
  - Early Treatment for Retinopathy of Prematurity
    - classification of, 326, 331*t*
    - extrafoveal retinal detachment in, 329*f*
    - extraretinal fibrovascular proliferation in, 329*f*
    - follow-up examinations for, 332*t*
    - insulin-like growth factor I in, 325, 326*t*
  - International Classification of Retinopathy of Prematurity, 325, 327*t*
  - location of, 327*t*
  - macular dragging associated with, 334, 334*f*
  - myopia associated with, 334
  - ocular examination for, 329, 331, 332*t*
  - panretinal photocoagulation for, 332, 333*f*
  - pathophysiology of, 325, 326*t*
  - plus disease, 326, 327*t*, 330*f*
  - pre-plus disease, 326, 327*t*, 330*f*
  - prethreshold disease, 326
  - pseudoexotropia associated with, 334, 335*f*
  - ranibizumab for, 333
  - risk factors for, 326–327
  - scleral buckling for, 335
  - screening for, 329, 331, 332*t*
  - sequelae of, 334–335
  - stage 1, 327*t*, 328*f*
  - stage 2, 327*t*, 328*f*
  - stage 3, 327*t*, 329*f*
  - stage 4, 327*t*, 329*f*
  - stage 5, 327*t*, 335
  - supplemental oxygen as risk factor for, 326–327
  - telemedicine for, 331
  - threshold level of, 331
  - treatment of, 331–334
  - type 1, 326, 331*t*, 332
  - type 2, 326, 331*t*, 332
  - vascular endothelial growth factor in, 325, 326*t*

- vitrectomy for, 335
  - zones of, 325, 328*f*
- Retinoschisis, juvenile
  - abusive head trauma as cause of, 383
  - description of, 342–343
  - diagnosis of, 344–345*f*
  - treatment of, 344
- Retinoscopy
  - cataract evaluations, 299
  - dynamic
    - accommodation measurements using, 9
    - in children, 9
- Retrolubar anesthesia, 174
- Retrogeniculate visual impairment, 186
- Reverse amblyopia, 55–56, 59–60
- RGCs. *See* Retinal ganglion cells
- Rhabdomyosarcoma
  - eyelid, 200
  - orbital, 217*f*, 217–218
- Rhegmatogenous retinal detachment, child abuse and, 384
- RHoT. *See* Right hypotropia
- Richner-Hanhart syndrome, 270
- Right hypotropia (RHoT), 17
- Riley-Day syndrome, 271
- Rituximab, 322
- Rod monochromatism, 337
- ROP. *See* Retinopathy of prematurity
- Rotations, ocular
  - definition of, 31
  - horizontal, 31
  - torsional, 31
  - vertical, 31
- RPE. *See* Retinal pigment epithelium
- RPE65 gene, 337
- RS1 gene, 342
- Rubella, 410*f*, 410–411
- Rush disease. *See* Aggressive posterior retinopathy of prematurity
  
- Saccadic system, 40
- Saccadic velocity, 73
- Sacculi, 40
- Saethre-Chotzen syndrome, 207, 208*f*
- Salmon patch, 269
- Sandhoff disease, 389*t*
- Sanfilippo syndrome, 388*t*
- Sarcoidosis, 318*f*, 318–319
- Satellite lesion, 409
- Scaphocephaly, 205
- Scheie syndrome, 270, 388*t*
- Schlemm canal, 286, 286*f*
- Schnyder corneal dystrophy, 270, 387*f*
- Schwalbe line, 255
- Schwannoma, orbital, 223
- Sclera
  - surgical perforation of, 30, 170
  - thinning of, from primary congenital glaucoma, 283
- Scleral buckling, for retinopathy of prematurity, 335
- Scleral spur, 181
- Sclerocornea, 257*t*, 260, 261*f*
- Scotoma
  - central suppression, 4Δ base-out prism test for, 79
  - suppression
    - description of, 49
    - 4Δ base-out prism test for, 79
    - Worth 4-dot test for, 80*f*, 80–81
- Seasonal allergic conjunctivitis, 246*f*, 246–248
- Secondary childhood glaucoma
  - acquired condition, 284
  - after cataract surgery, 285
  - classification of, 278*t*
  - nonacquired conditions associated with, 284*t*
- Secondary deviation
  - definition of, 39
  - primary deviation versus, 115
- Secondary diagnostic position of gaze, 31
- Secondary megalocornea, 254
- Sectoral cataracts, 297–298
- See-saw nystagmus, 152
- Semicircular canals, 40
- Senior-Løken syndrome, 391
- Sensory adaptation testing
  - afterimage test, 79, 79*f*
  - amblyoscope testing, 79–80
  - Bagolini lenses, 77*f*, 77–78
  - description of, 75
  - 4Δ base-out prism test, 78*f*, 78–79
  - red-glass test, 75–76, 76*f*
  - Worth 4-dot test, 80*f*, 80–81
- Sensory binocularity, 75
- Sensory esotropia, 93–94
- Sensory exotropia, 104
- Sensory fusion, 43
- Sensory nystagmus, 187
- Septo-optic dysplasia, 361, 363*f*
- Sequence, 183
- Serous retinal detachments, 362
- Shaken baby syndrome. *See* Abusive head trauma
- Sherrington's law of reciprocal innervation, 33
- Shield ulcer, 248, 249*f*
- Shunting, for idiopathic intracranial hypertension, 371
- Sialidosis, 388*t*
- Sickle cell trait/disease, 378
- Silver nitrate, for gonorrheal ophthalmia neonatorum, 239
- Simultaneous prism and cover test, 66–67
- Single binocular vision, 81–82, 82*f*
- Sinusitis, paranasal, 213, 214*f*
- Sixth nerve palsy, 95–97, 96*f*, 176
- SJS. *See* Stevens-Johnson syndrome
- Skew deviation, 125
- Skull
  - abnormal shapes of. *See* Craniosynostosis
  - bony growth of, 203
  - sutures of, 203–204, 204–205*f*
- SLC4A11 gene, 258
- Slit-lamp examination
  - in cataract evaluation, 300
  - in children, 4–5
  - in Duane retraction syndrome, 133
  - in uveitis associated with juvenile idiopathic arthritis, 314*f*
- Sly syndrome, 388*t*
- Smart System PC-Plus, 81
- Smoking, thyroid eye disease and, 140

- Smooth-pursuit system  
 description of, 40  
 in infantile esotropia, 88
- Snellen letters, monofixation syndrome and, 51  
 “Snow bank,” 316*f*
- Spasmus nutans syndrome, 151–152
- Spectral-domain optical coherence tomography  
 Best disease on, 342, 343*f*  
 juvenile retinoschisis on, 344, 344*f*
- Sphenoid dysplasia, 397
- Spherophakia, 305
- Spiral of Tillaux, 22, 23*f*, 169
- Spontaneous consecutive esotropia, 95
- Staphylococcus* sp  
 orbital cellulitis caused by, 213  
 preseptal cellulitis caused by, 213  
*S aureus*, 213, 240
- Staphyloma, peripapillary, 366
- Stargardt disease, 339–340, 340–341*f*
- Steady fixation, 6
- Stents, for congenital nasolacrimal duct obstruction, 234–235
- Stereoacuity  
 development of, 182  
 tests of  
 in monofixation syndrome, 51  
 sensory adaptation assessments using, 81
- Stereopsis  
 contour, 81  
 definition of, 43, 81  
 depth perception versus, 43  
 development of, 43  
 random-dot tests, 81  
 sensory tests for, 100
- Stevens-Johnson syndrome (SJS), 251–252, 252*f*
- Stickler syndrome, 183, 345–346
- Stimulus accommodative convergence/accommodation ratio, 71
- Stimulus deprivation amblyopia, 55
- Strabismic amblyopia  
 anisometric amblyopia versus, 54–55  
 clinical features of, 54  
 critical period for, 45  
 development of, 46–47  
 eccentric fixation in, 54  
 grating acuity associated with, 54, 56  
 occlusion therapy for, 58  
 pathophysiology of, 54  
 visual acuity in, 54
- Strabismus  
 abbreviations for, 17  
 abnormal visual experience caused by, 44  
 accommodative convergence/accommodation ratio  
 abnormalities as cause of, 39  
 acquired, 16  
 acute paralytic, 175  
 age at onset, 16  
 amblyopia treatment as cause of, 59–60  
 animal models of, 46  
 A-pattern. *See* A-pattern strabismus  
 in Apert syndrome, 208, 209*f*  
 Brown syndrome. *See* Brown syndrome  
 after cataract surgery, 304  
 classification terms for, 16–17  
 congenital, 16  
 consecutive, 16  
 convergent, 15  
 in craniostenosis, 208  
 cyclic, 93  
 cyclovertical, 162  
 definition of, 15  
 dissociated strabismus complex, 17, 105*f*  
 divergent, 15  
 early-onset, 154  
 history-taking for, 63  
 incomitant  
 abnormal head position caused by, 83  
 prism alternate cover test for, 66  
 infantile  
 description of, 16  
 dissociated vertical deviation associated with, 129  
 fusion maldevelopment nystagmus syndrome  
 associated with, 151, 154  
 primary inferior oblique muscle overaction  
 associated with, 117  
 intermittent, 182  
 latent  
 alternate cover test for, 65, 66*f*  
 description of, 15  
 exodeviation as, 99  
 manifest  
 alternate cover test for, 65, 66*f*  
 description of, 15  
 exodeviation as, 99  
 monocular cover-uncover test for, 64, 65*f*  
 normal retinal correspondence and, 48–49, 49*f*  
 nystagmus associated with, 154, 156–157  
 ocular surgery-related, 145–146  
 paralytic  
 extraocular muscle surgery for, 161  
 Hering’s law of motor correspondence and, 38  
 pattern. *See* Pattern strabismus  
 prefixes associated with, 15–16  
 restrictive, 146  
 screening for, 56  
 sensory adaptations in  
 anomalous retinal correspondence, 50–51  
 monofixation syndrome, 51–52  
 suppression, 48–50, 49*f*  
 sensory response to, 75  
 small-angle, 89  
 squinting associated with, 202  
 suffixes associated with, 15–16  
 terminology related to, 15–17  
 third nerve palsy. *See* Third nerve palsy  
 torticollis and, 63  
 types of, 17  
 vertical  
 description of, 15–16  
 diagnostic positions of gaze for, 64  
 V-pattern. *See* V-pattern strabismus  
 word origin of, 15
- Strabismus fixus, 135
- Strabismus surgery  
 anomalous retinal correspondence after, 50  
 esotropia treated with, 91

- infantile, monofixation syndrome after, 51
- tightening procedures in, 164*t*
- weakening procedures in, 164*t*
- Streptococcus* spp
  - bacterial conjunctivitis caused by, 240
  - preseptal cellulitis caused by, 213
  - S pneumoniae*, 213, 240
  - S pyogenes*, 213
- Striate cortex
  - description of, 44
  - monocular visual deprivation in, 44, 45
- STUMPED mnemonic, for corneal opacities, 257*t*, 257–258
- Sturge-Weber syndrome, 199, 251, 285, 349, 394*t*, 401*t*, 401–403, 402*f*
- Subarachnoid hemorrhage, 382
- Subconjunctival disorders, 250–252
- Subdural hematoma, 382
- Subperiosteal abscess, 213, 214*f*
- Subretinal fibrosis, in Coats disease, 360
- Subretinal hemorrhages, 373
- Sulfadiazine, for toxoplasmosis, 410
- Sulfite oxidase deficiency, 310
- Sunsetting, 185
- Superior oblique muscle
  - action of, 34*t*, 37*f*
  - characteristics of, 21*t*
  - congenital palsy of, 69
  - depressor function of, 73
  - field of action for, 33
  - innervation of, 19
  - origin of, 20, 21*t*
  - overaction of
    - A-pattern strabismus associated with, 107, 111
    - bilateral, 118*f*
    - description of, 17
    - horizontal deviation associated with, 118
    - overdepression in adduction caused by, 118, 118*f*, 137
  - palsy of
    - bilateral, 122–124
    - causes of, 119
    - clinical features of, 119–122
    - congenital versus acquired, 119
    - description of, 69
    - hypertropia associated with, 123
    - inhibitional palsy of contralateral antagonist, 120–121, 121*f*
    - management of, 122–124, 123*t*
    - masked bilateral, 122
    - neuroimaging evaluations, 119
    - right, 120–121*f*
    - surgical management of, 122–124, 123*t*
    - 3-step test for, 120
    - unilateral, 119–121, 120–121*f*, 122–123, 123*t*
    - V-pattern strabismus associated with, 109
  - paralysis of, inferior oblique muscle overaction
    - secondary to, 166
  - right, palsy of, 120–121*f*
  - tenotomy, 112, 138
  - tightening of, 123, 123*t*, 167
  - underaction of, 17
  - weakening of
    - bilateral, 166
    - for Brown syndrome, 138, 166
    - for  $\lambda$ -pattern strabismus, 113
    - for nystagmus, 156
    - surgical procedures for, 164*t*, 166
    - tenotomy for, 166
    - unilateral, 166
  - weakness of, 119
- Superior oblique myokymia, 145
- Superior oblique tendon
  - anatomy of, 19*f*
  - tightening of, 167
- Superior orbital vein, 23
- Superior rectus muscle
  - action of, 34*t*, 35, 36*f*
  - characteristics of, 21*t*
  - elevator function of, 73
  - innervation of, 19
  - intorsion of, 34
  - Knapp procedure, 127
  - origin of, 20, 21*t*, 22*f*
  - recession of, 30, 128, 130
  - resection of, 30
  - surgery considerations for, 29–30
  - transposition of, 167
- Superior rectus tendon, 19*f*
- Supplemental oxygen, retinopathy of prematurity risks
  - secondary to, 326–327
- Suppression
  - alternating, 49
  - central, 48
  - constant, 49
  - definition of, 48
  - facultative, 49
  - management of, 50
  - nonalternating, 49
  - orthoptic exercises for, 50
  - pathologic, 48
  - peripheral, 48
  - physiologic, 48
  - red-glass test findings in, 76*f*
  - as strabismus adaptation, 48–50, 49*f*
- Suppression scotoma
  - description of, 49
  - 4 $\Delta$  base-out prism test for, 79
  - Worth 4-dot test for, 80*f*, 80–81
- Supranuclear control systems, for eye movements, 40
- Surgery
  - cataract. *See* Cataract surgery
  - childhood glaucoma treated with, 285–288, 286*f*, 288*f*
  - extraocular muscle. *See* Extraocular muscle surgery
  - high AC/A ratio accommodative esotropia treated with, 92
  - intermittent exotropia treated with, 102–103
  - lens subluxation treated with, 310
  - primary congenital glaucoma treated with, 285–288, 286*f*, 288*f*
  - Sursumversion, 37
  - Sutural cysts, 224
  - Symblepharon, 146
  - Symbol charts, 7
  - Symmetric convergence, 41

- Syndactyly, in Apert syndrome, 206, 207f  
 Syndrome, 183. *See also specific syndrome*  
 Synergist, 33  
 Synergistic divergence, 133  
 Syphilis, congenital, 269, 412–413  
 Systemic diseases  
   ataxia-telangiectasia, 393t, 403f, 403t, 403–404  
   chromosomal abnormalities, 385, 386t  
   diabetes mellitus, 408–409  
   familial oculorenal syndromes, 391–392, 391–392f  
   inborn errors of metabolism. *See* Inborn errors of metabolism  
   intrauterine infections, 409–413  
   intrauterine/perinatal infections, 409–413  
   Leber congenital amaurosis-like phenotypes in, 336  
   leukemia, 413–414  
   malignant, 413–415  
   neuroblastoma, 414–415, 415f  
   neuro-oculocutaneous syndromes. *See* Neuro-oculocutaneous syndromes  
   ocular manifestations of, 385–415  
   von Hippel–Lindau syndrome, 393t, 399–401, 400f, 400t
- Tarsal kink, congenital, 194–195  
 Tarsorrhaphy, 207–208  
 Tay-Sachs disease, 389t  
 TCOF1 gene, 211  
 TED. *See* Thyroid eye disease  
 Telecanthus, 203  
 Telemedicine, 331  
 Teller Acuity Cards II, 8, 9f, 56, 154, 187  
 TEN. *See* Toxic epidermal necrolysis  
 Tenacious proximal fusion  
   definition of, 100  
   in intermittent exotropia, 71, 100  
 Tendon–trochlea complex, 20  
 Tenectomy, 164t  
 Tenon capsule  
   anatomy of, 25–27, 27f  
   posterior portion of, 27  
   scarring of, 171  
   surgical penetration of, 30  
 Tenotomy  
   definition of, 164t  
   superior oblique muscle, 112, 138  
 Teratoma, orbital, 225f, 225–226  
 Tertiary diagnostic position of gaze, 31  
 Thermal injury, 376  
 Third nerve palsy  
   acquired, 138  
   amblyopia with, 138  
   clinical features of, 138  
   complete, 139  
   congenital, 138  
   diplopia in, 139  
   incomplete, 139  
   management of, 138–140  
   spontaneous recovery of, 138  
   surgical management of, 139–140  
   upper eyelid ptosis associated with, 138, 139f  
 3-step test  
   description of, 73–75, 74f  
   unilateral superior oblique muscle palsy diagnosis using, 120  
 Thygeson superficial punctate keratitis, 269  
 Thyroid eye disease (TED), 140–141, 141f, 143t, 175, 215  
 Thyroid-stimulating immunoglobulins, 140  
 Tics, ocular, 201–202  
 Tightening procedures  
   for inferior oblique muscle, 166  
   for oblique muscles, 164t, 166–167  
   for rectus muscles, 163–164, 164t  
   for superior oblique muscle, 167  
 Tilted disc, 365–366, 366f  
 TINU. *See* Tubulointerstitial nephritis and uveitis syndrome  
 Titmus test, 81  
 TMEM98 gene, 263  
 TNO test, 81  
 Tonic convergence, 40  
 Tonic pupil, 275  
 Tonometry  
   in children, 10  
   in primary congenital glaucoma evaluations, 281–282  
 Tono-Pen, 10, 281  
 Topiramate  
   glaucoma caused by, 284  
   idiopathic intracranial hypertension treated with, 371  
 Torsional deviations, dissociated, 17, 129  
 Torsional fusional vergence, 72  
 Torticollis  
   abnormal head position associated with, 82  
   definition of, 82  
   differential diagnosis of, 82–84, 83t  
   evaluation of, 84  
   facial asymmetry and, 82  
   history-taking for, 63  
   ocular, 82–84, 83t  
   strabismus and, 63  
 Tourette syndrome, 202  
 Touton giant cells, 271  
 Toxic epidermal necrolysis (TEN), 251–252  
*Toxocara canis*, 317  
*Toxocara cati*, 317  
 Toxocariasis, 317f, 317–318  
*Toxoplasma chorioretinitis*, 409, 410f  
*Toxoplasma gondii*, 409  
 Toxoplasmosis  
   anterior uveitis caused by, 317  
   ocular manifestations of, 409–410, 410f  
 Trabeculectomy, 323  
 Trabeculotomy, for primary congenital glaucoma, 286f, 286–287  
 Trachoma, 241  
 Tractional retinal detachment, 348f, 360  
 Transillumination, iris, 265  
 Trauma, ocular  
   abusive head trauma, 381–384, 382–383f  
   accidental, 375–381, 377–378f, 380f  
   amblyopia secondary to, 375  
   anterior uveitis caused by, 316  
   blunt, 378–379  
   chemical injury, 376  
   corneal abrasion, 376  
   hyphema, 378f, 378–379

- incidence of, 375  
 management of, 375  
 nonaccidental  
   abusive head trauma, 381–384, 382–383f  
   ocular injury secondary to, 384  
   optic neuropathy caused by, 381  
   orbital floor fractures, 127–128, 128f, 379–380, 380f  
   orbital roof fractures, 380, 380f  
   penetrating, 376–378, 377f  
   perforating, 376–378, 377f  
   thermal injury, 376
- Traumatic breaks in Descemet membrane, 262, 262f
- Treacher Collins syndrome, 196, 211, 211f
- Treponema pallidum*, 240, 412
- Trichotillomania, 201, 201f
- Trisomy 13, 386t
- Trisomy 18, 386t
- Trisomy 21. *See* Down syndrome
- Trochlea  
   anatomy of, 19f  
   function of, 20
- Trochlear nerve  
   extraocular muscle innervation by, 19  
   palsy of, 140
- tropia (suffix), 16
- Tropicamide, 11, 11t
- TS. *See* Tuberous sclerosis
- TSC2 gene, 399
- TUBB3* gene, 135
- Tuberous sclerosis (TS), 393t, 397–399, 398f, 398t
- Tube shunts, 146, 287, 323
- Tubulointerstitial nephritis and uveitis (TINU)  
   syndrome, 316
- Tuck, 164t
- Tumbling E chart, 7
- Tumor(s). *See also* Neoplasms  
   anterior segment, 271–274  
   bony, 222  
   choristomatous, 225–226  
   ciliary body, 273f, 273–274  
   connective tissue, 222  
   corneal, 271  
   iris, 271–273, 272f  
   neural, 223
- Tumor necrosis factor- $\alpha$  inhibitors, 322
- Turner syndrome, 386t
- TWIST* gene, 206
- Tyrosinemia type II, 270
- UBIAD1* gene, 270
- UC fixation. *See* Uncentral (UC) fixation
- UDAd. *See* Underdepression in adduction
- UEAd. *See* Underelevation in adduction
- Ulcers, corneal, 248, 249f, 262–263
- Ultrasonic phacoemulsification, 302
- Uncentral, unsteady, and unmaintained fixation, 6
- Uncentral (UC) fixation, 6
- Uncrossed diplopia, 75
- Underdepression in adduction (UDAd), 17
- Underelevation in adduction (UEAd), 17
- Unharmonious anomalous retinal correspondence, 76
- Unifocal eosinophilic granuloma, 219, 219f
- Upgaze, 37
- Upper eyelid  
   hematoma of, in orbital roof fractures, 380, 380f  
   in plexiform neurofibromas, 395–396  
   ptosis of, in third nerve palsy, 138, 139f  
   retraction of, in thyroid eye disease, 140, 141f
- Utricle, 40
- Uveitis  
   anterior  
     description of, 312  
     differential diagnosis of, 312t  
     idiopathic causes of, 316  
     juvenile idiopathic arthritis as cause of, 312–315,  
       313–314t, 314f, 322  
     juvenile spondyloarthropathies as cause of, 315,  
       315t  
     Kawasaki disease as cause of, 316  
     laboratory tests for, 321t  
     screening for, 314–315  
     trauma as cause of, 316  
     tubulointerstitial nephritis and uveitis syndrome as  
       cause of, 316  
   band keratopathy caused by, 322  
   biologic drugs for, 322  
   cataract surgery in, 323  
   classification of, 311  
   complications of, surgical treatment of, 322–323  
   corticosteroids for, 320–321  
   definition of, 311  
   diagnosis of, 319  
   differential diagnosis of, 312t  
   epidemiology of, 311  
   evaluation of, 319  
   glaucoma surgery in, 323  
   imaging for, 321t  
   immunosuppressive therapy for, 321–322  
   inflammation in, 320–322  
   intermediate, 312t, 316, 316f, 320, 321t  
   laboratory tests for, 321t  
   masquerade syndromes for, 319, 320t  
   methotrexate for, 322  
   panuveitis, 318f, 318–319  
   posterior  
     definition of, 317  
     differential diagnosis of, 312t  
     inflammation in, 320  
     laboratory tests for, 321t  
     toxocariasis as cause of, 317f, 317–318  
     toxoplasmosis as cause of, 317  
   treatment of, 320–322
- Valsalva maneuver, 207
- Valve of Hasner, 230, 231f
- Valve of Rosenmüller, 228
- Varicella-zoster virus (VZV), 242–243
- Vascular endothelial growth factor (VEGF), in  
   retinopathy of prematurity pathophysiology, 325,  
   326t
- Vascular eyelid disorders, 199
- Vasoconstrictors, for ocular allergies, 247t
- VEGF. *See* Vascular endothelial growth factor (VEGF),  
   in retinopathy of prematurity pathophysiology
- Velocardiofacial syndrome, 255
- Venous malformations, orbital, 222

- VEP. *See* Visual evoked potential
- Vergences
- convergence, 39–40
  - definition of, 37, 39, 72
  - divergence, 40
  - fusional, 72, 72*t*
- Vergence system, of eye movements, 40
- Vernal keratoconjunctivitis (VKC), 248–249, 248–249*f*
- Versions
- definition of, 37
  - deorsumversion, 37
  - dextrocycloverversion, 38
  - dextroversion, 37
  - in infantile esotropia, 37
  - levocycloverversion, 38
  - levoversion, 37
  - sursumversion, 37
- Vertical deviations
- characteristics of, 116
  - clinical approach to, 115–116
  - dissociated
    - age at onset, 129
    - clinical features of, 129, 129*f*
    - definition of, 129
    - description of, 17, 105, 111, 115–116
    - hypertropia and, 115
    - inferior oblique anterior transposition for, 166
    - inferior oblique muscle overaction versus, 129–130
    - management of, 130
  - with horizontal comitance, 125–128
  - with horizontal incomitance, 116–125
  - inferior oblique muscle palsy
    - Brown syndrome versus, 124, 125*t*
    - clinical features of, 124, 124*f*, 125*t*
    - management of, 124–125
  - monocular elevation deficiency, 125–127, 126*f*
  - orbital floor fractures, 127–128, 128*f*
  - overdepression in adduction
    - causes of, 17, 116*t*, 116–118
    - description of, 17
    - pattern strabismus and, 107, 108*f*, 109
    - superior oblique muscle overaction as cause of, 118, 118*f*
  - overelevation in adduction
    - causes of, 17, 116*t*, 116–118
    - description of, 17
    - inferior oblique muscle overaction as cause of, 117*f*, 117–118
    - pattern strabismus and, 107, 108*f*, 109
  - skew deviation, 125
  - superior oblique muscle palsy
    - bilateral, 122–124
    - causes of, 119
    - clinical features of, 119–122
    - congenital versus acquired, 119
    - description of, 69
    - hypertropia associated with, 123
    - inhibitional palsy of contralateral antagonist, 120–121, 121*f*
    - management of, 122–124, 123*t*
    - masked bilateral, 122
    - neuroimaging evaluations, 119
    - right, 120–121*f*
    - surgical management of, 122–124, 123*t*
    - 3-step test for, 120
    - unilateral, 119–121, 120–121*f*, 122–123, 123*t*
    - V-pattern strabismus associated with, 109
    - thyroid eye disease as cause of, 140
- Vertical fusional vergence, 72
- Vertical nystagmus, 152
- Vertical rectus muscles
- anatomy of, 20, 22*f*
  - eyelid attachments to, 30*f*
  - insertion of, 22
  - surgery of
    - for nystagmus, 156
    - for pattern strabismus correction, 111
  - vertical strength of, 35
- Vertical retraction syndrome, 135
- Vertical rotations, 31
- Vertical strabismus, 15–16
- Vestibular-ocular system, 40
- VHL gene, 399
- Vieth-Müller circle, 41
- Vigabatrin, 399
- Viral conjunctivitis, 241–243, 243–244*f*
- Virchow's law, 203, 205*f*
- Visceral larva migrans (VLM), 317
- Vision
- binocular. *See* Binocular vision
  - decreased, evaluation of, 187–188
  - development of
    - abnormal visual experience effects on, 44–47, 45–46*f*
    - amblyopia and, 53
    - description of, 44
    - in young infants, 185
  - low
    - information sources on, 189*t*
    - rehabilitation for, 188–189, 189*t*
    - neurophysiology of, 43–52
- Vision loss
- amblyopia as cause of, 53, 56
  - childhood glaucoma as cause of, 290
- Vision rehabilitation, 188–189, 189*t*
- Visual acuity
- amblyopia effects on, 5
  - assessments of
    - for amblyopia diagnosis, 56
    - in children. *See* Visual acuity, in children
    - in nystagmus, 153–154
  - in children, assessment of
    - age-specific approaches, 5
    - alternative methods, 8–9
    - Central, Steady, and Maintained method of, 6
    - eye charts for, 6*t*, 6–8, 7*f*
    - fixation and following behavior for, 5
    - fixation behavior, 5–6
    - HOTV test, 6, 6*t*, 7*f*
    - induced tropia test, 6
    - in nystagmus, 8
    - occluders used in, 8
    - optotypes for, 6*t*, 6–8, 7*f*
    - preferential looking, 5, 8–9, 9*f*, 182, 300
    - preverbal children, 8–9, 154
    - sequence of, 8

- symbol charts for, 7
  - visual evoked potential for, 9, 182, 300
- development of, 182
- in morning glory disc anomaly, 363
- in newborn, 44
- Visual axis, 41
- Visual confusion, 47, 47*f*
- Visual cortex, 46*f*
- Visual deprivation
  - abnormal visual experience caused by, 44
  - monocular, 44, 45*f*
- Visual deprivation amblyopia
  - causes of, 55
  - congenital cataracts as cause of, 55
  - congenital nevocellular nevi as cause of, 200
  - corneal blood staining as cause of, 379
  - critical period for, 53
  - reverse amblyopia, 55–56
- Visual evoked potential (VEP), for visual acuity
  - assessment in preverbal children, 9, 182, 300
- Visual field testing, 10
- Visual impairment
  - cerebral, 186–187
  - cortical, 186
  - delayed visual maturation, 186–187
  - in infants, 186–187
  - pregeniculate, 186–187
  - retrogeniculate, 186
- Visual pathways
  - central, 44
  - development of, 44
  - white matter of, 44
- Visual stimulus deprivation amblyopia, 55
- Vitreal syneresis, 344
- Vitrectomy, for retinopathy of prematurity, 335
- Vitreorhexis, 302
- Vitreoretinopathies
  - familial exudative, 347–348, 348*f*
  - juvenile retinoschisis. *See* Juvenile retinoschisis
  - Knobloch syndrome, 346*f*, 346–347
  - Norrie disease, 347
  - Stickler syndrome, 345–346
- Vitreous veils, 344
- VKC. *See* Vernal keratoconjunctivitis
- VLM. *See* Visceral larva migrans
- Vogt-Koyanagi-Harada syndrome, 319
- Vogt striae, 254
- Vogt triad, 397
- Voluntary convergence, 40
- von Hippel internal ulcer, 259
- von Hippel–Lindau syndrome, 393*t*, 399–401, 400*f*, 400*t*
- von Recklinghausen disease. *See* Neurofibromatosis
  - type 1
- Vortex keratopathy, 270
- Vortex veins
  - extraocular muscles supplied by, 23
  - surgical considerations for, 30
- V-pattern strabismus
  - bilateral superior oblique palsy and, 122
  - in Brown syndrome, 137
  - clinical features of, 109
  - clinically significant, 109
  - craniofacial anomalies and, 107
  - in craniostylosis, 208
  - definition of, 107
  - etiology of, 107–109, 108*f*
  - exotropia with, 108*f*, 111
  - extorsion as cause of, 107, 110
  - heterotopy as cause of, 28
  - identification of, 109
  - infantile esotropia associated with, 109, 112
  - inferior oblique muscle overaction associated with, 107
  - palpebral fissure slanting associated with, 196
  - superior oblique palsy and, 122
  - surgical treatment of, 111–112, 112*t*
- VZV. *See* Varicella-zoster virus
- Waardenburg syndrome
  - description of, 270
  - type 1, 191, 192*f*
- WAGR syndrome, 267
- Weakening procedures
  - for inferior oblique muscle
    - bilateral, 165
    - indications for, 118
    - for superior oblique muscle palsy, 123, 123*t*
    - surgical procedures for, 164*t*, 165–166
    - for V-pattern strabismus, 111
  - for oblique muscles, 164*t*, 165–166
  - for rectus muscles, 163, 164*t*
- Weill-Marchesani syndrome, 309
- Well-differentiated pleomorphic tumors, 217
- White-eyed blowout fracture, 380
- Wildervanck syndrome, 131
- Wilson disease, 270
- Wolfflin nodules, 272
- Wolf-Hirschhorn syndrome, 386*t*
- Worth 4-dot test, 51–52, 80*f*, 80–81
- WT1* gene, 267
- Wyburn-Mason syndrome, 222, 394*t*, 405*t*, 405–406
- Xanthocoria, 360
- X-pattern strabismus
  - clinical features of, 110
  - surgical treatment of, 113
- Yersinia pseudotuberculosis*, 240
- Yoke muscles, 38
  - Y-pattern strabismus
    - clinical features of, 109–110
    - surgical treatment of, 113
- Zika virus, 413
- ZNF469* gene, 254



